



## **Gonadal Restructuring and Correlative Steroid Hormone Profiles during Natural Sex Change in Protogynous Honeycomb Grouper (*Epinephelus merra*)**

Authors: Bhandari, Ramji Kumar, Komuro, Hiroki, Nakamura, Shigeo, Higa, Mikihiro, and Nakamura, Masaru

Source: Zoological Science, 20(11) : 1399-1404

Published By: Zoological Society of Japan

URL: <https://doi.org/10.2108/zsj.20.1399>

---

BioOne Complete ([complete.BioOne.org](https://complete.BioOne.org)) is a full-text database of 200 subscribed and open-access titles in the biological, ecological, and environmental sciences published by nonprofit societies, associations, museums, institutions, and presses.

Your use of this PDF, the BioOne Complete website, and all posted and associated content indicates your acceptance of BioOne's Terms of Use, available at [www.bioone.org/terms-of-use](https://www.bioone.org/terms-of-use).

Usage of BioOne Complete content is strictly limited to personal, educational, and non - commercial use. Commercial inquiries or rights and permissions requests should be directed to the individual publisher as copyright holder.

---

BioOne sees sustainable scholarly publishing as an inherently collaborative enterprise connecting authors, nonprofit publishers, academic institutions, research libraries, and research funders in the common goal of maximizing access to critical research.

# Gonadal Restructuring and Correlative Steroid Hormone Profiles during Natural Sex Change in Protogynous Honeycomb Grouper (*Epinephelus merra*)

Ramji Kumar Bhandari, Hiroki Komuro, Shigeo Nakamura,  
Mikihiko Higa and Masaru Nakamura\*

*Sesoko Station, Tropical Biosphere Research Center, University of the Ryukyus,  
Sesoko, Motobu, Okinawa 905-0227, Japan*

**ABSTRACT**—The honeycomb grouper shows protogynous hermaphroditism. The endocrine mechanisms involved in gonadal restructuring throughout protogynous sex change are largely unknown. In the present study, we investigated changes in the gonadal structures and levels of serum sex steroid hormones during female to male sex change in the honeycomb grouper. On the basis of histological changes, entire process of sex change was assigned into four developmental phases: female, early transition (ET), late transition (LT), and male phase. At the female phase, the oocytes of several developmental stages were observed including gonial germ cells in the periphery of ovigerous lamellae. At the beginning of ET phase, perinucleolar and previtellogenic oocytes began degenerating, followed by proliferation of spermatogonia toward the center of lamella. The LT phase was characterized by further degeneration of oocytes and rapid proliferation of spermatogenic germ cells throughout the gonad. At the male phase, no ovarian cells were observed and testis had germ cells undergoing active spermatogenesis. Serum levels of estradiol-17 $\beta$  (E2) were high in females in the breeding season, but low in the non-breeding female, transitional and male phase, and those of 11-ketotestosterone (11-KT) and testosterone (T) were low in females and gradually increased in the transitional and male phase. The present results suggest that low serum E2 levels and degeneration of oocytes accompanied by concomitant increase in the 11-KT levels and proliferation of spermatogenic germ cells are probably the events mediating protogynous sex change in the honeycomb grouper.

**Key words:** natural sex change, gonadal restructuring, steroid profile, honeycomb grouper, protogynous hermaphrodite fish

## INTRODUCTION

In marine hermaphrodite fishes, sex changes are accomplished by complete alteration of gonadal anatomy and function as well as changes in color and behavior (Tang *et al.*, 1975; Reinboth, 1979; Shapiro, 1987). In protogynous hermaphrodite fishes, sequential phases of sex change are female  $\rightarrow$  transition  $\rightarrow$  male (Shapiro, 1987). It is still unknown when exactly, and what triggers their sex change from female to functional males. In contrast to numerous studies on reproductive cycles of protogynous hermaphrodite fishes (Cardwell and Liley; 1991; Johnson *et al.*, 1998; Lee *et al.*, 2002), very few studies have pointed out the endocrine changes in fish that undergo female to male sex

change (Tan and Tan, 1974; Chen *et al.*, 1980; Reinboth, 1979, 1988; Nakamura *et al.*, 1989; Siau, 1994). A rapid drop in plasma estradiol-17 $\beta$  (E2) levels and degeneration of vitellogenic oocytes were observed in wrasse, *Thalassoma duperrey*, during the onset of protogynous sex change (Nakamura *et al.*, 1989), indicating rapid decline in E2 levels may be necessary for the initiation of sex change in this species. However, the mechanisms of sex change in other protogynous hermaphrodites are largely unknown.

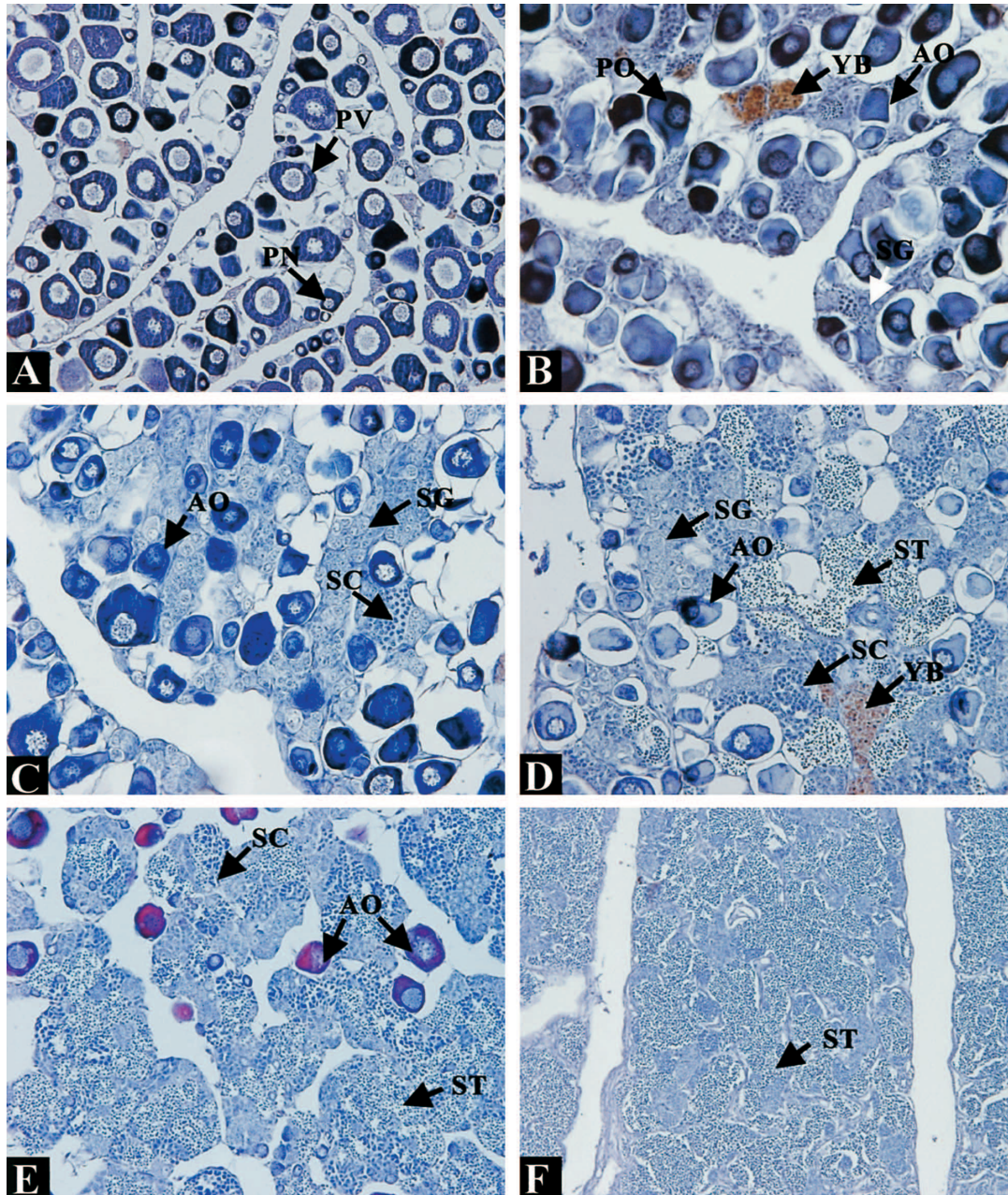
The honeycomb grouper, *Epinephelus merra*, is one of smallest species in genera *Epinephelus* and easily available in its wild, thus it could be a good model for protogynous sex change among grouper species. The ovary possesses some undifferentiated gonidia (personal observation) or already differentiated spermatogenic germ cells (Kobayashi *et al.*, 2000), which could be the point of departure for future spermatogonial proliferation (Brusle, 1987). In order to elucidate

\* Corresponding author: Tel. +81-980-47-6072;  
FAX. +81-980-47-6072.  
E-mail: masaru@lab.u-ryukyu.ac.jp

the mechanisms involved in the gonadal restructuring during protogynous sex change in grouper, a large number of individuals possessing transitional gonads are needed, which is extremely difficult to manage from wild populations. In the present study, we collected wild honeycomb groupers covering females, males and those possessing transitional gonads and examined gonadal succession, and the levels of sex steroid hormones to explain the endocrine mechanisms mediating protogynous sex change in *E. merra*.

## MATERIALS AND METHODS

Wild honeycomb groupers were collected every month by hook and line or bought from anglers of Nakijin village, northern Okinawa, from December 2001 through December 2002. Every month 10–30 fish were sacrificed. After anaesthetization with 0.05% phenoxyethanol (Kanto Chemicals, Japan), total length and body weight were measured, blood was collected from the caudal vein and separated serum was stored at  $-30^{\circ}\text{C}$  until analysis. The gonads were weighed to calculate gonadosomatic index (GSI; gonad 100 x



**Fig. 1.** Light micrograph ( $\times 200$ ) of gonadal structure of honeycomb grouper observed during protogynous sex change. (A): ovary at female phase, (B and C): early transition gonad, (D and E): late transition gonad, and (F): testis at functional male phase. Abbreviations: AO, atretic oocyte; PN, perinucleolar stage oocyte; PV previtellogenic stage oocyte; SG, spermatogonia; SC, spermatocyte; ST, spermatid; YB, yellow-brown substance.

weight/body weight) and a small piece of gonad was preserved in the Bouin's solution for 24 hr and subsequently transferred to 70% ethanol for storage. Later, fixed gonads were dehydrated and embedded in paraffin and sectioned (7  $\mu$ m). Sections were stained with hematoxylin and eosin (HE) and examined under a compound microscope.

Serum levels of testosterone (T), E2 and 11-ketotestosterone (11-KT) were determined by enzyme-linked immunosorbent assay (ELISA) according to Rahman *et al.* (2000). The inter- and intra-assay variations were below 11 and 3.5%, respectively. The changes in the serum levels of sex steroid hormone were analyzed by one-way ANOVA followed by Bonferroni's posthoc test using SPSS for windows software (SPSS Inc., Chicago, USA).

## RESULTS

One hundred and seventy one individuals were collected over 12-months from December 2001 to December 2002. All gonads were examined histologically and assigned process of sex change into four phases: (1) female, (2) early transition (ET), (3) late transition (LT), and (4) male phase on the basis of histological changes in germinal and somatic tissues of the gonad.

### 1. Female Phase

The ovary of *E. merra* is divided into two lobes, located on either side of the intestine, attached to the peritoneal wall. The lobes are fused at the posterior region of the ovary. Ovarian tissue was arranged in lamellae, which extended into the ventral, membrane-bound ovarian cavity or lumen. In non-breeding season (September to December), ovaries were characterized by the presence of oocytes at primary chromatin nucleolar, perinucleolar, and yolk vesicle stages, while mature ovary contained vitellogenic or hydrated oocytes in May through July. A mass of cells and cellular debris containing yellow-brown (YB) substances, which did not stain with HE was characteristically observed in the central region of ovigerous lamellae. A few gonial germ cells were distributed in the periphery of the lamellae (Fig. 1A); some were already developed into presumed-spermatogonia.

### 2. Early transition phase

The onset of sex change was characterized by the degeneration of primary oocytes, and simultaneous spermatogonial proliferation in the germinal epithelium lining ovarian lumen (Fig. 1B). As degeneration progressed, oocytes were absorbed and proliferation by spermatogenic germ cells increased further towards the central region of ovigerous lamellae (Fig. 1C). The mass of yellow brown cells persisted in the central region of lamella. This phase was observed from August through March.

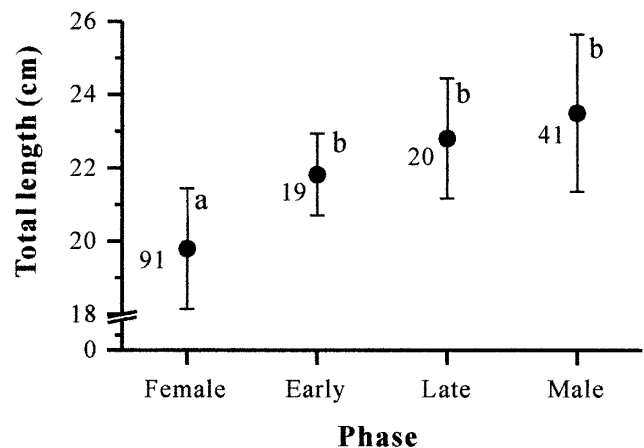
### 3. Late transition phase

At this stage, only a few degenerating pre-vitellogenic oocytes remained in the lamellae and there was an increasing tendency of spermatogenic germ cells, which covered almost 75% of the ovarian lamellae (Fig. 1D). At the end of

this stage, almost all atretic oocytes were absorbed, and those remaining were undergoing further degeneration and gonad was transformed into testis containing spermatogenic germ cells at various developmental stages from spermatogonia to spermatids (Fig. 1E). This phase was observed from December through May.

### 4. Male phase

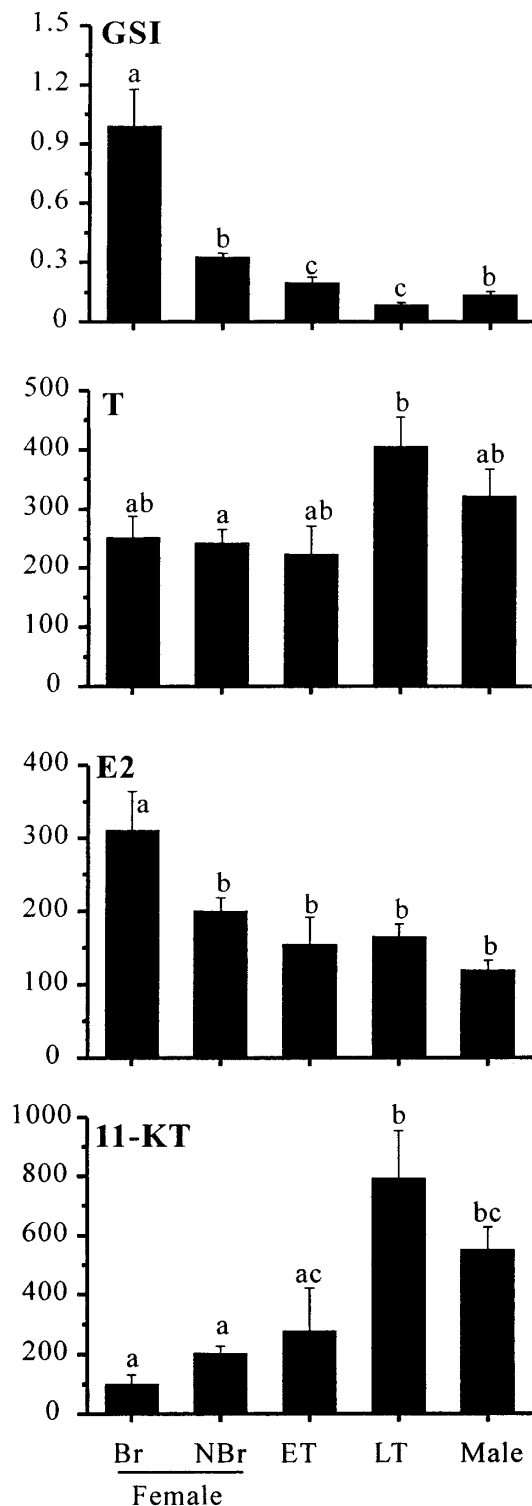
The individuals possessing gonads at this stage were observed throughout experimental period. In non-breeding season from September to December, spermatogenic germ cells mainly spermatogonia occupied the whole gonad. In breeding season from May to July, active spermatogenesis and spermiation proceeded in all parts of testis. No oocytes were observed in the gonads at this phase (Fig. 1F).



**Fig. 2.** Total length (TL) of honeycomb groupers undergoing female to male sex change. Numbers in the figures indicate total number of fish sampled. Different letters (a, b) indicate significant difference ( $P < 0.05$ ) among the means.

**Table 1.** Sex distribution of honeycomb grouper collected from December 2001 through December 2002. Abbreviations: ET, early transition; LT, late transition.

		Female	ET	LT	Male		
2001	Dec	6	2	1	0	↑	Non-breeding
2001	Feb	12	3	7	4		
	Mar	6	3	8	4	↓	Non-breeding
	May	14	0	1	8		
	Jul	7	0	0	7	↑	Breeding
	Aug	5	1	0	2		
	Sep	9	1	0	8	↑	Non-breeding
	Oct	10	2	0	3		
	Nov	11	3	0	3		
	Dec	11	4	3	2		



**Fig. 3.** Changes in gonadosomatic index (GSI), serum levels of testosterone (T), estradiol-17 $\beta$  (E2) and 11-ketotestosterone (11-KT) in honeycomb grouper during female to male sex change. Data are means and error bars represent standard errors. Abbreviations: Br, breeding season; NBr, non-breeding season; ET, early transition phase; LT, late transition phase. Bars marked with the same letter were not significantly different with each other.

### Body size and sex distribution

The mean total length (TL) of females was  $19.9 \pm 1.7$  cm. Transitionals and males had significantly higher TL than females, males being relatively bigger than remaining phases (Fig. 2). Sex distributions from December 2001 to December 2002 are shown in Table 1. The non-breeding season included the sampling period from December 2001 through March 2002, and August 2002 through December 2002, whereas breeding season was from April 2002 through July 2002. The GSI values were high in females in the breeding season and low in non-breeding females, ET, LT and male phase (Fig. 3).

### Levels of serum steroid hormones

Serum levels of E2, 11-KT and T are shown in the Fig. 3. Serum E2 levels were highest in females during breeding season, which remained low in the females in the non-breeding season, transitionals and males. In contrast, serum T and 11-KT levels were low in females and gradually increased with sex change with peak in the LT phase.

### DISCUSSION

We collected wild honeycomb groupers every month for one year, which comprised a large numbers of females, transitional and males. Differences in the gonads of fish at several stages of sex change were assumed to reflect the normal progression of sex change since the same individuals could not be sampled repeatedly. On the basis of histological observations, gonadal transformation was divided into four phases: female, ET, LT, and male. The average TL of females was less than 20 cm, and size distribution as assessed by TL was in order as female < ET < LT < male. Besides a strong association between the successive size increase and transformation of *E. merra* females into males, large females (20 to 23 cm) were also occasionally sampled. In the protogynous hermaphrodites, an overlap in size distribution between males and females exists (Smith, 1965; Tan and Tan, 1974; Chen *et al.*, 1980; Abu-Hakima, 1987). Although similar overlap was observed in *E. merra*, the average TL of females was significantly lower than that of transitionals and males. Similarly, TL of all female *E. merra* collected during both breeding and non-breeding seasons did not exceed 20 cm (Soyano K, 2003, personal communication). Taken together, in *E. merra*, size differences are correlated with the degree of sex change, with 20 cm in TL be a threshold size for the sex change.

We observed ET phase gonad from December 2001 through March 2002 and from August through December 2002, and LT phase gonad in March and May 2002. In July, no individuals possessing transitional gonad were observed. An overlap in the sex distribution of transitional individuals from December through March indicates that a shift from ET to LT phase was likely to occur during this period. Although, the present evidences could not be sufficient to strongly point out the exact timing for the commencement and termi-

nation of sex change, the appearance of ET phase soon after spawning season and LT phase in the pre-spawning season suggest that the sex change is likely to commence soon after spawning, continues through non-breeding season and tends to terminate in following spawning season. Sexual transition in protogynous hermaphrodites generally occurs in the non-breeding season (Smith, 1965). In the estuarine grouper, *E. tauvina*, the transition from female to male took more than one year to complete (Tan and Tan, 1974), whereas in *E. diacanthus*, sex change occurred during non-reproductive period and completed in following spawning season (Chen *et al.*, 1980). In order to examine sequential changes in the gonadal structure, same individuals should be repeatedly sampled, which could not be performed due to difficulty in artificial rearing of fish and disease susceptibility.

During early stages of sex change, low serum E2 levels were accompanied by degeneration of primary oocytes. Concomitantly, a gradual increase in 11-KT and T levels and rapid proliferation of spermatogenic germ cells were observed. It is probable that, during the non-breeding season, maintenance of low E2 levels and concomitant increase in 11-KT levels could be stimulatory to commencement of female to male sex change in the honeycomb grouper. The further progress of sex change (LT phase) was marked by complete disappearance of perinucleolar oocytes, increased atresia of remaining previtellogenic oocytes and proliferation of spermatogenic germ cells into the inner side of ovigerous lamellae, which in the gonads of some individuals were sparse and intermingled with the ovarian tissues. At the end of this phase, atretic oocytes were reabsorbed and the gonad was completely transformed into testis. Serum levels of E2 were low, while the levels of 11-KT peaked at this period. Taken together, present results indicate that sex change in *E. merra* accomplish with increasing 11-KT levels, while E2 levels are low, which is concurrent with degeneration of oocytes and simultaneous proliferation of spermatogenic germ cells. Similar changes are reported in the red grouper, *E. morio* (Johnson *et al.*, 1998) and wrasse, *T. duperrey* (Nakamura *et al.*, 1989).

In teleosts, E2 is involved in the maintenance of the female state (Fostier *et al.*, 1983), and 11-KT in spermatogenesis (Nagahama *et al.*, 1994; Miura and Miura, 2001). In *E. merra*, treatment with aromatase inhibitor (Fadrozole) *in vivo* suppressed serum E2 levels and elevated 11-KT levels leading to complete sex change from female to male including spermiation in the sex-changed males (Bhandari *et al.*, unpublished). Moreover, treatments with 11-KT have caused complete female to male sex change in many protogynous hermaphrodites (Cardwell and Liley, 1991; Grober *et al.*, 1991; Kroon and Liley, 2000; Yeh *et al.*, 2003). These reports support the present results that 11-KT plays an important role in natural sex change of honeycomb grouper. However, further studies are needed to clarify the roles of 11-KT in proliferation of spermatogenic germ cells that replace degenerating oocytes during sexual transition in the

hermaphrodite fishes, including honeycomb grouper.

The present study tried to elucidate the gonadal restructuring and endocrine events that undergo during protogynous sex change in the honeycomb grouper, which substantiate the role of endogenous sex hormones, but the exact chain of events which makes a functional female change into a functional male under natural conditions remains to be established. An old question asked repeatedly (e.g. Reinboth, 1983; Brusle, 1987) still awaits an answer: which is or are the factor (s) that turn a sexually bipotent gonocyte into either an oogonium or a spermatogonium. Future investigations will proceed accordingly toward finding the factors responsible for germ cell proliferation.

## ACKNOWLEDGEMENTS

We thank Mr. Kei Ogasawara and Ms. Ayumi Sakaguchi for their invaluable assistance throughout the study period. This study was supported in part by CREST, JST (Japan Science and Technology Corporation) and Ministry of Education, Culture, Sports and Technology, Japan. This is the contribution from Sesoko Station, TBRC, University of the Ryukyus, Japan.

## REFERENCES

- Abu-Hakima R (1987) Aspects of the reproductive biology of the grouper, *Epinephelus tauvina* (Forsk.) in Kuwaiti waters. *J Fish Biol* 30: 213–222
- Brusle S (1987) Sex inversion of the hermaphroditic protogynous teleost *Coris julis* L. (Labridae) *J Fish Biol* 30: 605–616
- Cardwell JT, Liley NR (1991) Hormonal control of sex and color change in the parrotfish, *Sparisoma viride*. *Gen Comp Endocrinol* 81: 7–20
- Chen CP, Hsieh HL, Chang KH (1980). Some aspects of the sex change and reproductive biology of the grouper, *Epinephelus diacanthus* (Cuvier et valenciensis). *Bull Inst Zool Academia Sinica* 19: 11–17
- Fostier AB, Jalabert R, Billard B, Breton B, Zohar Y (1983) The gonadal steroids. In "Fish Physiology Vol 9A" Ed by Hoar WS, Randall DJ, Donaldson EM, Academic Press, New York, pp 227–372
- Grober MS, Jackson IMD, Bass AH (1991) Gonadal steroid affect LHRH preoptic cell number in a sex/role changing fish. *J Neurobiol* 22: 734–741
- Johnson AK, Thomas P, Wilson JR RR (1998) Seasonal cycles of gonadal development and plasma sex steroid levels in *Epinephelus morio*, a protogynous grouper in the eastern Gulf of Mexico. *J Fish Biol* 52: 502–518
- Kobayashi Y, Lee YD, Takemura A, Takano K, Soyano K (2000) Histological observation of sex change in honeycomb grouper, *Epinephelus merra*. In "Proceedings of the 6th International symposium on the Reproductive Physiology of Fish", Ed by B Noberg, OS Kjesbu, GL Taranger, E Andersson, SO Stefansson, Institute for Marine Research and University of Bergen, pp 269
- Kroon FJ, Liley NR (2000) The role of steroid hormones in protogynous sex change in the Blackeye goby, *Coryphopterus nicholsii* (Teleostei: Gobiidae). *Gen Comp Endocrinol* 118: 273–283
- Lee YD, Park SH, Takemura A, Takano K (2002) Histological observations of seasonal reproductive and lunar-related spawning cycles in the female honeycomb grouper, *Epinephelus merra* in Okinawan waters. *Fish Sci* 68: 872–877
- Miura T, Miura C (2001) Japanese eel: a model for analysis of sper-

- matogenesis. *Zool Sci* 18: 1055–1065
- Nagahama Y, Miura T, Kobayashi T (1994) The onset of spermatogenesis in fish. *Ciba Found Symp* 182: 255–267
- Nakamura M, Hourigan TF, Yamauchi K, Nagahama Y, Grau GE (1989) Histological and ultrastructural evidence for the role of gonadal steroid hormones in sex change in the protogynous wrasse *Thalassoma duperrey*. *Env Biol Fish* 24: 117–136
- Rahman MS, Takemura A, Takano K (2000) Correlation between plasma steroid hormones and vitellogenin profiles and lunar periodicity in the female golden rabbitfish, *Siganus guttatus* (Bloch). *Comp Biochem Physiol* 127B: 113–122
- Reinboth R (1979) On steroidogenic pathways in ambisexual fishes. *Proc Indian Natl Sci Acad* 45B: 421–428
- Reinboth R (1983) The peculiarities of gonad transformation in teleosts. *Differentiation* 23: 82–86
- Reinboth R (1988) Physiological problems of teleost ambisexuality. *Env Biol Fishes* 22: 249–259
- Shapiro DY (1987) Differentiation and evolution of sex change in fishes. *Bioscience* 37: 490–497
- Siau Y (1994) Population structure, reproduction and sex-change in a tropical east Atlantic grouper. *J Fish Biol* 44: 205–211
- Smith CL (1965) The pattern of sexuality and the classification of serranid fishes. *Amer Mus Novit* 2207: 1–20
- Tan SM, Tan KS (1974) Biology of the tropical grouper. *Epinephelus tauvina* (Forsk.) I. A preliminary study on hermaphroditism in *E. tauvina*. *Sing J Pri Ind* 2: 123–133
- Tang F, Chan STH, Lofts B (1975) A study on the 3 $\beta$ - and 17 $\beta$ -hydroxy steroid dehydrogenase activities in the gonads of *Monopterus albus* at various sexual phases during natural sex reversal. *J Zool (London)* 175: 571–580
- Yeh SL, Kuo CM, Ting YY, Chang, CF (2003) The effects of exogenous androgens on ovarian development and sex change in female orange-spotted protogynous grouper, *Epinephelus coioides*. *Aquaculture* 218: 729–739

(Received January 6, 2003 / Accepted May 20, 2003)