

## **Prevalence of Macropod Progressive Periodontal Disease (“lumpy jaw”) in wild western grey kangaroos (*Macropus fuliginosus*)**

Authors: Rendle, Jessica, Yeap, Lian, Jackson, Bethany, Warren, Kristin, Ward, Samantha J., et al.

Source: Journal of Vertebrate Biology, 69(4)

Published By: Institute of Vertebrate Biology, Czech Academy of Sciences

URL: <https://doi.org/10.25225/jvb.20030>

---

BioOne Complete ([complete.BioOne.org](https://complete.BioOne.org)) is a full-text database of 200 subscribed and open-access titles in the biological, ecological, and environmental sciences published by nonprofit societies, associations, museums, institutions, and presses.

Your use of this PDF, the BioOne Complete website, and all posted and associated content indicates your acceptance of BioOne’s Terms of Use, available at [www.bioone.org/terms-of-use](https://www.bioone.org/terms-of-use).

Usage of BioOne Complete content is strictly limited to personal, educational, and non - commercial use. Commercial inquiries or rights and permissions requests should be directed to the individual publisher as copyright holder.

---

BioOne sees sustainable scholarly publishing as an inherently collaborative enterprise connecting authors, nonprofit publishers, academic institutions, research libraries, and research funders in the common goal of maximizing access to critical research.

# Prevalence of Macropod Progressive Periodontal Disease (“lumpy jaw”) in wild western grey kangaroos (*Macropus fuliginosus*)

Jessica RENDLE<sup>1,4\*</sup>, Lian YEAP<sup>1</sup>, Bethany JACKSON<sup>1</sup>, Kristin WARREN<sup>1</sup>, Samantha J. WARD<sup>2</sup>, Rebecca DONALDSON<sup>1</sup>, Chris MAYBERRY<sup>3</sup>, Jennifer RICHARDSON<sup>1</sup> and Rebecca VAUGHAN-HIGGINS<sup>1</sup>

<sup>1</sup> College of Science, Health, Engineering and Education, Murdoch University, Australia; e-mail: [jessica.rendle@twycrosszoo.org](mailto:jessica.rendle@twycrosszoo.org), [l.yeap@murdoch.edu.au](mailto:l.yeap@murdoch.edu.au), [b.jackson@murdoch.edu.au](mailto:b.jackson@murdoch.edu.au), [k.warren@murdoch.edu.au](mailto:k.warren@murdoch.edu.au), [r.donaldson@murdoch.edu.au](mailto:r.donaldson@murdoch.edu.au), [j.richardson@murdoch.edu.au](mailto:j.richardson@murdoch.edu.au), [r.vaughan-higgins@murdoch.edu.au](mailto:r.vaughan-higgins@murdoch.edu.au)

<sup>2</sup> School of Animal, Rural and Environmental Sciences, Nottingham Trent University, UK; e-mail: [samantha.ward@ntu.ac.uk](mailto:samantha.ward@ntu.ac.uk)

<sup>3</sup> School of Animal Biology, University of Western Australia, Australia; e-mail: [c.mayberry@ymail.com](mailto:c.mayberry@ymail.com)

<sup>4</sup> Twycross Zoo, East Midland Zoological Society, UK

► Received 26 March 2020; Accepted 1 July 2020; Published online 1 September 2020

**Abstract.** Macropod Progressive Periodontal Disease (MPPD), colloquially referred to as “lumpy jaw”, is a commonly observed disease in captive macropods. However, the prevalence of this disease in the wild is largely unknown. A systematic study of MPPD in wild macropods would provide an indication of the endemic presence of this disease in wild populations, and could assist those managing disease in captive populations, by highlighting potential risk factors for disease development. Utilising kangaroos culled as part of a population management program, this study used visual observation and computer tomography (CT) of skulls to investigate the prevalence of MPPD in wild western grey kangaroos (*Macropus fuliginosus*) from the Perth metropolitan region, Western Australia. The sample suitable for visual and CT analysis comprised 121 specimens, 71 (58.7%) male and 50 (41.3%) female, with the mean age for all 121 specimens being 4.5 years ( $\pm 2.63$  SD). No evidence of MPPD was detected in any of the specimens examined. Overabundance may not be associated with the development of MPPD, as previously considered, and age-related factors should not be eliminated. This results may reflect low susceptibility to MPPD in western grey kangaroos, given low prevalence is reported in this species in captive populations. Further investigation into species-specificity is recommended, and should include samples with soft tissue to improve sensitivity of disease detection. Surveillance of MPPD in wild populations of macropods helps to improve our understanding of the biological significance, development and potential spread of this disease. Notably, this information may assist in the management of MPPD in captive populations, and may have a positive impact on both the welfare and conservation of macropods in captivity.

**Key words:** macropod, wildlife, dental disease, epidemiology, osteomyelitis

\* Corresponding Author



## Introduction

Macropod Progressive Periodontal Disease (MPPD), or "lumpy jaw", is a complex syndrome and considered a continuum of oral disease, incorporating conditions from gingivitis through to periodontal disease, and result in proliferative osteomyelitis of the mandible and/or maxilla (Vogelnest & Portas 2008, Vogelnest 2015, McLelland 2019, Rendle 2019). MPPD is common in captive macropods, with a high prevalence resulting in morbidity and mortality (Jackson 2003). However the disease has rarely been reported in wild macropods (Wallach 1971, Vogelnest & Portas 2008) and there are few investigations documenting its presence and extent in wild populations (Arundel et al. 1977, Miller & Beighton 1979, Vogelnest & Portas 2008, Borland et al. 2012). Previous studies in wild macropod populations have been opportunistic, with MPPD detected during the course of other activities; such as during research on mortality in eastern grey kangaroos (Borland, unpublished data, Borland et al. 2012). A systematic study of MPPD in wild macropods is needed to provide an indication of the endemic presence of this disease in wild populations. This information would be useful to managers of disease in captive macropod populations, through the identification of potential risk factors for disease development. Here, we report a study investigating the prevalence of MPPD in wild western grey kangaroos in the metropolitan region of Perth, Western Australia.

MPPD in wild kangaroos was reported in Pleistocene fossils of mandibles from giant kangaroos (*Macropus titan*), estimated to be 26,000 years old (Horton & Samuel 1978). Early studies of MPPD in wild macropods by Tomlinson & Gooding (1954) offered no suggestions regarding causes for this disease, however Borland et al. (2012) describe circumstances in wild individuals where the disease is detected during periods of extreme environmental stress, during drought. In their study, Borland et al. (2012) demonstrate an association between a high density of kangaroos, limited access to essential resources and subsequent faecal contamination of pasture land, and a high prevalence of MPPD. There is a general acceptance that environmental contamination with infected faeces or discharge is a key factor in the development of MPPD (Fox 1923, Beveridge 1934, Burton, unpublished data, Vogelnest & Portas 2008). Bacterial faecal-oral transmission during

grazing via faecal contamination on the ground is likely in these situations, and may also occur through unintentional or intentional coprophagic behaviour (Bennett et al. 2009). The combination of stress-induced immunosuppression and exposure and ingestion of pathogenic faecal bacteria is reported to increase disease risk (Vogelnest & Portas 2008).

MPPD, originally considered to be a disease of captivity (Samuel 1983), has now been described in a range of wild macropod species across Australia (Borland et al. 2012). MPPD is considered to affect all species of macropod (Jackson 2003) and has been detected in wild species including: swamp wallabies (*Wallabia bicolor*), tammar wallabies (*Notamacropus eugenii*: Arundel et al. 1977), eastern grey kangaroos (*Macropus giganteus*: Borland et al. 2012), red kangaroos (*Osphranter rufus*: Tomlinson & Gooding 1954) and red-necked wallabies (*Notamacropus rufogriseus*: Kirkpatrick in Horton & Samuel (1978), p. 280; Munday 1978). However, prevalence of the disease in wild populations is largely unknown, and published reports regarding prevalence of the disease vary in their findings. Calaby & Poole (1971) reported that MPPD was common in wild kangaroos, and discussed species-specific susceptibilities to the disease; for example, the red-necked wallaby is more susceptible than the red kangaroo, which in turn is more susceptible than the grey kangaroo. Borland et al. (2012) then reported the prevalence of MPPD in the eastern grey kangaroo was high (54%). Several other studies, however, have reported low prevalence of MPPD in wild kangaroos (Wallach 1971, Butler 1981, Vogelnest & Portas 2008).

The detection and diagnosis of disease in wild animals is challenging, as normal health parameters are often unknown and clinical examination without chemical immobilisation is often not possible (Wobester 2006). Disease detection typically occurs following mass die-offs, major observed behavioural changes, clinically observed health abnormalities, or direct investigation of a particular species (Wobester 2006, Stallknecht 2007). In free-ranging populations, MPPD is often undetected until the disease has reached an advanced stage, when death commonly ensues due to an inability to masticate (Vogelnest & Portas 2008). Borland et al. (2012) reported MPPD lesions in the skulls of wild eastern grey kangaroos found dead at Serendip Wildlife Sanctuary, Victoria.



Diagnosis was based on visual observation of osteolytic changes; which in live animals may only be visible through the use of radiographic tools. In live animals, diagnosis of MPPD is typically undertaken through physical examination of the oral cavity and bacterial culture; in addition, radiographs may be carried out to confirm bony involvement (Barrie 2003, Jackson 2003, Vogelnest & Portas 2008).

A method that has been used to diagnose MPPD in captive macropods is computed tomography (CT), an advanced imaging modality (Melbourne Zoo 2007, Lee et al. 2011), however its use in wild specimens to date has been limited (Lee et al. 2011). Computed tomography is a non-invasive diagnostic tool used to create detailed 3D images of bone and soft tissue (Littleton & Durizch Littleton 1996). This study used CT scans of skulls sourced from carcasses associated with a population management cull in order to investigate MPPD in wild kangaroos. This provided a cross-sectional sample population for detecting the prevalence of MPPD in wild kangaroos. The western grey kangaroo has been the subject of several population management culls in recent years (Burbidge et al. 2016). Carcasses from these culls have provided an opportunity to report on the prevalence of MPPD in this macropod species under normal environmental conditions, as opposed to the drought conditions present during the Borland et al. (2012) study. These data may provide an indication of the endemic status of MPPD disease in free-ranging populations; information which may be utilised by macropod managers and rehabilitators to maintain health and reduce the risks of MPPD in captivity.

Given that MPPD is considered rare in wild populations (Wallach 1971, Vogelnest & Portas 2008), we hypothesised that prevalence of this disease would be lower than the prevalence reported in captive animals of the same species (2.6%) (Vogelnest & Portas 2008). The aim of this study was to use both visual observation, supported by CT analysis, to detect pathological changes within bones that are symptomatic of MPPD, and changes which may not readily be observed during visual inspection of the bones. This is the first systematic study of MPPD in wild populations of western grey kangaroos using CT as a diagnostic tool, reporting on disease prevalence and potential environmental risk factors for the disease.

## Material and Methods

### Sample collection and preparation

#### *Study site*

Methods for the collection and preparation of specimens used in this study follow those of Mayberry (2018) and Mawson et al. (2016). Kangaroo skulls were sourced following a population management program at Thomsons Lake Nature Reserve (hereafter referred to as Thomsons Lake). Thomsons Lake encompasses a 550 hectare site situated 22 kilometres south of Perth city centre in Western Australia. When full, the water at Thomsons Lake covers an area of 150 hectares and is surrounded by a belt of rushes (*Baumea articulata* and *Typha orientalis*) and couch grass (*Cynodon dactylon*). The vegetation advances as the lake recedes during the hot, dry months of summer and autumn, and these perennial grasses and sedges supplement the lower storeys of the surrounding woodlands to provide resident western grey kangaroos with year-round feed. The reserve is surrounded by a 2.4 metre high chain-link fence, which extends into the ground to contain the kangaroos. When the reserve was first fenced, a 1080 (sodium fluoroacetate) baiting program was undertaken to remove potential predators. The resident kangaroo population subsequently increased, and by 2005 the numbers were considered to be a problem to native flora through over-grazing and facilitation of the spread of introduced weeds, as well as a threat to water bird nest sites. There was a resident population of 1,100 western grey kangaroos in 2006, when the population control program was undertaken.

#### *Sample collection*

Western grey kangaroo skulls used in this study (from the aforementioned site) were sourced and prepared for a previous study of age estimation and anoestrus in the species (Mayberry et al. 2010, 2018). Between May 2006 and March 2007, the Department of Environment and Conservation (DEC) culled 1032 adult and sub-adult kangaroos from the Thomsons Lake Reserve to reduce the impact of the kangaroos on the native vegetation and biodiversity. A total of 292 male and 244 female kangaroos, of mixed ages, were culled from the Reserve between May and July 2006, and a further 496 kangaroos of mixed age and sex between August 2006 and February 2007.

The sex of each individual kangaroo was recorded at the time of culling. Age was estimated by



molar progression (Kirkpatrick 1964, 1965) and by comparing the head length with animals aged by molar progression (Poole et al. 1982). For the purposes of this study, a sample of skull specimens was taken from these culled populations for diagnostic imaging.

#### *Preparation for diagnostic imaging*

Initially, visual examination of the skulls was performed to select suitable (whole or near whole) skulls for CT examination. Fragmented specimens were reconstructed and secured using a Bosch® (Robert Bosch GmbH, Clayton South, Victoria) Glue Pen (3.6 V Lithium-ion all-purpose glue pen). Specimens were placed in a partitioned cardboard box, capable of securely holding six skulls, for CT scanning in batches.

#### **Diagnostic methods**

Specimens were considered as “Complete” (all parts of the mandible were present but might have been fragmented), or “Incomplete” (one hemimandible or large sections of the mandible were missing). All bones of each skull that were available were evaluated by independent observers, one using visual observation methods whilst another reviewed CT scan results.

#### *Visual observation of skulls*

Following methods by Miller & Beighton (1979) and Borland et al. (2012), initial observation of the skulls was performed to identify signs of signs of bone pathology and/or bony proliferation in the mandible and/or maxilla. Using diagnostic criteria similar to those used by Borland et al. (2012), we categorised kangaroo skulls based on visually observed bone loss. Each kangaroo skull was placed into one of four categories, from normal bone through to osteoproliferative change, with the researchers considering all samples with any osteolytic changes to be cases of MPPD (Table 1).

#### **Diagnostic imaging – computed tomography (CT)**

All specimens were scanned using a Siemens® 16 slice SOMATOM Emotion Scanner (Siemens Healthcare Pty Ltd, Bayswater, Victoria) using exposure factors of 130 kV and 250 mAs. A specialist Veterinary Radiologist carried out a clinical review of the CT images, including the control specimen.

Helical scans were performed at a slice thickness of 0.75 mm through the specimens using a 16 × 0.6 mm detector array and a 0.75 mm slice thickness. The specimens were scanned rostral-caudal at a pitch of 0.55. The scan field was set to include all relevant anatomy. Images were reconstructed using “syngo” CT Workplace software (Siemens, Erlangen, Germany). The images were reconstructed in the transverse plane using an Extremity algorithm and U90s Ultra Sharp reconstruction kernel (Seimens Medical 2007). Additional series were reconstructed using a Soft Tissue algorithm and B50s Standard reconstruction kernel. Multiplanar Reformats (MPR) were created in sagittal and dorsal planes from the initial Extremity U90s Ultra Sharp reconstructions. 3D surface renderings were created from the Soft Tissue B50s reconstructed series. A skull specimen from a wild red kangaroo of unknown age and sex, confirmed to have MPPD, was the case control for this study.

#### **Statistical analysis**

Power analysis was undertaken to determine population requirements for the study, using Epitools (Sergeant 2018). True prevalence was assumed at 0.02, Se 0.95, Sp 0.95, confidence level 95% using the exact binomial method (Ross 2003). The calculated sample size required for the study was 121. Microsoft® Excel 2016 was used to calculate descriptive statistics and prevalence of MPPD for this population of western grey kangaroos, sex ratios, and the mean age of animals ( $\pm$ SD).

**Table 1.** Classification of osteoproliferative and osteolytic changes in relation to Macropod Progressive Periodontal Disease (MPPD) adapted from Borland et al. (2012).

Category	Skull characteristics
Normal	No osteolytic change
Minor	Osteolytic bone lesion(s) present but no visible alteration of the physical dimensions was observed
Major	Significant osteolytic bone lesion(s) were observed
Osteoproliferative	Proliferative bony lesion(s) were observed visibly altering the dimensions of the jaw bone(s)

## Results

The CT study of the red kangaroo with MPPD lesions (control), confirmed bilateral lesions in the mandible, with the right mandible more severely affected than the left. Findings from the CT study of the red kangaroo skull were categorised as "osteoproliferative" and are presented in Fig. 1a, b.

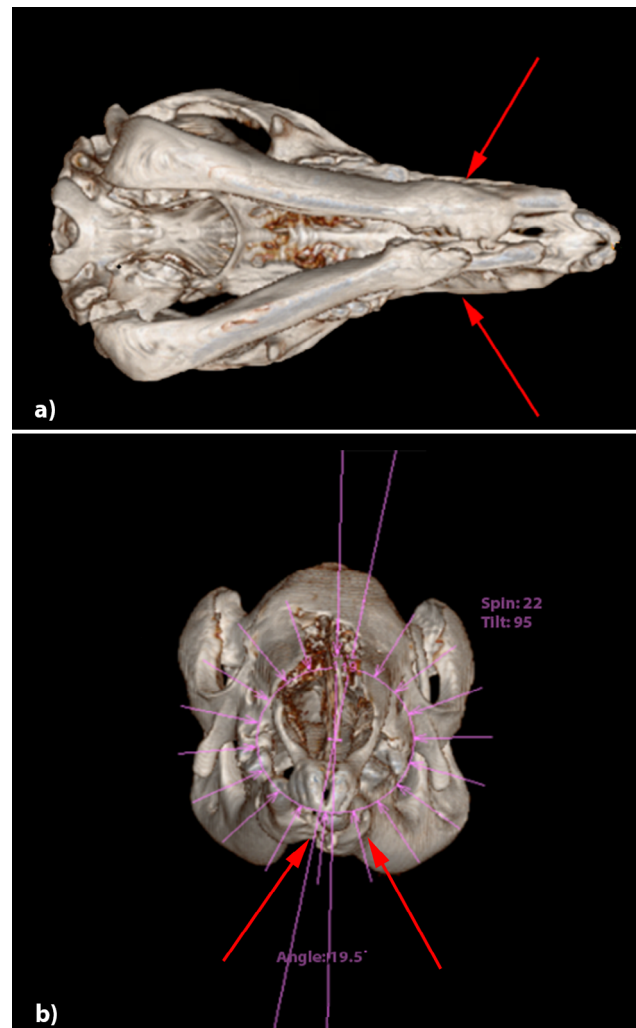
### Population

The population comprised of 326 western grey kangaroos, of which 121 specimens were considered suitable for visual and CT analysis from Thomsons Lake Reserve. A total of 97 (80.2%) of the specimens presented for CT were complete, and 24 (19.8%) were incomplete, having one hemimandible or large section of the mandible missing. In addition, the Veterinary Radiologist who reviewed the CT images noted that five individuals had missing rostral teeth, and one had a section of caudal temporomandibular joint (TMJ) missing.

Using records from the culls, sex and age was determined for all 121 specimens (Table 2). The ages of kangaroos ranged between 1.0-13.6 years (Table 2).

### Prevalence

The visual observations and CT scans of the 121 western grey kangaroos from Thomsons Lake Reserve did not detect MPPD in any specimens, with prevalence of MPPD in this population of western grey kangaroos was 0% (95% CI: 0.0-3.0) (Table 2).



**Fig. 1.** Computed tomography (CT) of the ventral view of a red kangaroo skull with confirmed Macropod Progressive Periodontal Disease (MPPD). The mandible has bilateral proliferative lesions with intraosseous opacity (osteolysis) and new periosteal new bone formation creating expansile lesions (red arrows); a) transverse plane, b) frontal plane. Lesions not visible from dorsal view.

**Table 2.** Specimen data and prevalence of Macropod Progressive Periodontal Disease (MPPD) in a population of isolated wild western grey kangaroos from Thomsons Lake Reserve, Western Australia.

Source (n)	Sex ratio m:f	Mean age (±SD)	Age range Years	MPPD	Prevalence (95% CI)
Thomsons Lake (121)	71:50	4.5 (2.61)	1.0-13.6	0	0% (0.0-3.0)

## Discussion

The review of CT images and visual observation of all available bones of the skull and jaw from this sample of western grey kangaroos did not detect osteolytic changes consistent with MPPD (prevalence 0%, 95% CI: 0.0-3.0). These results support our hypothesis that the prevalence of MPPD is lower in isolated wild western grey kangaroos than the prevalence previously reported in captive conspecifics (2.6%, 95% CI: 0.1-13.5%)

(Vogelnest & Portas 2008), although the 95% CI suggest there is not a significant difference between these findings. The absence of MPPD in the population we sampled does not confirm that the disease was not present in the wider population. However, we would expect that MPPD disease, if present in the overall population, would also have a low prevalence.

Detection of disease in wild animals often involves visual observation of noticeable behavioural or



physical abnormalities, or locating and sampling dead individuals (Thomas et al. 1997, Hartup et al. 2001, Borland et al. 2012). Visual observation of MPPD is subjective, and requires multiple modalities to provide a definitive diagnosis. Tomlinson & Gooding (1954) described jaw and leg swellings in red kangaroos, in addition to observed emaciation, yet it was not clear if the jaw swellings were cases of MPPD. A diagnosis of MPPD can be confirmed through clinical and radiographic examination, biological sampling and necropsy. We initially used visual observation of the specimens to detect evidence of pathological and proliferative bony changes, following methods similar to those by Miller & Beighton (1979) and Borland et al. (2012). However, using these methods, this disease was not detected. Accurate visual observation of osteolytic changes relies on the skill of the observer and it may not always be possible to detect changes. The development of clear diagnostic criteria may facilitate a more objective approach to this method of reporting, similar to that used by Borland et al. (2012). In our study, only the control specimen presented pathological lesions that appeared proliferative, and therefore, was considered to be our only case of MPPD. MPPD is syndromic, and it has been suggested that the disease requires not only the presence of proliferative bony change, but also soft tissue inflammation (Vogelnest & Portas 2008, McLelland 2019, Rendle 2019). There are obvious limitations to the use of skulls, without the presence of soft tissue, to describe the prevalence of this disease. This highlights the need for development of a clear definition of the physiological and biological factors required to represent a true case of MPPD.

To confirm the presence and extent of bony involvement in MPPD, diagnostic imaging is recommended (Miller et al. 1978, Miller & Beighton 1979, Vogelnest & Portas 2008). Plain radiography is typically used for this purpose (Jackson 2003), and was the diagnostic tool of choice for Miller & Beighton (1979). Computed tomography is a more advanced modality that has reliably been used in the diagnosis of MPPD in kangaroos (Melbourne Zoo 2007, Lee et al. 2011). Its major advantage over radiography includes enhanced soft tissue and bone detail, which may aid in the diagnosis of early cases (Lee et al. 2011). However, due to the costs of CT imaging, it is typically only available at large university teaching hospitals or through specialist referral to veterinary and/or human radiology practices, and so is not always a practical option in wildlife species.

Detection of MPPD in wild populations is also limited due to the flighty nature of macropods and the need for chemical immobilisation to enable clinical examination. Given this, disease detection in wild individuals frequently relies on examination of cadavers; for which soft tissue may have undergone autolysis or may not even be present, thereby limiting the extent of analysis possible with CT. In these circumstances, radiography may be of equal value, and potentially easier to access. In this current study, CT was used successfully to detect bony proliferations and osteolytic changes in the control specimen. In the study specimens (the western grey kangaroos) all areas of the mandible, maxilla and the skull were examined, and no signs of osteolysis or bony proliferation were detected in the population. It must be noted that the specimens examined were skulls only, without the presence of soft tissue, and therefore we cannot rule out the possibility of mild MPPD cases involving soft tissue in these populations. However, in a wild population where individuals are not receiving health interventions, it seems unlikely that mild cases would not progress to severe cases; which would have been observable in this study.

Additionally, 19.8% of the specimens presented for CT were incomplete, having either one hemimandible or large section of the rostral mandible missing. Borland et al. (2012) reported that the greatest number of proliferative MPPD lesions occurred in the rostral region of the mandible; so it cannot be ruled out that the low prevalence observed in the current study may be related to the missing bone matter from these regions. Although our sample size ( $n = 121$ ) met the requirements from a power analysis of a minimum requirement of  $n = 121$ , the total number of complete specimens ( $n = 97$ ) was below this requirement. In addition, information regarding the size of the original population at the source was not certain; therefore, the sample size obtained ( $n = 121$ ) for this location may not be sufficient for the true prevalence to be determined.

### **Risk factors for macropod progressive periodontal disease (MPPD)**

There are known physiological risk factors associated with MPPD, including macropod age and the process of molar progression. Several macropod species, including the western grey kangaroo, experience molar progression throughout their lives, however the rate of molar progression is age-specific (Jackson 2003). The risk



of infections associated with molar progression may potentially increase with age, as a result of repeated exposure over time, to events that present a risk of infection, such as breaches in the mucosa as molar teeth erupt (Finnie 1976, Arundel et al. 1977), and "post functional" molar teeth creating a trap for pathogens (Miller & Beighton 1979). In our study, the mean age of individuals was younger than the mean age of individuals presenting with proliferative lesions in the Borland et al. (2012) study. While our study population may potentially be at low risk of lumpy jaw due to age, ongoing molar progression throughout life means that this particular biological process cannot be eliminated as a possible causative factor.

Diet has an influence on macropod dentition, and on oral health and associated risk of disease (Clarke 2003). Macropods are categorised by dietary preference: as grazers, browsers or mixed grazer/browsers; and the western grey kangaroo is predominantly a grazer (Sanson 1989, Tyndale-Biscoe 2005, Arman & Prideaux 2015). The species feeds principally on grass, a product that is largely unvarying and is abrasive in its physical properties (Hume 1982, Johnson-Delaney 2014). Although the vegetation was varied at Thomsons Lake, grass was the predominant substrate at the Reserve (Mawson et al. 2016), and the abrasive nature of grass on the dentition (Sanson et al. 2007) may lead to a lower incidence of MPPD. The area from which the kangaroo specimens were sourced for this study is naturally sandy (Perth Metropolitan Region, WA), so any abrasion experienced during feeding may potentially not be caused by the grasses but by silica contamination from the substrate (Kaiser et al. 2009). The long-term effects of abrasiveness of dietary products on teeth have also been observed in another herbivorous species, the giraffe (*Giraffa camelopardalis*) (Clauss et al. 2007). The effects of different diets on dental anatomy have led to captive giraffes being classified as grazers while wild conspecifics are classified as browsers (Clauss et al. 2007, Kaiser et al. 2009). Further research into the effects of different diets and substrates ingested by wild kangaroos, and any association with the prevalence of MPPD, is recommended. Recommendations could be developed, based on the diet of wild conspecifics, regarding the feeding of specific dietary products that may reduce incidence of MPPD in captive populations, where this disease is of major concern (Vogelnest & Portas 2008).

We also considered any relationship between prevalence of MPPD and overpopulation. When western grey kangaroos experience overpopulation or overcrowding that causes declines in their preferred diet (graze), the species is able to obtain nutrients instead through the ingestion of shrubs and browse (Barker 1987, Munn et al. 2014). Overpopulation may result in kangaroos being at greater risk of developing MPPD for several reasons: a) being at increased risk of exposure to, and ingestion of, pathogenic bacteria during grazing on contaminated pasture (Smith et al. 1984, Smith & Thornton 1993, Vogelnest & Portas 2008); b) enduring oral trauma whilst grazing upon dry, coarse grazing material, as oral trauma often precedes infection (Finnie 1976, Gamble 2004, Vogelnest & Portas 2008); and c) overcrowding may lead to competition over resources, stimulating stress-induced immunosuppression (Blecha 2000). Reports taken at the time of specimen collection for this study, however, suggest that conditions were favourable, and the preferred diet was adequate (Mayberry et al. 2010). This may have contributed to the reported healthy, although potentially overpopulous, kangaroo population at the study site (Mayberry et al. 2010). The kangaroo population at the site was culled as they were having an impact on the vegetation. Overcrowding and a reduction in resources can be associated with MPPD, as was also demonstrated by Borland et al. (2012); yet despite the relatively high densities reported for our study population, no cases were detected. Although the exact population densities and food abundance are unknown, it is likely that there was still sufficient vegetation to support the populations in both these localities when samples were collected.

Environmental contamination and associated presence of pathogenic bacteria were also examined as a potential factor affecting the prevalence of MPPD. Overpopulation and forced congregation of animals can have a major effect on the presence of disease (Wobester 2006), and is noted to be a risk factor for MPPD in captive macropods, specifically in the presence of pathogenic bacteria (Ketzer 1997). *Fusobacterium necrophorum* is a primary causative bacterium of MPPD (Burton, unpublished data, Samuel 1983, Vogelnest & Portas 2008), and is also a species previously found to be associated with environmental factors such as overcrowding, subsequent faecal contamination and foot rot in domestic livestock (Bennett et al. 2009). Footrot is an





infectious bacterial disease known to be transmitted via contact with, or ingestion of, contaminated material (Whittier & Umberger 2009). Kangaroos that share their environment with infected livestock could be at increased risk of MPPD through the ingestion of pathogenic bacteria, particularly when grazing (Burton, unpublished data, Bennett et al. 2009); several studies have reported a high prevalence of MPPD when kangaroos cohabit an environment with domestic livestock (Tomlinson & Gooding 1954, Borland et al. 2012). In the present study, such contact was absent (Mayberry et al. 2010); the kangaroos in the Thomsons Lake Reserve were completely contained. This may be a factor in the observed absence of MPPD among sampled individuals. However, prevalence of MPPD is high in captive populations (McLelland 2019, Rendle 2019), where exposure to domestic livestock is also absent; indicating the need to consider the role of other variables. For both wild and captive macropods, population density is a variable that may affect levels of environmental contamination and the development of MPPD. Further investigations into potential links between MPPD and environmental contamination are recommended.

Research using specimens collected historically presents difficulties, and retrospective analysis of environmental risk factors is particularly challenging. An additional complication in our study was that some of the specimens were incomplete, with many missing sections of the jaw most associated with MPPD lesions (the rostral mandible) (Borland et al. 2012). The absence of soft tissue, which is required for confirmation of the presence of MPPD in live macropods, may also have influenced the absence of MPPD cases that we observed. Additionally, the lack of previous research into MPPD in wild populations of kangaroos meant that the evaluation of risk factors was limited.

This study reported prevalence of MPPD in a sample population of western grey kangaroos. We encourage further investigation into disease detection and the characterisation of prevalence in other populations and species of wild macropods. Undertaking a larger study incorporating opportunistic data collection from specimens from road traffic collisions, as well as systematic collection of specimens in the field, could potentially provide a clearer indication of true prevalence in this species. However to estimate the true prevalence in the wild it would be important to

adopt a stratified sampling approach that ensures a range of ages and sexes is sampled. Future studies should incorporate groups that are exposed to risk factors of interest, such as those identified by prior studies; drought and crowding (Borland et al. 2012), association with livestock (Tomlinson & Gooding 1954, Borland et al. 2012); and follow populations where these factors are controlled. Studies could extend further to examine environmental conditions, including quality, quantity and type of pasture/forage/browse on which the various species feed. Improved knowledge of vegetation selection by wild macropods could be used to inform captive collection managers regarding the most appropriate browse and forage for the species. Given that MPPD is widespread in captive settings, this information could be valuable for disease risk management. Additionally, a collaborative approach to disease surveillance should be encouraged, with wildlife managers, professional shooters, abattoirs and pastoralists working together to monitor the health and disease status of macropod populations in a systematic way. Knowledge gained regarding existing population health and demographics could aid the future management of kangaroo populations, with information benefitting both captive and wild macropods.

Given that the prevalence of MPPD in the western grey kangaroo appears to be low in captivity (Rendle 2019), and that the disease was undetected in this wild population, further investigations into species specificity of this disease are recommended. A potential risk factor for MPPD involves the impaction of food around the teeth and gums caused by the narrowness of the jaws (Crandall 1964); an aspect of macropod anatomy that is variable across Macropodidae (Jackson 2003). Anatomical differences in dentition could be the basis for a species-specific susceptibility (Calaby & Poole 1971). Investigations into species-specific prevalence and anatomical risk factors could benefit those who manage kangaroos in the wild and in captivity, and as such are highly recommended.

This epidemiologic study investigated the prevalence of MPPD in an isolated wild population of western grey kangaroos using visual observation and CT as a diagnostic tool. MPPD is a chronic condition that often leads to malnutrition, starvation and death, however this disease was not detected. Further surveillance

of wild kangaroo populations would assist with investigating species susceptibility and improve our understanding of the biological significance, development and potential spread of MPPD. MPPD continues to cause morbidity and mortality in captive macropods. There is ongoing interest to conduct investigations in wild populations, to gain knowledge of disease prevalence in the natural environment and a better understanding of risk factors associated with the development of MPPD in captive populations.

### Acknowledgements

---

*The authors wish to thank staff from Murdoch University Diagnostic Imaging department for their*

*help and support with this project. Specific thanks goes to Sierra Westbury and Nicholas Crawford. We are also grateful for the financial support of the Australian Postgraduate Award, kindly topped up by the Murdoch University Strategic Top-up Award. Author contributions: J. Rendle, K. Warren and R. Vaughan-Higgins conceived the study; C. Mayberry and L. Yeap collected kangaroo specimens; C. Mayberry and J. Rendle produced biological data; J. Rendle, S. Ward and B. Jackson analysed data; J. Richardson carried out CT analysis; J. Rendle, B. Jackson, R. Donaldson and K. Warren wrote the first version of the manuscript. All authors provided comments on the manuscript and agreed with publication.*




## Literature

- Arman S.D. & Prideaux G.J. 2015: Dietary classification of extant kangaroos and their relatives (Marsupialia: Macropodoidea). *Austral Ecol.* 40: 909–922.
- Arundel J., Barker I.K. & Beveridge I. 1977: Diseases of marsupials. In: Stonehouse B. & Gilmore D. (eds.), *The biology of marsupials*. Macmillan Press, London: 141–154.
- Barker R.D. 1987: The diet of herbivores in the sheep rangelands. In: Caughley G., Short J. & Shepherd N. (eds.), *Kangaroos: their ecology and management in the sheep rangelands of Australia*. Cambridge University Press, Cambridge, England: 69–83.
- Barrie M.T. 2003: Lumpy jaw in macropods. *The North American Veterinary Conference, Orlando, USA*.
- Bennett G., Hickford J., Sedcole R. & Zhou H. 2009: *Dichelobacter nodosus*, *Fusobacterium necrophorum* and the epidemiology of footrot. *Anaerobe* 15: 173–176.
- Beveridge W.I.B. 1934: A study of twelve strains of *Bacillus necrophorus*, with observations on the oxygen intolerance of the organism. *J. Pathol. Bacteriol.* 38: 467–491.
- Blecha F. 2000: Immune system response to stress. In: Moberg G.P. & Mench J.A. (eds.), *The biology of animal stress: basic principles and implications for animal welfare*. CABI Publishing Wallingford, England: 111–121.
- Borland D., Coulson G. & Beveridge I. 2012: Oral necrobacillosis ('lumpy jaw') in a free-ranging population of eastern grey kangaroos (*Macropus giganteus*) in Victoria. *Aust. Mammal.* 34: 29–35.
- Burbidge A., Menkhorst P., Ellis M. & Copley P. 2016: *Macropus fuliginosus*. The IUCN Red List of Threatened Species 2016: e.T40563A21953972. <https://www.iucnredlist.org/species/40563/21953972>
- Butler R. 1981: Epidemiology and management of "lumpy jaw" in macropods. In: Fowler M. (ed.), *Wildlife diseases of the Pacific Basin and other countries*. Wildlife Disease Association Sydney, New South Wales: 58–61.
- Calaby J.H. & Poole W.E. 1971: Keeping kangaroos in captivity. *Int. Zoo Yearb.* 11: 5–12.
- Clarke D.E. 2003: Oral biology and disorders of chiroptera, insectivores, monotremes, and marsupials. *Vet. Clin. North Am. Exot. Anim. Pract.* 6: 523–564.
- Clauss M., Franz-Odenaal T.A., Brasch J. et al. 2007: Tooth wear in captive giraffes (*Giraffa camelopardalis*): mesowear analysis classifies free-ranging specimens as browsers but captive ones as grazers. *J. Zoo Wildlife Med.* 38: 433–445.
- Crandall L.S. 1964: The management of wild mammals in captivity. *University of Chicago Press, Chicago, Illinois*.
- Finnie E.P. 1976: Necrobacillosis in kangaroos. In: Page L.A. (ed.), *Wildlife diseases*. Springer, Boston, Massachusetts: 511–518.
- Fox H. 1923: Disease in captive wild mammals and birds: incidence, description, comparison. *Joshua Ballinger Lippincott, Philadelphia, USA*.
- Gamble K.C. 2004: Marsupial care and husbandry. *Vet. Clin. North Am. Exot. Anim. Pract.* 7: 283–298.
- Hartup B.K., Dhondt A.A., Sydenstricker K.V. et al. 2001: Host range and dynamics of mycoplasmal conjunctivitis among birds in North America. *J. Wildl. Dis.* 37: 72–81.
- Horton D. & Samuel J. 1978: Paleopathology of a fossil macropod population. *Aust. J. Zool.* 26: 279–292.
- Hume I.D. 1982: Digestive physiology and nutrition of marsupials. *Cambridge University Press, Cambridge, UK*.
- Jackson S. 2003: Australian mammals: biology and captive management. *CSIRO Publishing, Collingwood, Victoria*.
- Johnson-Delaney C.A. 2014: Captive marsupial nutrition. *Vet. Clin. North Am. Exot. Anim. Pract.* 17: 415–447.
- Kaiser T.M., Brasch J., Castell J.C. et al. 2009: Tooth wear in captive wild ruminant species differs from that of free-ranging conspecifics. *Mamm. Biol.* 74: 425–437.
- Ketz V. 1997: Necrobacillosis in zoo kangaroos. Hypotheses of impact of management conditions. *Erkrankungen Der Zootiere, Verhandlungsbericht des 38 Internationalen Symposiums über die Erkrankungen der Zoo und Wildtiere, Zurich, Switzerland*: 137–142.
- Kirkpatrick T. 1964: Molar progression and macropod age. *Queensland J. Agric. Anim. Sci.* 21: 163–165.
- Kirkpatrick T. 1965: Studies of Macropodidae in Queensland. 2. Age estimation in the grey kangaroo, the red kangaroo, the eastern wallaroo and the red-necked wallaby, with notes on dental abnormalities. *Queensland J. Agric. Anim. Sci.* 22: 301–317.
- Lee K.J., Sasaki M., Miyauchi A. et al. 2011: Virtopsy in a red kangaroo with oral osteomyelitis. *J. Zoo Wildl. Med.* 42: 128–130.



- Littleton J.T. & Durizch Littleton M.L. 1996: Conventional tomography. In: Gagliardi R.A., McClennan B.L. & Knight N. (eds.), A history of the radiological sciences. *Radiology Centennial, Inc., Reston, Virginia*.
- Mawson P.R., Hampton J.O. & Dooley B. 2016: Subsidized commercial harvesting for cost-effective wildlife management in urban areas: a case study with kangaroo sharpshooting. *Wildl. Soc. Bull.* 40: 251–260.
- Mayberry C., Bencini R., Mawson P. & Maloney S. 2018: Estimating the age of western grey kangaroos (*Macropus fuliginosus ocydromus*). *Aust. Mammal.* 40: 254–261.
- Mayberry C., Maloney S.K., Mawson P. & Bencini R. 2010: Seasonal anoestrus in western grey kangaroos (*Macropus fuliginosus ocydromus*) in south-western Australia. *Aust. Mammal.* 32: 189–196.
- McLelland D.J. 2019: Macropod progressive periodontal disease ('lumpy jaw'). In: Vogelnest L. & Portas T. (eds.), Current therapy in medicine of Australian mammals. *CSIRO Publishing, Clayton South, Victoria*.
- Melbourne Zoo 2007: Computed tomography report – kangaroo. *Melbourne Zoo, Melbourne, Victoria*.
- Miller W. & Beighton D. 1979: Bone abnormalities in two groups of macropod skulls: a clue to the origin of lumpy jaw. *Aust. J. Zool.* 27: 681–689.
- Miller W.A., Beighton D. & Butler R. 1978: Histological and osteological observations on the early stages of lumpy jaw. *Proceedings of a Symposium – Comparative Pathology of Zoo Animals, the National Zoological Park, Smithsonian Institute, Washington, D.C.*
- Munday B. 1978: Marsupial disease. *Fauna: Proceedings No. 36 of a Course for Veterinarians. Post-Graduate Committee for Veterinary Science, University of Sydney, Sydney, New South Wales:* 335–386.
- Munn A.J., Skeers P., Kalkman L. et al. 2014: Water use and feeding patterns of the marsupial western grey kangaroo (*Macropus fuliginosus melanops*) grazing at the edge of its range in arid Australia, as compared with the dominant local livestock, the Merino sheep (*Ovis aries*). *Mamm. Biol.* 79: 1–8.
- Poole W., Carpenter S. & Wood J. 1982: Growth of grey kangaroos and the reliability of age determination from body measurements II. The western grey kangaroos, *Macropus fuliginosus fuliginosus*, *M. f. melanops* and *M. f. ocydromus*. *Wildlife Res.* 9: 203–212.
- Rendle J. 2019: Epidemiology of lumpy jaw in captive macropods across Australia and Europe: an investigation of disease risk and treatment approaches. *PhD thesis, Murdoch University, Australia*.
- Ross T.D. 2003: Accurate confidence intervals for binomial proportion and Poisson rate estimation. *Comput. Biol. Med.* 33: 509–531.
- Samuel J.L. 1983: Jaw disease in macropod marsupials: bacterial flora isolated from lesions and from the mouths of affected animals. *Vet. Microbiol.* 8: 373–387.
- Sanson G. 1989: Morphological adaptations of teeth to diets and feeding in the Macropodoidea. In: Grigg G., Jarman P. & Hume I. (eds.), Kangaroos, wallabies and rat-kangaroos. *Surrey Beathy & Sons, Sydney, New South Wales*.
- Sanson G.D., Kerr S.A. & Gross K.A. 2007: Do silica phytoliths really wear mammalian teeth? *J. Archaeol. Sci.* 34: 526–531.
- Seimens Medical 2007: SOMATOM Emotion 6/16-slice configuration: application guide – protocols, principles, helpful hints, Software Version syngo CT 2007E. *Seimens, Erlangen, Germany*.
- Sergeant E.S.G. 2018: Epitools epidemiological calculators. *Ausvet Pty Ltd. <http://epitools.ausvet.com.au>*
- Smith G., Oliphant J.C. & Parsons R. 1984: The pathogenic properties of *Fusobacterium* and *Bacteroides* species from wallabies and other sources. *J. Hyg.* 92: 165–175.
- Smith G.R. & Thornton E.A. 1993: Pathogenicity of *Fusobacterium necrophorum* strains from man and animals. *Epidemiol. Infect.* 110: 499–506.
- Stallknecht D. 2007: Impediments to wildlife disease surveillance, research, and diagnostics. In: Childs J.E., Mackenzie J.S. & Richt J.A. (eds.), Wildlife and emerging zoonotic diseases: the biology, circumstances and consequences of cross-species transmission. *Springer, Berlin, Germany*.
- Thomas C., Finn M., Twigg L. et al. 1997: Microsporidia (*Encephalitozoon cuniculi*) in wild rabbits in Australia. *Aust. Vet. J.* 75: 808–810.
- Tomlinson A.R. & Gooding C.G. 1954: A kangaroo disease. Investigations into 'lumpy jaw' on the Murchison, 1954. *J. Dep. Agric. W. Australia* 3: 715–718.
- Tyndale-Biscoe C.H. 2005: Life of marsupials. *CSIRO Publishing, Melbourne, Victoria*.
- Vogelnest L. 2015: Marsupialia (Marsupials). In: Miller R.E. & Fowler M.E. (eds.), *Fowler's Zoo*



- and wild animal medicine. *W.B. Saunders, St. Louis, Missouri, USA.*
- Vogelnest L. & Portas T. 2008: Macropods. In: Vogelnest L. & Woods R. (eds.), *Medicine of Australian mammals. CSIRO Publishing, Collingwood, Victoria.*
- Wallach J.D. 1971: Lumpy jaw in captive kangaroos. *Int. Zoo Yearb. 11: 13.*
- Whittier W.D. & Umberger S.H. 2009: Control, treatment and elimination of foot rot from sheep. *Virginia Cooperative Extension, USA.*
- Wobester G.A. 2006: Essentials of disease in wild animals. *Blackwell Publishing, Ames, Iowa.*