



## **Parapox Infection in a Gazelle Kid (*Gazella gazella*)**

Authors: Yeruham, I., Nyska, A., and Abraham, A.

Source: Journal of Wildlife Diseases, 30(2) : 260-262

Published By: Wildlife Disease Association

URL: <https://doi.org/10.7589/0090-3558-30.2.260>

---

BioOne Complete ([complete.BioOne.org](https://complete.BioOne.org)) is a full-text database of 200 subscribed and open-access titles in the biological, ecological, and environmental sciences published by nonprofit societies, associations, museums, institutions, and presses.

Your use of this PDF, the BioOne Complete website, and all posted and associated content indicates your acceptance of BioOne's Terms of Use, available at [www.bioone.org/terms-of-use](https://www.bioone.org/terms-of-use).

Usage of BioOne Complete content is strictly limited to personal, educational, and non-commercial use. Commercial inquiries or rights and permissions requests should be directed to the individual publisher as copyright holder.

---

BioOne sees sustainable scholarly publishing as an inherently collaborative enterprise connecting authors, nonprofit publishers, academic institutions, research libraries, and research funders in the common goal of maximizing access to critical research.

## Parapox Infection in a Gazelle Kid (*Gazella gazella*)

I. Yeruham,<sup>1</sup> A. Nyska,<sup>2</sup> and A. Abraham,<sup>3</sup> <sup>1</sup> "Hachaklait" Gadera, and the Koret School of Veterinary Medicine, the Hebrew University of Jerusalem, Jerusalem, Israel; <sup>2</sup> The Kimron Veterinary Institute, Bet-Dagan, and the Koret School of Veterinary Medicine, The Hebrew University of Jerusalem, Jerusalem, Israel; <sup>3</sup> The Kimron Veterinary Institute, Bet-Dagan, 50250, Israel

**ABSTRACT:** A captured gazelle kid (*Gazella gazella*) held in a mixed herd of sheep and goats in Israel developed the characteristic lesions of contagious ecthyma. Clinical diagnosis was confirmed by electron microscopy and histopathology examinations of infected tissue.

**Key words:** Contagious ecthyma, *Gazella gazella*.

Contagious ecthyma (CE), also known as orf, is a common disease in sheep and goats and is caused by infection with a parapoxvirus (Robinson and Balassu, 1981). The disease also has been reported in several wild ruminants including bighorn sheep (*Ovis canadensis canadensis*) (Turner and Payson, 1982), mountain goats (*Oreamnos americanus*) (Hebert et al., 1977), Dall sheep (*Ovis dalli dalli*) (Smith, 1982), captive musk oxen (*Ovibos moschatus*) (Kummeneje and Krogsrud, 1978), reindeer (*Rangifer tarandus*) (Kummeneje, 1979), mule deer (*Odocoileus hemionus*) (Lance et al., 1983), and white tailed deer (*Odocoileus virginianus*) (Lance et al., 1983).

Gazelles (*Gazella gazella*) and ibexes (*Capra ibex nubiana*) are abundant wild ruminants in the Middle East. However, little is known about contagious diseases of those animals.

A 2-wk-old gazelle kid was captured and held in a mixed herd of sheep and goats for a week in Gal-On, Lakhish District, in the southern part of Israel (31°08'N, 34°50'E). The CE-like lesions were first noticed on 10 February 1993. Before, during and after this period no morbidity with CE was observed in this herd. After several days, brown raised encrustations appeared on the swollen lips (Fig. 1), oral mucocutaneous junctions, and gingiva of the gazelle; there was no general clinical illness.

The gazelle kid was treated topically

once daily during 8 days with a mixture of 10% oxytetracycline (Vetimex, Bladel, Holland) and 0.1% propylene glycol (Vitamed, Pharmaceutical Industry, Benyamina, Israel). The course of the disease was benign and the lesions disappeared within 2 wk.

Material for electron microscopy and histopathological examination was taken from lip lesions at the acute stage of the disease and prior to treatment. For histological examination, tissue was fixed in 10% buffered formaldehyde. After dehydration and embedding of tissue in paraffin wax, sections were cut at 4 to 50  $\mu\text{m}$  thickness and stained with hematoxylin and eosin. The paraffin blocks and slides were deposited in the archives of the Department of Pathology, Kimron Veterinary Institute, Beit-Dagan, Israel (Reference No. 93-27087). The original material harvested from the infected *Gazella gazella* kid was diluted 1:5 and centrifuged at 8,000 rpm. The sediment was resuspended 1:5 in distilled water and negatively stained for electron microscopy (Amichai et al., 1993), and examined on a JEOL-GEM 100 CX electron microscope (Jeol, Tokyo, Japan).

The histopathologic findings were epidermal basal cell downgrowth proliferation, intrakeratinocytic edema, and only a few intracytoplasmic inclusion bodies typical of poxviruses (Fig. 2). In the adjacent stroma, prominent mixed inflammatory cell infiltration was noted. Electron microscopic examination of the infected tissue revealed virions characteristic of parapoxviruses. Their size was 150 by 250  $\mu\text{m}$ , with rounded ends and dense subpolar regions (Fig. 3).

Contagious ecthyma is a very common disease in sheep and goats in Israel (Yeruham et al., 1991). The disease is common

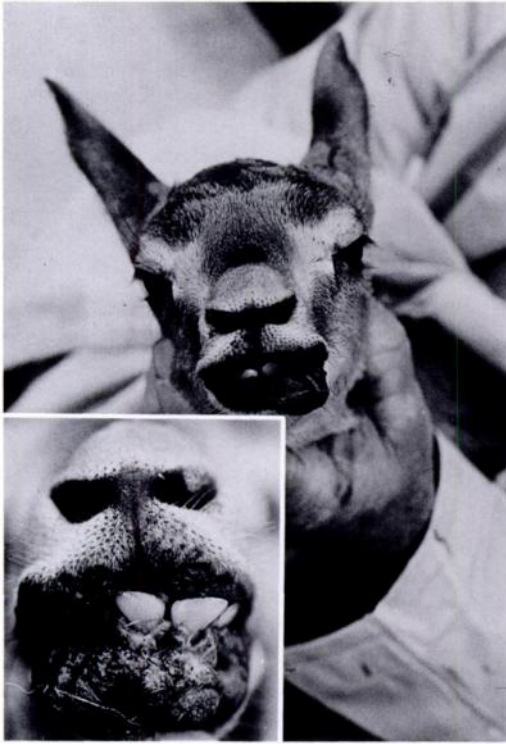

FIGURE 1. A gazelle kid infected with contagious ecthyma. Note swelling of the lips associated with dark encrustations. Inset: close-up view of the cauliflower proliferative skin outgrowth on the lips.

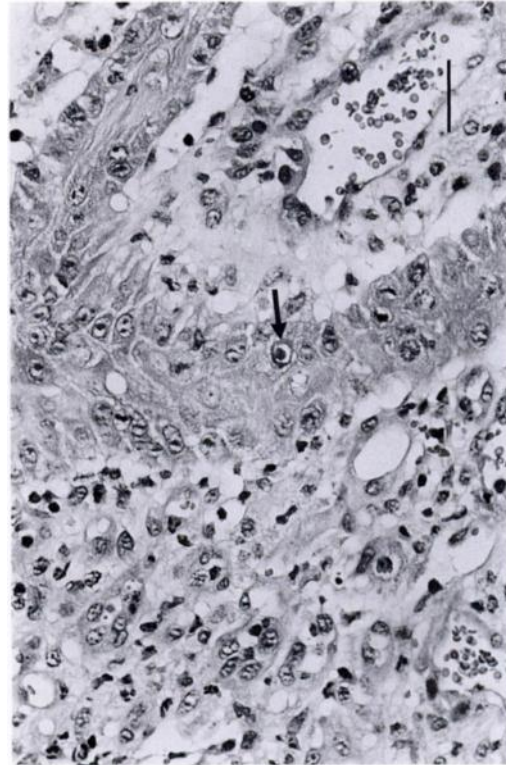


FIGURE 2. Histological section of a biopsy taken from the gazelle's lip. Note the appearance of epidermal proliferating cords of squamous cells associated with dense mixed inflammatory cell infiltration. A single squamous cell has an intracytoplasmic eosinophilic inclusion body (arrow). (H&E) Bar = 25  $\mu$ m.

mainly in lambs and kids and it appears as cauliflower proliferative skin and mucosal outgrowths of the lips and gums.

Although confirmatory tests were not done, the clinical signs and the epizootiological evidence strongly suggested that parapoxvirus observed by electron microscopy was CE virus. This is the first known report of CE in a gazelle.

The fact that this virus withstands drying and that premises have been known to harbor infection for more than a year after the removal of all animals (Gillespie and Timoney, 1981), is important from an epizootiological point of view. Wild ruminants can be either a reservoir for infection which may endanger domestic ruminants (McDiarmid, 1961; Thompson, 1961), or a recipient of infectious diseases via domestic animals, as suggested in our case.

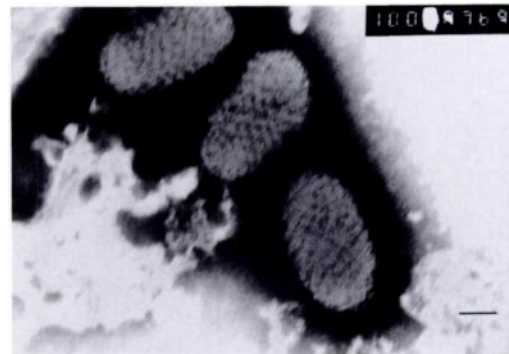


FIGURE 3. Negatively stained transmission electron microscopy of parapox virus found in lip lesion of a gazelle kid. Bar = 100  $\mu$ m.

## LITERATURE CITED

- AMICHAJ, B., M. GRUNWALD, A. ABRAHAM, AND S. HALEVY. 1993. Tense bullous lesions on fingers. *Archives of Dermatology* 129: 1043-1044.
- GILLESPIE, J. H., AND J. F. TIMONEY. 1981. The Poxviridae. In Hagan and Bruner's Infectious diseases of domestic animals. Cornell University Press, Ithaca, New York, pp. 527-550.
- HEBERT, D. M., W. M. SAMUEL, AND G. W. SMITH. 1977. Contagious ecthyma in mountain goat of coastal British Columbia. *Journal of Wildlife Diseases* 13: 135-136.
- KUMMENEJE, K. 1979. Contagious ecthyma (orf) in reindeer. *The Veterinary Record* 105: 60-61.
- , AND J. KROGSRUD. 1978. Contagious ecthyma (orf) in the musk ox (*Ovibos moschatus*). *Acta Veterinaria Scandinavica* 19: 461-462.
- LANCE, W. R., C. P. HIBLER, AND J. DEMARTINI. 1983. Experimental contagious ecthyma in mule deer, white-tailed deer, pronghorn and wapiti. *Journal of Wildlife Diseases* 19: 165-169.
- MCDIARMID, A. 1961. The role of wild life in the dissemination of disease. General introduction and some veterinary problems. *The Veterinary Record* 73: 1329-1334.
- ROBINSON, A. J., AND T. C. BALASSU. 1981. Contagious pustular dermatitis (orf). *Veterinary Bulletin* 51: 771-782.
- SMITH, T. C. 1982. Contagious ecthyma in an adult dall sheep (*Ovis dalli dalli*) in Alaska. *Journal of Wildlife Diseases* 18: 111-112.
- THOMPSON, H. V. 1961. The role of wild life in the dissemination of disease. 2. Ecology of diseases in wild mammals and birds. *The Veterinary Record* 73: 1334-1337.
- TURNER, J. C., AND J. B. PAYSON. 1982. Prevalence of antibodies of selected infectious disease agents in the peninsular desert Bighorn sheep (*Ovis canadensis cremonobates*) of the Santa Rosa mountains, California. *Journal of Wildlife Diseases* 18: 243-245.
- YERUHAM, I., A. HADANI, D. ELAD, D. RATNER, S. PERL, AND B. YAKOBSON. 1991. Dermatophilosis (*Dermatophilus congolensis*) accompanied by contagious ecthyma (orf) in a flock of Yaez in Israel. *Israel Journal of Veterinary Medicine* 46: 74-78.

Received for publication 2 August 1993.