

Mortality of Captive British Wartbiter Crickets: Implications for Reintroduction Programs

Authors: Cunningham, Andrew A., Frank, J. Mick, Croft, Pat, Clarke, Dave, and Pearce-Kelly, Paul

Source: Journal of Wildlife Diseases, 33(3) : 673-676

Published By: Wildlife Disease Association

URL: <https://doi.org/10.7589/0090-3558-33.3.673>

BioOne Complete (complete.BioOne.org) is a full-text database of 200 subscribed and open-access titles in the biological, ecological, and environmental sciences published by nonprofit societies, associations, museums, institutions, and presses.

Your use of this PDF, the BioOne Complete website, and all posted and associated content indicates your acceptance of BioOne's Terms of Use, available at www.bioone.org/terms-of-use.

Usage of BioOne Complete content is strictly limited to personal, educational, and non - commercial use. Commercial inquiries or rights and permissions requests should be directed to the individual publisher as copyright holder.

BioOne sees sustainable scholarly publishing as an inherently collaborative enterprise connecting authors, nonprofit publishers, academic institutions, research libraries, and research funders in the common goal of maximizing access to critical research.

Mortality of Captive British Wartbiter Crickets: Implications for Reintroduction Programs

Andrew A. Cunningham,¹ J. Mick Frank,² Pat Croft,³ Dave Clarke,³ and Paul Pearce-Kelly,³ ¹ Veterinary Science Group, Institute of Zoology, Regent's Park, London NW1 4RY, United Kingdom; ² School of Biological Sciences, University of Surrey, Guildford, Surrey GU2 5XH, United Kingdom; and ³ Invertebrate Conservation Centre, London Zoo, Regent's Park, London NW1 4RY, United Kingdom

ABSTRACT: A fungal infection was identified as the cause of a high mortality rate of captive wartbiter cricket (*Decticus verrucivorus*) nymphs at the London Zoo (United Kingdom) in 1994. This species is threatened with extinction in the United Kingdom and the animals concerned were part of a captive breeding and reintroduction program. Following these findings, reintroductions were postponed and release sites were used only where there were no extant wartbiter crickets.

Key words: Wartbiter cricket, *Decticus verrucivorus*, mycosis, pathology, disease, reintroduction.

Increasingly, endangered invertebrate species are being bred in captivity for reintroduction to the wild. As the current example demonstrates, and as with such programs for vertebrate species, veterinary involvement is required for invertebrate captive breeding programs in order to both maximize breeding success and ensure that disease is not a factor detrimental either to the target or sympatric species (Cunningham, 1996).

The wartbiter cricket (*Decticus verrucivorus*), an orthopteran insect, is vulnerable to extinction in the United Kingdom (Whitten, 1990). Historically, this species ranged throughout the south of England from Wiltshire to Kent, but following habitat loss, it has become restricted to four small, separate populations in recent years (Whitten, 1990). This insect now is one of the target species of the English Nature Species Recovery Programme.

Part of the Species Recovery Programme involves the breeding and rearing of wartbiter crickets in captivity and the reintroduction of the animals both to areas in the wild containing extant crickets and to other suitable habitats in southern England. This work was being carried out

jointly by London Zoo and Imperial College, London, United Kingdom.

Between April and June 1994, 638 of 1,200 eggs laid by wild-caught or F₁ captive-bred wartbiter crickets were hatched in the Invertebrate Conservation Centre, London Zoo. Five hundred eggs were noted to become swollen as if to hatch but failed to do so. The environmental regime used to induce hatching and the subsequent husbandry of the crickets have been described in detail by Croft et al. (1994). Briefly, up to seven crickets each were housed in either one of two sizes of plastic cylindrical containers (12.5 cm diameter × 23 cm high or 23 cm diameter × 38 cm high) and provided with a diet primarily of forbs and grasses (freshly-cut every other day), but which included also fish flake (Aquarian Tropical Fish Flakes, Pedigree Petfoods, Melton Mowbray, England) and cuttlebone. Environmental parameters, such as temperature and lighting, were regulated to mimic natural conditions; however, the humidity in the vivaria often was very high (Croft et al., 1994) and water condensation occurred frequently on the sides of the containers.

Of the 638 eggs that hatched, 354 (55%) crickets died prior to reaching the adult stage of development. The majority died during the first ($n = 254$) and second ($n = 66$) instar stages. Pathological examinations were carried out on 12 nymphs found dead and on one nymph found close to death that was euthanized by rapid manual crushing of the head. Also, in order to provide control material, 15 nymphs which developed malformed legs or wings when hatching or molting were euthanized and examined. Each nymph weighed <0.05 g.

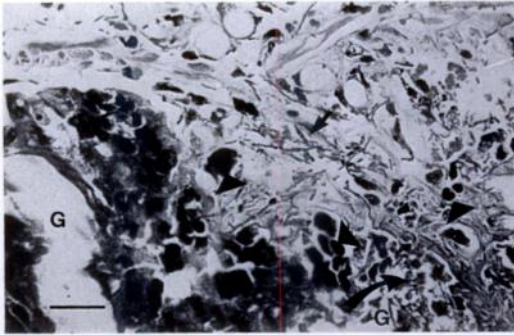


FIGURE 1. Histological section of the abdomen of a euthanized wartbiter cricket with fungal invasion, necrosis (curved arrow) and infiltration with inflammatory cells (arrowheads). Note the gut lumen (G) and an area of possible conidiogenesis (arrow). Hematoxylin and eosin. Bar = 25 μ m.

The cricket that was euthanized close to death was fixed in neutral buffered 10% formalin, embedded in paraffin, sectioned at 2 μ m and stained with hematoxylin and eosin, and with periodic acid-Schiff stains (Drury and Wallington, 1967). Invasion of fungal hyphae into the tissues with associated necrosis and inflammation was noted on histological examination (Fig. 1). In addition, sporulation appeared to be occurring within the carcass (Figs. 1, 2). Similar hyphae containing cross-walls also were seen in abdominal smears made from two of three crickets found dead, but no fungal hyphae were seen in abdominal smears made from 15 control crickets. Swabs taken from the abdominal cavities of nine nymphs found dead were cultured aerobically on horse blood columbia agar and on Sabouraud's agar (QMC Laboratories, London, England) at 25 C for 24 and 48 hrs. Bacteria were identified using API biochemical test strips (API-bio Merieux (UK) Limited, Basingstoke, Hampshire, England). A range of bacteria was isolated, with an approximate equal predominance of *Serratia marcescens* and *Rahnella aquatilis*; a mixed growth of mucoraceous fungi and yeasts also was cultured.

A more-detailed mycological examination of dead nymphs was made from three fresh carcasses. On inspection with a dis-

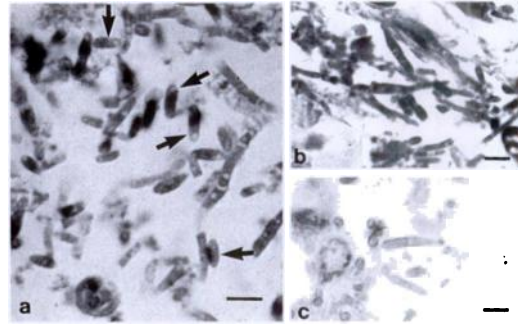


FIGURE 2. Histological sections of the abdomen of a euthanized wartbiter cricket: a) Note apparent *Verticillium lecanii*-form cross-walled hyphae and conidia (arrows). Periodic acid-Schiff; b) A higher power view of the area of possible conidiogenesis illustrated in Fig 1; c) Note apparent *V. lecanii*-form awl-shaped phialides. Periodic acid-Schiff. Each Bar = 5 μ m.

secting microscope we found no visible evidence of mold growth and on examination of abdominal smears we found copious amounts of branched fungal hyphae containing cross-walls in one nymph (carcass number 1), but no evidence of fungal growth in the other two nymphs (2 and 3). Each carcass was placed in a stomacher bag with 2 ml of sterile Ringer's solution and was gently macerated. The resultant suspension was plated on to the enumeration medium DG18 (Samson and van Reenen-Hoekstra, 1988) and also on to malt extract agar containing 5g/l of powdered malt extract (Oxoid L39, Unipath Limited, Basingstoke, Hampshire, England) supplemented with 60 μ g/ml of chloramphenicol (Sigma Chemical Company Limited, Poole, Dorset, England) to inhibit bacterial growth. In each case the fungal growth was greater than 6×10^3 colony forming units per carcass. Similar fungal communities were grown from carcasses 1 and 3, these being jointly dominated by *Mucor circinelloides* var. *lusitanicus* (Schipper, 1978) and *Penicillium olsonii* (Pitt, 1985). A significant growth of green-spored *Aspergillus* spp. also was cultured from carcass No. 3, but all isolates examined proved to be of *Aspergillus versicolor* rather than of the well-documented entomo-

pathogenic *Flavus* group (Klich and Pitt, 1988). All fungi identified from these two carcasses almost certainly were saprophytic. However, the dominant fungal growth from carcass No. 2 was of the well-known insect pathogen *Verticillium lecanii* (Samson et al., 1988) along with the saprophytic molds *Cladosporium* sp. and *P. olsonii*.

Although the sample size of crickets examined post mortem was small, there is evidence that the London Zoo wartbiter cricket colony was adversely affected by a mycotic infection: there was a 55% mortality rate of crickets from hatching to reaching adulthood, and fungal invasion was found on examination of affected, but not unaffected, animals. The species of fungus observed microscopically could not be determined; however the presence of cross-walls precludes the possibility of it being mucoraceous and the general morphology of the hyphae, conidia and phialides was consistent with *Verticillium* sp., as opposed to the other fungi isolated from the cricket carcasses. The question of whether the rate of mortality was within normal limits for captive cricket nymphs should be addressed. It is worth noting that of >1,000 English field crickets (*Gryllus campestris*) hatched at London Zoo in 1994, the comparable mortality rate was less than 10%.

Although the diagnosis of an infectious disease in the wartbiter colony was not made until after the peak of mortality had passed, and hence early control measures were not instigated in this instance, the recognition of the mycosis is of importance for the future management of this species in captivity, even though the species of fungus involved could not be identified conclusively. There were several husbandry factors which may have predisposed the animals to infection and these were addressed for future years. For example, the environmental regime for hatching may have been incorrect resulting in the emergence of weakened animals. The development of 500 eggs to the point of hatching prior to failing is an indicator that the

environmental parameters were not optimal. The high humidity in the vivaria also may have predisposed the insects to a mycotic infection. Additionally, large numbers of spores of the pathogenic fungus may have been present in the environment: *Verticillium lecanii* had been implicated in the deaths of Olympia ground beetles (*Chrysocarabus* (*Carabus*) *olympiae*) 5 yrs earlier (Cunningham and Frank, 1993) and which had been housed in the same room. The recurrence of this pathogen led to the destocking and disinfection (including fumigation) of appropriate areas.

The protocol for the 1994 reintroduction program was affected by the diagnosis of a mycotic infection; the program was delayed for several weeks until the colony appeared to be free of the fungal pathogen. It was assumed that the absence of deaths over a 3-wk period was strong evidence for the absence of the causative fungus, as insects are not known to carry entomopathogenic fungi acclinically. Additionally, the decision was taken not to release captive-reared crickets into areas with existing populations of wartbiter crickets in order to minimize the risk of an epizootic. Along with concerns about introducing a pathogenic fungus into the extant wartbiter cricket colonies, we were also wary of the possibility of adverse effects to sympatric species (Cunningham, 1996). This was particularly so, because the etiological agent was not determined beyond doubt and may not have been enzootic to the area of release. We believe it essential to integrate pathological investigations into captive breeding programs for all species, especially when animals are to be reintroduced to the wild. In addition, the apparent presence of sporulation within the host is of interest. It is generally accepted that sporulation is restricted to the hyphae of the pathogen which emerge from the carcass so that spore dispersal, and thereby further infection, can take place.

We thank Ellen S. Hoekstra and the staff at the Centraalbureau voor Schim-

melcultures, The Netherlands for confirmation of the identities of *V. lecanii* and *Mucor circinelloides* var. *lusitanicus*.

LITERATURE CITED

- CUNNINGHAM, A. A. 1996. Disease risks of wildlife translocations. *Conservation Biology* 10: 349–353.
- , AND J. M. FRANK. 1993. Veterinary observations on an arthropod mycosis with comparison of the efficacy of topical povidone-iodine, nystatin and clotrimazole treatments. *Journal of Zoo and Wildlife Medicine* 24: 508–514.
- CROFT, P., D. CLARKE, P. PEARCE-KELLY, AND A. CUNNINGHAM. 1994. Progress report for 1994 on the ZSL-based populations of the wartbiter cricket (*Decticus verrucivorus*). Zoological Society of London, London, United Kingdom, 13 pp.
- DRURY, R. A. B., AND E. A. WALLINGTON. 1967. Carleton's histological technique. Oxford University Press, Ely House, London, United Kingdom, 432 pp.
- KLICH, M. A., AND J. I. PITT. 1988. A laboratory guide to common *Aspergillus* species and their Teleomorphs. C.S.I.R.O., Division of Food Processing, North Ryde, Australia, pp. 102–103.
- PITT, J. I. 1985. A laboratory guide to common *Penicillium* species. C.S.I.R.O., Division of Food Research, North Ryde, Australia, pp. 140–141.
- SAMSON, R. A., AND E. S. VAN REENEN-HOEKSTRA. 1988. Introduction to Food-borne Fungi. 3rd ed. Centraalbureau voor Schimmelcultures, Baarn, The Netherlands, p. 288.
- , H. C. EVANS, AND J-P. LATGE. 1988. Atlas of entomopathogenic fungi. Springer-Verlag, Berlin, Germany, pp. 126–127.
- SCHIPPER, M. A. A. 1978. On certain species of mucor with a key to all accepted species. *Studies in mycology* No. 17. Centraalbureau voor Schimmelcultures, Baarn, The Netherlands, pp. 48–49.
- WHITTEN, A. J. 1990. Recovery: A proposed programme for Britain's protected species. Chief Scientist Directorate Report No. 1089, Nature Conservancy Council, Petersborough, England, p. 259.

Received for publication 2 February 1996.