

Effect of Emaciation on Liver Histology of Alpine Chamois During Winter

Authors: Bollo, Enrico, Bassano, Bruno, Peracino, Vittorio, and Biolatti, Bartolomeo

Source: Journal of Wildlife Diseases, 35(4) : 770-773

Published By: Wildlife Disease Association

URL: <https://doi.org/10.7589/0090-3558-35.4.770>

BioOne Complete (complete.BioOne.org) is a full-text database of 200 subscribed and open-access titles in the biological, ecological, and environmental sciences published by nonprofit societies, associations, museums, institutions, and presses.

Your use of this PDF, the BioOne Complete website, and all posted and associated content indicates your acceptance of BioOne's Terms of Use, available at www.bioone.org/terms-of-use.

Usage of BioOne Complete content is strictly limited to personal, educational, and non - commercial use. Commercial inquiries or rights and permissions requests should be directed to the individual publisher as copyright holder.

BioOne sees sustainable scholarly publishing as an inherently collaborative enterprise connecting authors, nonprofit publishers, academic institutions, research libraries, and research funders in the common goal of maximizing access to critical research.

Effect of Emaciation on Liver Histology of Alpine Chamois During Winter

Enrico Bollo,^{1,5} Bruno Bassano,² Vittorio Peracino,³ and Bartolomeo Biolatti⁴ ¹ Dipartimento di Patologia Animale, Università degli Studi di Torino, Via Nizza, 52, I-10126, Torino, Italy; ² Dipartimento di Produzioni Animali, Epidemiologia ed Ecologia, Università degli Studi di Torino, Via Nizza, 52, I-10126, Torino, Italy; ³ Ente Parco Nazionale Gran Paradiso, Via della Rocca, 47, I-10123, Torino, Italy; ⁴ Istituto di Patologia e Igiene Veterinaria, Università di Padova, Agripolis, I-35020 Legnaro, Italy; ⁵ Corresponding author (e-mail: bollo@veter.unito.it)

ABSTRACT: With the aim of describing the effect of severe feed restriction on the liver histology, morphometrical analysis of liver sections of 10 alpine chamois (*Rupicapra rupicapra*) was performed. Five animals were found dead during the winter season 1995–96 and five were collected during the hunting season 1996. Hepatocyte nuclear size was measured in squared micrometers using Image-Pro Plus software. A significant decrease in the mean size of the nuclei of hepatocytes in emaciated chamois, as compared to harvested animals was observed. The reduction in cell nuclear size may be linked to the mobilization of body protein to prevent ketosis during severe food restriction, as hypothesized for other wild ungulates. The change in hepatocyte size may be the consequence of a strategy to minimize energy expenditure and may be proposed as an index of metabolic stress during winter undernutrition.

Key words: Alpine chamois, emaciation, liver, hepatocyte size, histology, metabolic stress, *Rupicapra rupicapra*, undernutrition.

During winter and early spring, most northern ungulates develop emaciation because of limited food supply (Gasaway et al., 1983). High population density may aggravate this condition, reducing food availability (Ozoga and Verme, 1982). The annual mortality rate in these populations is closely related to the severity of the weather during the winter (Martinka, 1967; Clutton-Brock and Albon, 1982) and emaciation is the most important cause of mortality (Dean and Thorne, 1982).

When food intake is insufficient and animals enter a negative energy balance, endogenous fat becomes the main source of energy (Wolkers et al., 1994). Long-term dietary restrictions involve severe reduction in body condition. Bone marrow fat content decreases (Riney, 1955; Reich,

1981; Suttie, 1983, Torbit et al., 1988); relative organ sizes are reduced (Canas et al., 1982, Koong et al., 1983) and total protein content in liver, kidney, and muscles is decreased in undernourished animals (Winick and Noble, 1966, Burrin et al. 1988, El Haj et al., 1986, Wolkers et al., 1994). In the liver this protein loss may be brought about by reduction in cell numbers and the lower protein/DNA ratio suggests a reduction also in cell size (Wolkers et al., 1994).

Previous investigations of undernutrition performed using semi-domesticated reindeer (*Rangifer tarandus tarandus*) (Soveri, 1993), rats (Addis et al., 1936) and cattle (Reid et al., 1977a; 1977b) showed significant variation in the mean volume of the hepatocytes. Currently no reports on histological changes in the liver of food-restricted wild mammals are available. The purpose of this study was to investigate the effect of severe feed restriction on the liver histology of alpine chamois by morphometrical analysis.

The study was performed on 10 adult male (>5 yr of age) alpine chamois: five animals (average age = 7.5 yr, \pm 2.3 SD) were found dead in the Gran Paradiso National Park (GPNP; Western Italian Alps, Italy; 45°31'N, 07°16'E) during the 1995–96 winter season, and five harvested chamois (\bar{x} \pm SD = 5.5 \pm 1.7-yr-old) were collected during the 1996 hunting season (November–December) in the Piedmont region (Western Italian Alps, Italy; 45°04'N, 07°41'E). No signs of autolysis were observed in the five animals from the GPNP.

The chamois body condition was estimated by the percentage of fat in tibia marrow, according to Neiland's method (Neiland, 1970). Per cent fat was calculated as dry weight \div wet weight \times 100.

Samples of liver from each animal, were fixed in 10% buffered formalin, paraffin-embedded, cut at 4 μ m, stained either with hematoxylin and eosin or with hematoxylin alone, and observed by light microscopy.

Morphometric analysis of liver sections stained with hematoxylin only was performed using a light microscope (Olympus BX50, Olympus Optical Co., Tokyo, Japan) and a VC44 videocamera (PCO Computer Optics, Kelheim, Germany). The size (area) of the nucleic of hepatocytes was measured in squared micrometers, from the central vein (excluded) towards the periphery of the hepatic lobule, using the Image-Pro Plus Version 1.1 (Median Cybernetics, Silver Spring, Maryland, USA.) software. Ten optical fields at high magnification (400 \times) for each section were evaluated. Measurement of the size of the nuclei of hepatocytes was performed by setting the software's cut-off value at 6.0 squared micrometers, to exclude other types of cells (i.e., inflammatory or reticuloendothelial cells) present in the optic fields. Analysis of variance (ANOVA) was used to evaluate differences between the two groups. Post hoc multiple pairwise comparisons with the Least Significant Difference (LSD) test in an ANOVA analysis were performed (Sokal and Rohlf, 1995). All *P*-values were considered significant at a level of $\alpha = 0.05$.

The average (\pm SD) marrow fat content in the emaciated chamois was 5.5 (\pm 0.8%); while in control chamois was 85.3% (\pm 9.1). Based on per cent marrow fat content, the five animals from GPNP were included in the emaciated group.

The most common hepatic lesion in both groups was non suppurative cholangiohepatitis induced by liver parasites (one emaciated animal; two control animals); in one control animal such a lesion occurred

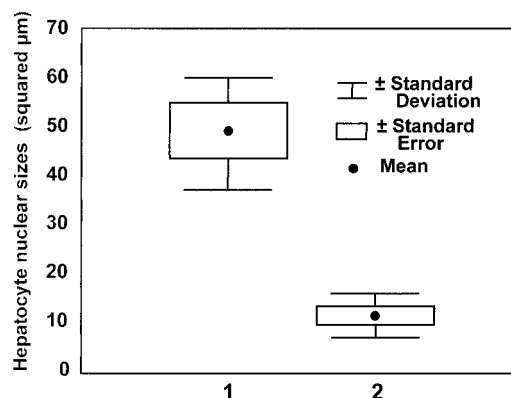


FIGURE 1. Mean hepatocyte nuclear sizes (in squared micrometers) in emaciated chamois and in control chamois (*t*-test; *t* = 6.67, *df* = 8; *P* < 0.001); 1 = Control chamois, 2 = Emaciated chamois).

in association with biliary hyperplasia, while in the other it was associated with an infiltration by eosinophils. No other significant gross or microscopic lesions were detected in control and emaciated animals.

ANOVA showed significant differences in mean hepatocyte nuclear sizes between emaciated and control animals (ANOVA, $F_{1,98} = 72.7$, $P < 0.0001$). Mean sizes of the nuclei of hepatocytes in emaciated chamois (x_2) differed significantly from control animals (x_1) ($t = 6.67$, $df = 8$; $P < 0.001$; $\bar{x}_1 = 48.3 \pm 11.9$ SD; $\bar{x}_2 = 11.3 \pm 3.4$ SD; Fig. 1). A parallel reduction in the total size of hepatocytes was detected, as revealed by the higher average number of nuclei/unit area counted for each sample in emaciated chamois ($\bar{x} = 197 \pm 42$ versus $\bar{x} = 152 \pm 34$ of the controls).

This investigation showed a significant decrease in the mean size of hepatocellular nuclei in emaciated chamois, as compared to control animals. In other mammals, such as reindeer, rat and cattle, the effect of emaciation on the structure of the liver includes a reduction in both cell number and cell size of hepatocytes; in cattle there was increase in the mean volume of lipid droplets in the cytoplasm (Addis et al., 1936; Kosterlitz and Campbell, 1945; Reid et al., 1977a; 1977b; Spence and Hansen-Smith, 1978; Burrin

et al., 1988; Soveri, 1993; Wolkers et al., 1994). Several hypothesis have been proposed to explain this phenomenon such as shortage of amino acids in the cells or hormone-mediated mechanism (Soveri, 1993). This reduction in cell number and size in different organs and tissues may be linked to the prevention of ketosis during severe feed restriction. In fact, in most mammals, massive fat mobilization results in elevated concentration of blood ketone bodies, but this does not occur in red deer (Wolkers et al., 1993). To prevent ketosis, wild ungulates may obtain glucogenetic precursors from body protein, resulting in a decreased protein content of body tissues (Wolkers et al., 1994). This metabolic stress during severe winter undernutrition may be responsible for reduction of cytoplasmic mass through shrinkage of hepatocytes in alpine chamois.

The decrease in the liver weight reported in reindeer during winter (Bjarghov et al., 1977), due to decreased blood circulation and shrinkage of liver cells, may be explained as a strategy to minimize energy expenditure (Soveri, 1993). The change in chamois liver weight and in hepatocytes size may be used as an index of metabolic stress during winter undernutrition. Further investigations are needed to elucidate metabolic mechanisms involved in adaptation of alpine ungulates to winter conditions.

The authors thank F. Mascarello and A. Sereno for their excellent technical assistance.

LITERATURE CITED

- ADDIS, T., L. J. POO, AND W. LEW. 1936. The quantities of protein lost by the various organs and tissues of the body during a fast. *Journal of Biological Chemistry* 115: 111–118.
- BURRIN, D. G., R. A. BRITTON, AND C. L. FERREL. 1988. Visceral organ size and hepatocyte metabolic activity in fed and fasted rats. *Journal of Nutrition* 118: 1547–1552.
- BJARGHOV, R. S., E. JACOBSEN, AND S. SKJENBERG. 1977. Composition of liver, bone and bone marrow of reindeer (*Rangifer tarandus tarandus*) measured at two different seasons of the year. *Comparative Biochemistry and Physiology* 56(A):337–341.
- CANAS, R., J. J. ROMERO, AND R. L. BALDWIN. 1982. Maintenance energy requirements during lactation in rats. *Journal of Nutrition* 112: 1876–1880.
- CLUTTON-BROCK, T. H., AND S. D. ALBON. 1982. Winter mortality in red deer (*Cervus elaphus*). *Journal of Zoology (London)* 198: 515–519.
- DEAN, R. E., AND E. T. THORNE. 1982. Starvation in wild ruminants. In *Diseases of Wildlife in Wyoming*, 2nd Edition. E. T. Thorne, N. Kingston, W. R. Jolley, and R. C. Bergstrom (eds.). Wyoming Game and Fish Department. Cheyenne, Wyoming, pp. 274–280.
- EL HAJ, A. J., S. E. M. LEWIS, AND D. F. GOLDSPIK. 1986. The effect of chronic and acute dietary restriction on the growth and protein turnover of fats and slow type of rat skeletal muscle. *Comparative Biochemistry and Physiology A* 85: 281–286.
- GASAWAY, W. C., R. O. STEPHENSON, J. L. DAVIS, P. E. K. SHEPHERD, AND O. E. BURRIS. 1983. Interrelationships of wolves, prey, and man in interior Alaska. *Wildlife Monographs* 84: 1–50.
- KOONG, L. J., J. A. NIENABER, AND H. J. MERSHMANN. 1983. Effects of plane nutrition on organ size and fasting heat production in genetically obese and lean pigs. *Journal of Nutrition* 113: 1626–1631.
- KOSTERLITZ, H. W., AND R. M. CAMPBELL. 1945. The storage of protein in the adult animal. *Nutrition Abstract Review* 15: 1–14.
- MARTINKA, C. J. 1967. Mortality of northern Montana pronghorns in a severe winter. *The Journal of Wildlife Management* 31: 159–164.
- NEILAND, K. A. 1970. Femur marrow fat in white-tailed deer carcasses. *The Journal of Wildlife Management* 34: 283–289.
- OZOGA, J. J., AND L. J. VERME. 1982. Physical and reproductive characteristics of a supplementally-fed white-tailed deer herd. *The Journal of Wildlife Management* 46: 281–301.
- REICH, A. 1981. Sequential mobilisation of marrow fat in the impala (*Aepyceros melampus*) and analysis of condition of wild dog (*Lycan pictus*) prey. *Journal of Zoology (London)* 194: 409–419.
- REID, I. M., G. D. BAIRD, AND R. J. HEITZMAN. 1977a. Effects of fasting in non-lactating cows. A correlated biochemical and stereological study of fasting-induced fatty liver. *Journal of Agricultural Sciences* 89: 319–325.
- , R. D. HARRISON, AND R. A. COLLINS. 1977b. Fasting and refeeding in the lactating dairy cow. 2. The recovery of liver cell structure and function following a six-day fast. *Journal of Comparative Pathology* 87: 253–265.
- RINEY, T. 1955. Evaluating condition of free-ranging red deer (*Cervus elaphus*), with special reference to New Zealand. *New Zealand Journal of Science and Technology, Section 36(B)*: 429–463.

- SOKAL, R. R., AND F. S. ROHLF. 1995. *Biometry*, 3rd Edition, W.H. Freeman & Co., New York, New York, 1,244 pp.
- SOVERI, T. 1993. Liver histology of reindeer calves during the winter season. *Anatomia Hystologia Embryologia* 22:313–318.
- SPENCE, C. A., AND F. M. HANSEN-SMITH. 1978. Comparison of the chemical and biochemical composition of thirteen muscles of the rat after dietary protein restriction. *British Journal of Nutrition* 39: 647–658.
- SUTTIE, J. M., 1983. The relationship between kidney fat index and marrow fat percentage as indicators of condition in red deer stags. *Journal of Zoology (London)* 201: 563–565.
- TORBIT, S. T., L. H. CARPENTER, R. M. BARTMANN, A. W. ALLDDEAN ET THORNEGE, AND G. C. WHITE. 1988. Calibration of carcass fat indices in wintering mule deer. *The Journal of Wildlife Management* 52: 582–588.
- WINICK, M., AND A. NOBLE. 1966. Cellular responses in rats during malnutrition at various ages. *Journal of Nutrition* 89: 300–306.
- WOLKERS, H., T. WENSING, G. W. T. A. GROOT BRUINDERINK, AND J. T. SCHONEWILLE. 1993. Nutritional status of wild boar (*Sus scrofa*). Body fat reserves in relation to haematology and blood chemistry. *Comparative Biochemistry and Physiology A* 105: 539–542.
- , ———, AND J. T. SCHONEWILLE. 1994. Effect of undernutrition on haematological and serum biochemical characteristics in red deer (*Cervus elaphus*). *Canadian Journal of Zoology* 72: 1291–1296.

Received for publication 12 April 1998