



**ASSESSMENT OF INCREASED SERUM
AMINOTRANSFERASES IN A MANAGED ATLANTIC
BOTTLENOSE DOLPHIN (TURSIOPS TRUNCATUS)
POPULATION**

Authors: Venn-Watson, Stephanie, Smith, Cynthia R., and Jensen, Eric D.

Source: Journal of Wildlife Diseases, 44(2) : 318-330

Published By: Wildlife Disease Association

URL: <https://doi.org/10.7589/0090-3558-44.2.318>

BioOne Complete (complete.BioOne.org) is a full-text database of 200 subscribed and open-access titles in the biological, ecological, and environmental sciences published by nonprofit societies, associations, museums, institutions, and presses.

Your use of this PDF, the BioOne Complete website, and all posted and associated content indicates your acceptance of BioOne's Terms of Use, available at www.bioone.org/terms-of-use.

Usage of BioOne Complete content is strictly limited to personal, educational, and non - commercial use. Commercial inquiries or rights and permissions requests should be directed to the individual publisher as copyright holder.

BioOne sees sustainable scholarly publishing as an inherently collaborative enterprise connecting authors, nonprofit publishers, academic institutions, research libraries, and research funders in the common goal of maximizing access to critical research.

ASSESSMENT OF INCREASED SERUM AMINOTRANSFERASES IN A MANAGED ATLANTIC BOTTLENOSE DOLPHIN (*TURSIOPS TRUNCATUS*) POPULATION

Stephanie Venn-Watson,^{1,2} Cynthia R. Smith,¹ and Eric D. Jensen¹

¹ US Navy Marine Mammal Program, Space and Naval Warfare Systems Center, San Diego, California 92152, USA

² Corresponding author (email: stephanie.vennwatson@navy.mil)

ABSTRACT: Nonspecific chronic hepatitis and increased activities of serum aminotransferases have been reported in cetaceans (dolphins, porpoises, and whales). We identified bottlenose dolphins in our current population with episodic increases in serum aminotransferases, specifically alanine aminotransferase (ALT) and aspartate aminotransferase (AST), and we hypothesized that hematologic and serum biochemical changes in these animals may provide clues as to potential causes of liver disease in cetaceans. A retrospective case-control study involving 1,288 blood samples collected during 1998–2006 from 18 dolphins (six cases and 12 age- and sex-matched healthy controls) was conducted to compare eosinophil and platelet counts; and serum proteins, albumin, globulins, bilirubin, gamma glutamyltransferase (GGT), cholesterol, triglycerides, glucose, iron, and erythrocyte sedimentation rates. Bottlenose dolphins with increased ALT and AST activities were more likely to have higher serum globulins, bilirubin, GGT, iron, glucose, triglycerides, and cholesterol levels, greater erythrocyte sedimentation rates, and lower platelet counts compared to healthy controls. Our findings suggest that dolphins with chronic increases in aminotransferases may have a chronic hepatitis involving iron overload with similar etiologies and pathophysiology compared to terrestrial mammals. Areas for future research include predisposing metabolic risk factors; associations between iron overload and a diabetes-like condition; and a potential overlap syndrome involving autoimmune responses that may or may not be associated with viral infection.

Key words: Atlantic bottlenose dolphin, chronic hepatitis, diabetes mellitus, iron overload, thrombocytopenia, *Tursiops truncatus*.

INTRODUCTION

Liver disease has been reported in cetaceans (dolphins, porpoises, and whales) (Bossart et al., 1990; Resendes et al., 2002; Jaber et al., 2003). Case reports that have described cetacean liver disease etiologies include *Sarcocystis* (Resendes et al., 2002), trematodes (Dailey and Stroud, 1978), hepatitis B-like virus (Bossart et al., 1990), and suspected acquired immunodeficiency (Bossart, 1984). Two population-based studies involving stranded cetaceans in the Canary Islands and coasts of Italy reported 38% and 40% prevalence of nonspecific chronic active hepatitis and nonpurulent hepatitis, respectively (Di Guardo et al., 1995; Jaber et al., 2004).

Etiologies of hepatitis have been extensively studied in terrestrial mammalian species, including dogs (Boomkens et al., 2004), humans (Bondesson and Saperston, 1996), and woodchucks (Menne and Cote,

2007). Causes of chronic hepatitis were once categorized as viral, autoimmune, or metabolic (nonalcoholic fatty liver syndrome); however, all three causes may occur concurrently or in succession to each other (Hui et al., 2002; Lecube et al., 2004; Bugianesi et al., 2006; Nobili et al., 2006; Strassburg, 2006; Wu et al., 2006).

The most common serum biochemical changes associated with hepatitis in terrestrial mammals are increases in liver aminotransferases, specifically, aspartate aminotransferase (AST) and alanine aminotransferase (ALT) (Bondesson and Saperston, 1996). In addition to increased aminotransferases and general indicators of inflammation, other hematologic and serum biochemical changes have been reported in animals with chronic hepatitis depending upon contributing viral, autoimmune, or metabolic factors. These changes include hypergammaglobulinemia associated with autoimmune disease

(Thiele, 2005); high bilirubin and gamma glutamyltransferase (GGT) levels associated with chronic cholestatic disease (Castro-e-Silva Junior et al., 1990); thrombocytopenia associated with the degree of liver cirrhosis (Lu et al., 2006); high serum ferritin levels associated with diabetes mellitus and iron overload in patients with chronic hepatitis C (Lecube et al., 2004); and increased glucose and hyperlipidemia along with diabetes mellitus type 2 and insulin resistance associated with fibrosis and nonalcoholic fatty liver syndrome (NAFLS) (Negro, 2006). As such, detection of hematologic and serum biochemical changes beyond aminotransferases may serve as a useful indicator of the cause and progression of chronic hepatitis.

The US Navy Marine Mammal Program (MMP) cares for a population of Atlantic bottlenose dolphins (*Tursiops truncatus*) that live and work in the open ocean. As part of the MMP's vigilant preventive medicine program, these animals receive routine health examinations, are fed a variety of quality-controlled, frozen-thawed fish, and receive vitamin supplements. Because MMP dolphins have an ongoing opportunity to ingest wild fish that coexist in their environment, semianual antihelminthics are provided to prevent parasitic infections. There are currently no vaccines licensed for use in marine mammals. During the past 20 yr, a number of dolphins have been identified with periodic increases of aminotransferases; clinical signs in these animals are limited to mild decreases in appetite. The cause of increased aminotransferases in these dolphins is unknown.

A retrospective case-control study involving current bottlenose dolphins with chronically increased aminotransferases was conducted under the null hypothesis that, aside from increased ALT and AST activities, there would be no additional significant differences when comparing selected hematologic and serum biochemical values of these cases with healthy age- and sex-matched controls over the years

1998 through 2006. Significant differences identified between cases and controls were subsequently compared to existing literature on hepatitis in other mammalian species.

MATERIALS AND METHODS

Sample collection and laboratory analysis

Blood samples were collected by venipuncture from animals trained to voluntarily present their tail for sampling or using behavioral conditioning out of the water on a foam mat during a routine physical exam. Samples were collected using a 20- or 21-gauge 1.5-inch Vacutainer® needle (Becton Dickinson VACUTAINER Systems, Rutherford, New Jersey, USA). Blood was collected into a Vacutainer® serum separator tube (SST) or a Vacutainer® ethylenediamine tetraacetic acid (EDTA) (K₃) tube for serum chemistry and complete blood counts (CBC), respectively. Samples marked as "fasting" were typically collected 12 to 14 hr after an animal's last feeding.

Samples were chilled for 30 min and centrifuged within 2 hr. Centrifugation was performed at 1,006 × G at 21 C for 10 min. Fibrin clots were removed, and serum was transferred to a 5-ml plastic submission tube. Whole blood was submitted in EDTA Vacutainer® tubes. All samples were sent on ice via courier to Quest Diagnostic Laboratories in San Diego, California, USA.

Automated analyses were used by Quest Diagnostic Laboratories, including the Coulter® LH 1500 Series (Beckman Coulter, Inc., Fullerton, California, USA) for hematology and the Olympus® AU600 (Olympus America Inc., Center Valley, Pennsylvania, USA) for serum chemistry analysis. Paired manual CBC counts using stained slides were routinely conducted on all samples to confirm automated counts, including comments regarding impacts on platelet counts due to artificial clumping. Samples impacted by artificial clumping were excluded from analyses involving platelet counts.

The following hematologic and serum biochemical variables were measured and incorporated into the retrospective study: absolute eosinophil count, platelet count, glucose, total protein, albumin, globulins, cholesterol, triglyceride, lactate dehydrogenase (LDH), aspartate aminotransferase (AST), alanine aminotransferase (ALT), gamma glutamyltransferase (GGT), iron, and erythrocyte sedimentation rate (ESR).

Case animals

A case was defined as an Atlantic bottlenose dolphin in the current MMP population with a minimum of 20 blood samples submitted for hematologic and serum biochemical analysis from July 1998 through October 2006, of which, at least 30% of samples had aspartate aminotransferase (AST) and alanine aminotransferase (ALT) activities in higher than normal reference ranges (>255 – $386 \mu\text{l}$ for AST and >41 – $60 \mu\text{l}$ for ALT, based upon the animal's age at time of blood collection) that occurred longer than a one-year period.

Once cases were identified, retrospective analysis and graphing of all serum ALT levels by age were conducted for each case (blood collection years ranged from 1975 to 2006, depending upon the age of the animal). The MMP records associated with identified cases were reviewed for clinically relevant information, including age, sex, clinical signs, and preventive- or treatment-associated medications. Ultrasound-guided percutaneous liver biopsies (16-gauge Tru-cut, Cardinal Health, Dublin, Ohio) were performed on two animals during the study period and submitted to external agencies for histopathologic examination.

Case-control animals

A control was defined as an Atlantic bottlenose dolphin with a minimum of 20 samples submitted for serum chemistry analysis during July 1998 through October 2006 for which no serum samples with ALT and AST activities higher than normal reference ranges were found. Two control animals were matched by age and sex to every case animal. Further, a one-way analysis of variance and a chi-squared test were conducted to assess significant differences in age and sex, respectively, between the case and control populations.

Statistical analysis

Platelet and selected serum biochemistry variable results from nonhemolyzed blood samples were compared between case and control groups; an analysis of covariance using a general linear model in SAS[®] software (Release 8e; SAS Institute, Inc., Cary, North Carolina, USA) was selected to control for varying numbers of serum samples per animal. Time of last feeding has been documented to affect serum biochemical variables in healthy bottlenose dolphins (Venn-Watson and Ridgway, 2007); as such, fasting status was controlled for as a covariate in the model. The independent variable was the animal's status as

a case or control, and the dependent variables were selected hematologic and serum biochemical variables. Significance was defined as a type-I sum of squares (SS) *P* value less than or equal to 0.01. Reported means from the general linear model are least squares means controlling for fasting status.

To further assess the clinical significance of the study's initial outcomes, follow-up Mantel-Haenszel chi-square tests were conducted to compare percentages of clinically high or low hematologic and serum biochemical values, by case or control status, for those variables with significant mean differences. Normal reference ranges were established previously using 1,113 routine, nonhemolyzed blood samples collected from 52 healthy bottlenose dolphins (mean value \pm 1.645 times the standard deviation); final reference ranges were determined by sex and/or the following four age categories: 1–5 yr, >5 to 10 yr, >10 to 30 yr, and >30 yr (Venn-Watson et al., 2007). Samples values were considered to be clinically high if they were greater than the following reference normal high values, in order of ascending age categories: globulins (g/dl, 2.8, 3.1, 3.1, 3.8), GGT (μl , females 35, 37, 70, 40; and males 36, 40, 49, 40), cholesterol (mg/dl, 282, 257, 257, 280), triglyceride (mg/dl, 83, 100, 137, 139), iron ($\mu\text{g/dl}$, females 279, 276, 326, 295; and males 270, 313, 290, 256), and ESR (60 min, females 19, 17, 19, 17; and males 17, 20, 18, 19). An animal was considered to be thrombocytopenic if platelet numbers were less than the following low normal reference values by ascending age category ($\times 10^3$ cells/ μl): 99, 89, 58, and 52. Glucose was considered to be clinically high if values were greater than 137 mg/dl in a female dolphin or greater than 142 mg/dl in a male dolphin.

RESULTS

Case animals

Six Atlantic bottlenose dolphins were identified with increased serum ALT and AST activities recurring longer than 1 yr. The median age of cases was 25 yr (range 23.1 to 43.0); three (50%) were female, and three (50%) were male. One animal was captive born, and the remaining five animals originated from the Gulf of Mexico. The median duration of time that case animals had been at the MMP was 21.2 yr (range 18.7–36.5). The duration of increased aminotransferases in cases ranged from 9 to 12 yr (Table 1), and

TABLE 1. Clinically relevant hematologic and serum biochemical values among Atlantic bottlenose dolphins (*Tursiops truncatus*) with increased aminotransferases occurring longer than 1 yr.

Animal ID (age in yr, sex ^a)	n	Case duration (yr)	L.S. means, ALT ^b (μl) Ref:		L.S. means, AST ^b (μl) Ref:		L.S. means, serum iron (μg/dl) Ref:		Hyperlipidemia		
			41–60	75	255–386	71–339	Thrombocytopenia (<52–58×10 ³ cells/μl) v	Hyperglobulinemia (>3.1–3.8 g/dl) % of blood samples	High cholesterol (>257–280 mg/dl) % of blood samples	High triglycerides (>137–139 mg/dl) % of blood samples	
Animal A 23 yr, F	69	9.0	75	402	395	7.6	2.9	15.9	58.0		
Animal B 29 yr, M	76	19.0	127	667	557	28.2	67.1	84.2	97.4		
Animal C 25 yr, F	55	15.5	150	708	485	13.2	16.4	41.8	47.3		
Animal D 25 yr, F	103	12.5	104	556	628	35.0	71.8	27.2	74.8		
Animal E 43 yr, M	63	12.5	80	364	317	24.2	49.2	30.2	12.7		
Animal F 24 yr, M	138	12.0	71	463	459	25.2	12.3	22.5	88.4		

^a M = male, F = female.

^b Least squares (L.S) means controlling for feeding state. ALT = alanine aminotransferase, AST = aspartate aminotransferase.

episodic increases in aminotransferases associated with decreased appetite and activity were detected in all six cases (Fig. 1a–f).

Fecal flotations were performed routinely on all six animals once or twice a year throughout the study period; no evidence of parasites was reported. All animals received routine antihelminthic medications throughout the study period.

A variety of medical treatments was administered to most case animals during episodes of increased serum aminotransferases. Animals B and E had routinely reported decreases in serum aminotransferases and normal appetite following administration of low-level oral corticosteroids (oral prednisolone, 5–20 mg once a day); animal C, the only case to have consistently increasing ALT activity over time (Fig. 1c), was the only animal not given corticosteroids or antibiotics during episodes. These results support the hypothesis that these potential hepatopathies were not steroid induced. Due to suspected *Brucella*-associated hepatitis in animal F, long-term doxycycline and rifampin treatment (600 mg rifampin and 600 mg doxycycline orally once a day) was initiated at the age of 22.5 yr; initiation of this treatment coincided with sustained normal serum ALT levels for greater than 200 days (Fig. 1f). Use of doxycycline and rifampin treatments in other case animals did not demonstrate a similar significant change in aminotransferases.

Liver biopsies were collected from animal B (2001) and animal C (2007), and tissues were submitted for histopathologic examination. Animal B was diagnosed with chronic active hepatitis and hemosiderosis possibly associated with a hemochromatosis-like condition. Reported tissue abnormalities included abundant iron, confirmed by histochemical staining, within most hepatocytes and sinusoidal macrophages; moderately increased fibrous connective tissue in portal areas extending to the border of hepatic lobules; increased bile duct and vascular

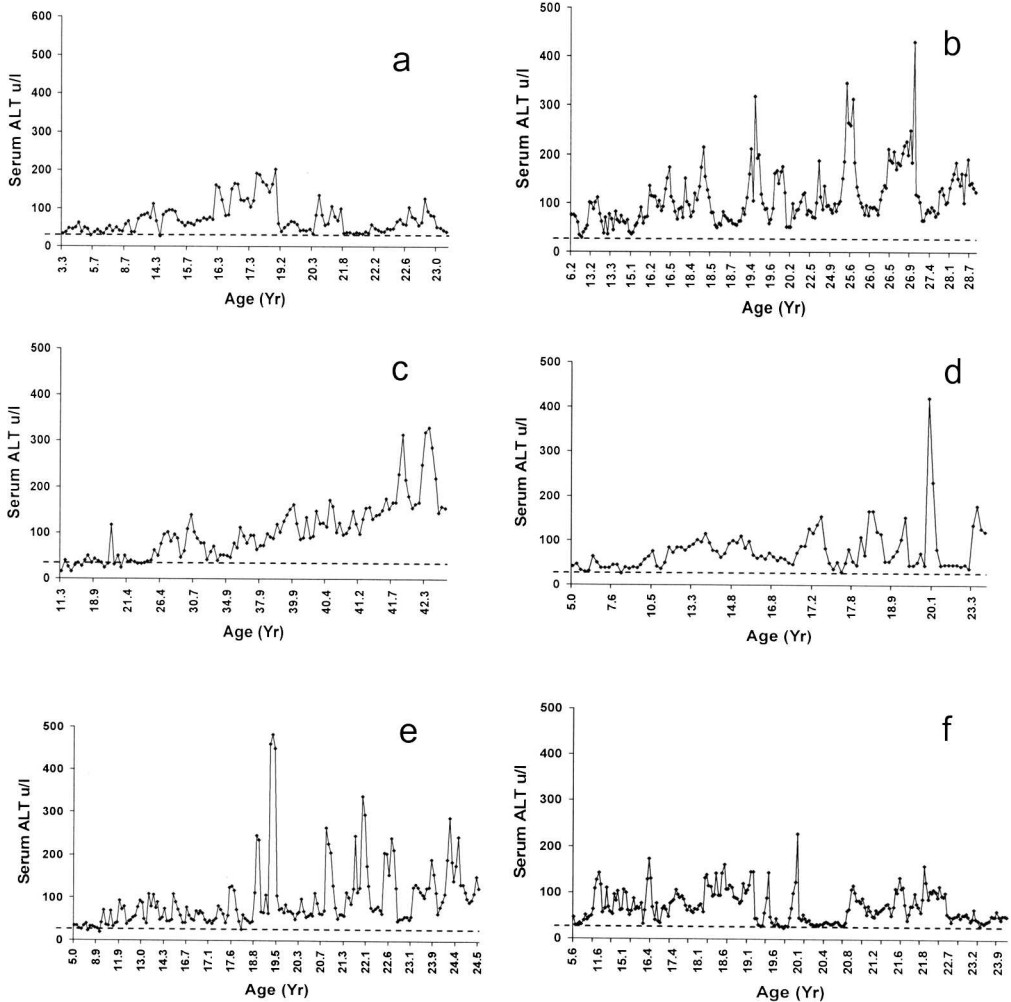


FIGURE 1. Serum alanine aminotransferase levels (ALT, μl) by age in six Atlantic bottlenose dolphins (*Tursiops truncatus*). High normal serum ALT levels in the Navy Marine Mammal population is 55 μl . (a) Animal A; (b) animal B; (c) animal C; (d) animal D; (e) animal E; (f) animal F.

profiles associated with the fibrosis; and scattered necrotic cells. Although mononuclear leukocytes and neutrophils were present within the portal triads, no infectious agents were detected with special stains.

Animal C was diagnosed with diffuse, moderate hemosiderosis with mild multifocal vacuolar degeneration. Mild and moderate amounts of intracellular iron were confirmed by histochemical staining in hepatocytes and Kupffer cells, respectively. No appreciable inflammatory process was visible at the time of biopsy.

Case-control study

Twelve healthy controls were matched by age and sex to six cases. There were no significant differences in sex (cases=50% females and controls=50% females) and age (median age, cases=24.5 yr; median age, controls=25.5 yr; $p=0.26$) when comparing the two study populations. The age range of animals in the study was 14.6 to 42.5 yr. Hematologic and serum biochemical data from 1,288 serum samples were included in the analysis; 504 (39.1%) and 784 (60.9%) were from cases and controls, respectively; analyses involv-

TABLE 2. Differences in mean hematologic and serum biochemical values by presence or absence of chronically elevated aminotransferases, *Tursiops truncatus* (1998–2006).

Variable	Reference range ^a	LS means, ^b cases (n=504)	LS means, controls (n=784)	P value
GGT ^c (μ/l)	21–48	313	37	<0.0001
Bilirubin (μ/l)	0.1–0.4	0.3	0.2	<0.0001
Eosinophil count (×10 ³ cells/μl)	0.8–1.8	1.3	1.2	0.22
Platelets (×10 ³ cells/μl)	55–143	85	105	<0.0001
Protein (g/dl)	6.2–7.6	7.4	7.0	<0.0001
Albumin (g/dl)	3.9–4.9	4.3	4.3	0.02
Globulins (g/dl)	2.1–3.1	3.1	2.7	<0.0001
Glucose (mg/dl)	85–144	111	108	0.01
Cholesterol (mg/dl)	153–262	258	206	<0.0001
Triglycerides (mg/dl)	11–175	218	94	<0.0001
Iron (μg/dl)	92–300	485	190	<0.0001
ESR ^d (60 min)	0–18	25	12	<0.0001

^a In-house reference ranges for an adult dolphin aged >10–30 yr (Venn-Watson et al., 2007).

^b LS means = least squares means controlling for feeding state.

^c GGT = gamma glutamyltransferase.

^d ESR = erythrocyte sedimentation rate.

ing platelet counts not affected by clumping were limited to 1,208 samples (458 [37.9%] cases and 750 [62.1%] controls). When comparing mean values of 12 blood variables among cases and controls (excluding the case-defining variables ALT and AST), 10 (83.3%) of the variables were significantly different (Table 2).

Cases were more likely to have higher glucose, protein, globulins, GGT, bilirubin, cholesterol, triglycerides, and iron levels, and ESR and lower platelets compared to controls. There were no significant differences when comparing absolute eosinophil counts or serum albumin values.

With regard to clinical relevance, cases were more likely to have thrombocytopenia (cases=23.8%, controls=13.0%; $P<0.0001$); hyperglobulinemia (cases=184/504 [36.5%], controls=132/784 [16.8%]; $P<0.0001$); and hyperlipidemia, including high serum cholesterol (cases=176/504 [34.9%], controls=71/784 [9.1%]; $P<0.0001$) and high serum triglycerides (cases=347/504 [68.9%], controls=109/784 [13.9%]; $P<0.0001$) compared to controls. A breakdown of

the prevalence of abnormal blood values in our case animals is provided in Table 1.

DISCUSSION

We report a series of hematologic and serum biochemical changes in six Atlantic bottlenose dolphins with episodic increases in serum aminotransferases (ALT and AST) over a minimum of 9 yr; these changes were not found in 12 age- and sex-matched control dolphins. Liver biopsies conducted on two of the cases confirmed chronic hepatitis in one dolphin and excessive iron deposition in both dolphins. While *Sarcocystis* (Resendes et al., 2002), a hepatitis B-like virus (Bossart et al., 1990), and suspected autoimmune deficiency (Bossart, 1984) have been associated with sporadic cases of hepatitis in cetaceans, two population-based studies involving stranded cetaceans in the Canary Islands and coasts of Italy reported 38% and 40% prevalence of nonspecific chronic active hepatitis and nonpurulent hepatitis, respectively (Di Guardo et al., 1995; Jaber et al., 2004).

Increased ALT activity is the most

common serum biochemistry abnormality reported in humans and dogs with chronic hepatitis (Bain and Ma, 1997), and the most common clinical signs in dogs with hepatitis are decreased appetite and lethargy (Sevelius, 1995). Due to the long duration of episodic increases in serum aminotransferases associated with periods of decreased appetite, significant associations of case dolphins with increased levels of inflammatory indicators (erythrocyte sedimentation rate), and previous documentation of a high prevalence of chronic, nonspecific hepatitis in wild dolphin populations (Jaber et al., 2004), our primary tentative diagnosis for these six cases is chronic hepatitis with associated hemosiderosis.

Causes of chronic hepatitis in terrestrial mammals have traditionally fallen under the categories of infectious, metabolic, or toxic. In most cases, the cause of hepatitis in mammals is unknown (Boomkens et al., 2004). In dogs, known etiologies include canine adenovirus (Davies et al., 1961), *Leishmania* spp. (Rallis et al., 2005), *Leptospira* serovars (Bishop et al., 1979), and copper storage disease (Hultgren et al., 1986; Webb et al., 2002; Hoffman et al., 2006). However, Boomkens et al. (2004) concluded that the etiology of hepatitis in dogs is likely multifactorial.

Animal F (Fig. 1f) maintained normal ALT levels while being treated with doxycycline and rifampin; interestingly, this dolphin had chronically high serum antibody titers to *Brucella*, a potential liver pathogen in cetaceans (Clavareau et al., 1998) that can respond to doxycycline and rifampin treatment. Similar responses were not reported when doxycycline and rifampin were used in other case dolphins, and liver biopsies from two cases did not indicate a primary infectious agent.

An infusion of research related to chronic hepatitis has emerged over the past 5 yr strongly supporting either concurrent or consequential infectious, metabolic, and autoimmune etiologies (Hui et al., 2002; Lecube et al., 2004; Nobili et al.,

2006). Many of these studies have focused on nonhepatic hematologic and serum biochemical indicators of potential chronic hepatitis etiologies, including iron, glucose, lipids, globulins, bilirubin, GGT, and platelets.

Iron

In our study, case dolphins had more than twice the mean value of serum iron compared to healthy controls. Further, animals B and E were diagnosed with excess iron deposition upon histopathologic examination of liver biopsies; tissue samples were not submitted from the remaining case animals. Based upon the histopathologic results and elevated serum iron levels in cases compared to controls, abnormal iron metabolism is likely associated with chronic hepatopathy in our dolphin population.

Iron overload, potentially associated with hemochromatosis, has been documented in northern fur seals (Mazzaro et al., 2004). Similarly, increased levels of hemosiderin and iron accumulation have been reported in livers of Bedlington terriers affected by copper-associated liver disease (Hultgren et al., 1986) and in 34 dogs studied with various types of chronic hepatitis (Fuentealba et al., 1997). Iron deposition from abnormally high serum iron may lead to liver disease; conversely, liver disease can be a risk factor for iron deposition (Bartolo et al., 1998). If iron overload is associated with hepatopathy in dolphins, further research will be needed to determine whether or not iron deposition is the cause of and/or caused by liver disease.

In terrestrial mammals, hepcidin has been identified as a peptide associated with iron metabolism, and changes in hepcidin have been correlated with iron overload and iron deficiency (Nicolas et al., 2002). More specifically, Nicolas et al. (2002) demonstrated associations among inflammatory disease–invoked hepcidin gene expression changes and iron metabolism.

Deposition of iron has been reported in human patients with chronic hepatitis C (CHC), and iron overload is a recognized risk factor of fibrosis in patients with CHC (Metwally et al., 2004). Mifuji et al. (2006) found that patients with CHC were significantly more likely to have higher total hepatic iron stores and transferrin receptor 2 (TfR2) expression compared to patients with chronic hepatitis B (CHB), indicating that hepatitis C virus (HCV) may upregulate TfR2 and subsequent deposition of iron in the liver. Another study by Nagashima et al. (2006) reported that patients with CHC had poorer regulation of serum prohepcidin compared to patients with CHB; they proposed that HCV may induce poor prohepcidin regulation, leading to elevated serum ferritin levels and iron overload.

To further complicate the picture, associations have been made between insulin resistance and serum ferritin, in which the severity of insulin resistance syndrome has been correlated to increasing serum ferritin levels (Wrede, 2006). Several studies have attempted to understand the relationships among iron overload, insulin resistance, and CHC (D'Souza et al., 2005; Palekar and Harrison, 2005); both Hernandez et al. (2000) and Lecube et al. (2004) found that the presence of diabetes mellitus was the primary risk factor for increased ferritin levels in patients with CHC.

Healthy bottlenose dolphins have been demonstrated to have a fasting hyperglycemia and a prolonged glucose tolerance curve that is similar to humans with diabetes mellitus; this diabetes-like physiologic response, however, appears to be a normal part of dolphin metabolism (Ridgway et al., 1970; Ridgway, 1972; Venn-Watson and Ridgway, 2007). Our findings of high serum iron associated with chronic hepatitis in a species with a diabetes mellitus-like fasting state may be a research avenue of interest.

Hyperlipidemia and increased glucose

We report that dolphins with episodic increases in serum aminotransferases were more likely to have higher serum glucose, cholesterol, and triglyceride levels, including a higher prevalence of hyperlipidemia, compared to controls. Hyperlipidemia and increased aminotransferases can indicate steatosis (fatty change) in humans (Bayard et al., 2006); retrospective examination of histopathologic reports from bottlenose dolphin liver tissues at necropsy revealed that five of 18 (27.8%) animals with hepatitis had evidence of mild or moderate steatosis, confirming that fatty liver changes are associated with hepatitis in dolphins.

Chronic steatosis in humans can be caused by metabolic disease (nonalcoholic fatty liver disease, NAFLD), HCV infection, or a combination of both metabolic and viral abnormalities. Bugianesi et al. (2006) reported that patients with viral-only-associated steatosis had low serum cholesterol levels, while patients with NAFLD-only steatosis had a higher prevalence of insulin resistance and high serum glucose, ferritin, and hypertriglyceridemia. Additional studies have demonstrated that people who are heavier, diabetic, hypertensive, and hypertriglyceridemic are more likely to have both HCV infection and NAFLD compared to people that had HCV alone (Sanyal et al., 2003); that hyperlipidemia, steatosis, and type-2 diabetes mellitus can trigger HCV infections (Negro, 2006); and that some genotypes of HCV can induce steatosis (Hui et al., 2002).

As mentioned previously, healthy bottlenose dolphins have a glucose metabolism that mimics that of people with diabetes (Venn-Watson and Ridgway, 2007). Previous studies reported in the human literature, paired with our findings of increased glucose and iron levels and hypertriglyceridemia in dolphins with suspected and confirmed chronic hepatitis (including three dolphin cases with greater than 50% of serum samples with

hyperlipidemia) may suggest that a NAFLD-like condition and an accompanying metabolic syndrome, with or without a viral infection, may play a role in chronic liver disease in our dolphin population.

Hyperglobulinemia

We found that dolphins with episodic increases in serum aminotransferases recurring greater than 1 yr were more likely to have higher serum globulins and a higher prevalence of hyperglobulinemia compared to controls. In human populations, sustained increased aminotransferases paired with hypergammaglobulinemia can be an indicator of chronic autoimmune hepatitis (Thiele, 2005). Autoimmune hepatitis can be triggered by hepatitis C (Czaja, 1999), hepatitis B (Nobili et al., 2006), and hepatitis A (Tanaka et al., 2005) viruses. Patients with chronic liver disease involving both hepatitis C virus and autoimmune hepatitis were more likely to have cirrhosis compared to patients without an autoimmune component (Wu et al., 2006).

Of our six cases, three dolphins had hyperglobulinemia for greater than 40% of blood samples collected from 1998 through 2006; at least two of these animals (B and E) traditionally responded well to corticosteroid treatment, the treatment of choice for human patients with autoimmune chronic hepatitis. Increased serum globulins, however, may increase after any immune stimulation, and hypergammaglobulinemia would need to be confirmed via electrophoresis to rule out acute phase responses to other immune stimulants, including primary viral infections.

There is evidence that hepatitis viruses may be present in cetaceans, including a hepatitis B-like virus in a Pacific white-sided dolphin with hepatitis (Bossart et al., 1990) and demonstrated susceptibility of dolphin cell lines to hepatitis A infection (Dotzauer et al., 1994). Due to the open-ocean nature of MMP animal pens, means of potential terrestrial hepatitis virus

exposure in our population include sewage line failures and land contamination that may occur after heavy rainstorms. To differentiate between acute phase immune response to a pathogen and autoimmune hepatitis in dolphin populations, follow-up studies using dolphin-specific IgG assays, protein electrophoresis, and viral hepatitis antibody and antigen assays are needed.

High GGT and Bilirubin

In our study, case dolphins were more likely to have higher serum bilirubin and GGT levels compared to control dolphins. Increased bilirubin and GGT levels can reflect chronic cholestatic disease associated with liver disease (Castro-e-Silva Junior et al., 1990). Chronic cholestatic diseases may involve primary biliary cirrhosis, primary sclerosing cholangitis, or autoimmune hepatitis (Beuers and Rust, 2005; Strassburg, 2006). Conditions involving multiple autoimmune liver diseases that affect hepatocytes and the biliary system are called overlap syndromes (Schramm and Lohse, 2005). Retrospective examination of histopathologic reports from bottlenose dolphin liver tissues at necropsy demonstrated that four of 18 (22.2%) dolphins diagnosed with mild or moderate hepatitis had cholestasis, confirming that cholestasis is associated with hepatitis in this population of animals. In addition to assessing well-established relationships between hepatitis and cholestasis, there may be a need for species-specific autoantibody tests to further assess the potential for autoimmune overlap syndromes, with or without viral infections, in dolphins with evidence of chronic hepatitis and cholestatic disease.

Thrombocytopenia

We report lower mean platelet counts and a higher prevalence of thrombocytopenia when comparing case and control dolphins. Ho et al. (1999) reported a correlation between decreasing platelet count and the severity of cirrhosis in

human patients; Lu et al. (2006) found that thrombocytopenia can serve as an effective indicator of chronic hepatitis that has progressed to cirrhosis. Of the six case dolphins, three had significantly higher numbers of serum samples with thrombocytopenia compared to controls; the dolphin with the greatest percentage of samples with thrombocytopenia (animal B) had periportal fibrosis and chronic hepatitis confirmed by histopathologic examination.

Thrombocytopenia has been associated with many human liver disorders, including autoimmune chronic hepatitis (Sotelo and Lopez, 2005), thrombocytopenic purpura-associated hepatitis C virus infection (Pyrsoopoulos and Reddy, 2001; Iga et al., 2005), and herpes simplex virus hepatitis (Allen and Tuomala, 2005). Due to decreased platelet counts and other coagulation factors, patients with liver disease are susceptible to bleeding abnormalities (Trotter, 2006). One explanation for thrombocytopenia in patients with hepatic disease is decreased thrombopoietin, a liver-generated cytokine responsible for production of thrombocytes in the bone marrow; as functional liver mass decreases, so does the amount of thrombopoietin (Peck-Radosavljevic, 2000). Another explanation for thrombocytopenia in patients with liver disease, especially viral-induced hepatitis, may be an autoimmune mechanism mediated by platelet-associated immunoglobulin, PAIg (Jiang et al., 2004). While animal B had the highest incidence of thrombocytopenia, no bleeding abnormalities were reported during the study period, including the liver biopsy procedure. Further work is needed to better understand platelet abnormalities in dolphins with liver disease.

In our study, there were no significant differences in albumin levels when comparing cases and controls. Sevelius (1995) reported that hypoalbuminemia was present in dogs with liver cirrhosis and chronic progressive hepatitis, while normal albumin levels were maintained in dogs with

chronic nonspecific hepatitis. Further research studying albumin levels and liver disease in dolphins may be a useful means of discriminating between types of hepatoopathies.

Limitations of our study include retrospective analysis of data not collected for the primary purpose of this research, potential variation of intralaboratory hematologic and serum biochemical results due to personnel changes over a 7-yr period, and potential variation in blood panel results due to small variations in storage time before processing.

In summary, we report that bottlenose dolphins with episodic increases in aminotransferases recurring over a minimum of nine years had associated serum chemistry changes similar to those reported in mammals with combined autoimmune-, viral-, and metabolic-associated chronic hepatitis. Follow-up research focusing on each of these components, including development of dolphin-specific autoantibodies and antibody assays for hepatitis viruses, improved diagnostics for potential *Brucella*-associated liver infections, and better understanding of the natural, diabetes-like metabolic state of dolphins, is needed. While a high prevalence of chronic hepatitis has been reported in wild cetacean populations, additional liver tissues need to be examined from suspect cases in our population to discriminate between chronic hepatitis and other liver diseases.

ACKNOWLEDGMENTS

We thank S. Ridgway for his leadership of scientific research at the US Navy Marine Mammal Program and W. Van Bonn for his management of select data and cases throughout the duration of this study. S.V. conceived the study, carried out the study and analysis, and wrote the manuscript; E.D.J. and C.R.S. managed and tracked the clinical cases in the study and edited the manuscript.

LITERATURE CITED

- ALLEN, R. H., AND R. E. TUOMALA. 2005. Herpes simplex virus hepatitis causing acute liver

- disfunction and thrombocytopenia in pregnancy. *Obstetrics and Gynecology* 106: 1187–1189.
- BAIN, V. G., M. MA. 1997. Chronic hepatitis. In *First principles of gastroenterology: The basis of disease and an approach to management*. 3rd Edition, E. A. Schaffer and A. B. Thomson, Astra Inc., Staff. 1997 Canadian Association of Gastroenterology Staff (eds.). 1997. Canadian Public Health Association, Ottawa, Canada, pp. 492–502.
- BARTOLO, C., P. E. McANDREW, AND R. C. SOSOLIK. 1998. Differential diagnosis of hereditary hemochromatosis from other liver disorders by genetic analysis: Gene mutation analysis of patients previously diagnosed with hemochromatosis by liver biopsy. *Archives of Pathology and Laboratory Medicine* 122: 633–637.
- BAYARD, M., J. HOLT, AND E. BOROUGHS. 2006. Nonalcoholic fatty liver disease. *American Family Physician* 73: 1961–1968.
- BEUERS, U., AND C. RUST. 2005. Overlap syndromes. *Seminars in Liver Disease* 25: 311–320.
- BISHOP, L., J. D. STRANDBERG, R. J. ADAMS, D. G. BROWNSTEIN, AND R. PATTERSON. 1979. Chronic active hepatitis in dogs associated with leptospires. *American Journal of Veterinary Research* 40: 839–844.
- BONDESSON, J. D., AND A. R. SAPERSTON. 1996. Hepatitis. *Emergency Medicine Clinics of North America* 14: 695–718.
- BOOMKENS, S. Y., L. C. PENNING, H. F. EBGERINK, T. S. VAN DEN INGH, AND J. ROTHUIZEN. 2004. Hepatitis with special reference to dogs. A review on the pathogenesis and infectious etiologies, including unpublished results of recent own studies. *Veterinary Quarterly* 26: 107–114.
- BOSSART, G. D. 1984. Suspected acquired immunodeficiency in an Atlantic bottlenosed dolphin with chronic-active hepatitis and lobomycosis. *Journal of the American Veterinary Medical Association* 185: 1413–1414.
- , T. A. BRAWNER, C. CABAL, M. KUHN, E. A. EIMSTAD, J. CARON, M. TRIMM, AND P. BRADLEY. 1990. Hepatitis B-like infection in a Pacific white-sided dolphin (*Lagenorhynchus obliquidens*). *Journal of the American Veterinary Medical Association* 196: 127–130.
- BUGIANESI, E., G. MARCHESINI, E. GENTILCORE, I. H. CUA, E. VANNI, M. RIZZETTO, AND J. GEORGE. 2006. Fibrosis in genotype 3 chronic hepatitis C and nonalcoholic fatty liver disease: Role of insulin resistance and hepatic steatosis. *Hepatology* 44: 1648–1655.
- CASTRO-E-SILVA JUNIOR, O., C. F. FRANCO, M. E. SOUZA, M. A. PICINATO, J. S. SANTOS, AND R. CENEVIVA. 1990. Serum gamma-glutamyl transpeptidase in chronic extrahepatic cholestasis. *Brazilian Journal of Medical Biological Research* 23: 515–518.
- CLAVAREAU, C., V. WELLEMANS, K. WALRAVENS, M. TRYLAND, J. M. VERGER, M. GRAYON, A. CLOECKAERT, J. J. LETESSON, AND J. GODFROID. 1998. Phenotypic and molecular characterization of a *Brucella* strain isolated from a minke whale (*Balaenoptera acutorostrata*). *Microbiology* 144: 3267–3273.
- CZAJA, A. J. 1999. Autoimmune liver disease. *Current Opinions in Gastroenterology* 15: 240–248.
- DAILEY, M., AND R. STROUD. 1978. Parasites and associated pathology observed in cetaceans stranded along the Oregon coast. *Journal of Wildlife Diseases* 14: 503–511.
- DAVIES, M. C., M. E. ENGLERT, M. R. STEBBINS, AND V. J. CABASSO. 1961. Electron microscopic structure of infectious canine hepatitis (ICH) virus—A canine adenovirus. *Virology* 15: 87–88.
- DI GUARDO, G., U. AGRIMI, L. MORELLI, G. CARDETI, G. TERRACCIANO, AND S. KENNEDY. 1995. Post mortem investigations on cetaceans found stranded on the coasts of Italy between 1990 and 1993. *Veterinary Record* 136: 439–442.
- DOTZAUER, A., S. M. FEINSTONE, AND G. KAPLAN. 1994. Susceptibility of nonprimate cell lines to hepatitis A virus infection. *Journal of Virology* 68: 6064–6068.
- D'SOUZA, R. F., R. FEAKINS, L. MEARS, C. A. SABIN, AND G. R. FOSTER. 2005. Relationship between serum ferritin, hepatic iron staining, diabetes mellitus and fibrosis progression in patients with chronic hepatitis C. *Alimentary Pharmacological Therapies* 21: 519–524.
- FUENTEALBA, C. S., S. GUEST, S. HAYWOOD, AND B. HONEY. 1997. Chronic hepatitis: A retrospective study in 34 dogs. *Canadian Veterinary Journal* 38: 365–373.
- HERNANDEZ, C., J. GENESCA, J. INGASI ESTEBAN, L. GARCIA, AND R. SIMO. 2000. Relationship between iron stores and diabetes mellitus in patients infected by hepatitis C virus: A case-control study. *Medicina Clinica* 115: 21–22.
- HO, C. H., M. C. HOU, H. C. LIN, F. Y. LEE, J. C. WU, AND S. D. LEE. 1999. Hemostatic changes in patients with liver cirrhosis. *Zhonghua Yi Xue Za Zhi (Taipei)* 62: 376–382.
- HOFFMAN, G., T. S. VAN DEN INGH, P. BODE, AND J. ROTHUIZEN. 2006. Copper-associated chronic hepatitis in Labrador retrievers. *Journal of Veterinary Internal Medicine* 20: 856–861.
- HUI, J. M., J. KENCH, G. C. FERRELL, R. LIN, D. SAMARASINGHE, C. LIDDLE, K. BYTH, AND J. GEORGE. 2002. Genotype-specific mechanisms for hepatic steatosis in chronic hepatitis C infection. *Journal of Gastroenterology Hepatology* 17: 873–881.
- HULTGREN, B. D., J. B. STEVENS, AND R. M. HARDY. 1986. Inherited, chronic, progressive hepatic degeneration in Bedlington terriers with increased liver copper concentrations: Clinical and pathologic observations and comparison

- with other copper-associated liver disease. *American Journal of Veterinary Research* 47: 365–377.
- IGA, D., M. TOMINMATSU, H. ENDO, S. OHKAWA, AND O. YAMADA. 2005. Improvement of a thrombocytopenia with disappearance of HCV RNA in patients treated by interferon-alpha therapy: Possible etiology of HCV-associated immune thrombocytopenia. *European Journal of Haematology* 75: 417–423.
- JABER, J. R., J. PEREZ, M. ARBELO, P. HERRAEZ, A. ESPINOSA DE LOS MONTEROS, F. RODRIGUEZ, T. FERNANDEZ, AND A. FERNANDEZ. 2003. Immunophenotypic characterization of hepatic inflammatory cell infiltrates in common dolphins (*Delphinus delphis*). *Journal of Comparative Pathology* 129: 226–230.
- , ———, ———, M. ANDRADA, M. HIDALGO, J. C. GOMEZ-VILLAMANDOS, T. VAN DEN INGH, AND ———. 2004. Hepatic lesions in cetaceans stranded in the Canary Islands. *Veterinary Pathology* 41: 147–153.
- JIANG, X. H., Y. T. XIE, AND D. M. TAN. 2004. Platelet associated immunoglobulin in the pathogenesis of thrombocytopenia in patients with chronic liver disease. *Zhong Nan Da Xue Xue Boa Yi Xue Ban* 29: 566–568.
- LECUBE, A., C. HERNANDEZ, J. GENESCA, J. I. ESTEBAN, L. GARCIA, AND R. SIMO. 2004. Diabetes is the main factor accounting for the high ferritin levels detected in chronic hepatitis C virus infection. *Diabetes Care* 27: 2669–2675.
- LU, S. N., J. H. WANG, S. L. LIU, C. H. HUNG, C. H. CHEN, H. D. TUNG, W. S. HUANG, C. M. LEE, C. C. CHEN, AND C. S. CHANGCHIEN. 2006. Thrombocytopenia as a surrogate for cirrhosis and a marker for the identification of patients at high-risk for hepatocellular carcinoma. *Cancer* 107: 2212–2222.
- MAZZARO, L. M., J. L. DUNN, D. J. ST. AUBIN, G. A. ANDREWS, AND P. S. CHAVEY. 2004. Serum indices of body stores of iron in northern fur seals (*Callosistrinus ursinus*) and their relationship to hemochromatosis. *Zoo Biology* 23: 205–218.
- MENNE, S., AND P. J. COTE. 2007. The woodchuck as an animal model for pathogenesis and therapy of chronic hepatitis B virus infection. *World Journal of Gastroenterology* 13: 104–124.
- METWALLY, M. A., C. O. ZEIN, AND N. N. ZEIN. 2004. Clinical significance of hepatic iron deposition and serum iron values in patients with chronic hepatitis C infection. *American Journal of Gastroenterology* 99: 286–291.
- MIFUJI, R., Y. KOBAYASHI, N. MA, Q. L. QIANG, N. URAWA, S. HORIIKE, M. IWASA, M. KAITO, F. MALAVASI, AND Y. ADACHI. 2006. Role of transferring receptor 2 in hepatic accumulation of iron in patients with chronic hepatitis C. *Journal of Gastroenterology Hepatology* 21: 144–151.
- NAGASHIMA, M., M. KUDO, H. CHUNG, E. ISHIKAWA, S. HAGIWARA, T. NAKATANI, AND K. DOTE. 2006. Regulatory failure of serum prohepcidin levels in patients with hepatitis C. *Hepatology Research* 36: 288–293.
- NEGRO, F. 2006. Mechanisms and significance of liver steatosis in hepatitis C virus infection. *World Journal of Gastroenterology* 12: 6756–6765.
- NICOLAS, G., C. CHAUVET, L. VIATTE, J. L. DANAN, X. BIGARD, I. DEVAUX, C. BEAUMONT, A. KAHN, AND S. VAULONT. 2002. The gene encoding the iron regulatory peptide hepcidin is regulated by anemia, hypoxia, and inflammation. *Journal of Clinical Investigations* 110: 1037–1044.
- NOBILI, V., M. MARCELLINI, R. DEVITO, D. COMPARCOLA, AND S. VENTO. 2006. Co-occurrence of chronic hepatitis B virus infection and autoimmune hepatitis in a young Senegalese girl. *European Journal of Gastroenterology Hepatology* 18: 927–929.
- PALEKAR, N. A., AND S. A. HARRISON. 2005. Extrahepatic manifestations of hepatitis C. *Southern Medicine Journal* 98: 1019–1023.
- PECK-RADOSAVLJEVIC, M. 2000. Thrombocytopenia in liver disease. *Canadian Journal of Gastroenterology* 14 (Suppl D): 60–66.
- PYRSOPOULOS, N. T., AND K. R. REDDY. 2001. Extrahepatic manifestations of chronic viral hepatitis. *Current Gastroenterology Report* 3: 71–78.
- RALLIS, T., M. J. DAY, M. N. SARIDOMICHELAKIS, K. K. ADAMMAN-MORAITOU, L. PAPAZOGLU, A. FYTIANOU, AND A. F. KOUTINAS. 2005. Chronic hepatitis associated with canine leishmaniasis (*Leishmania infantum*): A clinicopathological study of 26 cases. *Journal of Comparative Pathology* 132: 145–152.
- RESENDES, A. R., C. JUAN-SALLES, S. ALMERIA, N. MAJO, M. DOMINGO, AND J. P. DUBEY. 2002. Hepatic sarcocystis in a striped dolphin (*Stenella coeruleoalba*) from the Spanish Mediterranean coast. *Journal of Parasitology* 88: 206–209.
- RIDGWAY, S. H. 1972. *Mammals of the sea: Biology and medicine*. Charles C. Thomas, Springfield, Illinois, pp. 590–747.
- , J. G. SIMPSON, G. S. PATTON, AND W. G. GILMARTIN. 1970. Hematologic findings in certain small cetaceans. *Journal of the American Veterinary Medical Association* 157: 566–575.
- SANYAL, A. J., M. J. CONTOS, R. K. STERLING, V. A. LUKETIC, M. L. SHIFFMAN, R. T. STRAVITZ, AND A. S. MILLS. 2003. Nonalcoholic fatty liver disease in patients with hepatitis C is associated with features for the metabolic syndrome. *American Journal of Gastroenterology* 98: 2064–2071.
- SCHRAMM, C., AND A. W. LOHSE. 2005. Overlap syndromes of cholestatic liver diseases and autoimmune hepatitis. *Clinical Review of Allergy and Immunology* 28: 105–114.
- SEVELIUS, E. 1995. Diagnosis and prognosis of

- chronic hepatitis and cirrhosis in dogs. *Journal of Small Animal Practice* 36: 521–528.
- SOTELO, N., AND G. LOPEZ. 2005. Autoimmune-type chronic active hepatitis in children. A report of 23 cases at a hospital in northwestern Mexico. *Annals of Hepatology* 4: 255–260.
- STRASSBURG, C. P. 2006. Autoimmune liver diseases and their overlap syndromes. *Schweizerische Rundschau für Medizin Praxis* 95: 1363–1381.
- TANAKA, H., H. TUJIOKA, H. UEDA, H. HAMAGAMI, Y. KIDA, AND M. ICHINOSE. 2005. Autoimmune hepatitis triggered by acute hepatitis A. *World Journal of Gastroenterology* 11: 6069–6071.
- THIELE, D. L. 2005. Autoimmune hepatitis. *Clinical Liver Diseases* 9: 635–646.
- TROTTER, J. F. 2006. Coagulation abnormalities in patients who have liver disease. *Clinical Liver Disease* 10: 665–678.
- VENN-WATSON, S., AND S. H. RIDGWAY. 2007. Big brains and blood glucose: Common ground for diabetes mellitus in humans and dolphins. *Comparative Medicine* 57: 390–395.
- , E. D. JENSEN, AND S. H. RIDGWAY. 2007. Effects of age and sex on clinicopathologic ranges in a healthy managed Atlantic bottlenose dolphin population. *Journal of the American Veterinary Medical Association*. 231: 596–601.
- WEBB, C. B., D. C. TWEDT, AND D. J. MEYER. 2002. Copper-associated liver disease in dalmatians: A review of 10 dogs (1998–2001). *Journal of Veterinary Internal Medicine* 16: 665–668.
- WREDE, C. E., R. BUETTNER, L. C. BOLLHEIMER, J. SCHOLMERICH, K. D. PALITZSCH, AND C. HELLERBRAND. 2006. Association between serum ferritin and the insulin resistance syndrome in a representative population. *European Journal of Endocrinology* 154: 333–340.
- WU, C. H., X. Y. XU, G. S. TIAN, AND Y. Y. YU. 2006. Serum autoantibodies of patients with chronic hepatitis C and the significance thereof in infection of hepatitis C virus. *Zhonghua Yi Xue Za Zhi* 86: 390–393.

Received for publication 14 December 2006.