



**THE PATHOGENESIS OF CLADE 2.3.4.4 H5 HIGHLY PATHOGENIC AVIAN INFLUENZA VIRUSES IN RUDDY DUCK (*OXYURA JAMAICENSIS*) AND LESSER SCAUP (*AYTHYA AFFINIS*)**

Authors: Spackman, Erica, Prosser, Diann J., Pantin-Jackwood, Mary J., Berlin, Alicia M., and Stephens, Christopher B.

Source: Journal of Wildlife Diseases, 53(4) : 832-842

Published By: Wildlife Disease Association

URL: <https://doi.org/10.7589/2017-01-003>

---

BioOne Complete ([complete.BioOne.org](https://complete.BioOne.org)) is a full-text database of 200 subscribed and open-access titles in the biological, ecological, and environmental sciences published by nonprofit societies, associations, museums, institutions, and presses.

Your use of this PDF, the BioOne Complete website, and all posted and associated content indicates your acceptance of BioOne's Terms of Use, available at [www.bioone.org/terms-of-use](https://www.bioone.org/terms-of-use).

Usage of BioOne Complete content is strictly limited to personal, educational, and non - commercial use. Commercial inquiries or rights and permissions requests should be directed to the individual publisher as copyright holder.

---

BioOne sees sustainable scholarly publishing as an inherently collaborative enterprise connecting authors, nonprofit publishers, academic institutions, research libraries, and research funders in the common goal of maximizing access to critical research.

# THE PATHOGENESIS OF CLADE 2.3.4.4 H5 HIGHLY PATHOGENIC AVIAN INFLUENZA VIRUSES IN RUDDY DUCK (*OXYURA JAMAICENSIS*) AND LESSER SCAUP (*AYTHYA AFFINIS*)

Erica Spackman,<sup>1,4</sup> Diann J. Prosser,<sup>2</sup> Mary J. Pantin-Jackwood,<sup>1</sup> Alicia M. Berlin,<sup>3</sup> and Christopher B. Stephens<sup>1</sup>

<sup>1</sup> Southeast Poultry Research Laboratory, US National Poultry Research Center, US Department of Agriculture-Agricultural Research Service, 934 College Station Road, Athens, Georgia 30605, USA

<sup>2</sup> Patuxent Wildlife Research Center, US Geological Survey, Beltsville Lab, 10300 Baltimore Avenue, Beltsville, Maryland 20705, USA

<sup>3</sup> Patuxent Wildlife Research Center, US Geological Survey, 12100 Beech Forest Road, Laurel, Maryland 20708, USA

<sup>4</sup> Corresponding author (email: erica.spackman@ars.usda.gov)

**ABSTRACT:** Waterfowl are the natural hosts of avian influenza virus (AIV) and disseminate the virus worldwide through migration. Historically, surveillance and research efforts for AIV in waterfowl have focused on dabbling ducks. The role of diving ducks in AIV ecology has not been well characterized. In this study, we examined the relative susceptibility and pathogenicity of clade 2.3.4.4 H5 highly pathogenic AIV (HPAIV) in two species of diving ducks. Juvenile and adult Ruddy Duck (*Oxyura jamaicensis*) and juvenile Lesser Scaup (*Aythya affinis*) were intranasally inoculated with A/Northern Pintail/WA/40964/2014 H5N2 HPAIV. Additional groups of juvenile Lesser Scaups were inoculated with A/Gyrfalcon/WA/41088/2014 H5N8 HPAIV. The approximate 50% bird infectious doses (BID<sub>50</sub>) of the H5N2 isolate for adult Ruddy Ducks was <math>10^2</math> 50% egg infectious doses (EID<sub>50</sub>) and for the juvenile Lesser Scaups it was <math>10^4</math> EID<sub>50</sub>. There were insufficient juvenile Ruddy Ducks to calculate the BID<sub>50</sub>. The BID<sub>50</sub> for the juvenile Lesser Scaups inoculated with the H5N8 isolate was 10<sup>3</sup> EID<sub>50</sub>. Clinical disease was not observed in any group; however, mortality occurred in the juvenile Ruddy Ducks inoculated with the H5N2 virus (three of five ducks), and staining for AIV antigen was observed in numerous tissues from these ducks. One adult Ruddy Duck also died and although it was infected with AIV (the duck was positive for virus shedding and AIV antigen was detected in tissues), it was also infected with coccidiosis. The proportion of ducks shedding virus was related to the dose administered, but the titers were similar among dose groups. The group with the fewest ducks shedding virus was the adult Ruddy Ducks. There was a trend for the Lesser Scaups to shed higher titers of virus than the Ruddy Ducks. No virus shedding was detected after 7 d postinoculation in any group. Similar to dabbling ducks, Lesser Scaups and Ruddy Ducks are susceptible to infection with this H5 HPAIV lineage, although they excrete lower titers of virus.

**Key words:** Disease, diving duck, H5N8, H5N2, highly pathogenic avian influenza, Lesser Scaup, Ruddy Duck.

## INTRODUCTION

The natural hosts for avian influenza virus (AIV) are aquatic birds, including waterfowl, shorebirds, and gulls (Swayne et al. 2013). Most AIV surveillance and research efforts have focused on dabbling ducks (Anatidae subfamily Anatinae), a proven reservoir for AIV (Stallknecht and Brown 2008). High species abundance, accessible habitats, targeting by hunters, and readily available commercial stocks have directed surveillance and research toward dabbling ducks.

However, ducks (family Anatidae) represent a group of animals with very diverse

habitats and biology. Diving ducks (subfamilies Aythyinae, Oxyurinae, and Merginae) of different species can be found in freshwater, brackish, and marine habitats. Two species of diving ducks that prefer freshwater or brackish habitats are Ruddy Duck (*Oxyura jamaicensis*; Baldassarre 2014a) and Lesser Scaup (*Aythya affinis*; Baldassarre 2014b). Both of these species have North American distributions and migratory patterns that are similar to many dabbling ducks, facilitating interactions with dabbling ducks known to be AIV reservoirs (Baldassarre 2014a, b).

Given this niche overlap between species, the importance of diving ducks on AIV

ecology warrants further research. In addition, recovery of a few AIV isolates from limited surveillance in Ruddy Ducks and Lesser Scaups suggests that these species are susceptible to infection with some AIV lineages (Bahl et al. 2013; National Center for Biotechnology Information 2016). However, the pathogenesis, relative susceptibility (i.e., 50% bird infectious dose [ $BID_{50}$ ]), levels of virus shed, and duration of AIV infection of Ruddy Ducks and Lesser Scaups are not known. Therefore, to better characterize the pathobiology of AIV in Ruddy Ducks and Lesser Scaups, we experimentally challenged these species with two recent highly pathogenic AIV (HPAIV) isolates from the US: A/Northern Pintail/WA/40964/2014 H5N2 (NOPI/14) and A/Gyr Falcon/WA/41088/2014 H5N8 (GYRF/14). These isolates were selected for several reasons: 1) they are the US index isolates for the most extensive HPAIV outbreak in US history, which cost an estimated \$3.3 billion in direct and indirect costs (US Senate Committee on Agriculture, Nutrition and Forestry 2015; Dargatz et al. 2016); 2) it is unknown whether they will persist in North American wild birds, which increases the risk for another introduction into poultry; and 3) they have been extensively characterized in numerous avian species, so their use will provide for comparison among these species (DeJesus et al. 2016; Spackman et al. 2016).

## MATERIALS AND METHODS

Adult Ruddy Ducks and hatching eggs for Ruddy Ducks and Lesser Scaups were obtained from US Geological Survey captive breeding colonies at Patuxent Wildlife Research Center (PWRC). Ducks were hatched at Southeast Poultry Research Laboratory, US National Poultry Research Center, US Department of Agriculture-Agricultural Research Service (USNPRC), and they were reared until they were 4–8 wk old. Two age groups were evaluated: juveniles (Ruddy Ducks and Lesser Scaups) 4–8 wk old and adults (Ruddy Ducks) 3–4 yr old. An age range of 4–8 wk for the juveniles had to be used because the colonies mate naturally, so the hatch was spread throughout the breeding season. There were seven male and seven female adult Ruddy Ducks,

and the sex was not determined for the juvenile ducks. Each bird was individually tagged and had ad libitum access to feed (Mazuri® Seaduck Diet, Land O'Lakes, Arden Hills, Minnesota, USA) and water. All procedures involving animals and husbandry for these experiments were approved by the USNPRC and PWRC institutional animal care and use committees.

The NOPI/14 and GYRF/14 viruses were obtained from the National Veterinary Services Laboratories, US Department of Agriculture-Animal and Plant Health Inspection Service. The viruses were propagated in embryonated chicken eggs according to standard procedures (Spackman and Stephens 2016). Dilutions were prepared in brain heart infusion broth, and the titer in embryonated chicken eggs was determined by the Reed-Muench method (Reed and Muench 1938). The Ruddy Ducks were challenged with NOPI/14 (egg pass 2) HPAIV. There were sufficient Lesser Scaups to conduct two challenge studies: one study with NOPI/14 (egg pass 2) and one study with GYRF/14 HPAIV (egg pass 2).

Blood was collected from each duck immediately before challenge to test for pre-existing AIV antibody. The ducks were divided into groups of four or five and were inoculated with 0.1 mL of virus by the intranasal route in varying doses (Table 1). Different doses (low,  $10^2$  EID<sub>50</sub> per bird; middle,  $10^4$  EID<sub>50</sub> per bird; and high,  $10^6$  EID<sub>50</sub> per bird) were administered to each group (Table 1). Groups were limited by the availability of the ducks, so not all species and ages could be evaluated at all doses. For the same reason, noninoculated groups were not included. The adult Ruddy Ducks were divided so that there were three males and two females in the high dose group, two males and three females in the middle dose group, and two of each sex in the low dose group.

The clinical condition of each duck was evaluated daily. Oropharyngeal (swabbing through the buccal cavity and choanal cleft) and cloacal swabs were collected 2, 4, 7, 10, and 14 d postinoculation (DPI) from each duck. Due to the small group sizes, only ducks that died were necropsied before termination of the experiment (14 DPI), at which time all surviving ducks were bled, euthanized, and necropsied to examine for gross lesions. The following tissue samples were collected for microscopic evaluation from ducks that died during the study: beak, trachea, lung, heart, spleen, adrenal glands, liver, intestine, bursa, kidney, brain, thymus, pancreas, air sacs, and thigh muscle. Tissues were fixed in 10% neutral buffered formalin solution, sectioned, and stained with H&E. Duplicate sections were stained by immunohistochemical methods (Pan-

TABLE 1. Seroconversion (14 d postinoculation), proportion of ducks shedding, and approximate 50% bird infectious dose for adult and juvenile Ruddy Ducks (*Oxyura jamaicensis*) and juvenile Lesser Scaup (*Aythya affinis*) inoculated with clade 2.3.4.4 H5 highly pathogenic avian influenza virus.

Challenge isolate	Species	Age group	Dose EID <sub>50</sub> /bird <sup>a</sup>	No. antibody positive/no. tested	No. shedding/no. tested <sup>c</sup>	No. dead/no. in group	Approximate 50% bird infectious dose <sup>d</sup>
A/Northern Pintail/WA/40964/2014 H5N2	Ruddy Duck	Juvenile	10 <sup>6</sup>	2/2	5/5	3/5	NC <sup>e</sup>
	Ruddy Duck	Adult	10 <sup>2</sup>	3/4 <sup>b</sup>	0/4	0/4	<10 <sup>2</sup> EID <sub>50</sub>
	Ruddy Duck	Adult	10 <sup>4</sup>	5/5	0/5	0/5	
	Ruddy Duck	Adult	10 <sup>6</sup>	4/4	3/5	1/5	
	Lesser Scaup	Juvenile	10 <sup>4</sup>	4/4	4/4	0/4	<10 <sup>4</sup> EID <sub>50</sub>
	Lesser Scaup	Juvenile	10 <sup>6</sup>	4/4	4/4	0/4	
A/Gyrfalcon/WA/41088/2014 H5N8	Lesser Scaup	Juvenile	10 <sup>2</sup>	0/4	0/4	0/4	10 <sup>3</sup> EID <sub>50</sub>
	Lesser Scaup	Juvenile	10 <sup>4</sup>	3/5	5/5	0/5	
	Lesser Scaup	Juvenile	10 <sup>6</sup>	5/5	5/5	0/5	

<sup>a</sup> EID<sub>50</sub> = 50% egg infectious dose.

<sup>b</sup> Number positive/total.

<sup>c</sup> Birds were counted as positive for shed if virus was detected in oral or cloacal swabs at any time.

<sup>d</sup> Birds were considered infected if they shed detectable levels of virus at any time, they seroconverted, or both.

<sup>e</sup> NC = not calculated.

tin-Jackwood 2014) to determine influenza viral antigen distribution in individual tissues.

For calculations of the BID<sub>50</sub>, birds that shed detectable levels of virus, were positive for antibody at 14 DPI, or both were considered infected. Detectable antibody levels and titers of virus shed varied among individual birds, so it was not uncommon for only one test to be positive with mild infections.

Two assays were used because performance data for serologic assays with Ruddy Ducks and Lesser Scaups are lacking. A commercial non-species-specific blocking enzyme-linked immunosorbent assay for Type A influenza (IDEXX MultiS-Screen, IDEXX Laboratories Inc., Westbrook, Maine, USA) was used to test prechallenge sera for influenza A antibody. The manufacturer's recommended sample/negative cut-off, where values of 0.5 or below were considered positive, was followed; however, no sample had a sample/negative value below 0.75. The hemagglutination inhibition (HI) assay using homologous antigen (Pedersen 2014) was used to evaluate and quantify antibody levels postchallenge. A serum dilution of 1:8 and above, which fully inhibited agglutination, was considered positive, and dilutions of 1:4 or lower were considered to be nonspecific.

Swab samples were evaluated by quantitative real-time reverse transcription-PCR. This method, which targets the influenza M gene, and RNA extraction procedures were described previously (Spackman et al. 2002; Das et al. 2009). The RNA

from the same virus stock used to prepare the inocula was used to produce the standard curve.

## RESULTS

Only five juvenile Ruddy Ducks were available; therefore, only the highest virus dose of NOPI/14 H5N2 HPAIV was evaluated. Three of the five juvenile Ruddy Ducks died, one each at 3, 5, and 6 DPI. Neither clinical signs before death nor gross lesions on necropsy were observed. Tissues for microscopic examination and viral antigen staining from the ducks that died at 3 and 5 DPI were collected. On histopathologic examination, ducks presented similar microscopic lesions to those reported for other waterfowl species (Pantin-Jackwood and Swayne 2007), including: mild-to-moderate diffuse rhinitis, sinusitis, tracheitis, and bronchitis; severe diffuse interstitial pneumonia; mild focal necrosis of cardiac myofibers; randomly scattered foci of malacia in the brain; mild focal necrosis of hepatocytes in the liver; and mild lymphoid depletion in the spleen and the bursa. Viral antigen was present in numerous organs including lung, heart, spleen, adrenal gland, liver, intestine, bursa, brain, and thymus. In

both juvenile ducks examined, viral antigen was present in epithelial cells and macrophages in the lungs, in myofibers in the heart, in resident and infiltrating phagocytes of the spleen, in hepatocytes and Kupffer cells in the liver, and in phagocytes in the bursa and thymus (Fig. 1A–D; Table 2). In one or the other juvenile ducks, viral antigen was also found in epithelial cells and macrophages in the nasal turbinates, in cortical and medullary cells of the adrenal gland, in feather epidermal cells, in intestinal epithelial cells, and in neurons and glial cells of the brain.

All five juvenile Ruddy Ducks were positive for virus, shed at either 2 or 4 DPI by the oral route, cloacal route, or both, but no individual shed for more than two consecutive sample days (Fig. 2B). The surviving juvenile Ruddy Ducks did not shed virus at 7, 10, or 14 DPI. No clinical signs were observed in the two surviving juvenile Ruddy Ducks, all of which were positive for antibody at 14 DPI (Table 1).

Adult Ruddy Ducks were inoculated with three doses of NOPI/14 H5N2 HPAIV. No clinical signs were observed in any of the ducks at any time after challenge, with the exception of one adult female Ruddy Duck from the high dose group, which was found dead at 3 DPI. At necropsy, severely hemorrhagic intestines were the only gross lesion observed. The microscopic lesions and presence of viral antigen in tissues were similar to those described for the juvenile Ruddy Ducks, but, in addition, hemorrhage and widespread necrosis of intestinal villi were present in the intestine, and numerous developmental stages of an unknown coccidian species were found in intestinal crypt and villi epithelial cells. Also, moderate diffuse airsacculitis, severe multifocal necrotizing pancreatitis, mild focal tubular necrosis in kidneys, and severe diffuse necrosis of hepatocytes in the liver were present. In addition to that observed in the juvenile Ruddy Ducks, viral antigen was also present in the trachea, air sacs, pancreatic acinar cells, and tubular epithelial cells in the kidneys of the adult Ruddy Ducks (Table 2). Staining for viral antigen in the intestine was not widespread; the necrosis and hemorrhage

observed was most likely caused by the coccidian. No other adult Ruddy Ducks had gross lesions when necropsied at the termination of the experiment (14 DPI).

Virus shedding was not detected in swabs from any adult Ruddy Ducks in the lowest two dose groups of NOPI/14 H5N2 HPAIV ( $10^2$  and  $10^4$  EID<sub>50</sub> per bird; Table 1). In contrast, three of five adult Ruddy Ducks in the highest dose group ( $10^6$  EID<sub>50</sub> per bird) shed detectable levels of virus at 2, 4, or 7 DPI by the oral route, cloacal route, or both, but no individual shed for more than two consecutive sample days (Fig. 2A). No virus was detected in swabs at 10 and 14 DPI. The highest titers were detected at 2 DPI from the adult Ruddy Ducks that died (Fig. 2A). At termination, 75, 100, and 100% of ducks in the  $10^2$ ,  $10^4$ , and  $10^6$  EID<sub>50</sub> per bird dosage groups, respectively, were antibody positive by HI assay (Table 1). Based on serology and detection of virus shedding, the BID<sub>50</sub> was  $<10^2$  EID<sub>50</sub>.

Juvenile Lesser Scaups were challenged with the two highest doses ( $10^4$  and  $10^6$  EID<sub>50</sub> per bird) of NOPI/14 H5N2 HPAIV. No Lesser Scaups died and no clinical signs were observed. No gross lesions were observed at necropsy at the termination of the experiment (tissues were not collected for examination of microscopic lesions). All eight juvenile Lesser Scaups shed detectable levels of virus by the oral route, cloacal route, or both at 2, 4, and/or 7 DPI; no individual shed for more than two consecutive sample days (Fig. 2C), but no virus was detected at 10 or 14 DPI. All eight juvenile Lesser Scaups were positive for antibody by HI assay at 14 DPI. Because an endpoint was not reached, the BID<sub>50</sub> was  $<10^4$  EID<sub>50</sub> (Table 1).

No clinical signs or mortality were observed in juvenile Lesser Scaups inoculated with GYRF/14 H5N8 HPAIV. No gross lesions were observed when the juvenile Lesser Scaups were euthanized and necropsied at 14 DPI (tissues not collected for microscopic examination). All juvenile Lesser Scaups in the middle and high dose groups shed virus at some time between 2 and 7 DPI orally (no individual shed for more than two consecutive

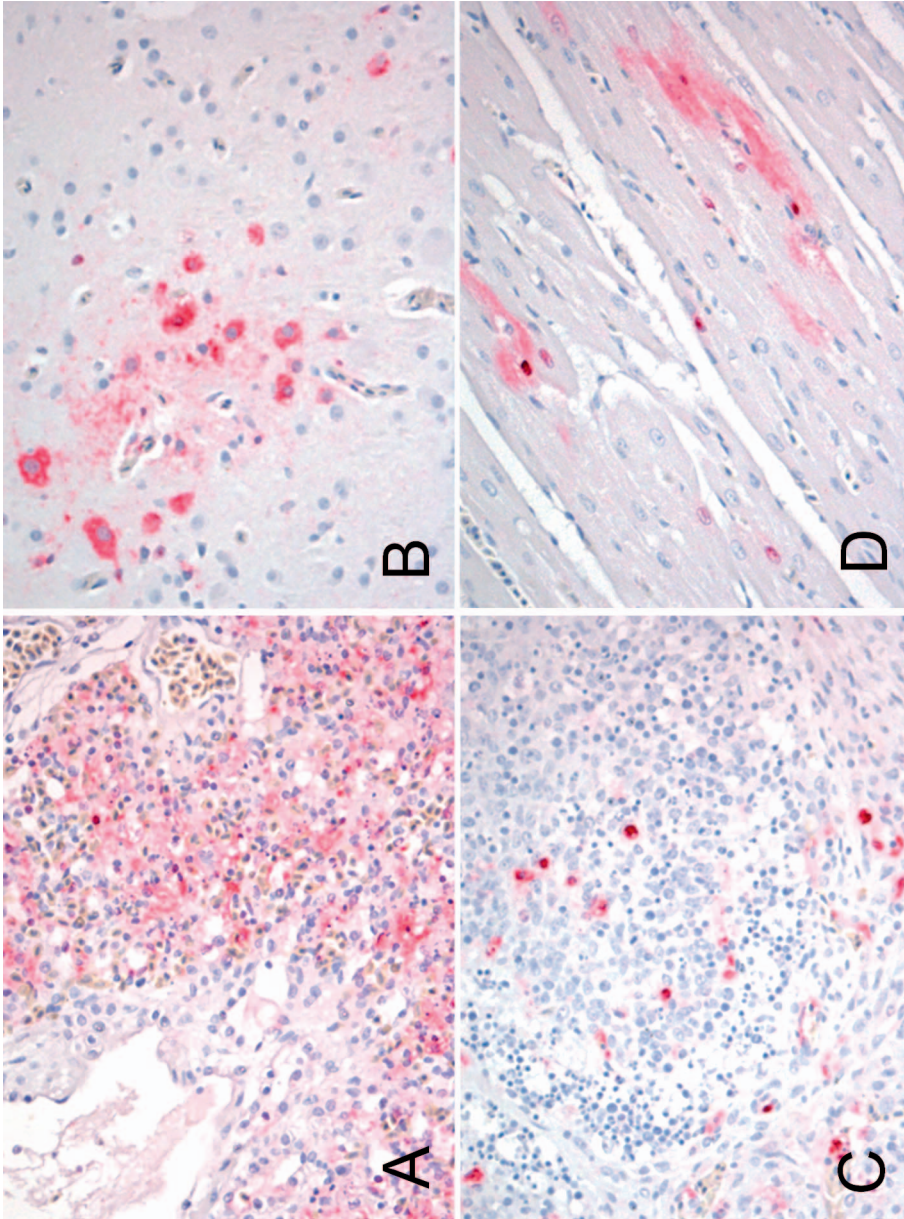


FIGURE 1. Immunohistochemical staining for avian influenza virus in tissues from juvenile Ruddy Ducks (*Oxyura jamaicensis*) that died after inoculation with A/Northern Pintail/WVA/40964/2014 H5N2 highly pathogenic avian influenza virus. Virus antigen appears as red staining. Magnification, 40X. (A) Lung. (B) Brain. (C) Bursa. (D) Heart. Viral antigen was present in alveolar epithelial cells and macrophages in the lung, in neurons and glial cells of the brain, in phagocytes in the bursa, and in cardiac myofibers.

TABLE 2. Distribution of avian influenza virus antigen visualized by immunohistochemical staining in tissues from Ruddy Ducks (*Oxyura jamaicensis*) inoculated with A/Northern Pintail/WA/40964/2014 H5N2 highly pathogenic avian influenza virus.

Duck	Detection of avian influenza virus antigen in tissues <sup>a</sup>															
	Nasal	Trachea	Lung	Heart	Spleen	Adrenal	Liver	Intestine	Bursa	Kidney	Brain	Feather follicles	Thymus	Pancreas	Air sacs	Muscle
577 (juvenile)	-	-	+++	+	+++	NA	++	+	+++	-	-	+	+	-	NA	-
574 (juvenile)	++	-	+++	++	++	+	+	-	+	-	++	-	+	-	NA	-
233 (adult)	++	+	+++	+	+++	NA	+++	++	NA	+++	+	+	NA	+++	+++	-

<sup>a</sup> - = no positive cells; + = single positive cells; ++ = scattered groups of positive cells; +++ = widespread positivity; NA = not available.

sample days) and three of five juvenile Lesser Scaups in both groups shed detectable levels of virus by the cloaca at least once (Fig. 2D). No virus was detected being shed from any juvenile Lesser Scaups at 10 and 14 DPI. Based on seroconversion and virus shedding, the BID<sub>50</sub> was 10<sup>3</sup> EID<sub>50</sub> (Table 1).

DISCUSSION

The two isolates that were used are the index isolates of the most widespread variants of the H5 clade 2.3.4.4 HPAIVs in the US. The GYRF/14 H5N8 is genetically a wholly Eurasian virus, and NOPI/14 H5N2 is a reassortant of the Eurasian H5N8 virus and North American AIV strains (Lee et al. 2016). In the US and Canada, infections with the H5N2 isolate were much more widespread in poultry than infections with the H5N8 isolate (Pasick et al. 2015; US Department of Agriculture 2017). However, the H5N8 has a wider geographic distribution; in 2014–15 it was isolated numerous times in Europe and Asia, and in late 2016–early 2017 it has caused infections in domestic and wild birds throughout Europe, Asia, and northern Africa. Because of their relevance in these outbreaks, these isolates have also been extensively characterized in wild birds and numerous domestic avian species (DeJesus et al. 2016; Pantin-Jackwood et al. 2016), which provides data for comparison among species.

Avian influenza surveillance and research in waterfowl have primarily focused on dabbling ducks, mainly because of the relative logistical ease of sample collection and because they are a proven reservoir. In contrast, the role of diving ducks in the ecology of AIV is largely unknown, although diving ducks have been implicated in the ecology of the 2016 H7N8 AIV that infected turkeys in Indiana (Xu et al. 2017). There are limited reports on AIV surveillance in diving ducks, and they have focused on seaducks (Germundsson et al. 2010; Liu et al. 2011; Hall et al. 2015). Experimental studies with diving ducks are very limited because of the difficulty in obtaining these species. One challenge study

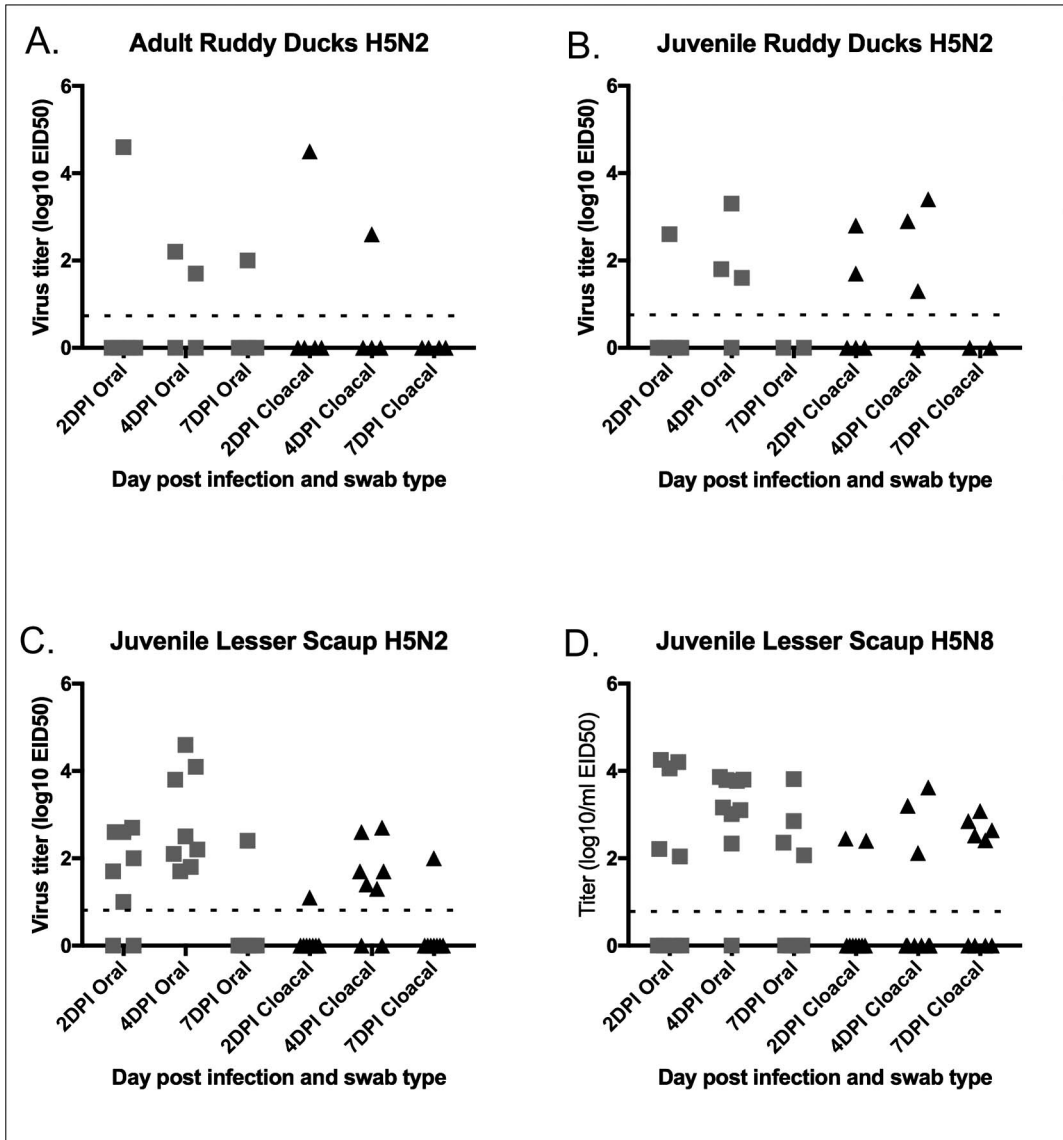


FIGURE 2. Titers of virus shed by ducks inoculated with clade 2.3.4.4 H5 highly pathogenic avian influenza virus at 2, 4, and 7 d postinoculation (data for days postinoculation 10 and 14 are not shown, as all samples were negative): (A) adult Ruddy Ducks (*Oxyura jamaicensis*) exposed to  $10^6$  50% egg infectious doses per bird (EID<sub>50</sub> per bird) of A/Northern Pintail/WA/40964/2014 H5N2 (only the highest dose group is shown as lower doses did not shed detectable levels of virus;  $n=5$ ); (B) juvenile Ruddy Ducks exposed to  $10^6$  EID<sub>50</sub> per bird of A/Northern Pintail/WA/40964/2014 H5N2 ( $n=5$ ); (C) juvenile Lesser Scaup (*Aythya affinis*) exposed to  $10^4$  EID<sub>50</sub> per bird ( $n=4$ ) or  $10^6$  EID<sub>50</sub> per bird of A/Northern Pintail/WA/40964/2014 H5N2 bird ( $n=4$ ); (D) juvenile Lesser Scaup exposed to  $10^4$  EID<sub>50</sub> per bird ( $n=5$ ) or  $10^6$  EID<sub>50</sub> per bird of A/Gyr Falcon/WA/41088/2014 H5N8 (the lowest dose group is not shown, because all ducks were negative for detectable virus shedding;  $n=5$ ). The limit of the real-time reverse transcription-PCR detection test is denoted with a dashed horizontal line. Gray squares indicate oral swabs; black triangles indicate cloacal swabs.



with low pathogenicity AIV (LPAIV) in Common Eiders (*Somateria mollissima*) revealed similar results to the Lesser Scaups inoculated with HPAIV (i.e., susceptibility to infection with no mortality or clinical disease; Hall et al. 2015). One difference between the results of the studies is that there was mortality in the juvenile Ruddy Ducks, which could have been due to differences in species or to pathotype combination. Finally, two studies have evaluated A/goose/Guangdong/1996 lineage H5N1 HPAIV isolates in *Aythya* species. One study with Redhead Ducks (*Aythya americana*) produced results similar to those we observed in the Lesser Scaups, where 100% infection was achieved in three ducks at a dose of  $10^6$  EID<sub>50</sub> per bird, but no clinical disease was observed (Brown et al. 2006). In the second study, the pathology and tissue distribution were characterized in wild Tufted Ducks (*Aythya fuligula*), which had been naturally infected (Bröjer et al. 2009). Clinical disease presentation was variable, but because this was natural infection of wild ducks, the prior disease status was unknown and sampling was biased to sick and dead birds. However, it shows that the H5N1 HPAIV could cause disease and death in Tufted Ducks (Bröjer et al. 2009).

Similar to dabbling ducks, the adult Ruddy Ducks and juvenile Lesser Scaups were susceptible to HPAIV infection, although overt disease was absent. The infectious doses were similar to those used for Mallards (*Anas platyrhynchos*; Pantin-Jackwood et al. 2016) and were lower than those reported for gallinaceous birds (Bertran et al. 2016; Spackman et al. 2016). The groups were too small for statistical analysis, but there was a trend for the Lesser Scaups to shed higher titers and for a higher proportion of birds to shed virus compared to the Ruddy Ducks. The duration of shed was 7 d, which is shorter than the 11 d (GYRF/14) and 14 d (NOPI/14) that has been reported for Mallards with these same viruses (Pantin-Jackwood et al. 2016). Shorter shed duration and lower titers would suggest that Ruddy Ducks and Lesser Scaups are less likely to efficiently transmit the viruses than Mallards.

Juvenile and adult Ruddy Ducks inoculated with the high dose of H5N2 virus had different mortality rates, indicating age differences in susceptibility to disease. Age-associated differences in clinical outcome with HPAIV infection have been reported before with Pekin Ducks (Pantin-Jackwood et al. 2007). Although one adult Ruddy Duck died, most likely HPAIV was not the sole cause but rather the HPAIV infection acted synergistically with the coccidial infection. In contrast, the mortality in juvenile Ruddy Ducks is likely specifically due to HPAIV exposure; these ducks were hatched and reared in isolation in our facilities. A lack of clinical signs before death is not uncommon with HPAIV in avian species as the clinical period, characterized by severe lethargy, can be very short. Viral antigen was observed in multiple organs of the Ruddy Ducks that died, demonstrating that the infection was systemic.

The adult Ruddy Ducks were reared with some limited access outdoors, so exposure to other infectious agents was possible and prior exposure to AIV could not be ruled out; however, the adult Ruddy Ducks were serologically negative to both type A influenza by ELISA and the challenge virus by HI assay at the time of challenge. The adult Ruddy Ducks were held in biosecurity level 2 facilities for nearly 6 wk before challenge, so the chance of infection immediately before challenge is negligible. In the case of a distant prior AIV infection (long enough ago that antibody was below the level of detection), it is possible that remaining cellular immunity mitigated the clinical severity of infection.

Although wild waterfowl can disseminate HPAIV, they typically carry LPAIV. The designation of low pathogenicity and HP is based on virulence in gallinaceous birds (World Organization for Animal Health 2016). Wild birds (species unknown) have been implicated in the introduction of H5 HPAIV into North America in 2014 (Ip et al. 2015; Bevins et al. 2016). With the exception of some isolates of H5N1 HPAIV of the goose/Guangdong/1996 lineage, typically neither LPAIV nor HPAIV cause clinical disease in dabbling ducks (Kishida et al. 2005; Pantin-

Jackwood et al. 2016). Because the recent H5 HPAIVs in North America are of the goose/Guangdong/1996 lineage (clade 2.3.4.4; Ip et al. 2015; Lee et al. 2016), there is greater potential for these HPAIVs to cause disease in ducks. Clinical outcome of infection has a crucial role in how a species can maintain and disseminate the virus; hosts that shed high titers of virus are more likely to spread the virus than are hosts that shed lower titers of virus. Whether the H5 clade 2.3.4.4 HPAIVs can be maintained in North American wild birds is unknown. This HPAIV lineage has been eradicated from poultry in North America since June 2015, and there have been only two detections of the H5N2 HPAIV since, both of which were from wild Mallards in August 2016 and December 2016 (US Department of Agriculture 2017). Currently (October 2016–January 2017), there are numerous reports of the clade 2.3.4.4 H5N8 detection in wild birds in Europe and Asia, indicating that the H5N8 lineage may be maintained in wild birds. Tufted Ducks, among other species, have been greatly affected by this event in Europe and have been found dead in large numbers (World Organization for Animal Health 2017). Tufted Ducks and Lesser Scaups are members of the same genus, but the reason for the drastic difference in outcome of infection with closely related H5N8 viruses between the two species is unknown, and numerous host and virus factors may be involved.

Both Ruddy Ducks and Lesser Scaups are susceptible to infection with the clade 2.3.4.4 H5 HPAIVs. A lack of clinical disease in the Lesser Scaups and adult Ruddy Ducks suggests that they could serve as reservoirs of the virus. However, the relatively low titers being shed and duration of virus being shed indicates that they would not be the most efficient species for maintaining and disseminating the virus. The death of one adult Ruddy Duck with a naturally acquired coccidiosis infection demonstrates how multiple factors may be involved in viral pathogenesis in the field that are difficult to account for in a laboratory setting. In the wild, HPAIV infection may have a greater impact on bird health.

Finally, the outcome of AIV infection is influenced by both the host species and the characteristics of the AIV isolate; therefore, these results should not be extrapolated to all lineages of AIV.

## ACKNOWLEDGMENTS

The authors gratefully acknowledge Scott Lee, Diane Smith, Suzanne DeBlois, Keith Crawford, Gerald Damron, Ho Sung Lee, Paul Marban, and Roger Brock for technical assistance with this work. This research was supported by US Department of Agriculture, Agricultural Research Service Current Research Information System project 6612-32000-063-00D; US Geological Survey Ecosystems Mission Area; and the National Institute of Allergy and Infectious Diseases, National Institutes of Health, under interagency agreement AAI12004-001-00001. Its contents are solely the responsibility of the authors and do not necessarily represent the official views of the National Institutes of Health. Mention of trade names or commercial products in this manuscript is solely for the purpose of providing specific information and does not imply recommendation or endorsement by the US Government. The US Department of Agriculture is an equal opportunity provider and employer.

## LITERATURE CITED

- Bahl J, Krauss S, Kühnert D, Fourment M, Raven G, Pryor SP, Niles LJ, Danner A, Walker D, Mendenhall H, et al. 2013. Influenza A virus migration and persistence in North American wild birds. *PLoS Pathog* 9:e1003570.
- Baldassarre G. 2014a. Ruddy Ducks. In: *Ducks, geese and swans of North America*, Vol 2. Johns Hopkins University Press, Baltimore, Maryland, pp. 990–1013.
- Baldassarre G. 2014b. Lesser Scaup. In: *Ducks, geese and swans of North America*, Vol 2. Johns Hopkins University Press, Baltimore, Maryland, pp. 666–695.
- Bertran K, Swayne DE, Pantin-Jackwood MJ, Kapczynski DR, Spackman E, Suarez DL. 2016. Lack of chicken adaptation of newly emergent Eurasian H5N8 and reassortant H5N2 high pathogenicity avian influenza viruses in the U.S. is consistent with restricted poultry outbreaks in the Pacific flyway during 2014–2015. *Virology* 494:190–197.
- Bevins SN, Dusek RJ, White CL, Gidlewski T, Bodenstern B, Mansfield KG, DeBruyn P, Kraege D, Rowan E, Gillin C, et al. 2016. Widespread detection of highly pathogenic H5 influenza viruses in wild birds from the Pacific Flyway of the United States. *Sci Rep* 6: 28980.
- Bröjer C, Ågren EO, Uhlhorn H, Bernodt K, Mörner T, Jansson DS, Mattsson R, Zohari S, Thoren P, Berg

- M, et al. 2009. Pathology of natural highly pathogenic avian influenza H5N1 infection in wild tufted ducks (*Aythya fuligula*). *J Vet Diagn Invest* 21:579–587.
- Brown JD, Stallknecht DE, Beck JR, Suarez DL, Swayne DE. 2006. Susceptibility of North American ducks and gulls to H5N1 highly pathogenic avian influenza viruses. *Emerg Infect Dis* 12:1663–1670.
- Dargatz D, Beam A, Wainwright S, McCluskey B. 2016. Case series of turkey farms from the H5N2 highly pathogenic avian influenza outbreak in the United States during 2015. *Avian Dis* 60:467–472.
- Das A, Spackman E, Pantin-Jackwood MJ, Suarez DL. 2009. Removal of real-time reverse transcription polymerase chain reaction (RT-PCR) inhibitors associated with cloacal swab samples and tissues for improved diagnosis of avian influenza virus by RT-PCR. *J Vet Diagn Invest* 21:771–778.
- DeJesus E, Costa-Hurtado M, Smith D, Lee DH, Spackman E, Kapczynski DR, Torchetti MK, Killian M, Suarez DL, Swayne DE, et al. 2016. Changes in adaptation of H5N2 highly pathogenic avian influenza H5 clade 2.3.4.4 viruses in chickens and mallards. *Virology* 499:52–64.
- Germundsson A, Madslie KI, Hjortaa MJ, Handeland K, Jonassen CM. 2010. Prevalence and subtypes of influenza A viruses in wild waterfowl in Norway 2006–2007. *Acta Vet Scand* 52:28.
- Hall JS, Russell RE, Franson JC, Soos C, Dusek RJ, Allen RB, Nashold SW, TeSlaa JL, Jónsson JE, Ballard JR, et al. 2015. Avian influenza ecology in North Atlantic sea ducks: not all ducks are created equal. *PLoS One* 10:e0144524.
- Ip H, Torchetti MK, Crespo R, Kohrs P, DeBruyn P, Mansfield KG, Baszler T, Badcoe L, Bodenstern B, Shearn-Bochsler V, et al. 2015. Novel Eurasian highly pathogenic avian influenza A H5 viruses in wild birds, Washington, USA, 2014. *Emerg Infect Dis* 21:886–890.
- Kishida N, Sakoda Y, Isoda N, Matsuda K, Eto M, Sunaga Y, Umemura T, Kida H. 2005. Pathogenicity of H5 influenza viruses for ducks. *Arch Virol* 150:1383–1392.
- Lee DH, Bahl J, Torchetti MK, Killian ML, Ip HS, DeLiberto TJ, Swayne DE. 2016. Highly pathogenic avian influenza viruses and generation of novel reassortants, United States, 2014–2015. *Emerg Infect Dis* 22:1283–1285.
- Liu Y, Keller I, Heckel G. 2011. Range-wide genetic population structure of common pochard (*Aythya ferina*): a potentially important vector of highly pathogenic avian influenza viruses. *Ecol Evol* 1:529–545.
- National Center for Biotechnology Information. 2016. *Influenza virus resource*. <https://www.ncbi.nlm.nih.gov/genome/viruses/variation/flu/>. Accessed November 2016.
- Pantin-Jackwood MJ. 2014. Immunohistochemical staining of influenza virus in tissues. *Methods Mol Biol* 1161:51–58.
- Pantin-Jackwood MJ, Costa-Hurtado M, Shepherd E, DeJesus E, Smith D, Spackman E, Kapczynski DR, Suarez DL, Stallknecht DE, Swayne DE. 2016. Pathogenicity and transmission of H5 and H7 highly pathogenic avian influenza viruses in mallards. *J Virol* 90:9967–9982.
- Pantin-Jackwood MJ, Suarez DL, Spackman E, Swayne DE. 2007. Age at infection affects the pathogenicity of Asian highly pathogenic avian influenza H5N1 viruses in ducks. *Virus Res* 130:151–161.
- Pantin-Jackwood MJ, Swayne DE. 2007. Pathobiology of Asian highly pathogenic avian influenza H5N1 virus infections in ducks. *Avian Dis* 51:250–259.
- Pasick J, Berhane Y, Joseph T, Bowes V, Hisanaga T, Handel K, Alexandersen S. 2015. Reassortant highly pathogenic influenza A H5N2 virus containing gene segments related to Eurasian H5N8 in British Columbia, Canada, 2014. *Sci Rep* 5:9484.
- Pedersen JC. 2014. Hemagglutination-inhibition assay for influenza virus subtype identification and the detection and quantitation of serum antibodies to influenza virus. *Methods Mol Biol* 1161:11–25.
- Reed LJ, Muench H. 1938. A simple method for estimating fifty percent endpoints. *Am J Hyg* 27:493–497.
- Spackman E, Pantin-Jackwood MJ, Kapczynski DR, Swayne DE, Suarez DL. 2016. H5N2 highly pathogenic avian influenza viruses from the US 2014–2015 outbreak have an unusually long pre-clinical period in turkeys. *BMC Vet Res* 12:260.
- Spackman E, Senne DA, Myers TJ, Bulaga LL, Garber LP, Perdue ML, Lohman K, Daum LT, Suarez DL. 2002. Development of a real-time reverse transcriptase PCR assay for type A influenza virus and the avian H5 and H7 hemagglutinin subtypes. *J Clin Microbiol* 40:3256–3260.
- Spackman E, Stephens CB. 2016. Virus isolation and propagation in embryonated eggs. In: *A laboratory manual for the isolation, identification, and characterization of avian pathogens*, 6th Ed., Williams SM, editor. American Association of Avian Pathologists, Jacksonville, Florida, pp. 361–368.
- Stallknecht DE, Brown JD. 2008. Ecology of avian influenza in wild birds. In: *Avian influenza*, Swayne DE, editor. Blackwell, Ames, Iowa, pp. 43–58.
- Swayne DE, Suarez DL, Sims LD. 2013. Influenza. In: *Diseases of poultry*, Swayne D, editor. Blackwell, Ames, Iowa, pp. 181–218.
- US Department of Agriculture. 2017. *Avian influenza disease*. [https://www.aphis.usda.gov/aphis/ourfocus/animalhealth/animal-disease-information/avian-influenza-disease/ct\\_avian\\_influenza\\_disease](https://www.aphis.usda.gov/aphis/ourfocus/animalhealth/animal-disease-information/avian-influenza-disease/ct_avian_influenza_disease). Accessed March 2017.
- US Senate Committee on Agriculture, Nutrition and Forestry. 2015. *Testimony of Dr. Tom Elam: Full committee hearing on highly pathogenic avian influenza: the impact on the U.S. poultry sector and protecting U.S. poultry flocks*. <http://www.agriculture.senate.gov/hearings/highly-pathogenic-avian-influenza-the-impact-on-the-us-poultry-sector-and-protecting-us-poultry-flocks>. Accessed December 2016.

- World Organization for Animal Health. 2016. *Manual of diagnostic tests and vaccines for terrestrial animals: avian influenza*. <http://www.oie.int/international-standard-setting/terrestrial-manual/access-online/>. Accessed July 2016.
- World Organization for Animal Health. 2017. *Update on highly pathogenic avian influenza in animals (type H5 and H7)*. <http://www.oie.int/animal-health-in-the-world/update-on-avian-influenza/2016/>. Accessed January 2017.
- Xu Y, Ramey AM, Bowman AS, DeLiberto TJ, Killian ML, Krauss S, Nolting JM, Torchetti MK, Reeves AB, Webby RJ, et al. 2017. Low-pathogenic influenza A viruses in North American diving ducks contribute to the emergence of a novel highly pathogenic influenza A (H7N8) virus. *J Virol* 91:e02208–16.

*Submitted for publication 3 January 2017.*

*Accepted 5 April 2017.*