



Prionailurus rubiginosus (Carnivora: Felidae)

Author: Langle, Paige R.

Source: Mammalian Species, 51(986) : 155-162

Published By: American Society of Mammalogists

URL: <https://doi.org/10.1093/mspecies/sez020>

BioOne Complete (complete.BioOne.org) is a full-text database of 200 subscribed and open-access titles in the biological, ecological, and environmental sciences published by nonprofit societies, associations, museums, institutions, and presses.

Your use of this PDF, the BioOne Complete website, and all posted and associated content indicates your acceptance of BioOne's Terms of Use, available at www.bioone.org/terms-of-use.

Usage of BioOne Complete content is strictly limited to personal, educational, and non - commercial use. Commercial inquiries or rights and permissions requests should be directed to the individual publisher as copyright holder.

BioOne sees sustainable scholarly publishing as an inherently collaborative enterprise connecting authors, nonprofit publishers, academic institutions, research libraries, and research funders in the common goal of maximizing access to critical research.



Prionailurus rubiginosus (Carnivora: Felidae)

PAIGE R. LANGLE

www.mammalogy.org

Department of Collections, The Buffalo Museum of Science, 1020 Humboldt Parkway, Buffalo, NY 14211, USA; plangle@sciencebuff.org

Abstract: *Prionailurus rubiginosus* (Geoffroy Saint-Hilaire, 1831), the smallest felid at nearly one-half the size of a domestic cat, is commonly called the rusty-spotted cat. One of five species in the genus *Prionailurus*, it is found in wet or dry deciduous forests as well as scrubby grasslands throughout Sri Lanka, India, and Nepal's western Terai. Habitat loss, road accidents, and the spread of agricultural cultivation are considered major threats throughout its range. Rare in captivity and museum collections, it is considered "Near Threatened" by the International Union for Conservation of Nature and Natural Resources, with the Indian population listed under Appendix I and the Sri Lankan and Nepali populations listed with all Felidae under Appendix II of the Convention on International Trade in Endangered Species of Wild Fauna and Flora.

Key words: conservation, feline, habitat loss, India, Near Threatened, Nepal, rusty-spotted cat, Sri Lanka

Synonymy completed 1 September 2019

DOI: 10.1093/mspecies/sez020

Version of Record, first published online December 11, 2019, with fixed content and layout in compliance with Art. 8.1.3.2 ICZN.

Nomenclatural statement.—A life science identifier (LSID) number was obtained for this publication: urn:lsid:zoobank.org:pub:9E25C015-0E09-43FC-AFD4-B8F152E72A38

Prionailurus rubiginosus (Geoffroy Saint-Hilaire, 1831)

Rusty-Spotted Cat

Felis rubiginosa I. Geoffroy Saint-Hilaire, 1831:140. Type locality "bois de lataniers qui couvrent une hauteur voisine de Pondichery," [=India, wooded hills in the vicinity of Pondicherry].

Viverriceps rubiginosa: Gray, 1867:269. Name combination.

[*Prionailurus*] *rubiginosa*: Pocock, 1917:332. Name combination.

[*Prionailurus*] *rubiginosus*: Pocock, 1917:339. First use of current name combination.

CONTEXT AND CONTENT. Order Carnivora, suborder Feliformia, family Felidae, subfamily Felinae. Taxonomy of the leopard cat lineage of Asian small cats has been controversial for many decades, as evidenced by its long history of reclassification at the generic (e.g., *Felis*, *Prionailurus*, *Viverriceps*, *Ictailurus*, *Zibethailurus*, *Ailurogale*, *Ailurinus*, and *Mayailurus*) and species levels (Nowell and Jackson 1996; Kitchener et al.



Fig. 1.—An adult female *Prionailurus rubiginosus* from the Rare Species Conservation Centre, Sandwich, United Kingdom. Photograph by Balázs Buzás used with permission. Copyright (2013), available at Balázs Buzás Photographer (<http://www.balazsbuzas.com>, accessed 2 April 2013).

2017). The placement of *rubiginosus* in *Prionailurus* was considered problematic by several investigators (Sunquist and Sunquist 2002; Wozencraft 2005). However, relatively recent phylogenetic work based on both morphological and molecular

© The Author(s) 2019. Published by Oxford University Press on behalf of American Society of Mammalogists.

This is an Open Access article distributed under the terms of the Creative Commons Attribution Non-Commercial License (<http://creativecommons.org/licenses/by-nc/4.0/>), which permits non-commercial re-use, distribution, and reproduction in any medium, provided the original work is properly cited. For commercial re-use, please contact journals.permissions@oup.com

evidence suggests this classification is correct (Johnsen et al. 2006; O'Brien and Johnson 2007; Kitchener et al. 2017). Here, I have followed Kitchener et al. (2017), who recognized three subspecies of *rubiginosus*:

- P. r. koladivius* Deraniyagala, 1956:113. Type locality "Kathiraveli (E.P.)," Sri Lanka.
P. r. phillipsi Pocock, 1939:278. Type locality "Mousakanda, Gammaduwa, C. P., 3,000 ft," Sri Lanka.
P. r. rubiginosus (Geoffroy Saint-Hilaire, 1831). See above.

NOMENCLATURE NOTES. Common names for *Prionailurus rubiginosus* are rusty-spotted cat and rustie or rusty. Local names from the Indian subcontinent are spoken in Kannada or Kanarese, Waddari, and Tamil, and in these vernacular are Kiraba-bekku, Ark-philli, and Namali Pilli, listed respectively (Srinivasulu 2019). In Sri Lankan Tamil, common names include Kadu-poona, Verewa puni, and Kardup-poonai (Srinivasulu 2019). There are a number of additional common names in the Sri Lankan vernacular Sinhala, which include Kola Diviya, Balal Diviya (Miththapala 2012; Weerakoon 2012), Wal-balala, Handun Diviya, and Kula Diya (Srinivasulu 2019). The common names Ceylon rusty-spotted cat and small jungle cat specifically refer to *P. r. phillipsi* (Srinivasulu 2019). Other vernacular names include the French names chat rougeâtre, chat rubigineux, and chat-léopard de l'Inde and the Spanish or Castilian names gato rojizo and gato rubiginosa (Mukherjee et al. 2016).

DIAGNOSIS

Prionailurus rubiginosus is distinguished from *Prionailurus bengalensis*, the leopard cat, by its typically smaller size, with a total length of 500–780 mm (Sunquist and Sunquist 2002), whereas the total length of *P. bengalensis* is generally 750–925 mm. In specimens where total lengths overlap, it is advisable to compare coat patterns; overall, *P. rubiginosus* has a characteristically subdued pelage pattern in comparison to that of *P. bengalensis*, as well as a notable uniform coloring and indistinct patterning of the tail. Additionally, in *P. rubiginosus*, the solid spots are small, widely separated, often lanceolate, and arranged linearly on the dorsum, whereas the pattern of spots on the shoulders and head form clear stripes (Pocock 1939; Fig. 1). *P. rubiginosus* is distinguishable from *Prionailurus viverrinus*, the fishing cat, by comparisons of tail length in relation to head and body length and the length of the hind foot. In *P. rubiginosus*, the tail is greater than one-half the length of the head and body and more than twice as long as the hind foot, whereas in *P. viverrinus*, the tail is less than one-half the head-body length and less than two times the length of the hind foot. Additionally, *P. viverrinus* is considered the largest member of the genus *Prionailurus* (Pocock 1939). The flat-headed cat, *Prionailurus planiceps*, is easily distinguished from *P. rubiginosus* by its short tail, at 140 mm as opposed to 150–300 mm for *P. rubiginosus*; its flat or lengthened head; and its

delicate and elongated extremities (Vigors and Horsfield 1827; Sunquist and Sunquist 2002). With a range that does not extend much beyond the islands of the Sunda Shelf, the Sunda leopard cat, *Prionailurus javanensis*, does not occur sympatrically with *P. rubiginosus* (Kitchener et al. 2017).

The skulls of the five species in the genus *Prionailurus* are noticeably different. Strongly compressed nasals and greatly expanded maxillae are characteristic of *P. rubiginosus* (Fig. 2); both are useful traits to distinguish its skull from that of *P. bengalensis*, the type of *Prionailurus* (Pocock 1939). *P. bengalensis* has the most generalized skull with a mean total length of about 93 mm, and is most similar to that of *Felis*. In comparison, *P. rubiginosus* has a much smaller skull, roughly 75 mm long, with weakly developed musculature tending to superficially resemble the skull of a young *P. bengalensis* (Pocock 1939). *P. javanensis*, which was recently recognized as a separate species rather than a subspecies of *P. bengalensis* (Kitchener et al. 2017), is similarly distinguished by its larger skull, with a mean total length of 85 mm (Sicuro and Oliveira 2015). In contrast to *P. viverrinus*, *P. rubiginosus* lacks a sagittal crest, always has a narrower rostrum than the postorbital area, and only two upper premolars are present (Pocock 1939). The skull of *P. planiceps* is immediately distinguishable from that of *P. rubiginosus* by the extreme depression of the skull that extends from the anterior portion of the frontal bones along the length of the nasal bones (Vigors and Horsfield 1827).

GENERAL CHARACTERS

Prionailurus rubiginosus has short, predominately brownish gray fur with a hint of rust color (Sunquist and Sunquist 2002). This color extends from the head to the tip of the tail, and also trails down the outside of the limbs (Fig. 1). The Sri Lankan subspecies, *P. r. phillipsi*, which occurs in more tropical regions, is generally darker, richer, and warmer in hue than its dry zone counterpart, *P. r. koladivius*, and the Indian subspecies, *P. r. rubiginosus*, both of which on average have more of a grayish wash to their coats (Pocock 1939; Deraniyagala 1956; Kitchener et al. 2017). *P. r. koladivius* differs from *P. r. rubiginosus* by its generally darker, less gray head, and its dorsal spots and bands that are nearly black rather than rusty in color (Deraniyagala 1956; Kitchener et al. 2017). In all subspecies, the back and flanks have faintly colored elliptical rust spots and a white underbelly and throat with large dark spots and bars. The soles of its feet are black and the tail is substantial and thick. The tail is also markedly darker and more uniformly colored than the rest of the body, rendering the spots less distinct and more difficult to discern (Pocock 1939; Sunquist and Sunquist 2002). There are two streaks of darker fur on the cheeks of the face and four streaks of darker fur extending from above the eyes, over the forehead toward the back of the head, and down onto the shoulders (Sunquist and Sunquist 2002). The skulls of the subspecies of *P. rubiginosus* are not distinguishable from one another (Pocock 1939; Kitchener et al. 2017).

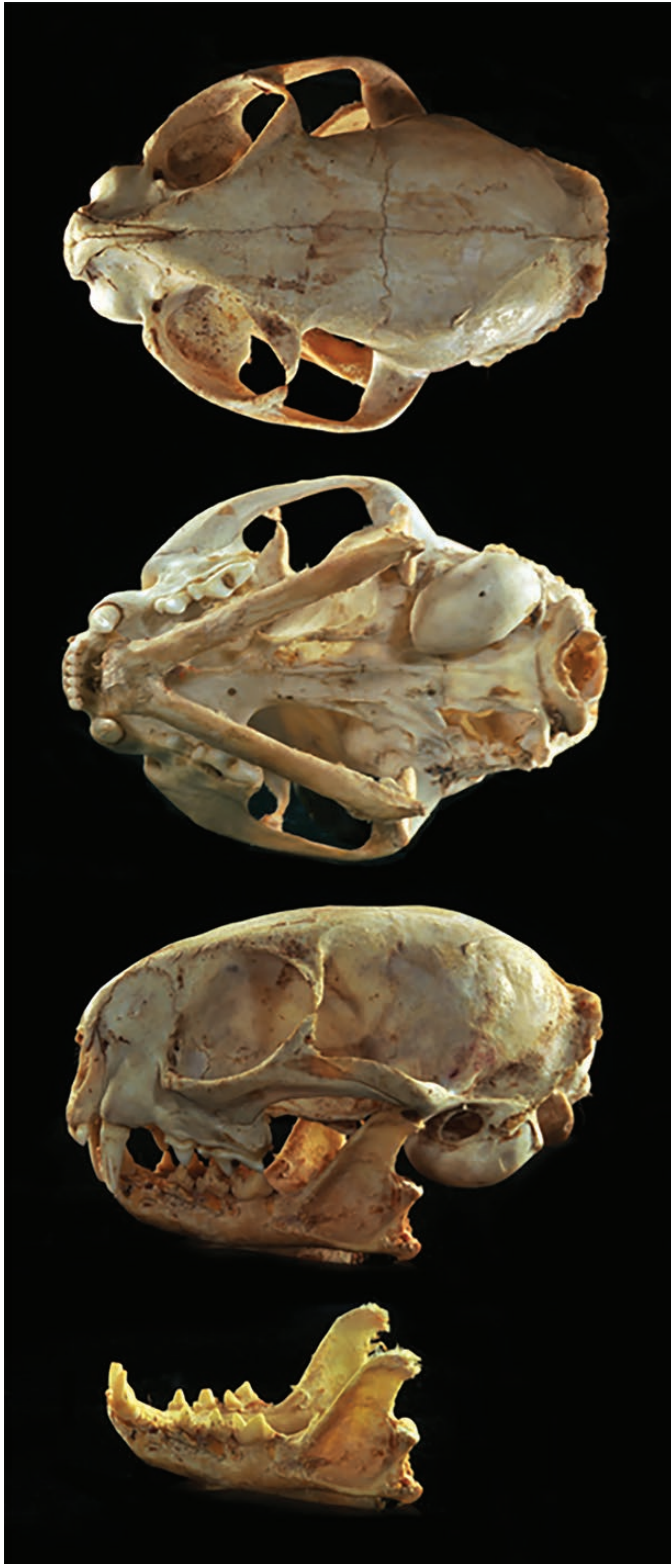

Fig. 2.—Dorsal, ventral, and lateral views of skull and lateral view of mandible of a female *Prionailurus rubiginosus* (Sri Lanka National Museum of Natural History registration number 38) from Katagamuwa southern province, 5.09.1933. Photo courtesy of the Sri Lanka National Museum of Natural History. Greatest length of skull is 61 mm.

Prionailurus rubiginosus is considered to be the smallest felid species in the world with adults approximately one-half the mass of *Felis catus*, domestic cat (Pocock 1939; Dmoch 1997; Sunquist and Sunquist 2002). Adults have a mean weight of 1.1 kg for females ($n = 3$) and 1.6 kg for males ($n = 5$), as measured from specimens of *P. r. phillipsi* (Phillips 1935), whereas adult domestic cats average 2.7 kg for females ($n = 34$) and 3.8 kg for males ($n = 63$ —Eberhard 1954). Head-body length of *P. rubiginosus* is 350–480 mm, and tail length is 150–300 mm, for a total length of 500–780 mm (Sunquist and Sunquist 2002). According to Pocock (1939), the average adult hind foot measurement is 88.5 mm ($n = 14$). The small rounded ears of *P. rubiginosus* average 40 mm, as measured from three specimens in the British Museum.

DISTRIBUTION

Prionailurus rubiginosus is restricted to the Indian subcontinent and Sri Lanka (Pocock 1939; Sunquist and Sunquist 2002; Fig. 3). It inhabits both humid and wet or dry deciduous forests as well as scrub and grassland, but it is likely absent from evergreen forests because it prefers dense vegetation and rocky areas (Nowell and Jackson 1996; Kittle and Watson 2004; Patel 2006). *P. rubiginosus* was originally believed to be confined to Sri Lanka and a small portion of southwestern India (Weigel 1972; Guggisberg 1975; Sterndale 1884), but more recent research and sightings have established its presence throughout most of India (Nowell and Jackson 1996; Sunquist and Sunquist 2002) and in Nepal's Shuklaphanta Wildlife Reserve and Bardiya National Park (Lamichhane et al. 2016). Accordingly, the distribution of the subspecies *P. r. phillipsi* and *P. r. koladivius* are restricted to Sri Lanka, whereas *P. r. rubiginosus* is distributed throughout most of India (Pocock 1939; Deraniyagala 1956; Nowell and Jackson 1996; Dmoch 1997; Khan and Mukherjee 2008; Fig. 3) and in the western region of Nepal's Terai (Lamichhane et al. 2016). Kittle and Watson (2004) observed *P. r. phillipsi* outside of Yala National Park in Sri Lanka in addition to a possible hybrid with a domestic cat.

In the state of Tamil Nadu, India, *P. r. rubiginosus* is found in the Varushanad Valley in the southern region of the Western Ghats, a noted biodiversity hotspot (Pillay 2008). Its presence has also been well documented in the Nagarjunasagar Srisailem Tiger Reserve, as well as in the Nellore district, and throughout the state of Andhra Pradesh (Behera 2008). Furthermore, its presence is known from the Nugu Wildlife Sanctuary among other areas in the state of Karnataka (Kumara and Singh 2005) and from areas in the state of Orissa (Prater 1998; Sunquist and Sunquist 2002).

Camera traps first documented *P. rubiginosus* in Central India at the Nagzira Wildlife Sanctuary (Anwar et al. 2010; Patel 2010) and later in the Tadoba-Andhari Tiger Reserve (Dubey 1999); both areas are in the state of Maharashtra. Since then, sightings in the state of Maharashtra have increased notably. Moreover, researchers have identified a breeding population

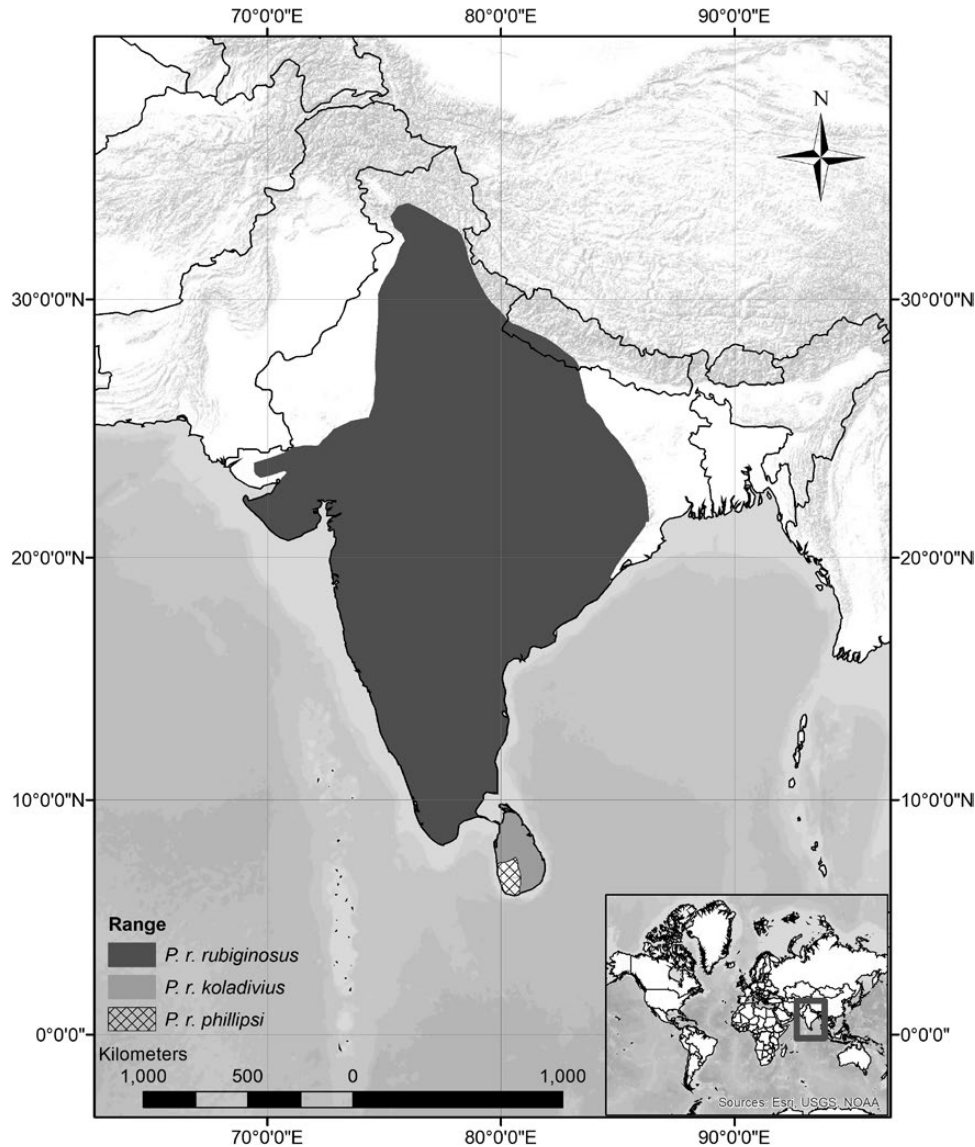


Fig. 3.—Geographic distribution of *Prionailurus rubiginosus*; subspecies are *P. r. koladivius* in light gray, *P. r. phillipsi* in cross-hatch, and *P. r. rubiginosus* in dark gray. Borders between *P. r. phillipsi* and *P. r. koladivius* are conjectural. Map generated by K. Petter based on Kitchener et al. (2017).

in western Maharashtra, an area with human and agriculturally dominated landscapes, where high rodent densities have been recorded (Athreya 2010).

Prionailurus rubiginosus is present in the Gir Wildlife Sanctuary and National Park (Pathak 1990) in the state of Gujarat, its southern part (Singh 1987), as well as in eastern Gujarat (Patel 2006). The species also occurs in the states of Madhya Pradesh and Rajasthan (Mukherjee 1998; Bhatnager et al. 2000), and additional observations indicate its presence on the east coast (Manakadan and Sivakumar 2006).

Sightings of *P. rubiginosus* in the Pilibhit Tiger Reserve in the Indian Terai region of the state of Uttar Pradesh were once thought to represent the northernmost extent of its range (Anwar et al. 2010), but more recently camera traps have detected its presence in the Corbett Tiger Reserve in Uttarakhand. Additionally,

reports of sightings in the states of Jammu and Kashmir have been recorded (Prater 1998; Sunquist and Sunquist 2002), indicating that its distribution extends even farther north than formerly suspected. However, the contiguity of its distribution remains unknown due to a lack of information on habitat preferences (Nowell and Jackson 1996). No fossils are known.

FORM AND FUNCTION

The low-set rounded ears of *Prionailurus rubiginosus* are small in relation to the head (Pocock 1939). As with other felid species, *P. rubiginosus* has sharp, strongly curved, and retractile claws. Its short rostrum has wide postorbital and zygomatic areas to accommodate the substantial craniomandibular muscles.

These muscles are responsible for the powerful bite that is typical of members of the Felidae. Furthermore, *P. rubiginosus* has the archetypal cat carnassial pair of molars, which provides the shearing and cutting action of its mostly animal diet (Sicuro 2011).

The skull has a notably short rostrum, plus the ends of the nasals curve downward and the anterior nares are in a plane nearly vertical with the maxilla-premaxillary suture. The nasals are strongly constricted posteriorly and the maxillae are laterally expanded. In adults, the orbits are completely surrounded by bone. *P. rubiginosus* lacks a sagittal crest and the temporal ridges form a U- or lyriform shape (Pocock 1939).

The skulls of four males, one female, and one of unknown sex averaged (mm) total length 76, condylobasal length 70, zygomatic width 50, postorbital width 24, inter-orbital width 12, maxillary width 19, and mandibular length 48 (Pocock 1939).

The dental formula of *P. rubiginosus* is $i\ 3/3$, $c\ 1/1$, $p\ 2/2$, $m\ 1/1$, total 28. As a result of the evolutionarily shortened muzzle, the area immediately behind the upper canine is reduced and the first two premolars are lost (Pocock 1939). The P4/m1 form the carnassial pair, wherein the inner lobe of the upper carnassial is reduced. The P4 averages 8 mm ($n = 6$), and the m1 averages 7 mm ($n = 6$) in length (Pocock 1939).

Published data on basic physiological aspects, such as basal metabolic rate, heart and respiration rates, or cellular processes, are virtually unavailable.

ECOLOGY

Population characteristics.—Little is known of the ecology of *Prionailurus rubiginosus* in the wild, so aspects of its ecology and behavior are inferred from captive individuals and observational reports (Dmoch 1997; Sabapara 1999; Sunquist and Sunquist 2002; Behera 2008; Pillay 2008). Unlike many species of small felids, relatively few *P. rubiginosus* have been held in captivity (Dmoch 1997; Sabapara 1999; Sunquist and Sunquist 2002). Longevity ranges from 12 to 18 years in captivity. Males and females reach sexual maturity within their first year. Gestation is 67–71 days (mean 69 days, $n = 22$), and litter size is 1–3 kittens ($n = 58$ —Dmoch 1997; see “Husbandry” for additional details).

Space use.—In India, *Prionailurus rubiginosus* inhabits both wet and dry deciduous forests, scrub forests, tropical forests, grass and shrub lands, rocky areas, and hilly slopes. Sightings occur often in grassy areas, teak or bamboo forests, and arid vegetation areas (Pocock 1939; Guggisberg 1975; Pathak 1990; Nowell and Jackson 1996; Sunquist and Sunquist 2002), but sometimes dense vegetation and rocky areas are favored (Kittle and Watson 2004; Patel 2006). In Sri Lanka, they are found in humid forests, in low scrub lands, on mountaintops, and in arid coastal belts ranging from sea level to elevations as high as 2,100 m (Sunquist and Sunquist 2002). In recent years, *P. rubiginosus* frequents

human-inhabited agricultural areas as well as the attics of abandoned houses in urbanized areas. Some investigators speculate that *P. rubiginosus* is responding more to substantial rodent populations rather than to habitat type (Nowell and Jackson 1996; Mukherjee 1998; Pillay 2008).

Diet.—Information on the diet of wild *Prionailurus rubiginosus* is scant. Early descriptions of diet include small mammals, birds, and possibly small lizards and frogs (Phillips 1935; Pocock 1939; Sunquist and Sunquist 2002). Direct observations suggest it feeds primarily on small rodents, but one particular cat hunted frogs (Patel 2006). Hunting activity tends to increase after heavy rains, which is likely the direct result of a corresponding increase in the activity of rodents, their primary prey, and of frogs (Worah 1991; Bambaradeniya and Amarasinghe 2001). They also prey on domestic fowl (Phillips 1935; Pocock 1939; Sunquist and Sunquist 2002), which has resulted in their persecution (Pillay 2008; see “Husbandry” for further details on captive diet).

Diseases and parasites.—Information on diseases and disease transmission, illness and infection, and parasitism is drawn exclusively from captive animals and from a handful of necropsied wild animals. Feral domestic cats transmit diseases to *Prionailurus rubiginosus* (Bambaradeniya and Amarasinghe 2001), specifically feline enteritis (Sunquist and Sunquist 2002), panleucopaenia, pneumonia, pseudo-tuberculosis, and bone-marrow disease (Dmoch 1997). Some zoos vaccinate their *P. rubiginosus* for calicivirus and herpes (Dmoch 1997). Over the course of several decades, Dmoch (1997) of the Frankfurt Zoo (Germany) recorded 13 cases of adult mortality and their causes, as follows: three from nephritis and one each of foreign bodies, food aspiration, gastro-intestinal inflammation, gastritis, rhinitis, uterus rupture, pneumonia, acute hepatitis, pseudo-tuberculosis, and hypernatremia amyloidosis. Furthermore, *P. rubiginosus* is highly susceptible to parasites. Round worms in the stomach and intestines of a necropsied wild kitten suggested that the severe congestion and hemorrhages in the intestines were linked to the heavy worm infestation (Sabapara 1999). On examination, the feces contained large numbers of eggs of *Toxoscaris leonini*, *Trichuris*, and *Anchylostoma*. Additionally, liver, spleen, and lung tissue samples revealed the presence of *Pseudomonas*, a bacterium. Infestations of *Uncinaria*, *Toxocara*, *Coccidia*, and *Toxoscaris* were often treated at the Frankfurt Zoo (Dmoch 1997). For further information, see “Husbandry.”

Interspecific interactions.—*Prionailurus rubiginosus* is sympatric with other small felids, such as *P. bengalensis* and *Felis chaus*, the jungle cat, but interspecific interactions have scarcely been investigated (Nowell and Jackson 1996). Although *P. rubiginosus* has no known wild predators, because of its size it is often assumed that it is prey for larger predators. Mostly ground dwelling, *P. rubiginosus* is quite agile and adept in trees, perhaps its primary means of escape from larger predators (Sunquist and Sunquist 2002).

Miscellaneous.—Detailed research on *Prionailurus rubiginosus* is grossly deficient (Dmoch 1997; Sabapara 1999; Sunquist and Sunquist 2002; Behera 2008; Pillay 2008) and therefore standard methods of capture, marking, tracking, recording, censusing, or sampling are virtually lacking. Camera traps, used to document much of its known range (Dubey 1999; Anwar et al. 2010; Patel 2010), sometimes capture the variable stripe patterns along the inner sides of limbs, making it possible to identify individuals (Lamichhane et al. 2016). However, such coat variation is not always visible or captured with camera trapping.

Prionailurus rubiginosus is easily domesticated yet rarely held in captivity (Sunquist and Sunquist 2002). Accounts describe them as graceful and agile, superbly vicious hunters relative to their size, and expressive, playful, and affectionate toward their human owners (Jerdon 1874; Sunquist and Sunquist 2002; see “Husbandry”).

HUSBANDRY

Prionailurus rubiginosus is rarely held in zoos, and currently the Frankfurt, Cincinnati (USA), Port Lympne (England), and Colombo (Sri Lanka) zoos host the majority of the small captive population (Sunquist and Sunquist 2002; Jayaratne et al. 2015) with all animals originating from the founding pair at the Frankfurt Zoo (Dmoch 1997). These felines do not fare well in captivity if not immediately vaccinated after capture or arrival because they are prone to contracting a host of diseases, such as feline enteritis (Sunquist and Sunquist 2002), panleucopaenia, pneumonia, pseudo-tuberculosis, and bone-marrow disease (Dmoch 1997). Despite its susceptibility to disease, those held in captivity can have high longevity, with the longest lifespan recorded at 18 years in the Frankfurt Zoo (Dmoch 1997). Breeding has ceased at the Frankfurt and Cincinnati zoos, probably due to the effects of inbreeding depression. To ensure the future of captive *P. rubiginosus*, new founder animals from the wild are required to restore genetic diversity (Dmoch 1997). In the Frankfurt Zoo, kittens are vaccinated against panleucopaenia with Felidovac P, and annual vaccination is needed to prevent this condition (Dmoch 1997). Wild kittens taken into captivity need immediate treatment for intestinal parasites, such as *Uncinaria*, *Toxoscaris*, *Trichuris*, and *Anchylostoma* (Dmoch 1997; Sabapara 1999).

Because *P. rubiginosus* is generally believed to be strictly nocturnal based on reported sightings in the wild only occurring at night, dawn, or dusk, captive animals are kept on a similar light regime. At the Frankfurt Zoo, *P. rubiginosus* is housed in the nocturnal section, and the reversed lighting conditions are set to mimic seasonal variation in day length (Dmoch 1997). Observations of captive animals indicate that *P. rubiginosus* may not be strictly nocturnal, but this may be a captive behavior (Dmoch 1997; Sunquist and Sunquist 2002). Based on observations of six individuals in non-exhibit enclosures at the National Zoological Gardens in Dehiwala,

Sri Lanka, *P. rubiginosus* tends to be most active between the hours of 1800 to 2000 (Jayaratne et al. 2015). However, these authors discussed the difficulties of comparing the behaviors of wild and captive animals. The original enclosure at Frankfurt Zoo consisted of a forest display with a soil substrate, a range of climbing options, and a number of sleeping boxes (Scherpner 1982).

Very young kittens in captivity are fed pasteurized lukewarm milk through a sterile feeding bottle, usually every 2 h during the day and every 4 h at night (Sabapara 1999). Older kittens brought to the Frankfurt Zoo were reared on a diet of minced beef muscle and heart, protein-rich mash, and mice and rats, and they mostly declined eating day-old chicks (Dmoch 1997). The daily diet of captive adults, as recorded by the Frankfurt Zoo, usually consists of large chunks and small strips of beef muscle and heart (ca. 100 g), 2-day-old chicks (ca. 40 g), one mouse (ca. 30 g), and 2–5 g of scraped carrot, apple, boiled egg, and cooked rice, and sometimes germinated wheat, fish, and banana too (Dmoch 1997). Furthermore, a mineral supplement was provided daily and multi-vitamins, such as vitamin B complex and vitamin K, were supplied one to two times per week (Dmoch 1997). Adults eat more than 6% of their body weight each day (Sunquist and Sunquist 2002).

Most ontogenetic and reproductive information for *Prionailurus rubiginosus* comes from captive breeding programs in zoos (Sunquist and Sunquist 2002). In captivity, both sexes reach sexual maturity within their first year (Dmoch 1997). Although *P. rubiginosus* breeds year round, about 50% of young are born between July and October, yet there is insufficient evidence to solely suggest seasonal breeding (Dmoch 1997; Sunquist and Sunquist 2002). Captive animals begin mating activity anywhere from 1 to 72 days after first introduction, a mean of 7–8 days to first copulation, and 49% of the time mating occurred within 4 days of introductions. There is no relationship between the first time of mating and the age of the female, the time elapsed from weaning a previous litter, the distinguishing characteristics of the male, or the season (Dmoch 1997). Estrus lasts approximately 5 days, and, as in other small felids, mating includes the typical nape bite and straddling (Sunquist and Sunquist 2002). Males mount on average 7.64 times per hour; however, copulation is unusually brief, lasting just under a minute (Sunquist and Sunquist 2002). It is assumed that shortened periods of receptivity and swift copulations may be one way for small felids to reduce their vulnerability to predation (Sunquist and Sunquist 2002). The Frankfurt Zoo determined that mating activity ranged from 1 to 11 days (mean 5–7 days, $n = 49$ —Dmoch 1997).

Females consistently selected birthing boxes on the ground rather than those at higher locations (Dmoch 1997). Captive females give birth in seclusion to one or two kittens (Sunquist and Sunquist 2002) or very rarely three kittens (Dmoch 1997). In captivity, neonates weigh 60–70 g and are blind (Sunquist and Sunquist 2002). Young emerge from their birthing box for

the first time after 28–32 days, having already developed full mobility and locomotory skills (Dmoch 1997). Additionally, weaning begins at days 35–40, although a 60-day-old cub was observed suckling (Dmoch 1997).

GENETICS

The diploid number (2n) for *Prionailurus rubiginosus* is 38. Autosomal chromosomes include 12 metacentric, 14 submetacentric, 8 acrocentric, and 2 telocentric. The X is a submetacentric chromosome, but the Y is not yet documented. Despite similarities to other felid species, subtle variations in the D and F chromosomal groups set it apart (Centerwall et al. 1983; Eroğlu 2017). The karyotype symmetry/asymmetry index (S/A_1) formula gives an index value of 2.0000 for females, indicating a symmetric karyotype (Eroğlu 2017).

The phylogenetic relationships of the Felidae have been a source of great contention for over a century (Pocock 1917; Sunquist and Sunquist 2002). However, recent genetic analyses confirm the placement of *rubiginosus* in the genus *Prionailurus* (Johnsen et al. 2006; O'Brien and Johnson 2007), which is contrary to the suggestions of Wozencraft (2005) and Sunquist and Sunquist (2002), investigators who considered *rubiginosus* to be incertae sedis in *Prionailurus*. Genetic analyses on the modern-day Felidae, including molecular phylogenetic reconstruction and DNA sequencing from autosomal, mitochondrial, and nuclear DNA, revealed that *P. rubiginosus* is a certain member of the leopard cat lineage, one of the most recently derived lineages.

Kittle and Watson (2004) recorded *P. rubiginosus* mating with a domestic cat, and they also described a potential hybrid as being slightly larger in size, with longer legs, and having a pelage with unusual markings on a paler background than is typical for *P. rubiginosus*. Although not substantiated, some investigators consider hybridization with domestic cats to be a common occurrence (Worah 1991). If true, hybridization is a threat to *P. rubiginosus*, a rare and vulnerable species.

CONSERVATION

In Sri Lanka and India, *Prionailurus rubiginosus* is considered “Near Threatened” by the International Union for the Conservation of Nature and Natural Resources (Mukherjee et al. 2016). The total effective population size is estimated to be < 10,000 (Khan and Mukherjee 2008), and the declining population trend is mainly attributed to habitat loss, specifically the major spread of agricultural cultivation, which poses a significant threat (Nowell and Jackson 1996). Also, *P. rubiginosus* does not assimilate well into cultivated or urban areas, yet some individuals have adapted by living in abandoned buildings and likely by exploiting rodent populations in nearby farm fields. However, it is not welcomed by local people due to its appetite for domestic fowl (Sunquist and Sunquist 2002; Pillay 2008). The Indian population (*P. r. rubiginosus*) is listed

under the Convention of International Trade in Endangered Species of Wild Fauna and Flora as Appendix I, and the Nepali (*P. r. rubiginosus*) and Sri Lankan (*P. r. phillipsi*) populations are listed as an Appendix II rating (Dmoch 1997; Mukherjee et al. 2016). *P. rubiginosus* is fully protected under Schedule I of the Indian Wildlife (Protection) Act, 1972 in India (Sabapara 1999), and, in Sri Lanka, is listed as a strictly protected mammal under Schedule II of the Fauna and Flora Protection (Amendment) Act, No. 22 of 2009. Because its presence in Nepal has only recently been documented (Lamichhane et al. 2016), it is likely not explicitly listed or protected under Nepali conservation laws (Mukherjee et al. 2016). The protection offered by law during the 1990s did not prevent the occasional report of skins or live animals surfacing in trade (Nowell and Jackson 1996). However, current data on how conservation actions have curtailed domestic trade is lacking (Mukherjee et al. 2016). Hunting by humans for food or to control as a livestock pest in some areas of Sri Lanka and India are potential sources of mortality, and Sri Lankan locals frequently mistake kittens for baby leopards, *Panthera pardus*, and kill them (Sunquist and Sunquist 2002). *P. rubiginosus* is secretive, elusive, and rare, and further study is needed to fully understand the status of this species (Dmoch 1997; Sunquist and Sunquist 2002).

ACKNOWLEDGMENTS

First and foremost, special thanks to my mentor and friend Dr. T. Holmes, Jr., Department of Biology, Humboldt State University (retired) for providing me this opportunity, for reviewing multiple drafts of this account, and for his gracious instructional support throughout the endeavor. Without his encouragement, this account would have never been completed. I also thank my academic advisor Dr. M. Szykman Gunther, Department of Wildlife, Humboldt State University for supervising and facilitating the writing process. It is with great appreciation that I acknowledge my valuable colleague and good friend K. Petter for volunteering to generate the account distribution map. Finally, I am very grateful to all investigators who contributed to this account through their published research.

LITERATURE CITED

- ANWAR, M., H. KUMAR, AND J. VATTAKAVAN. 2010. Range extension of rusty-spotted cat to the Indian Terai. *Cat News* 53:25–27.
- ATHREYA, V. 2010. Rusty-spotted cat more common than we think? *Cat News* 53:27.
- BAMBARADENIYA, C. N. B., AND S. AMARASINGHE. 2001. Wild cats in Sri Lanka. *Cat News* 35:18.
- BEHERA, S. 2008. Rusty-spotted cat in Nagarjunasagar Srisailem Tiger Reserve. *Cat News* 48:19.
- BHATNAGER, R., V. S. RANA, AND S. K. SHARMA. 2000. The occurrence of rusty-spotted cat (*Prionailurus rubiginosus*) near Thur-Magra Forest Block in Udaipur City, Rajasthan. *Zoos' Print* 15:8.
- CENTERWALL, W. R., D. H. WURSTER-HILL, E. J. MARUSKA, AND L. W. KRAMER. 1983. Chromosome identification of the rusty-spotted

- cat (*Felis rubiginosa*): one more down and four to go. American Journal of Veterinary Research 44:856–858.
- DERANIYAGALA, P. E. P. 1956. A new subspecies of rusty spotted cat from Ceylon. Spolia Zeylanica 28:113–114.
- DMOCH, R. 1997. Husbandry, breeding and population development of the Sri Lankan rusty-spotted cat *Prionailurus rubiginosus phillipsi*. International Zoo Yearbook 35:115–120.
- DUBEY, Y. 1999. Sighting of rusty-spotted cat in Tadoba Andhari Tiger Reserve, Maharashtra. Journal of the Bombay Natural History Society 96:310.
- EBERHARD, T. 1954. Food habits of Pennsylvania house cats. The Journal of Wildlife Management 18:284–286.
- EROĞLU, H. E. 2017. The comparison of the Felidae species with karyotype symmetry/asymmetry index (S/A₁). Punjab University Journal of Zoology 32:229–235.
- GEOFFROY SAINT-HILAIRE, I. 1834 [1831]. Mammifères. Bélanger, C., Voyage aux Indes-orientales, par le nord de l'Europe, les provinces du Caucase, la Géorgie, l'Arménie et la Perse, suivi de détails topographiques, statistiques et autres sur le Pégou, les Iles de Java, de Maurice et de Bourbon, sur le Cap-de-Bonne-Espérance et Sainte-Hélène, pendant les années 1825, 1826, 1827, 1828. Arthus Bertrand, Paris, France.
- GRAY, J. E. 1867. Notes on the skulls of the cats (Felidae). Proceedings of the Scientific Meetings of the Zoological Society of London 1867:269.
- GUGGISBERG, C. A. W. 1975. Wild cats of the world. Taplinger Publishing Company, New York.
- JAYARATNE, C., P. K. P. PERERA, AND P. N. DAYAWANSA. 2015. A preliminary investigation of the behavior of rusty spotted cats *Prionailurus rubiginosus* in captivity. Wildlanka 3:1–11.
- JERDON, T. C. 1874. The mammals of India: a natural history of all the animals known to inhabit continental India. John Wheldon, London, United Kingdom.
- JOHNSON, W. E., ET AL. 2006. The late Miocene radiation of modern Felidae: a genetic assessment. Science 311:73–77.
- KHAN, J. A., AND S. MUKHERJEE. 2008. *Prionailurus rubiginosus*. International Union for the Conservation of Nature and Natural Resources Red list of Threatened Species. International Union for the Conservation of Nature and Natural Resources, Gland, Switzerland. www.iucnredlist.org. Accessed 20 February 2013.
- KITCHENER, A. C., ET AL. 2017. A revised taxonomy of the Felidae. The final report of the Cat Classification Task Force of the IUCN/SSC Cat Specialist Group. Cat News Special Issue 11:80pp.
- KITTLE, A., AND A. WATSON. 2004. Rusty-spotted cat in Sri Lanka: observations of an arid zone population. Cat News 40:17–19.
- KUMARA, H. N., AND M. SINGH. 2005. Occurrence of the rusty-spotted cat *Prionailurus rubiginosus* (Geoffroy) in Nugu Wildlife Sanctuary, Karnataka. Journal of the Bombay Natural History Society 102:336–337.
- LAMICHHANE, B. R., ET AL. 2016. Rusty-spotted cat: 12th cat species discovered in western Terai of Nepal. Cat News 64:30–33.
- MANAKADAN, R., AND S. SIVAKUMAR. 2006. Rusty-spotted cat on India's east coast. Cat News 45:26.
- MITHTHAPALA, S. 2012. The Gulf of Mannar and its surroundings: a resource book for teachers in the Mannar district. IUCN Sri Lanka Office, Colombo, Sri Lanka.
- MUKHERJEE, S. 1998. Cats: some large, many small. ENVIS Wildlife and Protected Areas 1:5–13.
- MUKHERJEE, S., J. W. DUCKWORTH, A. SILVA, A. APPEL, AND A. KITTLE. 2016. *Prionailurus rubiginosus*. The IUCN Red List of Threatened Species. www.iucnredlist.org. Accessed 30 January 2019.
- NOWELL, K., AND P. JACKSON. 1996. The wild cats: a status survey and conservation action plan. IUCN/SSC Cat Specialist Group, Gland, Switzerland.
- O'BRIEN, S. J., AND W. E. JOHNSON. 2007. The evolution of cats. Scientific American 297:68–75.
- PATEL, K. 2006. Observations of rusty-spotted cat in eastern Gujarat. Cat News 45:27–28.
- PATEL, K. 2010. New distribution record data for rusty-spotted cat from Central India. Cat News 53:26–27.
- PATHAK, B. J. 1990. Rusty spotted cat *Felis rubiginosa* Geoffroy: a new record for Gir Wildlife Sanctuary and National Park. Journal of the Bombay Natural History Society 87:445.
- PHILLIPS, W. W. A. 1935. Manual of the mammals of Ceylon. Ceylon Journal of Science, Dulau and Company, London, United Kingdom.
- PILLAY, R. 2008. Sighting of a rusty-spotted cat in the Varushanad Valley, India. Cat News 49:26–27.
- POCOCK, R. I. 1917. The classification of existing Felidae. The Annals and Magazine of Natural History, Series 8 20:332–339.
- POCOCK, R. I. 1939. The fauna of British India, including Ceylon and Burma. Mammalia – Vol. 1. Taylor and Francis, Ltd., London, United Kingdom.
- PRATER, S. H. 1998. The book of Indian animals. Bombay Natural History Society, Oxford University Press, Mumbai, India.
- SABAPARA, R. H. 1999. Multiple infection in a rusty-spotted cat (*Prionailurus rubiginosus*). Zoos' Print Journal 14:67.
- SCHERPNER, C. 1982. The Grzimek House for small mammals at Frankfurt zoo. International Zoo Yearbook 22:276–287.
- SICURO, F. L. 2011. Evolutionary trends on extant cat skull morphology (Carnivora: Felidae): a three-dimensional geometrical approach. Biological Journal of the Linnean Society 103:176–190.
- SICURO, F. L., AND L. F. B. OLIVEIRA. 2015. Variations in leopard cat (*Prionailurus bengalensis*) skull morphology and body size: sexual and geographic influences. PeerJ 3:e1309.
- SINGH, D. 1987. Sighting of a rusty-spotted cat (*Felis rubiginosa*). Journal of the Bombay Natural History Society 84:200.
- SRINIVASULU, C. 2019. South Asian mammals: an updated checklist and their scientific names. CRC Press, Taylor & Francis Group, Boca Raton, Florida.
- STERNDALE, R. A. 1884. Natural history of the Mammalia of India and Ceylon. Thacker, Spink, & Co., Calcutta, India.
- SUNQUIST, M., AND F. SUNQUIST. 2002. Rusty-spotted cat *Prionailurus rubiginosus* (Geoffroy, 1831). Pp. 237–240 in Wild cats of the world. University of Chicago Press, Chicago, Illinois.
- VIGORS, N. A., AND T. HORSFIELD. 1827. Description of two species of the genus *Felis*, in the collection of the Zoological Society. The Zoological Journal 3:449–450.
- WEERAKOON, D. K. 2012. The taxonomy and conservation status of mammals in Sri Lanka. Pp. 134–137 in The national red list 2012 of Sri Lanka: conservation status of the fauna and flora (Weerakoon, D. K. and S. Wijesundara, eds.). Ministry of Environment, Colombo, Sri Lanka.
- WEIGEL, I. 1972. Small felids and clouded leopards. Pp. 281–332 in Grzimek's animal life encyclopedia, vol. 12, Mammals III (H. C. B. Grzimek ed.). Van Nostrand Reinhold, New York.
- WILSON, D. E., AND R. A. MITTERMEIER (Eds.). 2009. Handbook of the mammals of the world. Vol. 1. Carnivores. Lynx Edicions, Barcelona, Spain.
- WORAH, S. 1991. The ecology and management of a fragmented forest in south Gujarat, India: the Dangs. Ph.D. thesis, University of Pune, Pune, India.
- WOZENCRAFT, W. C. 2005. Order Carnivora. Pp. 542–544 in Mammal species of the world: a taxonomic and geographic reference (D. E. Wilson and D. M. Reeder, eds.). 3rd ed. Johns Hopkins University Press, Baltimore, Maryland.

Associate Editor of this account was ROBERT K. ROSE. RYAN W. NORRIS and LUIS A. RUEDAS reviewed the synonymy. Editor was Meredith J. HAMILTON.