



Selective fatty replacement of the exocrine pancreas in a domestic shorthair cat: histopathological findings with long-term outcome

Authors: Dobromylskyj, Melanie J, and Dobromylskyj, Peter

Source: Journal of Feline Medicine and Surgery Open Reports, 1(2)

Published By: SAGE Publishing

URL: <https://doi.org/10.1177/2055116915593967>

BioOne Complete (complete.BioOne.org) is a full-text database of 200 subscribed and open-access titles in the biological, ecological, and environmental sciences published by nonprofit societies, associations, museums, institutions, and presses.

Your use of this PDF, the BioOne Complete website, and all posted and associated content indicates your acceptance of BioOne's Terms of Use, available at www.bioone.org/terms-of-use.

Usage of BioOne Complete content is strictly limited to personal, educational, and non - commercial use. Commercial inquiries or rights and permissions requests should be directed to the individual publisher as copyright holder.

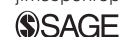BioOne sees sustainable scholarly publishing as an inherently collaborative enterprise connecting authors, nonprofit publishers, academic institutions, research libraries, and research funders in the common goal of maximizing access to critical research.



Selective fatty replacement of the exocrine pancreas in a domestic shorthair cat: histopathological findings with long-term outcome

Journal of Feline Medicine and Surgery
Open Reports
 1–5

© The Author(s) 2015
 Reprints and permissions:
sagepub.co.uk/journalsPermissions.nav
 DOI: 10.1177/2055116915593967
jfmsopenreports.com



Melanie J Dobromylskyj¹ and Peter Dobromylskyj²

Abstract

The clinical, histopathological findings and eventual outcome of a cat with marked and selective fatty replacement of the exocrine pancreas are described in this case report. A 9-year-old female neutered domestic shorthair cat presenting with polyphagia, weight loss and intermittent vomiting was diagnosed on histopathology with severe exocrine pancreatic atrophy, with relative sparing of the endocrine pancreas and replacement of the acinar cells by mature adipose tissue. This case report discusses the histological findings in this case and the eventual outcome, as well as the potential underlying causes of this histological change.

Accepted: 12 April 2015

Case description

A 9-year-old female neutered domestic shorthair cat was presented to the veterinary surgeon with an 8–10 week history of weight loss, markedly increased appetite and polydipsia, accompanied by occasional vomiting but no diarrhoea. Clinical examination revealed a body condition score (BCS) of 2/9, and a diffuse, smooth-surfaced hepatomegaly was apparent on abdominal palpation. Clinical biochemistry demonstrated elevated levels of alanine aminotransferase (671.0 U/l; reference interval [RI] 5.0–75.0 U/l), bilirubin (31.3 µmol/l; RI <6.8 µmol/l) and alkaline phosphatase (179 U/l; RI 5–100 U/l), with total protein, urea and creatinine all within normal limits. Total thyroxine was within normal limits (19.70 nmol/l; RI 13.00–50.00 nmol/l). There was no evidence of hyperglycaemia or glucosuria.

The cat had previously been presented to veterinary surgeons on eight occasions, irregularly spaced over the preceding 8 years and without any apparent seasonality. Each episode, varying in length from a few days to several weeks, was characterised by decreased appetite or inappetence, variably accompanied by vomiting, diarrhoea and/or mild pyrexia (ranging from 39.1–40.0°C), and neutrophilia with a left shift. The first episode occurred at approximately 1 year of age. The clinical signs resolved over a short time with symptomatic antibiotic and non-steroidal anti-inflammatory treatment, and

the cat's body weight, although low, had remained constant at approximately 3 kg (BCS 2/9).

Given the continuation of the polyphagia and polydipsia over the following month, an exploratory laparotomy was performed; gross changes included a diffusely enlarged liver with an enhanced lobular pattern, together with multiple enlarged lymph nodes within the mesentery. There was no abdominal fat present. The pancreas was grossly abnormal and was diffusely amorphous, pale cream to yellow in colour with little or no normal structure, resembling adipose tissues. Representative biopsies were obtained from the pancreas, liver, duodenum, jejunum, ileum and mesenteric lymph node.

Histological examination of haematoxylin and eosin-stained sections of the pancreas revealed severe parenchymal loss, with the residual pancreatic cells widely separated by well-differentiated adipose tissue (Figure 1).

¹Finn Pathologists, Diss, UK

²The Veterinary Hospital, Lowestoft, UK

Corresponding author:

Melanie Dobromylskyj BSc Vet Path (Hons), BVSc, PhD, FRCPath, MRCVS, Finn Pathologists, The Old School House, One Eyed Lane, Diss, IP21 5TT, Norfolk, UK
 Email: melanie.dobromylskyj@finnpathologists.com



Creative Commons CC-BY-NC: This article is distributed under the terms of the Creative Commons Attribution-NonCommercial 3.0 License (<http://www.creativecommons.org/licenses/by-nc/3.0/>) which permits non-commercial use, reproduction and distribution of the work without further permission provided the original work is attributed as specified on the SAGE and Open Access page (<http://www.uk.sagepub.com/aboutus/openaccess.htm>).

The remaining cells were disorganised and did not contain zymogen granules. Special staining for connective tissues (Masson's trichrome) showed minimal fibrosis and there was no evidence of either chronic or acute inflammation. Immunohistochemical (IHC) staining of the pancreatic tissues was performed for various cell markers, including pancytokeratin for epithelial cells, and insulin, glucagon, chromogranin and synaptophysin for islet cells; IHC staining for pancytokeratin confirmed the absence of exocrine pancreatic tissues and that the residual tissues were islets that appeared to have been selectively spared (Figure 2). The morphological diagnosis was of selective exocrine pancreatic atrophy, with fatty replacement.

Haematoxylin and eosin-stained sections of the liver showed moderate portal-to-portal bridging fibrosis accompanied by parenchymal loss and moderate biliary proliferation, with special staining with Masson's trichrome confirming the presence of bridging fibrosis. The portal areas also contained a moderate inflammatory cell infiltrate of lymphocytes and plasma cells with fewer neutrophils; the diagnosis was of a chronic active cholangiohepatitis with bridging fibrosis.¹ Full-thickness biopsies from the duodenum, jejunum and ileum were all similar in appearance and consistent with a mild-to-moderate, chronic active lymphoplasmacytic and neutrophilic enteritis.² The mesenteric lymph node demonstrated reactive hyperplasia.

At the time of histological diagnosis, further clinical biochemistry revealed normal levels of amylase, lipase (1,2-o-dilauryl-rac-glycero glutaric acid-(6'-methyl-resorufin) ester [DGGR] lipase assay) and folate but a decreased level of feline trypsin-like immunoreactivity (fTLI) (11.5 µg/l; RI 12.0–82.0 µg/l); in cats, values ≤8.0 µg/l are diagnostic for exocrine pancreatic insufficiency (EPI), with values between 8.0 and 12.0 being equivocal. There was a concurrent low level of vitamin B12 (cobalamin, <150 pg/ml; RI 290–1500 pg/ml).

The cat initially started treatment with replacement pancreatic enzymes but soon refused to eat any food treated with the enzymatic powder, nor would the cat accept the enzymes packaged within gelatine capsules. The cat also refused to eat raw or lightly cooked pancreas, and the owner, knowing the eventual outcome for untreated cases of EPI is generally poor, was happy to continue without such treatments for as long as the cat had good quality of life. The owner was repeatedly offered further treatments and tests on several occasions, including cobalamin supplementation, ursodeoxycholic acid and sequential fTLI monitoring, but these were declined.

The cat survived for 2 years following the diagnosis of exocrine pancreatic atrophy with fatty replacement, without any pancreatic supplementation (Figure 3). The cat had one further episode of anorexia, which lasted 3

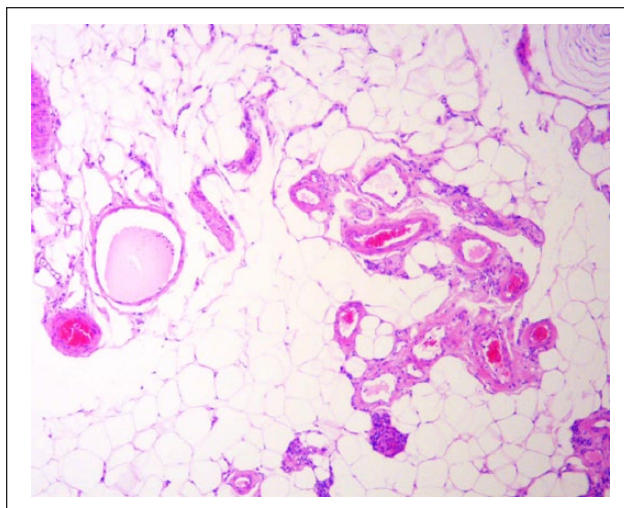


Figure 1 Histological appearance of the pancreatic tissues at initial biopsy. Haematoxylin and eosin-stained section of the pancreas revealing severe parenchymal loss, with residual pancreatic cells and blood vessels widely separated by well-differentiated adipose tissue. Note the pacinian corpuscle in the top right corner; prominent pacinian corpuscles such as this are often seen in feline pancreata (magnification × 40)

days; this responded, as in previous episodes, to antibiotic treatment. After 2 years, owing to the cat's continued weight loss (BCS 1/9) and deteriorating quality of life, the owner elected for euthanasia and gave consent for a partial post-mortem examination. The gross findings at this stage were similar to those seen previously. Samples obtained from the pancreas, liver, mesenteric lymph nodes and small intestines demonstrated similar histological changes to those previously described. However, there was evidence of occasional small islands of residual exocrine pancreatic tissues immediately surrounding the main pancreatic duct; these islands were surrounded and separated by mature fibrous tissues. The remaining pancreatic sample was composed of mature adipose tissues and isolated islets, as in the previous pancreatic biopsy.

Discussion

The most striking feature in this case was the marked and selective fatty replacement of the exocrine pancreas, with relative sparing of the islet cells. Such histological changes have not previously been reported in cats: a study looking at pancreata from 115 cats did not describe fatty replacement of exocrine tissues.³ However, such changes are seen in a well-documented albeit rare entity in human medicine,^{4,5-8} which is known as lipomatosis or pancreatic lipomatous pseudohypertrophy, and is of uncertain aetiology; this condition has not been reported in the veterinary literature to date. The condition occurs in humans with no obesity, diabetes mellitus or history

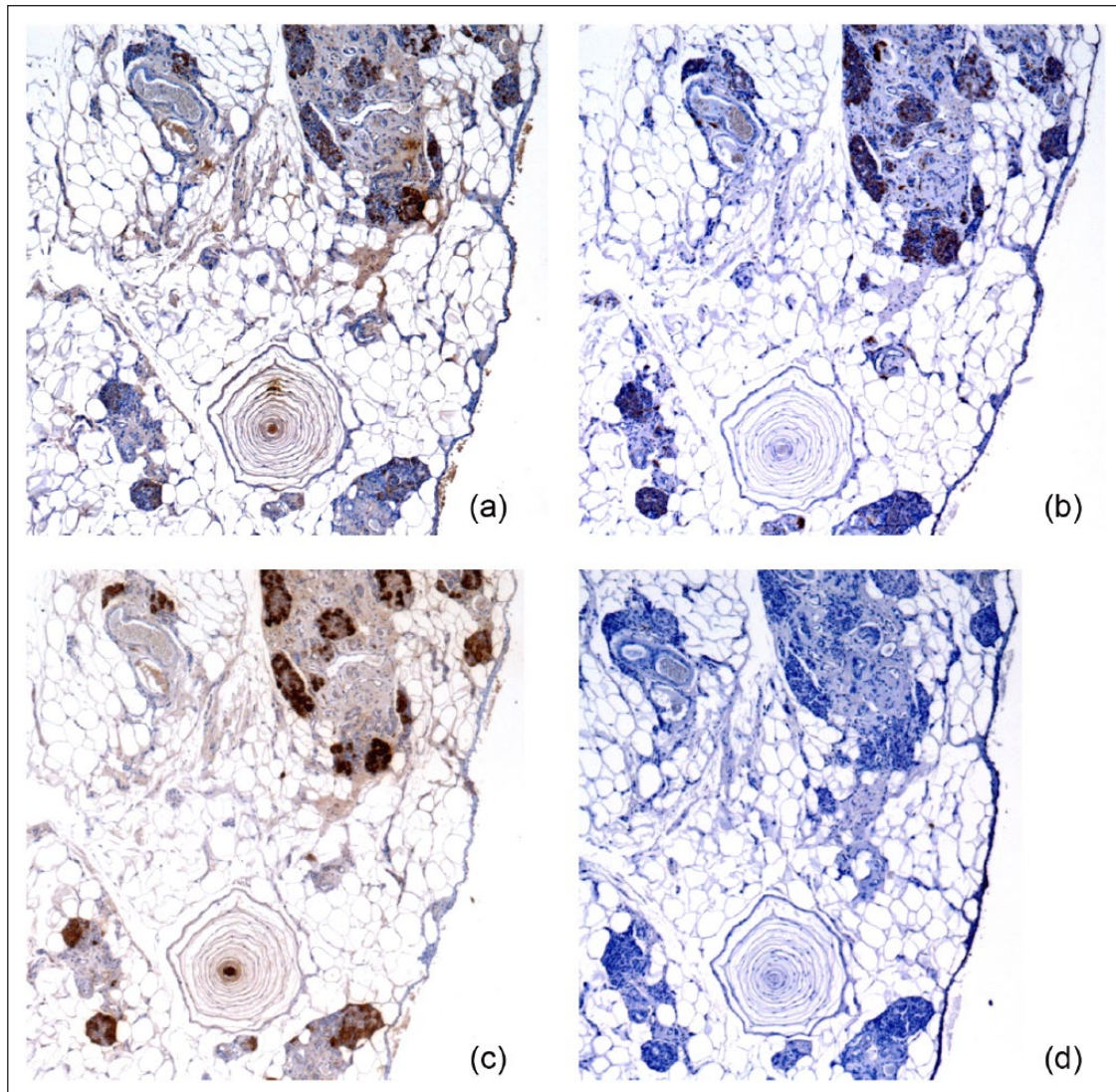


Figure 2 Immunohistochemical staining of the pancreatic tissues with antibodies against various cell markers: (a) chromogranin and (b) synaptophysin are neuroendocrine cell markers, while (c) insulin is more specific for insulin-secreting β -cells within islets and (d) cytokeratin labels epithelial cells. The majority of residual pancreatic tissues demonstrate staining compatible with endocrine islet cells rather than exocrine pancreatic tissues (magnification for all images $\times 40$)



Figure 3 Photograph of the cat >1 year after diagnosis (courtesy, and with permission, of the owners)

of pancreatitis, presenting clinically with signs related to EPI. Macroscopically, the pancreas retains its usual shape, with superficial lobular markings and sometimes moderate enlargement; grossly, the pancreas is pale yellow and rubbery.⁶ These cases have massive replacement of acinar cells by mature adipose tissues, spared islet cells and minimal-to-mild periductal fibrosis. Some cases appear to be caused by bile duct obstruction by calculi but others have been associated with advanced hepatic disease, including bridging fibrosis,^{5,6,8} as seen in the current case, and there is some speculation as to whether the liver disease in some way causes the changes in the pancreas.

The histological appearance of the pancreas in this case also has features in common with some forms of

pancreatic acinar atrophy (PAA). While PAA is well-characterised in German shepherd dogs, rough collies and other canine breeds, there are no well documented cases in cats. At least three feline cases of PAA are discussed but not published in the primary literature,⁹ reported as having pathological findings at necropsy identical to PAA in dogs. Histologically, in canine cases of PAA there is replacement of exocrine tissue with mature fat and relative sparing of the islets, together with an absence of inflammation or fibrosis.¹⁰ However, PAA is likely to be a genetic disorder in the dog and, short of a spontaneous point mutation occurring in this cat, it is difficult to prove in this case. The older age of this cat is not consistent with a developmental defect; that is, pancreatic aplasia or hypoplasia (J Steiner, 2012, personal communication). Furthermore, the gross appearance of the pancreas in this case is not consistent with PAA, where the pancreas is typically decreased in size and misshapen.

The histological changes seen in cats with either acute or chronic pancreatitis (or both) most often involve inflammation, degeneration, fibrosis (chronic), necrosis and oedema (acute),³ but fatty replacement of the pancreas has not been described. Repeated bouts of acute pancreatitis, without the chronic inflammatory component, could, in theory, explain infiltration with fat as opposed to fibrous tissues (J Steiner, 2012, personal communication), but, to our knowledge, this has not been described.

EPI results from a deficiency in pancreatic digestive enzymes occurring when the large functional reserve (approximately 85–90%) of the exocrine pancreas is lost, resulting in maldigestion; therefore, any pathological process resulting in widespread loss of pancreatic parenchyma can result in EPI, and there are several potential underlying causes. In the past, EPI in cats has been considered rare; however, the introduction of assays for fTLI has made the diagnosis easier.¹¹ In this case, the fTLI measurement obtained at the time of pancreatic biopsy was 11.5 µg/l; values between 8.0 and 12.0 µg/l in cats are considered equivocal for EPI. This value implies the presence of some degree of residual exocrine pancreatic function at this point in time, which would be consistent with a 2 year survival time without any enzyme replacement therapy or cobalamin supplementation. There was also histological evidence of small residual islands of exocrine pancreatic tissues immediately surrounding the main pancreatic duct in the post-mortem samples. Repeat evaluation of fTLI should ideally have been performed after 1 month and thereafter at regular intervals to assess the exocrine pancreatic function; however, financial constraints meant this was not possible in this case.

Ideally, a full diagnostic investigation of this case would have included assessment of fTLI and cobalamin with results available prior to performing an exploratory

laparotomy. This would have given an indication of the equivocal and possible contribution of exocrine pancreatic insufficiency to this cat's clinical signs. Abdominal imaging could also have provided additional information about concurrent abdominal pathology and, in particular, hepatic, intestinal and pancreatic abnormalities, with cytological assessment of fine-needle aspiration samples of the liver and lymph nodes. However, in the current case, with the financial and practical limitations, exploratory surgery facilitated the most expedient route to a definitive diagnosis.

Conclusions

There have been four recent case series and studies describing the clinical presentation, diagnosis and treatment of feline EPI,^{11–14} and also a number of individual case reports,^{15–17} but these often include little or no histological description of the pancreas, most likely owing to the fact that as most cases of feline EPI are presumed to be a result of chronic pancreatitis few are biopsied as part of diagnostic investigation. The striking appearance of the pancreas in this case has features in common with some forms of PAA and also with pancreatic lipomatous pseudohypertrophy, a rare entity in humans, which, to date, has not been described in any other species.

Funding The authors received no specific grant from any funding agency in the public, commercial or not-for-profit sectors for the preparation of this case report.

Conflict of interest The authors do not have any potential conflicts of interest to declare.

References

- 1 Rothuizen J, Bunch SE, Charles JA, et al. WSAVA standards for clinical and histological diagnosis of canine and feline liver disease. Philadelphia, PA: Saunders Elsevier, 2006.
- 2 Day MJ, Bilzer T, Mansell J, et al. **Histopathological standards for the diagnosis of gastrointestinal inflammation in endoscopic biopsy samples from the dog and cat: a report from the World Small Animal Veterinary Association Gastrointestinal Standardization Group.** *J Comp Pathol* 2008; 138: S1–S43.
- 3 De Cock HEV, Forman MA, Farver TB, et al. **Prevalence and histopathologic characteristics of pancreatitis in cats.** *Vet Pathol* 2007; 44: 39–49.
- 4 Altinel D, Basturk O, Sarmiento JM, et al. **Lipomatous pseudohypertrophy of the pancreas.** *Pancreas* 2010; 39: 392.
- 5 Anand R, Narula MK, Chaudhary V, et al. **Total pancreatic lipomatosis with malabsorption syndrome.** *Indian J Endocrinol Metab* 2011; 15: 51–53.
- 6 Patel S, Bellon EM, Haaga J, et al. **Fat replacement of the exocrine pancreas.** *AJR Am J Roentgenol* 1980; 135: 843–845.
- 7 Shimada M, Shibahara K, Kitamura Y, et al. **Lipomatous pseudohypertrophy of the pancreas taking the form of huge massive lesion of the pancreatic head.** *Case Rep Gastroenterol* 2010; 4: 457–464.

- 8 Kuroda N, Okada M, Toi M, et al. **Lipomatous pseudohypertrophy of the pancreas: further evidence of advanced hepatic lesion as the pathogenesis.** *Pathol Int* 2003; 53: 98–101.
- 9 Williams DA. **Feline exocrine pancreatic insufficiency.** In: Kirk RW and Bonagura JD (eds). *Current veterinary therapy*. XII ed. Philadelphia, PA: WB Saunders, 1995, pp 732–735.
- 10 Steiner JM. **Exocrine pancreatic insufficiency in the cat.** *Top Comp Anim Med* 2012; 27: 113–116.
- 11 Steiner JM and Williams DA. **Serum feline trypsin-like immunoreactivity in cats with exocrine pancreatic insufficiency.** *J Vet Intern Med* 2000; 14: 627–629.
- 12 Thompson KA, Parnell NK, Hohenhaus AE, et al. **Feline exocrine pancreatic insufficiency: 16 cases (1992–2007).** *J Feline Med Surg* 2009; 11: 935–940.
- 13 Kook PH, Zerbe P and Reusch CE. **Exocrine pancreatic insufficiency in the cat.** *Schweiz Arch Tierheilkd* 2011; 153: 19–25.
- 14 Xenoulis PG, Wooff P, Zoran, et al. **Feline exocrine pancreatic insufficiency: 150 cases. 2012 ACVIM forum research abstracts program.** *J Vet Intern Med* 2012; 26: 765.
- 15 Browning T. **Exocrine pancreatic insufficiency in a cat.** *Aust Vet J* 1998; 76: 104–106.
- 16 Packer RA, Cohn LA, Wohlstadter DR, et al. **D-lactic acidosis secondary to exocrine pancreatic insufficiency in a cat.** *J Vet Intern Med* 2005; 19: 106–110.
- 17 Perry LA, Williams DA, Pidgeon GL, et al. **Exocrine pancreatic insufficiency with associated coagulopathy in a cat.** *J Am Anim Hosp Assoc* 1991; 27: 109–114.