



Spontaneous thoracolumbar hematomyelia secondary to hemophilia B in a cat

Authors: Barnard, Laura R, Leblond, Guillaume, Nykamp, Stephanie G, and Gaitero, Luis

Source: Journal of Feline Medicine and Surgery Open Reports, 1(2)

Published By: SAGE Publishing

URL: <https://doi.org/10.1177/2055116915597239>

BioOne Complete (complete.BioOne.org) is a full-text database of 200 subscribed and open-access titles in the biological, ecological, and environmental sciences published by nonprofit societies, associations, museums, institutions, and presses.

Your use of this PDF, the BioOne Complete website, and all posted and associated content indicates your acceptance of BioOne's Terms of Use, available at www.bioone.org/terms-of-use.

Usage of BioOne Complete content is strictly limited to personal, educational, and non - commercial use. Commercial inquiries or rights and permissions requests should be directed to the individual publisher as copyright holder.

BioOne sees sustainable scholarly publishing as an inherently collaborative enterprise connecting authors, nonprofit publishers, academic institutions, research libraries, and research funders in the common goal of maximizing access to critical research.

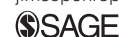

Spontaneous thoracolumbar hematomyelia secondary to hemophilia B in a cat

Laura R Barnard¹, Guillaume Leblond², Stephanie G Nykamp² and Luis Gaitero²

Journal of Feline Medicine and Surgery
Open Reports
1–6

© The Author(s) 2015
Reprints and permissions:
sagepub.co.uk/journalsPermissions.nav
DOI: 10.1177/2055116915597239
jfmsopenreports.com



Abstract

Case summary A 10-year-old neutered male domestic shorthair cat presented for evaluation of acute onset of paraplegia with loss of nociception and thoracolumbar spine hyperesthesia and no history of trauma. Activated partial thromboplastin time (aPTT) was markedly prolonged, and specific coagulation factor testing revealed a factor IX level of 4% of normal activity, confirming the presence of mild hemophilia B. Prior abnormal bleeding had occurred at the time of castration as a kitten, as well as with laceration to a toe. Advanced imaging, including computed tomography (CT) and magnetic resonance imaging (MRI) of the thoracolumbar spine, confirmed the presence of multifocal intradural and intramedullary spinal cord hemorrhage through demonstration of focal ring enhancement on CT and multifocal areas of signal void on gradient echo T2* images on MRI. Despite factor IX supplementation through the use of fresh frozen plasma transfusions and normalization of the aPTT time, the cat's neurological status did not improve. Owing to repeated urinary tract infections, with increasing resistance to antibiotic therapy, the cat was ultimately euthanized. Post-mortem examination showed no evidence of another underlying primary pathology for the hematomyelia.

Relevance and novel information To our knowledge, this case demonstrates the first reported occurrence of spontaneous hematomyelia secondary to hemophilia B in a cat.

Accepted: 11 June 2015

Introduction

Hemophilia is the most common congenital coagulation disorder affecting secondary hemostasis in humans.¹ Two different X chromosome-linked factor deficiencies have historically been described as hemophilia. Hemophilia A, a deficiency in factor VIII, is the most common, with hemophilia B, caused by a deficiency in factor IX, suspected to occur in one-quarter to one-third of human and canine hemophilic populations.^{1,2} Approximately 1 in 30,000 human males are affected by hemophilia B, with an unknown prevalence in dogs and cats.³ Owing to the decreased levels of factor IX, hemophilic B individuals lack a key part of the intrinsic pathway of coagulation and frequently suffer spontaneous bleeding in areas of low tissue factor concentration, such as skeletal muscle and joints.² Following minor injuries or spontaneous, subcutaneous and intramuscular hematomas, hemarthrosis, bleeding gums or hemorrhage in other areas can develop.

Hemophilia B has been previously reported in cats.^{3–5} However, spontaneous intraspinal hemorrhage secondary

to this condition has not been documented. This case report presents the first spontaneous, non-traumatic, multifocal spinal hemorrhage in a cat secondary to hemophilia B.

Case description

A 10-year-old neutered male indoor domestic shorthair cat presented to the Ontario Veterinary College Health Sciences Centre with an acute onset of paraplegia. No history of trauma was reported. As a kitten, the cat tested

¹Ontario Veterinary College Health Sciences Centre, Ontario Veterinary College, University of Guelph, Guelph, ON, Canada

²Department of Clinical Studies, Ontario Veterinary College, University of Guelph, Guelph, ON, Canada

Corresponding author:

Luis Gaitero DVM, Dipl ECVN, Associate Professor and Service Head, Neurology and Neurosurgery, Department of Clinical Studies, Ontario Veterinary College, University of Guelph, 50 Stone Road East, Guelph, ON N1G 2W1, Canada
Email: lgaitero@uoguelph.ca



Creative Commons CC-BY-NC: This article is distributed under the terms of the Creative Commons Attribution-NonCommercial 3.0 License (<http://www.creativecommons.org/licenses/by-nc/3.0/>) which permits non-commercial use, reproduction and distribution of the work without further permission provided the original work is attributed as specified on the SAGE and Open Access page (<http://www.uk.sagepub.com/aboutus/openaccess.htm>).

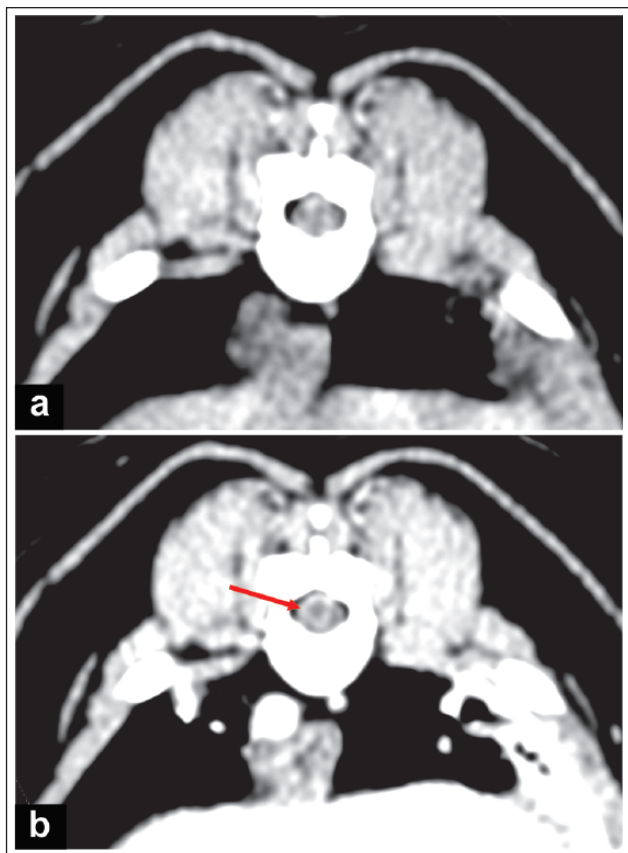


Figure 1 Transverse computed tomography images at T9–T10 intervertebral disc space (a) pre- and (b) postintravenous contrast administration. Precontrast images show multifocal hyperdensities in the spinal cord. The postcontrast image shows ring enhancement (arrow) around the periphery of the hematoma, indicating breach of the blood–central nervous system barrier

positive for feline immunodeficiency virus (FIV), and increased hemorrhage with the development of a large subcutaneous hematoma at the time of castration was reported by the family veterinarian. One year prior to the current episode, the cat presented with a persistently bleeding left pelvic limb toe. Coagulation profiles at that time were markedly prolonged. Activated clotting time was 297 s (normal interval <150 s) and activated partial thromboplastin time (aPTT) was 208 s (normal interval <119 s), while prothrombin time was normal. Factor XII (Hageman factor) function level was normal (81%; normal interval 60–150%). Specific coagulation factor testing revealed a factor IX level of 4% (normal interval 55–167%), with a normal factor VIII level of 120% (normal interval 45–155%), confirming hemophilia B.

On current presentation, physical examination was relatively unremarkable other than a previously detected grade II/VI left-sided systolic heart murmur. Cardiology consultation and echocardiogram had previously been pursued, with no underlying structural or functional

cardiac disease identified, resulting in diagnosis of a physiological murmur. Neurological examination revealed paraplegia with lack of deep pain perception in both pelvic limbs and the tail. Postural reactions in the pelvic limbs and cutaneous trunci reflex were absent bilaterally. Patellar reflexes, withdrawal reflexes and muscle tone were normal in both pelvic limbs. Diffuse moderate spinal pain was present on palpation of the thoracolumbar spine. A lesion was localized to the T3–L3 spinal cord segments. Main differential diagnoses included intervertebral disc herniation, vascular myelopathy (eg, fibrocartilaginous embolic myelopathy or hemorrhage related to hemophilia B), neoplasia and inflammatory/infectious conditions.

A complete blood count and serum biochemistry profile were unremarkable. Coagulation tests revealed an aPTT beyond the readability of the equipment. Despite the poor-to-grave clinical prognosis with loss of nociception, the cat's owner elected to proceed with further diagnostic imaging to better understand what had occurred. Computed tomography (CT) (GE BrightSpeed 16 slice scanner) of the spine was performed immediately after presentation, as magnetic resonance imaging (MRI) was not available at the time of admission. Within the thoracic and lumbar spinal cord there were multifocal poorly margined hyperdense lesions (Figure 1a). Following intravenous administration of contrast (iohexol 300 mgI/ml [Omnipaque; GE Healthcare]) there was focal ring enhancement surrounding the lesion at T9–T10 and patchy enhancement at L1 (Figure 1b). Based on those imaging findings, intramedullary hemorrhage due to hemophilia B was suspected. Additional etiologies such as neoplasia, inflammation (infectious, ie, feline infectious peritonitis, or immune-mediated) or vascular anomalies could not be entirely ruled out with CT alone.

Blood typing (RapidVet-H agglutination test) had been performed prior to dental extractions 2 years prior and blood type A was identified. In an attempt to replace factor IX and to limit the possibility of ongoing or further hemorrhage, therapy with fresh frozen plasma (FFP) was initiated at 10 ml/kg over 6 h. Pain management was also initiated with fentanyl (2 µg/kg/h IV), gabapentin (13 mg/kg PO q8h) and tramadol (3 mg/kg PO q8h). aPTT repeated 8 h following administration of FFP revealed normalization to 114 s. A second dose of FFP (10 ml/kg over 6 h) was administered 36 h after presentation, and aPTT remained within reference interval (at 99–119 s) during the first 3 days. After the first day, a urinary catheter was placed as manual bladder expression and the increased tendency to bleed had resulted in hematuria.

Owing to lack of improvement of clinical signs and to rule out another lesion, an MRI (GE Signa 1.5 Excite II) study of the thoracolumbar spine was performed on

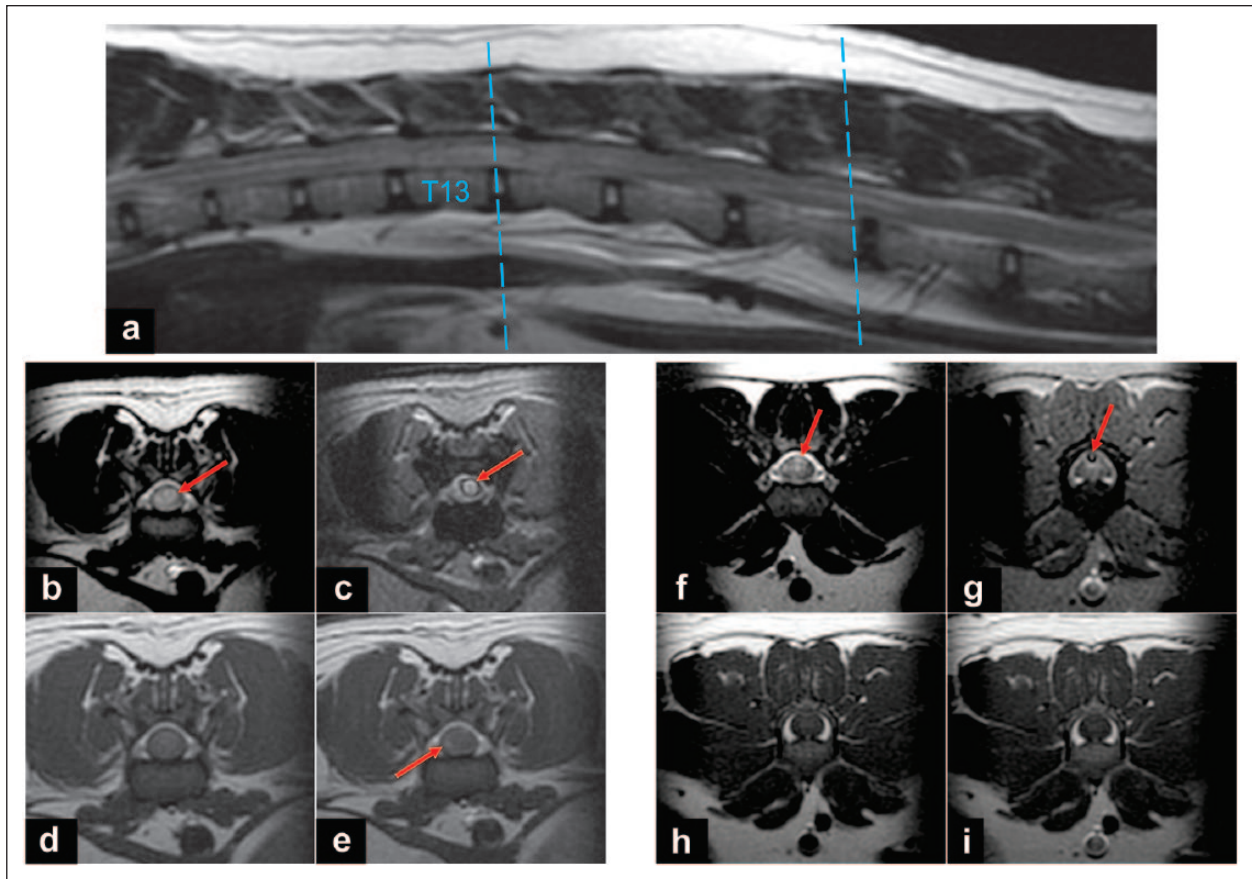


Figure 2 Magnetic resonance images of the thoracolumbar spine. (a) Sagittal T2-weighted image showing multifocal intramedullary hyperintense areas with the lines marking the T13–L1 and L3–L4 intervertebral disc spaces. (b–e) Transverse images taken from the T13–L1 intervertebral disc space; (f–i) L3–L4 intervertebral disc space. (b,f) T2-weighted images with intramedullary mixed hypo- to hyperintense areas marked by arrows. (c,g) T2* image with large signal void peripheral to the hyperintense lesion. (d) T1-weighted image showing the lesion as isointense to the spinal cord. (e) T1-weighted image postcontrast showing mild contrast enhancement marked by the arrow. (h,i) T1-weighted images (h) pre- and (i) postcontrast showing no evidence of contrast enhancement

day 3 following admission. Throughout the mid-thoracic to the cranial lumbar spinal cord, there were multiple small round well-circumscribed lesions that were iso- to hypointense lesions on T1-weighted images (WI), mixed hyper- to hypointense on T2WI and multifocal areas of signal void were seen on gradient echo T2* images (Figure 2). Surrounding these focal lesions there was a poorly defined T2 hyperintensity. Subacute hemorrhage with adjacent vasogenic edema was suspected based on MRI findings.

A urinary culture obtained from the catheter on day 6 showed the presence of a urinary tract infection with *Enterococcus faecium*, which showed susceptibility to amoxicillin/clavulanic acid, ampicillin, enrofloxacin and tetracycline. Treatment was initiated with ampicillin (22 mg/kg IV q8h) and then transitioned to oral amoxicillin (100 mg PO q12h) at the time of discharge. Prazosin (0.5 mg PO q12h) to decrease urethral resistance and bethanechol (5 mg PO q12h) to increase bladder contractility

were added to aid manual bladder expression. Ongoing supportive medications also included buprenorphine (0.02 mg/kg PO q8–12h PRN) to facilitate bladder expression. Owing to difficulties in oral administration phenoxybenzamine was compounded as a transdermal ointment; however, this medication resulted in skin ulceration and was therefore discontinued.

Recurrent hematuria and repeated positive urine cultures were obtained over the next 2 months, with increasing antimicrobial resistance observed. The cat remained paraplegic with lack of nociception throughout this period. The cat was kept on a single level within the house and crated during the day to reduce the risk of further injury and hemorrhage. Recurrent hematuria may have been related to manual expression and the cat's already documented bleeding tendencies. However, final urine culture showed antimicrobial resistance to all antibiotics aside from amikacin and imipenem.

Euthanasia was ultimately elected by the owners owing to concern for the cat's quality of life secondary to lack of neurological improvement, continued difficult bladder expressions and an inability to manage the increasingly resistant urinary tract infections. Post-mortem evaluation was performed. Gross examination revealed evidence of multifocal intradural and intramedullary spinal cord hemorrhages at the level of T7–T9 and T10, each being approximately 1 cm in length. No lesions were observed within the brain and peripheral nerves. Histopathological examination revealed segmental myelomalacia with organizing haemorrhage and axonal degeneration (Figure 3). A left kidney hematoma and a neutrophilic cystitis were also detected.

Discussion

To our knowledge, this is the first report of an acute, non-traumatic hematomyelia secondary to hemophilia B in a cat. Owing to the repeated episodes of abnormal bleeding beginning early in life with castration, a hereditary factor IX deficiency was considered the most likely, although an acquired form through the development of antibodies was not ruled out with further testing. Underlying pathology was not detected in the tissues examined. Intraspinal hemorrhage secondary to hemophilia A has been described in dogs.^{6–8} Other reported underlying causes of spontaneous intraspinal hemorrhage in dogs include *Angiostrongylus vasorum* and *Leishmania infantum* infection, juvenile polyarteritis syndrome, Von Willebrand factor deficiency, vascular malformations, iatrogenic secondary to cerebrospinal fluid collection, brown snake envenomation, intervertebral disc herniation, trauma and neoplasia.^{9–15}

Overall, clinical signs in cats with coagulopathies have previously been considered to be less severe than those of dogs with similar hemostatic abnormalities. Bleeding times for the intrinsic (aPTT) and extrinsic (one-stage prothrombin time) pathways are typically considered to be abnormal when they are 25% above or below the concurrent controls. In a retrospective case series in cats with coagulopathies 9/69 (13%) individuals had prolonged aPTT times with only 3/69 cats reported to have spontaneous bleeding.¹⁶ Not specified in that study was whether Hageman factor deficiency (factor XII) was present in these cats, which results in prolongation of aPTT but not spontaneous bleeding.⁴ Hemophiliac dogs were also mentioned to very commonly present with episodes of spontaneous bleeding, while hemophiliac cats rarely developed detectable spontaneous bleeding.¹⁶ In humans, the severity of hemophilia is found to be inversely proportional to the plasma activity level of the involved protein; a level of $\leq 1\%$ classified as severe vs a level of 5% classified as mild.¹⁷ Based on the human literature, the cat in this case was a mildly to moderately affected individual with a

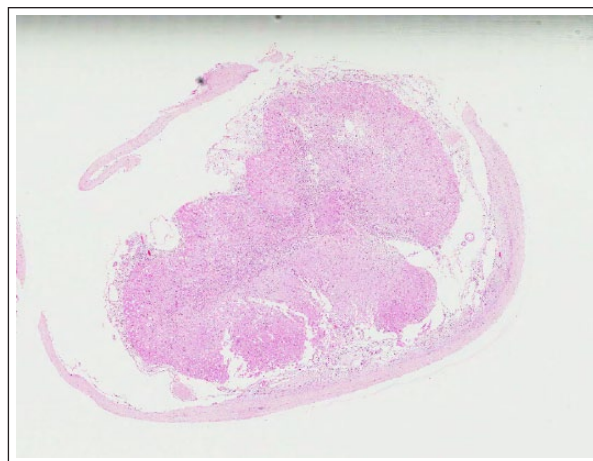


Figure 3 The most severely affected segment of the spinal cord is from approximately T8, which is shown in this image. Approximately 100% of the gray matter on one side and 75% on the other side is completely effaced and replaced by sheets of macrophages containing homogeneous, pale eosinophilic foamy cytoplasm (myelin macrophages). Both the dorsal and ventral horns are affected. Approximately 50% of the remaining neurons within the gray matter are fragmented and pale eosinophilic (necrotic). The white matter is also effaced and primarily replaced with myelin macrophages. In addition, bilaterally within both the dorsal and medial aspects of the lateral funiculus are dilated myelin sheaths, which occasionally contain distended, rounded, eosinophilic axons with poorly discernible cell borders (spheroids), or macrophages with large quantities of foamy cytoplasm and condensed shrunken nuclei (digestion chamber). There are occasional astrocytes with enlarged eosinophilic cytoplasmic bodies and laterally displaced basophilic nuclei (gemistocytic astrocytes) scattered throughout the white matter; occasional multinucleated giant cells are present. The overlying dura mater is two- to three-fold thickened and hypercellular, containing moderate numbers of both macrophages and lymphocytes, and is also expanded by clear spaces (edema). The pia mater is also approximately three-fold expanded with both edema and a similar mononuclear cell infiltrate. There is a loss of the gray and white distinction, with a generalized pallor of the overall neuropil. Large numbers of macrophages and moderate numbers of lymphocytes are present within the dorsal root ganglion on one side. The only viable area within this section of T8 is the dorsal ascending tract

plasma activity level of 4%. Two of the documented bleeding events in this cat's clinical history had an inciting cause. Aside from the intraspinal hemorrhage, no other spontaneous bleeding episodes were documented, which was in keeping with a mildly to moderately affected individual.

Spontaneous central nervous system (CNS) hemorrhage secondary to hemophilia is relatively uncommon, occurring in approximately 2–8% of hemophiliac children.¹⁸ However, it constitutes a significant cause of death in human hemophiliacs.¹⁹ The vast majority of

reported CNS hemorrhages in humans were located intracranially, with approximately 10% occurring within the vertebral canal and/or spinal cord.^{18,19}

Intraspinal hemorrhage, also termed hematomyelia, which is spontaneous and non-traumatic in nature, is a rarely reported but recognized risk in human hemophiliacs.¹⁸ Controversy exists over the most appropriate therapy to employ when faced with an acute case of hematomyelia, and prospective clinical studies are non-existent owing to the rarity of the condition.^{18–20} Medical management with specific factor replacement to limit and prevent ongoing hemorrhage has been recommended in cases where spinal pain and/or mild neurological deficits, such as changes in sensation or mild paresis, are present.¹⁸ Replacement with the specific factor to obtain levels of 80–100% of normal activity prior to any imaging studies and >50% for a minimum of 14 days has been advocated.²¹ Based on review of the human literature, it is unlikely that the FFP administered in this case was adequate to provide this level of FIX in the cat, despite returning aPTT to within the normal reference interval. Reference laboratory results for FIX testing are not available in a timely fashion, which is why aPTT was used in this case. In future cases, it is recommended, where clinically and financially possible, to provide more thorough factor supplementation and to optimize the chance for return of neurological function.

More aggressive therapy in the form of surgical evacuation, in addition to the medical management, has been recommended in cases where there is progressive worsening of neurological signs or where the initial presentation is severe, as in our case.^{22,23} However, the treatment choice between conservative and more aggressive intervention does not seem to act as a prognostic indicator.^{21–23} Owing to the extensive multifocally intramedullary nature of the lesion, surgical decompression of the hemorrhage was not elected in this case. Successful decompressive surgery of an intramedullary hematoma has previously been described in a 4-year-old Jack Russell terrier.¹⁵ However, the hemorrhage in that case was limited to the C4 vertebral level, and no underlying disorder of coagulation was identified.

The FIV-positive status in this individual was not confirmed at the time of hematomyelia, and had only been diagnosed at an early point in life, which could have been confounded by maternal antibodies. However, if FIV infection was present, it could also contribute to the marked prolongation in aPTT noted on presentation for hematomyelia, as well as previously noted for the toe bleed. A published study identified prolongation of aPTT in 55% of cats seropositive for FIV alone, without the presence of factor IX deficiency.²⁴

Ultimately, repeated urinary tract infections with the development of bladder wall necrosis, and

possible expression-induced renal hematoma, led to euthanasia. Urinary tract morbidity is the second most common cause of death in humans with spinal cord injury.^{25,26}

Conclusions

In cats suffering an acute and painful thoracolumbar myelopathy, acute intraspinal hemorrhage due to an underlying coagulopathy such as hemophilia B should be considered. Coagulation testing and advanced diagnostic imaging can provide valuable information for the correct diagnosis and subsequent management of these cases. Where feasible, aggressive factor replacement therapy should be initiated to provide the best opportunity for maintenance and/or return of neurologic function, whether or not surgical intervention is deemed appropriate for the specific case.

Acknowledgments The authors thank Drs J Kylie, R Foster and A Vince for assistance with the postmortem examination and histopathology images. We also thank Dr A Abrams-Ogg for comments on the manuscript.

Funding The authors received no specific grant from any funding agency in the public, commercial or not-for-profit sectors for the preparation of this case report.

Conflict of interest The authors do not have any potential conflicts of interest to declare.

References

- 1 Brooks M. A review of canine inherited bleeding disorders: biochemical and molecular strategies for disease characterization and carrier detection. *J Hered* 1999; 90: 112–118.
- 2 Barr JW and McMichael M. Inherited disorders of hemostasis in dogs and cats. *Top Companion Anim Med* 2012; 27: 53–58.
- 3 Goree M, Catalfamo JL, Aber S, et al. Characterization of the mutations causing hemophilia B in 2 domestic cats. *J Vet Intern Med* 2005; 19: 200–204.
- 4 Dillon AR and Boudreaux MK. Combined factors IX and XII deficiencies in a family of cats. *J Am Vet Med Assoc* 1988; 193: 833–834.
- 5 Maggio-Price L and Dodds WJ. Factor IX deficiency (hemophilia B) in a family of British shorthair cats. *J Am Vet Med Assoc* 1993; 203: 1702–1704.
- 6 Thompson M and Kreeger JM. Acute paraplegia in a puppy with hemophilia A. *J Am Anim Hosp Assoc* 1999; 35: 36–37.
- 7 Stokol T, Parry B, Mansell P, et al. Hemorrhachis associated with hemophilia A in three German shepherd dogs. *J Am Anim Hosp Assoc* 1994; 30: 239–243.
- 8 Joseph SA, Brooks MB, Coccari PJ, et al. Hemophilia A in a German shorthaired pointer: clinical presentations and diagnosis. *J Am Anim Hosp Assoc* 1996; 32: 25–28.
- 9 Wessmann A, Lu D, Lamb CR, et al. Brain and spinal cord haemorrhages associated with *Angiostrongylus vasorum* infection in four dogs. *Vet Rec* 2006; 158: 858–863.

- 10 Caswell JL and Nykamp SG. **Intradural vasculitis and hemorrhage in full sibling Welsh springer spaniels.** *Can Vet J* 2003; 44: 137–139.
- 11 Applewhite AA, Wilkens BE, McDonald DE, et al. **Potential central nervous system complications of von Willebrand's disease.** *J Am Anim Hosp Assoc* 1999; 35: 423–429.
- 12 MacKillop E, Olby NJ, Linder KE, et al. **Intramedullary cavernous malformation of the spinal cord in two dogs.** *Vet Pathol* 2007; 44: 528–532.
- 13 Platt SR, Dennis R, Murphy K, et al. **Hematomyelia secondary to lumbar cerebrospinal fluid acquisition in a dog.** *Vet Radiol Ultrasound* 2005; 46: 467–471.
- 14 Ong RK, Lenard ZM, Swindells KL, et al. **Extradural haematoma secondary to brown snake (*Pseudonaja* species) envenomation.** *Aust Vet J* 2009; 87: 152–156.
- 15 Thibaud JL, Hidalgo A, Benchebroun G, et al. **Progressive myelopathy due to a spontaneous intramedullary hematoma in a dog: pre- and postoperative clinical and magnetic resonance imaging follow-up.** *J Am Anim Hosp Assoc* 2008; 44: 266–275.
- 16 Peterson JL, Couto CG and Wellman ML. **Hemostatic disorders in cats: a retrospective study and review of the literature.** *J Vet Intern Med* 1995; 9: 298–303.
- 17 Nichols TC, Dillow AM, Franck HW, et al. **Protein replacement therapy and gene transfer in canine models of hemophilia A, hemophilia B, von willebrand disease, and factor VII deficiency.** *ILAR J* 2009; 50: 144–167.
- 18 Kiehna EN, Waldron PE and Jane JA. **Conservative management of an acute spontaneous holocord epidural hemorrhage in a hemophiliac infant.** *J Neurosurg Pediatr* 2010; 6: 43–48.
- 19 Friday RY, Pollack IF, Bowen A, et al. **Spontaneous spinal subdural hematoma in a young adult with hemophilia.** *J Natl Med Assoc* 1999; 91: 289–294.
- 20 Arya R, Jain P, Kumar A, et al. **Spontaneous spinal epidural hematoma in an infant.** *J Child Neurol* 2012; 27: 1577–1579.
- 21 Zhong W, Chen H, You C, et al. **Spinal epidural hematoma in a child with hemophilia B.** *Neurol India* 2011; 59: 294–296.
- 22 Henry JB, Messerer M, Thomas V, et al. **Nontraumatic spinal epidural hematoma during pregnancy: diagnosis and management concerns.** *Spinal Cord* 2012; 50: 655–660.
- 23 Bruce-Brand RA, Collieran GC, Broderick JM, et al. **Acute nontraumatic spinal intradural hematoma in a patient on warfarin.** *J Emerg Med* 2013; 45: 695–697.
- 24 Hart SW and Nolte I. **Hemostatic disorders in feline immunodeficiency virus- seropositive cats.** *J Vet Intern Med* 1994; 8: 355–362.
- 25 Siroky MB. **Pathogenesis of bacteriuria and infection in the spinal cord injured patient.** *Am J Med* 2002; 113 Suppl 1A: 67S–79S.
- 26 Garcia Leoni ME and Esclarin De Ruz A. **Management of urinary tract infection in patients with spinal cord injuries.** *Clin Microbiol Infect* 2003; 9: 780–785.