

## **Nasofacial infection in a cat due to a novel bacterium in Neisseriaceae**

Authors: Carr, Susan V, Martin, Patricia A, Keyes, Samantha L, Tong, Lydia J, Talbot, Jessica J, et al.

Source: Journal of Feline Medicine and Surgery Open Reports, 1(2)

Published By: SAGE Publishing

URL: <https://doi.org/10.1177/2055116915597240>

---

BioOne Complete ([complete.BioOne.org](http://complete.BioOne.org)) is a full-text database of 200 subscribed and open-access titles in the biological, ecological, and environmental sciences published by nonprofit societies, associations, museums, institutions, and presses.

Your use of this PDF, the BioOne Complete website, and all posted and associated content indicates your acceptance of BioOne's Terms of Use, available at [www.bioone.org/terms-of-use](http://www.bioone.org/terms-of-use).

Usage of BioOne Complete content is strictly limited to personal, educational, and non - commercial use. Commercial inquiries or rights and permissions requests should be directed to the individual publisher as copyright holder.

---

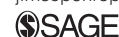BioOne sees sustainable scholarly publishing as an inherently collaborative enterprise connecting authors, nonprofit publishers, academic institutions, research libraries, and research funders in the common goal of maximizing access to critical research.



# Nasofacial infection in a cat due to a novel bacterium in *Neisseriaceae*

Journal of Feline Medicine and Surgery  
Open Reports  
1–5

© The Author(s) 2015  
Reprints and permissions:  
sagepub.co.uk/journalsPermissions.nav  
DOI: 10.1177/2055116915597240  
jfmsopenreports.com



Susan V Carr, Patricia A Martin, Samantha L Keyes, Lydia J Tong, Jessica J Talbot, Gary Muscatello and Vanessa R Barrs

## Abstract

**Case summary** A 2-year-old female spayed domestic shorthair cat was presented for a progressive subcutaneous nasofacial swelling. Histology of biopsy tissue revealed pyogranulomatous inflammation and large numbers of gram-negative capsulated bacterial coccobacilli within macrophages. The isolate was fastidious and grew after 6 days under microaerophilic conditions in a candle jar. The molecular identity of the isolate, from comparative sequence analysis of the 16s rRNA gene, is an as yet to be classified bacterial species within a novel genus of *Neisseria*. Infection resolved after 7 months of antimicrobial therapy with doxycycline and trimethoprim sulfamethoxazole. There has been no further recurrence of clinical signs in a 3 year follow-up period.

**Relevance and novel information** Cats are susceptible to nasofacial infections as a result of traumatic inoculation of environmental bacteria, fungi and protozoa. We report a novel pathogen in the *Neisseriaceae* family, identified by 16 sRNA comparative sequence analysis, as a cause of nasofacial infection in a cat, and its subsequent successful treatment with combination antimicrobial therapy.

**Accepted:** 16 June 2015

## Introduction

Bacteria from clinical specimens can be challenging to identify, not least because a specific set of climatic conditions may be required for primary culture. Little is known about the pathogenic potential of isolates within *Neisseriaceae* to cats. Species of one genus within the family, *Neisseria*, are known to be feline and canine oropharyngeal flora,<sup>1</sup> and have been reported to cause disease, including subcutaneous mandibular inflammatory lesions and pneumonia.<sup>2–4</sup>

## Case description

A 2-year-old female spayed domestic shorthair cat was presented for a subcutaneous swelling over the bridge of the nose (Figure 1). It had been acquired as a kitten from an animal shelter and had been otherwise well. The lesion first occurred 3 months before presentation as a soft swelling, which grew progressively and then became ulcerated. No other abnormalities were detected on physical examination, and parameters on routine haematological and serum biochemistry profiles were within reference intervals. A *Cryptococcus* antigen latex agglutination assay on serum was negative (CALAS;

Meridian Biosciences). A single dose of cefovecin at 1 mg/kg (Convenia; Zoetis) was given subcutaneously and the lesion was biopsied and surgically debulked.

Histological examination of biopsy tissue revealed a dense nodular infiltrate of inflammatory cells, including epithelioid macrophages, plasma cells, neutrophils, aggregates of lymphocytes and reactive stromal cells, consistent with chronic pyogranulomatous inflammation. Gram-negative coccobacilli were identified predominantly within macrophages, in focal areas of inflammation. A scant number of a coagulase-negative *Staphylococcus* species were recovered from aerobic culture of biopsy tissue and were considered contaminants. Anaerobic, fungal and *Mycoplasma* species cultures were negative. The infection was treated

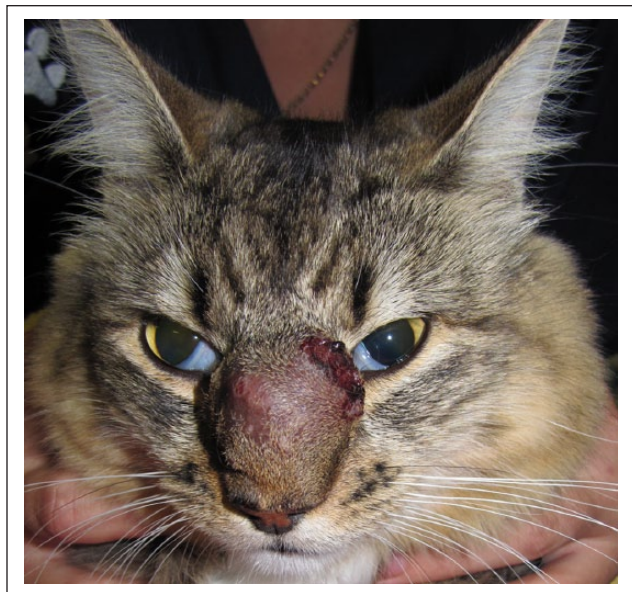Faculty of Veterinary Science, University of Sydney, NSW, Australia

### Corresponding author:

Vanessa R Barrs BVSc(Hons), PhD, MVetClinStud, FANZCVS (Feline Med), Valentine Charlton Cat Centre, Faculty of Veterinary Science, University of Sydney, NSW 2006, Australia  
Email: vanessa.barrs@sydney.edu.au



Creative Commons CC-BY-NC: This article is distributed under the terms of the Creative Commons Attribution-NonCommercial 3.0 License (<http://www.creativecommons.org/licenses/by-nc/3.0/>) which permits non-commercial use, reproduction and distribution of the work without further permission provided the original work is attributed as specified on the SAGE and Open Access page (<http://www.uk.sagepub.com/aboutus/openaccess.htm>).



**Figure 1** Large subcutaneous swelling over the nasal bridge at initial presentation

empirically with amoxicillin–clavulanate (12.5 mg/kg PO q8h for 10 days) (Amoxyclav; Apex Laboratories) and enrofloxacin (6.25 mg/kg PO q24h for 10 days) (Baytril; Bayer).

Although the lesion initially regressed after surgical debulking and antimicrobial therapy, 5 months later the cat was re-presented with a recurrent lesion similar in size to the initial presentation. Enrofloxacin was prescribed again at the same dose rate for 6 weeks with no effect. A second debulking surgery was performed and tissue biopsies were submitted to the Veterinary Pathology Diagnostic Services at the University of Sydney. Histological examination revealed extensive pyogranulomatous inflammation similar to that described in the previous biopsy. Special stains (Gram, Ziehl–Neelsen [ZN], periodic acid–Schiff [PAS] and Giemsa) revealed large numbers of gram-negative coccobacilli within macrophages (Figure 2a,b). These bacteria were ZN negative but had PAS-positive capsules (Figure 2c). Isolation of the bacteria was attempted by inoculating fresh biopsy tissue onto 5% sheep blood agar (SBA) incubated under aerobic, anaerobic and microaerophilic atmospheric conditions (candle jar method) at 37°C. Tissue was cultured aerobically for fungi on Sabouraud dextrose agar containing chloramphenicol and gentamicin at 28°C. After 6 days of incubation, significant growth was only identified on the 5% SBA-inoculated plates incubated microaerophilically. Colonies were non-pigmented, <1 mm in diameter and oxidase positive. Gram staining demonstrated coccobacilli. Subculturing was attempted and growth was initially observed under microaerophilic conditions at

37°C after 4 days of incubation. Subsequent subcultures were unsuccessful, preventing further biochemical characterisation and antimicrobial susceptibility testing.

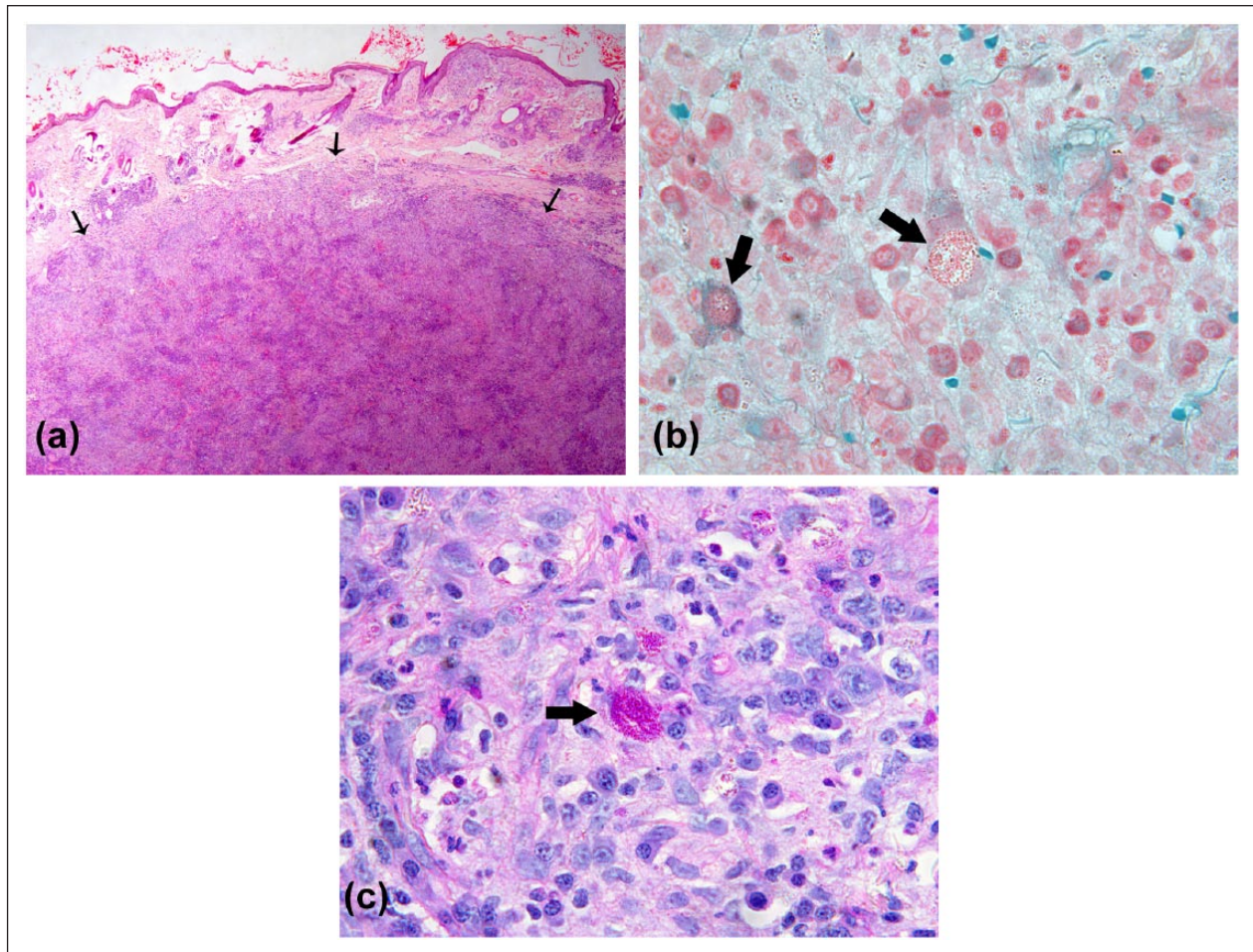
Molecular identification was attempted through PCR amplification of the 1.5 kb bacterial 16s rRNA gene using colony template derived from the 5% SBA microaerophilic subculture and universal 16s rRNA primers (forward 5' AGAGTTTGATCCTGGCTCAG 3'; reverse 5' TACGGYTACCTTGTTACGACTT 3') and sequencing the resultant purified PCR product.<sup>5</sup> The resulting 16s rRNA gene sequence was compared with the GenBank database, using the Basic Local Alignment Search Tool (<http://blast.ncbi.nlm.nih.gov>) to establish identification with a species ( $\geq 99\%$  sequence homology) or genus level ( $\geq 97\%$  sequence homology).<sup>5</sup> The resulting sequence of the full-length 16s rRNA gene of this bacterium (*Neisseriaceae* bacterium 1359/10; GenBank accession number KJ643423) had the highest matched homology (98.8%) with an isolate (Lie5-2) from an unclassified, unnamed novel genus within the *Neisseriaceae* family (GenBank accession number GU199453.1). These and other closely related sequences were edited using BioEdit Sequence Alignment Editor version 7.2.5 (Ibis Biosciences). Alignment of homologous positions on the multiple sequences were performed using the BioEdit ClustalW algorithm.<sup>6</sup> Phylogenetic trees were constructed (Figure 3), with Mega 6 using the maximum likelihood discrete data method (Kamuri model G1, 1000 replicates).<sup>7</sup>

The cat was treated empirically with doxycycline 6.25 mg/kg PO q12h (Doxycycline; Apex Laboratories), and trimethoprim sulfamethoxazole 5mg/kg PO q12h (Tribrissen; Jurox) for 4 weeks initially, and then with doxycycline monotherapy for a further 4 months at 5 mg/kg PO q24h. During this time the lesion gradually resolved. Two weeks after doxycycline was discontinued, the lesion began to recur and dual therapy with doxycycline and trimethoprim sulfamethoxazole therapy at the initial doses was recommenced for a further 2 months, during which time the lesion resolved. There has been no clinical recurrence of the lesion at the time of writing, 3 years after antimicrobial therapy was stopped.

## Discussion

In this report we describe a recurrent pyogranulomatous lesion on the nasal bridge of a cat due to a fastidious gram-negative bacterium. Based on phylogenetic analysis of the sequenced 16s RNA gene the isolate from this cat (Genbank accession number KJ6434243) is a novel, as yet unclassified, genus and species within the *Neisseriaceae* family (Figure 3). There is limited information about the closest isolates to this bacterium; Lie5-2 (Genbank accession number GU199453), T60-Ps25C-56 (Genbank



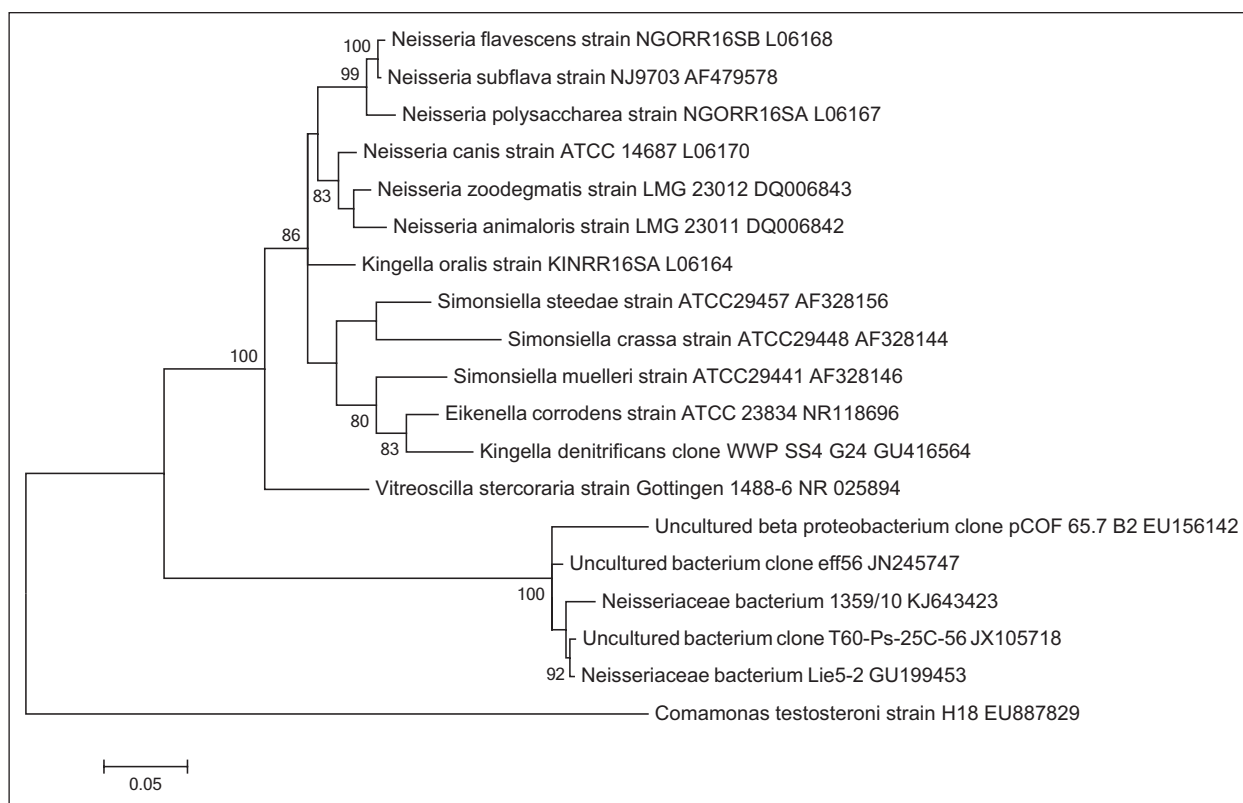


**Figure 2** (a) Section of skin showing marked focally expansile nodular non-encapsulated inflammatory infiltrate effacing and expanding the deep dermis, with small satellite nodules of inflammation in the superficial dermis (arrows). Haematoxylin and eosin stain (× 40). Bacteria are demonstrated with special stains. (b) Dense histiocytic and plasmacytic inflammation including multiple macrophages containing large numbers of intracytoplasmic gram-negative coccobacilli (arrows). Gram-Twort stain (× 400). (c) Macrophages containing large numbers of the same organisms with periodic acid-Schiff-positive capsule (arrow) (× 400)

accession number JX105718) and uncultured  $\beta$  proteobacterium clone (Genbank accession number EU156142) have been isolated from aquatic environments in diverse geographical locations, including a lake in China, an ornamental fish aquarium in Greece, and a thermal spring in the USA, respectively.<sup>8,9</sup> As the cat had access to a garden adjacent to a canal, traumatic inoculation is a possible route of entry for this bacterium, if its environmental niche is aquatic. Cats are also susceptible to nasofacial infections after traumatic inoculation of environmental saprophytes from a cat scratch. Infection and disease may occur in immunocompetent individuals when the cutaneous barrier is breached and there is a sufficient inoculum to establish an infection. Other saprophytic organisms reported to cause cutaneous and subcutaneous nasofacial infections in cats include *Corynebacterium pseudotuberculosis*, *Mycobacterium avium*

subsp *avium*, *Nocardia nova* and the algae *Prototheca wickerhamii* and *Prototheca zopfii*, and a variety of fungal species, including those that cause phaeohyphomycoses (eg, *Alternaria* species) and dimorphic fungi (eg, *Cryptococcus neoformans*, *Sporothrix schenckii*).<sup>10</sup>

As illustrated in Figure 3, the isolate in this report is phylogenetically distant from more commonly described *Neisseriaceae* opportunistic pathogens, including *Neisseria*, *Simonsiella*, *Eikenella* and *Kingella* species that are normal flora of the feline, canine or human oral cavity.<sup>1,11,12</sup> Owing to their location, *Neisseria* species have been identified as contaminants of bite wounds from dogs or cats.<sup>13</sup> It seems unlikely, based on the phylogenetic analysis that the isolate from the cat of this report resides in the feline oral cavity. The nasal bridge area is an uncommon site for cat bites, but is a common site for cat scratches.<sup>14</sup>



**Figure 3** Maximum likelihood phylogenetic tree of genera in *Neisseriaceae*, based on 16S rRNA gene sequences and showing the position of the isolate from a nasofacial infection in a cat (*Neisseriaceae* bacterium KJ643423). Species and strain are listed, followed by GenBank number

Previously reported subcutaneous mandibular lesions caused by *Neisseria animaloris* and *Neisseria canis* had a similar clinical presentation to this case.<sup>2,3</sup> However, both isolates were susceptible to most commonly used antibiotic agents in vitro and treatment with amoxicillin–clavulanate was effective after 3 weeks of antibiotic therapy. Unfortunately, antimicrobial susceptibility testing could not be performed for the isolate in the current study owing to loss of viability. This isolate could only be grown under microaerophilic laboratory conditions. Although *Neisseriaceae* are aerobes, a partial carbon dioxide environment enhances primary growth for some medically important members including *Neisseria gonorrhoea* and *Neisseria meningitidis*.<sup>15</sup>

## Conclusions

A novel genus and species within the *Neisseriaceae* family was identified as the cause of a pyogranulomatous nasofacial subcutaneous lesion in a cat. The isolate was a fastidious gram-negative bacterium that grew under microaerophilic conditions. Comparative sequence analysis of the 16S rRNA gene is useful for rapid identification of bacterial isolates. The lesion resolved after prolonged antimicrobial therapy with doxycycline and trimethoprim sulfoximazole.

**Acknowledgements** We would like to thank Dr Eloise Koelmeyer for case contribution and management.

**Funding** The authors received no grant from any funding agency in the public, commercial or not-for-profit sectors for the preparation of this case report.

**Conflict of interest** The authors do not have any potential conflicts of interest to declare.

## References

- 1 Sturgeon A, Pinder S, Costa M, et al. **Characterization of the oral microbiota of healthy cats using next-generation sequencing.** *Vet J* 2014; 201: 223–229.
- 2 Baral RM, Catt MJ, Soon L, et al. **Successful treatment of a localised CDC Group EF-4a infection in a cat.** *J Feline Med Surg* 2007; 9: 67–71.
- 3 Cantas H, Pekarkova M, Kippenes HS, et al. **First reported isolation of *Neisseria canis* from a deep facial wound infection in a dog.** *J Clin Microbiol* 2011; 49: 2043–2046.
- 4 Foster SF and Martin P. **Lower respiratory tract infections in cats: reaching beyond empirical therapy.** *J Feline Med Surg* 2011; 13: 313–332.
- 5 Drancourt M, Bollet C, Carlioz A, et al. **16S ribosomal DNA sequence analysis of a large collection of environmental and clinical unidentifiable bacterial isolate.** *J Clin Microbiol* 2000; 38: 3623–3630.

- 6 Hall TA. **BioEdit: a user-friendly biological sequence alignment editor and analysis program for Windows 95/98/NT.** *Nucl Acid Symp Ser* 1999; 41: 95–98.
- 7 Tamura K, Peterson D, Peterson N, et al. **MEGA5: molecular evolutionary genetics analysis using maximum likelihood, evolutionary distance, and maximum parsimony methods.** *Mol Biol Evol* 2011; 28: 2731–2739.
- 8 Vlahos N, Kormas KA, Pachiadaki MG, et al. **Changes of bacterioplankton apparent species richness in two ornamental fish aquaria.** *Springerplus* 2013; 2: 66.
- 9 Hall JR, Mitchell KR, Jackson-Weaver O, et al. **Molecular characterization of the diversity and distribution of a thermal spring microbial community by using rRNA and metabolic genes.** *Appl Environ Microbiol* 2008; 74: 4910–4922.
- 10 Malik R, Vogelnest L, O'Brien CR, et al. **Infections and some other conditions affecting the skin and subcutis of the naso-ocular region of cats – clinical experience 1987–2003.** *J Feline Med Surg* 2004; 6: 383–390.
- 11 Hedlund BP and Staley JT. **Phylogeny of the genus *Simonsiella* and other members of the Neisseriaceae.** *Int J Syst Evol Micr* 2002; 52: 1377–1382.
- 12 Dewhirst FE, Chen CK, Paster BJ, et al. **Phylogeny of species in the family Neisseriaceae isolated from human dental plaque and description of *Kingella oralis* sp. nov [corrected].** *Int J Syst Bacteriol* 1993; 43: 490–499.
- 13 Talan DA, Citron DM, Abrahamian FM, et al. **Bacteriologic analysis of infected dog and cat bites.** *N Engl J Med* 1999; 340: 85–92.
- 14 Malik R, Norris J, White J, et al. **'Wound cat'.** *J Feline Med Surg* 2006; 8: 135–140.
- 15 Martin JE, Armstrong JH and Smith PB. **New system for cultivation of *Neisseria gonorrhoea*.** *Appl Microbiol* 1974; 27: 802–805.