



Cutaneous squamous cell carcinoma manifesting as follicular isthmus cysts in a cat

Authors: Layne, Elizabeth A, and Graham, Melissa

Source: Journal of Feline Medicine and Surgery Open Reports, 2(1)

Published By: SAGE Publishing

URL: <https://doi.org/10.1177/2055116915625356>

BioOne Complete (complete.BioOne.org) is a full-text database of 200 subscribed and open-access titles in the biological, ecological, and environmental sciences published by nonprofit societies, associations, museums, institutions, and presses.

Your use of this PDF, the BioOne Complete website, and all posted and associated content indicates your acceptance of BioOne's Terms of Use, available at www.bioone.org/terms-of-use.

Usage of BioOne Complete content is strictly limited to personal, educational, and non - commercial use. Commercial inquiries or rights and permissions requests should be directed to the individual publisher as copyright holder.

BioOne sees sustainable scholarly publishing as an inherently collaborative enterprise connecting authors, nonprofit publishers, academic institutions, research libraries, and research funders in the common goal of maximizing access to critical research.



Cutaneous squamous cell carcinoma manifesting as follicular isthmus cysts in a cat

Journal of Feline Medicine and Surgery
Open Reports
 1–6

© The Author(s) 2016
 Reprints and permissions:
sagepub.co.uk/journalsPermissions.nav
 DOI: 10.1177/2055116915625356
jfmsopenreports.com



Elizabeth A Layne¹ and Melissa Graham²

Abstract

Case summary A 9-year-old spayed female domestic shorthair cat was examined for swelling of the right upper lip. The cat had been receiving oral ciclosporin A for eosinophilic plaques. The swelling appeared clinically and cytologically consistent with an abscess; exudate was cultured and treatment consisted of antibiotic therapy and surgical curettage. Five months of antibiotic therapy with three separate surgical treatments resulted in minimal improvement; three separate biopsy samples demonstrated epithelial cysts with severe dermal inflammation. Swelling and drainage of purulent material from the affected lip persisted and progressed to involve the left upper lip. Euthanasia was elected 13 months after initial examination due to disease progression. On necropsy, histopathology demonstrated multiple isthmus cysts intermixed with squamous cell carcinoma (SCC).

Relevance and novel information The clinical and histopathologic features were unusual for feline cutaneous SCC. The cystic nature and lack of epidermal involvement suggest the tumor arose from non-epidermal squamous cells such as follicular isthmus or ductal epithelium. There is a pattern of SCC recognized in human renal transplant patients with features of epidermal inclusion cysts. These features have not been previously reported in SCC from a cat.

Accepted: 9 December 2015

Introduction

Squamous cell carcinoma (SCC) accounts for 10–15% of all skin tumors in cats.^{1,2} It occurs most commonly on the sparsely haired non-pigmented skin of the pinnae, eyelids and nasal planum in older cats (mean age 12 years).² The proposed pathogenesis involves chronic ultraviolet (UV) light exposure and subsequent keratinocyte damage that progresses from benign actinic keratosis to non-invasive malignant SCC confined to the epidermis, or to invasive, and rarely metastatic, SCC.³ Lesions usually begin with erythema and scale, or crusted erosions, that can progress to severe ulcerations or proliferative plaques and nodules.⁴ A non-UV light-induced form of SCC, SCC in situ, is also recognized in cats. SCC in situ (also called Bowenoid carcinoma in situ or Bowen's disease) is confined to the epidermal and follicular epithelium without invasion of the dermis.⁵ The purpose of this case report is to describe a cat with an atypical clinical and histologic presentation of cutaneous SCC.

Case description

A 9-year-old spayed female domestic shorthair cat was examined for a 3 month history of firm swelling of the right upper lip (Figure 1). The lesion was reported to be not painful or pruritic. Previous diagnostics included fine-needle aspiration, impression cytology and trichogram; no definitive diagnosis was made. Serum chemistry, complete blood count and total thyroxine tests were within the reference intervals (RIs) 2 months prior to

¹Department of Medical Sciences, School of Veterinary Medicine, University of Wisconsin-Madison, Madison, WI, USA

²Department of Pathobiological Sciences, School of Veterinary Medicine, University of Wisconsin-Madison, Madison, WI, USA

Corresponding author:

Elizabeth A Layne DVM, Department of Medical Sciences, School of Veterinary Medicine, University of Wisconsin-Madison, 2015 Linden Drive, Madison, WI 53706, USA
 Email: elayne@vetmed.wisc.edu



Creative Commons Non Commercial CC-BY-NC: This article is distributed under the terms of the Creative Commons

Attribution-NonCommercial 3.0 License (<http://www.creativecommons.org/licenses/by-nc/3.0/>) which permits non-commercial use, reproduction and distribution of the work without further permission provided the original work is attributed as specified on the SAGE and Open Access pages (<https://us.sagepub.com/en-us/nam/open-access-at-sage>).

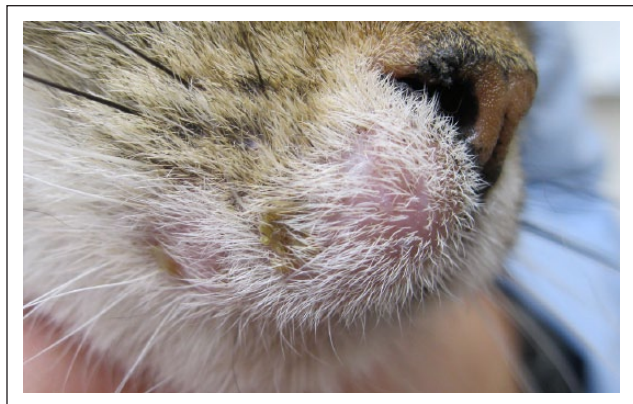

Figure 1 Right upper lip swelling at initial examination

referral examination. The cat had been receiving ciclosporin A modified (Atopica for Cats; Novartis) 2 mg/kg q48h for eosinophilic plaques in the inguinal region diagnosed 2 years prior via biopsy performed by a board-certified veterinary dermatologist. Those lesions were in remission at the time of referral examination. The cat was acquired as a stray kitten and lived exclusively indoors in a multi-cat household. There was no history of trauma and no other cats had skin abnormalities. The cat was fed a commercial prescription urinary health diet, owing to another cat's medical needs.

On physical examination the sole abnormality was a 2 cm × 3 cm firm swelling of the right upper lip adjacent to the nasal philtrum; the overlying skin was moderately erythematous with two patches of yellow serocellular crusts. Copious yellow purulent fluid was easily expressed from beneath the crusts and through a draining tract on the buccal mucosal side of the lip. Cytological examination of this fluid revealed neutrophils, macrophages, lymphocytes and intracytoplasmic coccoid bacteria that were too numerous to count. Wood's lamp and trichogram were negative for dermatophyte fluorescence and *Demodex* species mites, respectively. A presumptive diagnosis of abscess was made; a swab of the purulent fluid was submitted for aerobic bacterial culture and susceptibility. *Pasteurella multocida* and coagulase negative *Staphylococcus* species were isolated, which are normal flora of the feline oral cavity and skin.^{6,7} Based on broad antibiotic susceptibility, cefovecin (Convenia; Zoetis) was administered 8 mg/kg by subcutaneous injection in two doses, 2 weeks apart. There was concern that immunosuppression might have been preventing resolution of the abscess so ciclosporin administration was decreased to every third day.

At follow-up examination 4 weeks later there was a noticeable reduction in swelling size and overlying skin erythema; however, purulent fluid could still be expressed from the lesion. A third cefovecin injection was administered and surgical curettage of the region

was recommended, owing to suspicion of a foreign body (eg, cat claw, whisker fragment) perpetuating the abscess.

Surgical exploration under general anesthesia was performed by the referring veterinarian; it did not reveal a focus of fluid for drainage. A 2 mm punch biopsy of the affected area was obtained and cefovecin injection repeated (culture was not repeated). Histopathology revealed moderate-to-severe chronic perivascular to interstitial lymphoplasmacytic and mastocytic dermatitis. No evidence of neoplasia, foreign material or etiologic agents was detected. These findings supported the presumptive diagnosis of a chronic abscess or cellulitis. A more aggressive surgical approach was recommended but declined. The site was treated with warm compresses daily followed by manual expression of the fluid and a 6 week course of cefovecin.

At month 4 after initial referral presentation oral radiographs and a dental prophylaxis were performed by a second primary care veterinarian. The right upper lip lesion was unchanged, with purulent fluid easily expressed from multiple draining tracts. Surgical exploration under general anesthesia from the buccal mucosal surface was performed and, again, no foreign body or focus of purulent fluid was found. Histologic examination of a wedge tissue biopsy specimen from the buccal mucosal surface revealed multiple epithelial cysts with focal neutrophilic inflammation and mild-to-moderate interstitial lymphoplasmacytic inflammation. This was an unusual finding as the cystic structures did not appear to be hair follicles (ie, devoid of hair shafts and adnexae). It was hypothesized that a low-grade bacterial infection was the cause of intraluminal cystic neutrophilic inflammation. The working diagnosis was changed from abscess or cellulitis to epithelial cysts with secondary infection. Complete resection of the area was recommended to remove all affected tissue. Further treatment was declined at that time. Oral ciclosporin was discontinued for several reasons: the original eosinophilic lesions were resolved and in remission for >6 months, the cat was resisting medication administration, presumably because of facial pain, and although the dose was low, ciclosporin is an immunosuppressive drug which might have contributed to delayed resolution of infection.

Nine months after initial presentation the right upper lip swelling had continued to enlarge with severe exudation and crusting (Figure 2). General anesthesia was induced to facilitate wide excision of the affected skin and closure with an advancement flap (Figure 3). One subcutaneous meloxicam injection (Metacam; Boehringer-Ingelheim Vetmedica) 0.3 mg/kg and oral administration of injectable buprenorphine solution 0.02 mg/kg q8h for 5 days was administered for analgesia. Histologic examination of excised tissue demonstrated

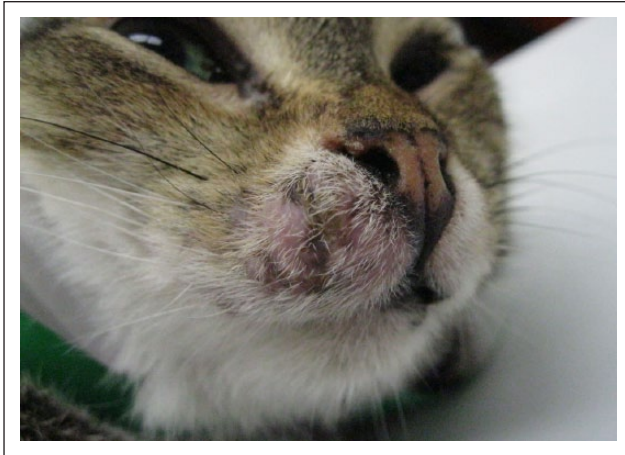


Figure 2 Right upper lip swelling 9 months after initial examination

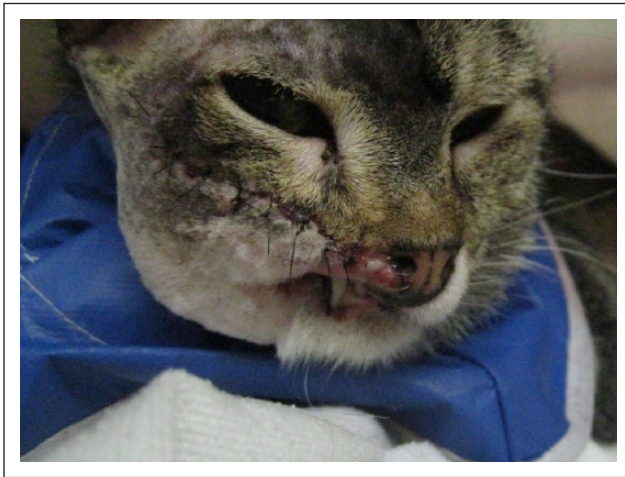

Figure 3 Right upper lip after wide surgical excision

multiple cysts lined by keratinizing stratified squamous epithelium containing laminated keratin, basophilic debris, individual keratinocytes, and lymphocytes and plasma cells (Figure 4). There was follicular displacement and rupture in some sites with associated severe neutrophilic inflammation. These findings were consistent with the previous biopsy; it was hoped that surgical resection had removed all of the cystic tissue. No etiology for epithelial cyst development was evident.

Eleven months after initial presentation and 2 months after wide surgical excision the cat was examined for swelling of the left upper lip. The previously affected right upper lip surgical site appeared to have healed normally; the left upper lip adjacent to the nasal philtrum was mildly thickened, with a 2 mm focus of purulent exudate. Cytologic examination of exudate revealed neutrophils and coccoid bacteria that were too numerous to count; bacterial culture and susceptibility was obtained. It was hypothesized that the cause of this

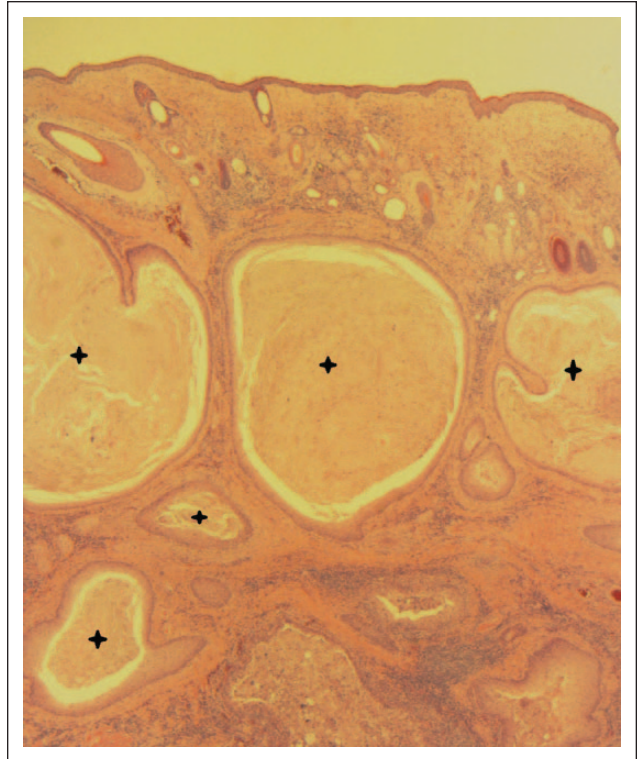


Figure 4 Section of the right upper lip. Multiple epithelial cysts (crosses) invading the dermis, with surrounding severe lymphoplasmacytic, neutrophilic, and mastocytic dermatitis (hematoxylin and eosin $\times 2$)

swelling and purulent exudate was an abscess due to lower left canine tooth impingement on the left upper lip from altered anatomy caused by previous dental procedures and the facial advancement flap surgery. Multi-drug resistant methicillin-resistant *Staphylococcus pseudintermedius* was isolated; chloramphenicol oral suspension 20 mg/kg q12h was prescribed for 30 days. Dental surgery was performed to correct the impingement. Oral administration of injectable buprenorphine solution 0.02 mg/kg q8h 5 days was used for analgesia.

Two months after the dental procedure and 13 months after initial examination the left upper lip swelling had continued to enlarge, without response to chloramphenicol and dental surgery. The previously excised right upper lip area had also developed new swelling and erosions. Copious serous discharge from the left eye was also present. The lip swelling resulted in deviation of the nasal planum (Figure 5). The cat had lost 1 kg of body weight in the previous 2 months. Hyperglobulinemia (5.9 g/dl; RI 2.3–3.8 g/dl) and hypernatremia (159 mmol/l; RI 148–157 mmol/l) were detected by serum chemistry (Ortho Clinical Diagnostics; model VITROS 5,1 FS). These abnormalities were attributed to chronic inflammation and infection of epithelial cysts and decreased water intake, respectively.

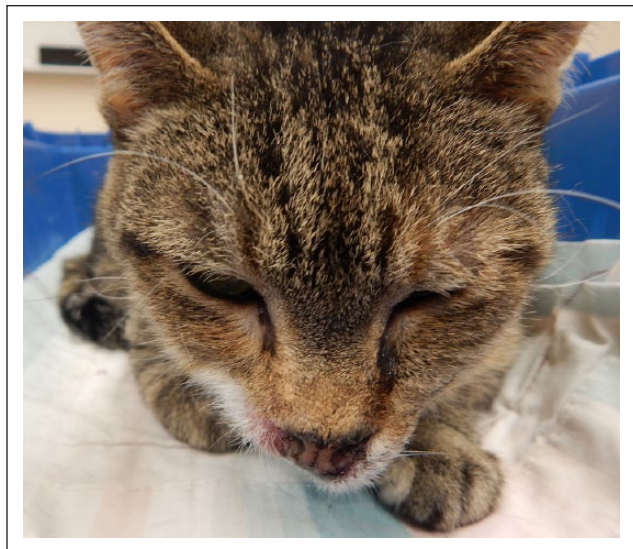

Figure 5 Thirteen months after initial examination, prior to euthanasia, demonstrating deviation of the nasal philtrum to the cat's right

Thoracic radiographs revealed mild cardiomegaly with no evidence of pulmonary metastatic disease. A computed tomography scan of the skull demonstrated moderate-to-marked thickening of nasal subcutaneous tissues and labial and buccal soft tissues with heterogeneous contrast enhancement. Areas of hypoattenuation without contrast enhancement were present centrally in the nasal subcutaneous tissues. No discrete mass, bony lysis or obvious neoplastic process was evident, though cystic areas were identified. There was moderate-to-marked enlargement of the mandibular and retropharyngeal lymph nodes. Owing to disease progression with no definitive diagnosis euthanasia was elected.

Gross necropsy findings were consistent with clinical and radiological findings. Locally extensive subcutaneous swelling of both sides of the upper lip with exudate consistent with an abscess was the major gross abnormality of the skin. Histopathology of the affected skin again revealed epithelial cysts. These were numerous and variably sized, replacing the dermis and extending to and invading underlying skeletal muscle. The cysts were lined by 1–6 cell layers of stratified squamous keratinizing epithelium lacking a distinct granular layer. The cysts contained variable numbers of neutrophils, amphophilic globular-to-lamellar material, well-differentiated squamous epithelial cells and basophilic granular material consistent with mineralization. The lack of keratohyalin granules and well-differentiated squamous cells suggested these were follicular isthmus cysts.

In addition to the cysts, there were numerous nests and nodules composed of neoplastic polygonal cells demonstrating aberrant keratinocyte differentiation, moderate anisocytosis and anisokaryosis, and necrosis.

Some of these nodules formed keratin pearls. These features were compatible with SCC (Figure 6). Both cysts and neoplastic nodules were surrounded by desmoplasia and fibrosis. There was marked lymphoplasmacytic, neutrophilic and mastocytic dermatitis and myositis. The overlying epidermis was focally acanthotic and had orthokeratotic hyperkeratosis with few intracorneal pustules. There were no features of cytologic atypia typically associated with SCC in the overlying epidermis. Regional lymph nodes, while enlarged, demonstrated no evidence of metastasis; enlargement was attributed to lymphoid hyperplasia and suppurative lymphadenitis. No evidence of metastatic SCC was detected in the lungs, liver, heart or kidneys.

Discussion

To our knowledge, this is the first published report of feline SCC arising from non-epidermal squamous epithelium with a cystic presentation. One veterinary case report describes draining tracts associated with SCC; however, the epidermis was affected in the usual pattern.⁸ There is also anecdotal mention of rare SCC cases arising from follicular cysts without epidermal involvement.⁹ Physician dermatopathologists have reported on a rare subset of SCC termed infundibular or infundibulocystic SCC.^{10,11} In some of these cases the overlying epidermis was not affected.¹⁰

It is recognized that human and feline renal transplant patients are predisposed to the development of certain neoplasms, including SCC.^{12,13} A subset of those tumors in people has been described, with unique features including epidermal inclusion cyst-like structures.¹³ The pathogenesis of neoplasia in transplant patients is not clear. Theories include chronic immunosuppression leading to decreased immune surveillance and destruction of early malignant cells, increased susceptibility to infection and direct effects on T cells.¹² The cat in this report was receiving ciclosporin for eosinophilic dermatitis. The dose and frequency were lower than that used for post-transplant therapy; however, it is impossible to know if ciclosporin therapy contributed to the development of this unusual variant of SCC.

The involvement of feline papillomavirus (*Felis catus* papillomavirus [FcaPV]) would have been worth considering in this case. FcaPV has recently been causally linked to Bowenoid carcinoma in situ, and there is increasing evidence for involvement with non-UV-induced SCC.¹⁴ Viral cytopathology was not detected in the tissues examined in this report; however, neither immunohistochemical nor molecular techniques were available for further examination.

Feline immunodeficiency virus (FIV) and feline leukemia virus (FeLV) infections have been reported in association with SCC, specifically Bowenoid carcinoma in situ.^{5,9} The FIV and FeLV status of this cat was

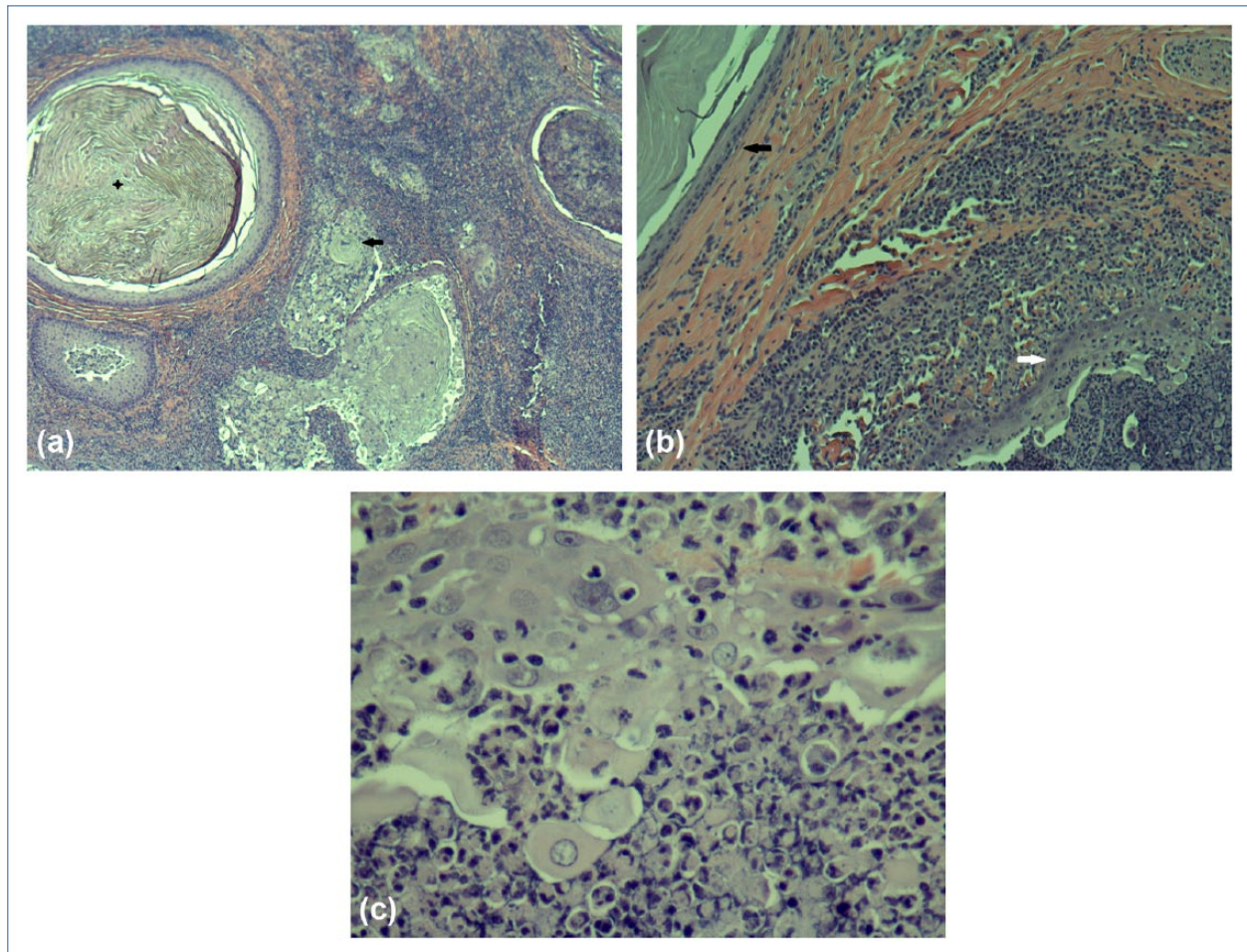


Figure 6 Sections of the right upper lip. (a) Nests of squamous cell carcinoma (SCC; arrow) adjacent to epithelial cyst (cross) (hematoxylin and eosin $\times 4$). (b) Juxtaposition of epithelial cyst (black arrow), demonstrating squamous keratinization, and SCC (white arrow), demonstrating aberrant keratinocyte differentiation and necrosis (haematoxylin and eosin $\times 10$). (c) Detail of SCC image in (b) (haematoxylin and eosin $\times 40$)

unknown. While histopathologic features of Bowenoid carcinoma in situ were absent, it is possible that immunosuppression from FIV and/or FeLV infection might have contributed to development of SCC.

Conclusions

This report describes the clinical and histopathologic findings of an unusual case of feline cutaneous SCC. While the common presentation of feline cutaneous SCC is well recognized in the veterinary literature, it can manifest in an atypical manner. While cytologic evidence typical of neoplasia may not be noted on histopathology, invasive morphology with lack of response to rational therapy should prompt reconsideration of all differential diagnoses.

Acknowledgements We thank Drs Karen Moriello, Melissa Behr and Daniel Bennett for slide review and manuscript input.

Funding The authors received no financial support for the research, authorship, and/or publication of this article.

Conflict of interest The authors declared no potential conflicts of interest with respect to the research, authorship, and/or publication of this article.

References

- 1 Miller MA, Nelson SL, Turk JR, et al. **Cutaneous neoplasia in 340 cats.** *Vet Pathol* 1991; 5: 389–395.
- 2 Hauck ML. **Tumors of the skin and subcutaneous tissues.** In: Withrow S, Vail D and Page R (eds). *Withrow and MacEwen's small animal clinical oncology*. 5th ed. St Louis, MO: Elsevier/Saunders, 2012, pp 305–320.
- 3 Webb JL, Burns RE, Brown HM, et al. **Squamous cell carcinoma.** *Compend Contin Educ Vet* 2009; 3: 133–142.
- 4 Murphy S. **Cutaneous squamous cell carcinoma in the cat: current understanding and treatment approaches.** *J Feline Med Surg* 2013; 5: 401–407.

- 5 Baer KE and Helton K. **Multicentric squamous cell carcinoma in situ resembling Bowen's disease in cats.** *Vet Pathol* 1993; 30: 535–543.
- 6 Freshwater A. **Why your housecat's trite little bite could cause you quite a fright: a study of domestic felines on the occurrence and antibiotic susceptibility of *Pasteurella multocida*.** *Zoonoses Public Health* 2008; 55: 507–513.
- 7 Gandolfi-Decristophoris P, Regula G, Orlando P, et al. **Prevalence of risk factors for carriage of multi-drug resistant *Staphylococci* in healthy cats and dogs.** *J Vet Sci* 2013; 14: 449–456.
- 8 Mwase M, Mumba C, Square D, et al. **Cutaneous squamous cell carcinoma presenting as a wound with discharging sinus tracts in a wild African lion (*Panthera leo*).** *J Comp Pathol* 2013; 4: 520–523.
- 9 Gross TL, Ihrke PJ, Walder EJ, et al. **Skin diseases of the dog and cat.** 2nd ed. Ames, IA: Blackwell, 2005, pp 579–589.
- 10 Diaz-Cascajo C, Borghi S, Weyers W, et al. **Follicular squamous cell carcinoma of the skin: a poorly recognized neoplasm arising from the wall of hair follicles.** *J Cutan Pathol* 2004; 1: 19–25.
- 11 Kossard S, Tan K-B and Choy C. **Keratoacanthoma and infundibulocystic squamous cell carcinoma.** *Am J Dermatopathol* 2008; 2: 127–134.
- 12 Wormser C, Mariano A, Holmes ES, et al. **Post-transplant malignant neoplasia associated with cyclosporine-based immunotherapy: prevalence, risk factors and survival in feline renal transplant recipients.** *Vet Comp Oncol.* Epub ahead of print 10 October 2014. DOI: 10.1111/vco.12120
- 13 Stelow EB, Skeate R, Wahi MM, et al. **Invasive cutaneous verruco-cystic squamous cell carcinoma: A pattern commonly present in transplant recipients.** *Am J Clin Pathol* 2003; 6: 807–810.
- 14 Munday JS. **Papillomaviruses in felids.** *Vet J* 2014; 3: 340–347.