

## **Hybrid technique coil embolisation for intrahepatic arterioportal fistula in a cat: case report**

Authors: Uemura, Akiko, Haruyama, Takashi, Nakata, Mary, Fukayama, Toshiharu, Goya, Seijirow, et al.

Source: Journal of Feline Medicine and Surgery Open Reports, 2(1)

Published By: SAGE Publishing

URL: <https://doi.org/10.1177/2055116916642256>

---

BioOne Complete ([complete.BioOne.org](https://complete.BioOne.org)) is a full-text database of 200 subscribed and open-access titles in the biological, ecological, and environmental sciences published by nonprofit societies, associations, museums, institutions, and presses.

Your use of this PDF, the BioOne Complete website, and all posted and associated content indicates your acceptance of BioOne's Terms of Use, available at [www.bioone.org/terms-of-use](https://www.bioone.org/terms-of-use).

Usage of BioOne Complete content is strictly limited to personal, educational, and non - commercial use. Commercial inquiries or rights and permissions requests should be directed to the individual publisher as copyright holder.

---

BioOne sees sustainable scholarly publishing as an inherently collaborative enterprise connecting authors, nonprofit publishers, academic institutions, research libraries, and research funders in the common goal of maximizing access to critical research.



# Hybrid technique coil embolisation for intrahepatic arterioportal fistula in a cat: case report

Akiko Uemura<sup>1</sup>, Takashi Haruyama<sup>2</sup>, Mary Nakata<sup>1</sup>, Toshiharu Fukayama<sup>1</sup>, Seijirow Goya<sup>1</sup>, Ryuji Fukushima<sup>1</sup> and Ryou Tanaka<sup>1</sup>

Journal of Feline Medicine and Surgery  
Open Reports  
1–5

© The Author(s) 2016

Reprints and permissions:

sagepub.co.uk/journalsPermissions.nav

DOI: 10.1177/2055116916642256

jfmsopenreports.com

This paper was handled and processed by the European Editorial Office (ISFM) for publication in JFMS



## Abstract

**Case summary** A 13-month-old, female, mixed breed, 4.0 kg cat was referred with a 6 month history of decreased appetite, loss of vigour and intermittent vomiting. Physical examination revealed no cyanosis or wasting, and no audible heart murmur was auscultated. Blood profile revealed mild anaemia and mildly elevated postprandial serum ammonia (109 µg/dl). Abdominal ultrasonography revealed dilation of an intrahepatic portal vein branch and an intrahepatic aneurysm, with splenomegaly and ascites. Hepatic arteriovenous fistula/hepatic artery–portal vein fistula with multiple acquired portosystemic shunts was strongly suspected. Medical control was achieved using antibiotics, liver-protecting agents, a low-protein diet and blood transfusions. However, because medical treatment proved ineffective, coil embolisation was performed on day 11, using a hybrid approach via the mesenteric vein. Subsequent follow-up showed good appetite, with no signs of diarrhoea or ascites. Abdominal ultrasonography revealed that the mosaic pattern around the site of coil placement in the portal vein branch had improved and pulsatility had disappeared.

**Relevance and novel information** Intrahepatic arterioportal fistula involves a circulatory shunt between the hepatic artery and the hepatic or portal vein within the liver, and may be congenital or acquired. Both forms have been reported in humans, but most cases in cats have been congenital. Few reports have described treatment methods or prognosis in cats. We report here that coil embolisation using a hybrid approach is a procedure offering easy, effective treatment by blocking hepatofugal blood flow.

**Accepted:** 2 March 2016

## Introduction

Intrahepatic arterioportal fistula (IHAPF) is a congenital or acquired condition in which a circulatory shunt forms between the hepatic artery and a hepatic or portal vein within the liver. This pathology is uncommon in humans and dogs but extremely rare in cats. Only three cases of IHAPF have previously been described in cats,<sup>1,2</sup> whereas congenital IHAPF has been reported in 18 human cases.<sup>3</sup> Both congenital and acquired cases have been reported in people,<sup>4</sup> but almost all reported cases in dogs and cats have been congenital.<sup>1,2,5–7</sup>

IHAPF in dogs has been treated by hepatic lobectomy, feeding artery ligation and feeding artery glue embolisation. Comparing results from these procedures, glue embolisation has been found to offer the best long-term prognosis.<sup>7</sup> In people, IHAPF has been treated by liver

transplantation, feeding artery surgical ligation, feeding artery embolisation and end-to-side portocaval shunt.<sup>3,8,9</sup> A previous study in cats only reported diagnosis, and treatment and prognosis have not been described.<sup>1,2</sup>

A cat with IHAPF and multiple concomitant acquired portosystemic shunts was treated by coil embolisation

<sup>1</sup>Tokyo University of Agriculture and Technology Animal Medical Center, Tokyo, Japan

<sup>2</sup>SyuSyu Cat Clinic, Tokyo, Japan

### Corresponding author:

Akiko Uemura DVM, Tokyo University of Agriculture and Technology Animal Medical Center, 3-5-8 Saiwaicho, Fuchu-shi, Tokyo, 183-8509, Japan  
Email: anco@vet.ne.jp



Creative Commons Non Commercial CC-BY-NC: This article is distributed under the terms of the Creative Commons

Attribution-NonCommercial 3.0 License (<http://www.creativecommons.org/licenses/by-nc/3.0/>) which permits non-commercial use, reproduction and distribution of the work without further permission provided the original work is attributed as specified on the SAGE and Open Access pages (<https://us.sagepub.com/en-us/nam/open-access-at-sage>).

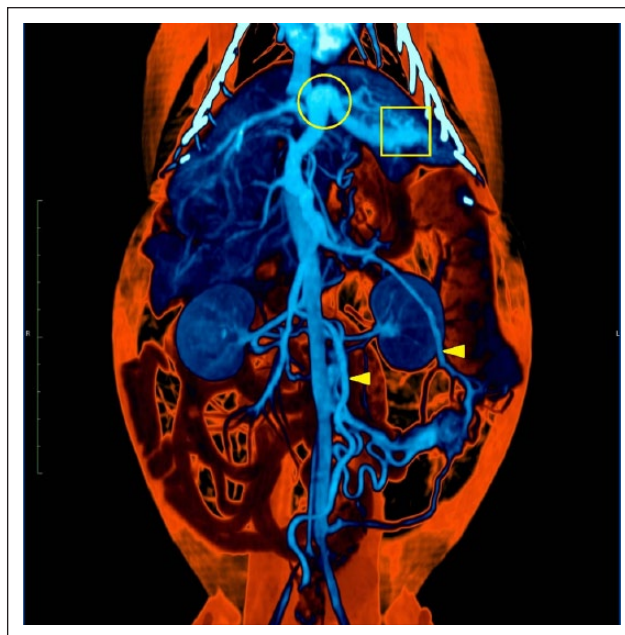
via the mesenteric vein. Coil embolisation using a hybrid approach was effective in blocking the direct flow of arterial blood into the intrahepatic portal vein branch. This treatment may be effective for IHAPF in cats.

### Case description

A 13-month-old, female, mixed-breed cat weighing 4.0 kg was referred to the Animal Medical Center at the Tokyo University of Agriculture and Technology with chronic decreased appetite, loss of vigour and intermittent vomiting from 7 months of age. Physical examination revealed no cyanosis or wasting, and no heart murmur was auscultated. Arterial blood pressure was within the normal range (139/98 mmHg [mean arterial pressure 113 mmHg]). Complete blood count revealed mild anaemia with haematocrit (Hct) 22.5%, and serum biochemistry revealed elevated levels of aspartate aminotransferase (114 U/l), alanine aminotransferase (366 U/l) and preprandial serum ammonia (109 µg/dl). Levels of albumin (3.1 g/dl) and total bile acid (TBA) (preprandial, 3.3 µmol/l; postprandial, 3.6 µmol/l levels) were within normal limits. Abdominal ultrasonography revealed dilation of an intrahepatic portal vein branch and an intrahepatic saccular dilation (maximum diameter 10.3 mm) showing pulsatile mosaic perfusion. Contrast-enhanced (4 ml iodine contrast agent; Iopamidol injection [Konica Minolta Health Care]) CT confirmed dilation of a portal vein branch (diameter 6.7 mm) in the left lateral hepatic lobe with several tortuous vessels that appeared continuous with the hepatic artery and a nidus visible around the associated portal vein branch (Figure 1). CT also confirmed the presence of multiple shunt vessels.

Moderate splenomegaly and ascites were also present. Based on these findings, hepatic arteriovenous fistula/hepatic artery–portal vein fistula with multiple acquired portosystemic shunts was strongly suspected. The cat was medically controlled using antibiotics (ampicillin sodium, 15 mg/kg q12h), liver-protecting agent (ursodeoxycholic acid, 50 mg q12h) and a low-protein diet with blood transfusions. However, because medical treatment proved ineffective, coil embolisation was performed on day 11 using a hybrid approach via the mesenteric vein.

Intravenous (IV) ampicillin sodium was administered at 30 mg/kg (ampicillin Na injection; Kyoritsu Seiyaku) to prevent infection, with IV buprenorphine hydrochloride at 0.01 mg/kg (Lepetan 0.2 mg; Otsuka Pharmaceutical) as pain relief. Following preadministration of a subcutaneous injection of atropine sulfate at 0.02 mg/kg, general anaesthesia was induced using 5% isoflurane (Isoflurane for Animal Use; Intervet). Coil embolisation was performed via a transperitoneal approach under general anaesthesia maintained with isoflurane inhalation (3.5–4.0%). For the midline



**Figure 1** Abdominal CT before treatment with coil occlusion. Portal venous phase contrast-enhanced CT of the abdomen shows dilation and curvature of the portal vein branch (O) in the left lateral hepatic lobe, with several tortuous vessels that appeared continuous with the hepatic artery and a nidus visible around the associated portal vein branch (□). No portal vein branch in the right lateral hepatic lobe is evident. Multiple shunt vessels are seen in the abdominal cavity (Δ)

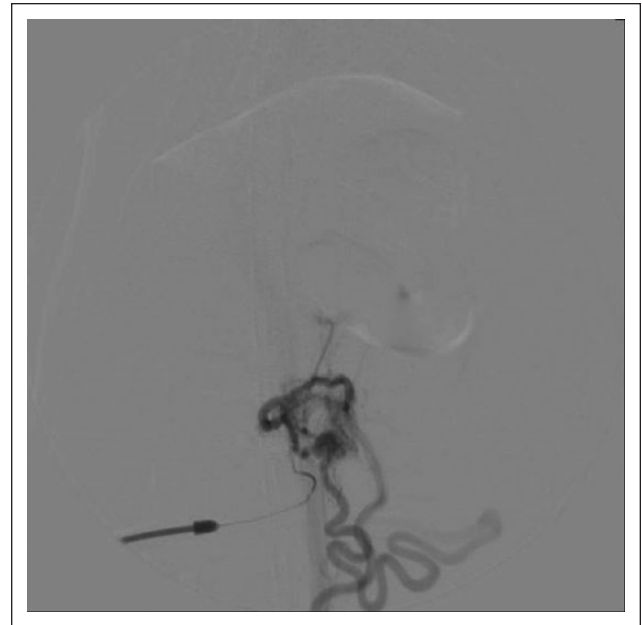transperitoneal approach, the mesenteric vein was cannulated with an IV catheter, and portal venous pressure was 26/24 mmHg (mean pressure 24 mmHg) (portal venous pressure in anaesthetised cats is  $8.9 \pm 0.35$  mmHg, with a mean of  $7.38 \pm 2.7$  mmHg).<sup>10</sup> A wide area of greater omentum was pale and the colour of the intestines suggested congestion. Anterograde angiography with iodine contrast agent (4 ml) showed that the contrast medium injected into the portal vein branch immediately diverted into the mesenteric vein, and multiple shunts were visible in the abdominal cavity. Congestion, dark-red colouration and varicose projections were apparent in part of the right medial hepatic lobe, which presented an extremely irregular texture. However, no abnormalities in external appearance were observed in the quadrate or left medial lobes. A small amount of pale-yellow ascites fluid was accumulated in the abdominal cavity. The splenic head was enlarged and dark red, and splenectomy to improve anaemia was performed using a vessel-sealing system (LigaSure; Covidien). After splenectomy, a 3 Fr sheath was inserted in the proximal mesenteric vein and a 0.018 inch guidewire was introduced. A microcatheter (Virtus 2Marker microcatheter; Boston Scientific Japan) was then inserted under fluoroscopic guidance as far as the region of the arteriportal

fistula. A detachable coil (interlocking detachable coil, 12 mm, 20 cm × 1 coil; Boston Scientific Japan) was deployed inside the portal vein branch under fluoroscopic guidance. Portal venous pressure was measured and peristaltic movements and colour of the intestines were checked, then five push-up coils (Cook push-up coils: 10 mm, 14.2 cm; Cook Japan) were added in order to embolise the intrahepatic portal vein (Figures 2 and 3). Portal venous pressure after coil embolisation was 27/23 mmHg (mean pressure 25 mmHg). Recovery from anaesthesia was uneventful, and appetite was evident 3 h postoperatively. Postoperative condition was improved, with no diarrhoea or vomiting. The day after the operation (day 12), pulsatile mosaic perfusion on abdominal ultrasonography was decreased in the intrahepatic branches of the portal vein. The animal was discharged on day 15. On day 92, the animal was vigorous and showed a good appetite, with no sign of diarrhoea or ascites. Postprandial serum ammonia (197 µg/dl) showed no decrease and remained medically controlled using ursodeoxycholic acid, but no sign of hepatic encephalopathy was identified and the cat exhibited good levels of activity and a stable condition. In addition, anaemia was improved (Hct 30.9%). On day 113, abdominal ultrasonography revealed that the mosaic pattern around the site of coil placement was nearly undetectable.

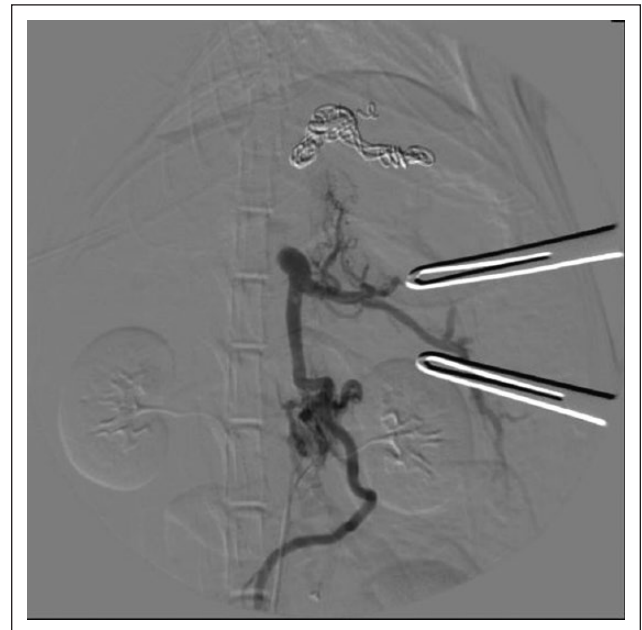
## Discussion

IHAPF is extremely rare in cats, and our search of the literature suggests that this represents the first report of surgical treatment.<sup>1,2</sup> Clinical signs in this case were loss of vigour, decreased appetite, vomiting and ascites, similar to previous reports of this condition in dogs and cats.<sup>1,2,6,7,11</sup> However, signs of hypoalbuminaemia and high TBA were not observed in previous reports of canine cases, and no cases with vascular murmurs in the anterior abdomen have been reported. Unlike the situation in dogs, these signs may not be seen in cats. Colour Doppler ultrasonography has been reported as a useful tool for the diagnosis of IHAPF in both cats and dogs.<sup>2,12,13</sup> In the present case, ultrasonography revealed a dilation of an intrahepatic portal vein branch and an intrahepatic saccular dilation with pulsatile mosaic perfusion in the portal vein branch. Contrast-enhanced CT also revealed a dilated portal vein branch, tortuous vessels and a nidus in the liver. Moreover, CT was useful in detecting multiple shunt vessels. These diagnostic tools are therefore very useful for the diagnosis of IHAPF. In surgery, antegrade angiography from the mesenteric vein produced a stain only on a small part of the portal vein, suggesting that retrograde blood flow was entering from the hepatic artery via the fistula.

IHAPF in dogs has been treated surgically by hepatic lobectomy, arterial ligation or arterial glue embolisation.



**Figure 2** Angiography before coil placement. Contrast medium injected into the portal vein branch immediately diverts into the mesenteric vein and multiple thick shunts are also evident. Portal venous pressure is 26/24 mmHg (mean pressure 24 mmHg)



**Figure 3** Angiography after coil placement. The contrast medium injected reaches the proximal portal vein because the retrograde hepatofugal flow is blocked by the coils, but the right hepatic parenchyma is not clearly visualised. Portal venous pressure after coil embolisation is 27/23 mmHg (mean pressure 25 mmHg)

Of these, glue embolisation has been found to offer the best long-term prognosis.<sup>7</sup> Attempts at surgical treatment for feline IHAPF have not been described.<sup>1,2</sup>



Hepatic lobectomy enables the removal of the lesion, as the origin of this disorder itself, and is useful if the IHAPF has developed within a single hepatic lobe. However, this entails a risk of major haemorrhage, and the large amount of hepatic parenchyma removed may cause liver dysfunction. A study comparing outcomes between the various treatments found that lobectomy does not always provide favourable prognosis.<sup>7</sup> Coil embolisation reduces the risk of haemorrhage compared with lobectomy, although a recurrence of portal hypertension often occurs with congenital IHAPH in people.<sup>3</sup> Vessel ligation at the site of the arteriovenous fistula can treat the shunt directly, but these procedures also require dissection of the hepatic parenchyma, resulting in a risk of major haemorrhage and extending surgical time.

In the present case, the arteriovenous fistula was localised to the left lateral hepatic lobe, so anatomical lobectomy was possible. However, considering the anaemia and other conditions, intrahepatic portal vein branch embolisation was selected as a means of reducing the volume of haemorrhage and produced good outcomes.<sup>14–16</sup> Coils were chosen rather than glue embolisation, to enable accurate embolisation at the target position under conditions in which the iodine contrast agent was being pushed back by the strong blood flow from the artery via the fistula. Performing coil embolisation using a hybrid approach, rather than percutaneously, reduces the distance to the target position compared with an approach via the neck. Consequently, this makes the operation easier to perform, and enables additional coils to be placed while the state of the intestines is confirmed by visual inspection at the same time as measurements of portal venous pressure before and after coil placement.

In this cat, high-pressure arterial blood flowing into the left intrahepatic portal vein branch from the hepatic artery branch created retrograde hepatofugal flow to the right hepatic lobe and the distal part of the portal vein, causing portal hypertension. This high-pressure hepatofugal flow interferes with the natural flow of blood into the liver from the portal vein. The presence of splenomegaly also suggested an increase in the volume of blood flowing from the spleen to the liver. The portal vein hypertension generated by the inflow of hepatofugal arterial blood and its interference with the flow of portal venous blood into the liver was the underlying cause of the condition prior to coil placement. After coil placement, the inflow of hepatofugal arterial blood was stopped and portal venous blood could flow into the hepatic lobes.<sup>17</sup>

In the present case, no great change in portal venous pressure was observed before (26/24 mmHg [mean pressure 24 mmHg]) and after coil placement (27/23 mmHg [mean pressure 25 mmHg]). This is similar to cases in dogs that have undergone hepatic lobectomy

that have not exhibited major reductions in portal venous pressure immediately after lobectomy.<sup>18</sup> This suggests that closure of the IHAPF, the origin of the disease itself, does not immediately lead to a drop in portal venous pressure. Increased retrograde hepatofugal flow may be related to histological findings, including fibrosis of the hepatic parenchyma at the IHAPF and hypoplasia of the intrahepatic portal vein.<sup>7</sup> Even after closure of the IHAPF, these hepatic changes remained and the increased portal venous pressure was maintained. The disappearance of retrograde hepatofugal flow may lead to the regeneration of hepatic tissue and decreases in portal venous pressure in the future. Alternatively, the disappearance of hepatofugal flow may have been related to suppression of the intrahepatic arteriovenous fistula by the coils preventing flow from the high-pressure system of the hepatic artery to the low-pressure system of the portal vein.

A previous study evaluated the prognosis for surgical treatment of intrahepatic arteriovenous fistula based on clinical signs.<sup>7</sup> In that investigation, prognoses were divided into four types: excellent (clinical signs resolved and no medical treatment required), good (clinical signs resolved but some sort of medical treatment required), poor (clinical signs continued or surgery-related death occurred) and overall poor (clinical signs exacerbated or intraoperative death). Under this classification, the present case corresponded with 'good' (clinical signs resolved but administration of ursodeoxycholic acid continued), suggesting that the therapeutic outcome of this method was at least equivalent to those of previously applied surgical methods. We demonstrated an improvement of clinical signs and prevention of pathological exacerbation.

## Conclusions

The present case suggests that coil embolisation using a hybrid approach is a procedure that offers an easy and effective treatment by blocking hepatofugal blood flow. This procedure may therefore constitute an effective method of surgical treatment for feline IHAPF.

**Acknowledgements** We gratefully acknowledge the work of past and present members of our laboratory.

**Funding** The authors received no financial support for the research, authorship, and/or publication of this article.

**Conflict of interest** The authors declared no potential conflicts of interest with respect to the research, authorship, and/or publication of this article.

## References

- 1 Legendre AM, Krahwinkel DJ, Carrig CB, et al. **Ascites associated with intrahepatic arteriovenous fistula in a cat.** *J Am Vet Med Assoc* 1976; 168: 589–591.

- 2 McConnell JF, Sparkes AH, Ladlow J, et al. **Ultrasonographic diagnosis of unusual portal vascular abnormalities in two cats.** *J Small Anim Pract* 2006; 47: 338–343.
- 3 Sutcliffe R, Mieli-Vergani G, Dhawan A, et al. **A novel treatment of congenital hepatoportal arteriovenous fistula.** *J Pediatr Surg* 2008; 43: 571–573.
- 4 Gomes MM and Bernatz PE. **Arteriovenous fistulas: a review and ten-year experience at the Mayo Clinic.** *Mayo Clin Proc* 1970; 45: 81–102.
- 5 McGavin MD and Henry J. **Canine hepatic vascular hamartoma associated with ascites.** *J Am Vet Med Assoc* 1972; 160: 864–866.
- 6 Easley JC and Carpenter JL. **Hepatic arteriovenous fistula in two Saint Bernard pups.** *J Am Vet Med Assoc* 1975; 166: 167–171.
- 7 Chanoit G, Kyles AE, Weisse C, et al. **Surgical and interventional radiographic treatment of dogs with hepatic arteriovenous fistulae.** *Vet Surg* 2007; 36: 199–209.
- 8 Ozyer U, Kirbas I, Aytekin C, et al. **Coil embolization of a congenital intrahepatic arterioportal fistula: increasing experience in management.** *Pediatr Radiol* 2008; 38: 1253–1256.
- 9 Kumar N, de Goyet Jde V, Sharif K, et al. **Congenital, solitary, large, intrahepatic arterioportal fistula in a child: management and review of the literature.** *Pediatr Radiol* 2003; 33: 20–23.
- 10 Buob S, Johnston AN and Webster CR. **Portal hypertension: pathophysiology, diagnosis, and treatment.** *J Vet Intern Med* 2011; 25: 169–186.
- 11 Schaeffer IG, Kirpensteijn J, Wolvekamp WT, et al. **Hepatic arteriovenous fistulae and portal vein hypoplasia in a Labrador retriever.** *J Small Anim Pract* 2001; 42: 146–150.
- 12 Bailey MQ, Willard MD, McLoughlin MA, et al. **Ultrasonographic findings associated with congenital hepatic arteriovenous fistula in three dogs.** *J Am Vet Med Assoc* 1988; 192: 1099–1101.
- 13 Szatmari V, Nemeth T, Kotai I, et al. **Doppler ultrasonographic diagnosis and anatomy of congenital intrahepatic arterioportal fistula in a puppy.** *Vet Radiol Ultrasound* 2000; 41: 284–286.
- 14 Weisse C, Schwartz K, Stronger R, et al. **Transjugular coil embolization of an intrahepatic portosystemic shunt in a cat.** *J Am Vet Med Assoc* 2002; 221: 1287–1291.
- 15 Lipscomb VJ, Jones HJ and Brockman DJ. **Complications and long-term outcomes of the ligation of congenital portosystemic shunts in 49 cats.** *Vet Rec* 2007; 160: 465–470.
- 16 Hunt GB, Kummeling A, Tisdall PL, et al. **Outcomes of cellophane banding for congenital portosystemic shunts in 106 dogs and 5 cats.** *Vet Surg* 2004; 33: 25–31.
- 17 Swinbourne F, Smith KC, Lipscomb VJ, et al. **Histopathological findings in the livers of cats with a congenital portosystemic shunt before and after surgical attenuation.** *Vet Rec* 2013; 172: 362.
- 18 Koide K, Koide Y, Asaeda H, et al. **Case report of congenital hepatic arteriovenous fistula treated with liver lobectomy and graded attenuation of multiple acquired portosystemic shunts in a dog.** *J Jpn Vet Med Assoc* 2013; 66: 257–262.