

## **Chronic intestinal pseudo-obstruction associated with enteric ganglionitis in a Persian cat**

Authors: Mortier, Jeremy, Elissalt, Estelle, Palierne, Sophie, Semin, Marie Odile, Delverdier, Maxence, et al.

Source: Journal of Feline Medicine and Surgery Open Reports, 2(1)

Published By: SAGE Publishing

URL: <https://doi.org/10.1177/2055116916655173>

---

BioOne Complete ([complete.BioOne.org](https://complete.BioOne.org)) is a full-text database of 200 subscribed and open-access titles in the biological, ecological, and environmental sciences published by nonprofit societies, associations, museums, institutions, and presses.

Your use of this PDF, the BioOne Complete website, and all posted and associated content indicates your acceptance of BioOne's Terms of Use, available at [www.bioone.org/terms-of-use](https://www.bioone.org/terms-of-use).

Usage of BioOne Complete content is strictly limited to personal, educational, and non - commercial use. Commercial inquiries or rights and permissions requests should be directed to the individual publisher as copyright holder.

---

BioOne sees sustainable scholarly publishing as an inherently collaborative enterprise connecting authors, nonprofit publishers, academic institutions, research libraries, and research funders in the common goal of maximizing access to critical research.



# Chronic intestinal pseudo-obstruction associated with enteric ganglionitis in a Persian cat

Jeremy Mortier<sup>1\*</sup>, Estelle Elissalt<sup>1†</sup>, Sophie Palierne<sup>2</sup>, Marie Odile Semin<sup>3</sup>, Maxence Delverdier<sup>3</sup> and Armelle Diquélou<sup>1</sup>

Journal of Feline Medicine and Surgery  
Open Reports  
1–5

© The Author(s) 2016  
Reprints and permissions:  
sagepub.co.uk/journalsPermissions.nav  
DOI: 10.1177/2055116916655173  
jfmsopenreports.com

This paper was handled and processed by the European Editorial Office (ISFM) for publication in JFMS Open Reports



## Abstract

**Case summary** A 7-year-old neutered male Persian cat was presented for acute vomiting and inappetence. Physical examination revealed severe abdominal distension. Radiographs demonstrated pneumoperitoneum, megaesophagus and generalised gaseous distension of the digestive tract. Exploratory coeliotomy was performed, revealing markedly distended and thickened small and large intestines with no observable peristalsis. No intestinal perforation was present. Bacteriological and cytological analysis of abdominal fluid revealed a septic peritonitis involving *Pasteurella multocida*. Full-thickness intestinal biopsies demonstrated lymphocytic ganglioneuritis localised to the enteric nervous system, in association with glandular atrophy and muscular layer hypertrophy. Amoxicillin-clavulanate and analgesics were given. The cat's general condition gradually improved after the addition of pyridostigmine bromide (0.5 mg/kg q12h PO), initiated 3 days postsurgery. Vomiting resolved and did not recur. Follow-up radiographs at 15 days, and 1 and 6 months showed persistent intestinal ileus, milder than on the pretreatment radiographs. Thirty months after presentation the cat is still alive, without clinical signs, and receives 1 mg/kg q12h pyridostigmine.

**Relevance and novel information** To our knowledge, this is the first case of ganglioneuritis of the myenteric plexus described in cats, as well as the first one successfully treated with pyridostigmine. Chronic intestinal pseudo-obstruction is a very rare condition in cats but should be included in the differential diagnosis of generalised gastrointestinal ileus.

**Accepted:** 25 May 2016

## Case description

A 7-year-old neutered male Persian cat weighing 4.7 kg and with a body condition score of 5/9 was presented at the National Veterinary School of Toulouse Teaching Hospital (NVST-TH) with a 2 day history of acute vomiting, inappetence and abdominal distension. Abnormal noise while drinking had also been observed for several days without other gastrointestinal signs. The cat had previously been successfully treated for cutaneous dermatophytosis and gingivostomatitis complex. The cat was up to date with vaccinations and worming, and was receiving no medication at the time of presentation. Feline leukaemia virus/feline immunodeficiency virus (FIV) serology had been negative 2 years prior to presentation.

Initial physical examination revealed moderate abdominal distension associated with mild discomfort.

<sup>1</sup>Internal Medicine, Department of Clinical Sciences, University of Toulouse, INP ENVT, Toulouse, France

<sup>2</sup>Surgery, Department of Clinical Sciences, University of Toulouse, INP ENVT, Toulouse, France

<sup>3</sup>Pathology, Department of Biological and Fundamental Sciences, University of Toulouse, INP ENVT, Toulouse, France

\*Current address: Department of Diagnostic Imaging, University of Liverpool, School of Veterinary Science, Neston, Cheshire, CH64 7TE, UK

†Current address: Clinique Vétérinaire de l'Estuaire, 8 Place Ferdinand Lartigue, 33340 Bégadan, France

### Corresponding author:

Armelle Diquélou DVM, PhD, Internal Medicine, INP Ecole Nationale Vétérinaire de Toulouse, 23 chemin des Capelles, BP 87 614, 31076 Toulouse cedex 3, France  
Email: a.diquelou@envt.fr

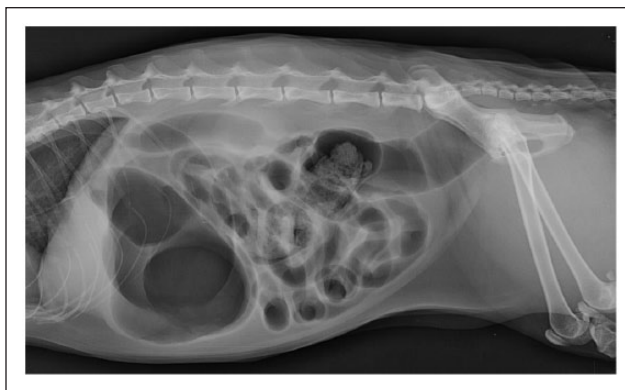


Creative Commons Non Commercial CC-BY-NC: This article is distributed under the terms of the Creative Commons

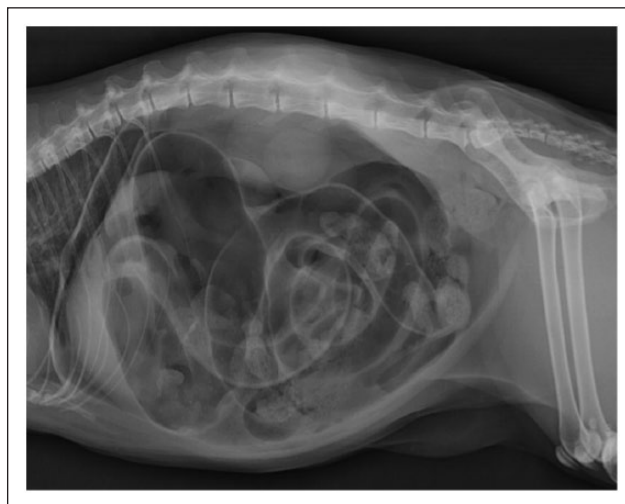
Attribution-NonCommercial 3.0 License (<http://www.creativecommons.org/licenses/by-nc/3.0/>) which permits non-commercial use, reproduction and distribution of the work without further permission provided the original work is attributed as specified on the SAGE and Open Access pages (<https://us.sagepub.com/en-us/nam/open-access-at-sage>).

Respiratory and cardiac auscultation were normal. Mucous membranes were pink and moist. No myosis or mydriasis was noted, and the pupillary reflex was normal. Thoracic and abdominal radiographs showed megaesophagus, and generalised intestinal ileus and gastric gaseous distension (Figure 1). No abnormality was noted on radiographs of the pharynx. Plasma biochemistry profile (total proteins, albumin, chloride, potassium, sodium, total  $\text{CO}_2$ , magnesium, alkaline phosphatase, alanine transaminase, gamma ( $\gamma$ )-glutamyl transferase, ionised calcium, blood pH, creatinine, phosphate) and complete blood count (CBC) were within the respective reference intervals (RIs). Oral treatment with metoclopramide (Primperid; CEVA) 1 mg/kg q12h for 5 days was prescribed and the cat was discharged under surveillance.

Over 24 h, the abdominal distension worsened, the cat had an episode of syncope and returned to NVST-TH. The owners had been unable to administer the treatment. Tachycardia (190 bpm) and severe abdominal distension associated with tympany and pain were noted on physical examination. Abdominal and thoracic radiographs showed pneumoperitoneum and persistent generalised ileus (Figure 2). Megaesophagus was no longer visible. Neurological and ophthalmological examinations, including Schirmer's tests, were normal. A CBC showed increased immature neutrophils (band cells  $2.29 \times 10^9/\text{l}$ ), toxic neutrophils and basophilia without leukocytosis. A plasma biochemistry profile remained within the RIs. Anti-acetylcholine receptor antibody titre was negative ( $<0.3 \text{ pmol/l}$ ). Exploratory coeliotomy was performed. Intravenous fluid therapy was initiated with NaCl 0.9% 5 ml/kg/h. The cat was premedicated with acepromazine (Calmivet Solution injectable 5 mg/ml; Laboratoire Vetoquinol), 0.05 mg/kg intravenously, and general anaesthesia was induced using intravenous propofol (Propovet 10 mg/ml; Axience), which was slowly injected until induction onset, followed with inhaled isoflurane (Isoflo; Axience) for maintenance of anaesthesia. Intravenous morphine (Morphine 1 mg/ml sol inj; Aguettant), 0.2 mg/kg then 0.1 mg/kg q2h, was used for analgesia and amoxicillin-clavulanate (Augmentin 125 mg; GlaxoSmithKline), 20 mg/kg IV, was administered for prophylactic antibiotic therapy. Surgery revealed severely distended and thickened small and large intestines, with no observable peristalsis. No intestinal perforation or mechanical obstruction was observed. No macroscopic signs of peritonitis were noted; however, cytological and bacteriological peritoneal lavage analysis revealed septic peritonitis due to *Pasteurella multocida*, sensitive to amoxicillin-clavulanate. Abdominal lymph nodes had a normal appearance. Full-thickness biopsies were obtained from the stomach, duodenum and jejunum. Passive drains were placed during surgery. The cat recovered from anaesthesia without any complications.



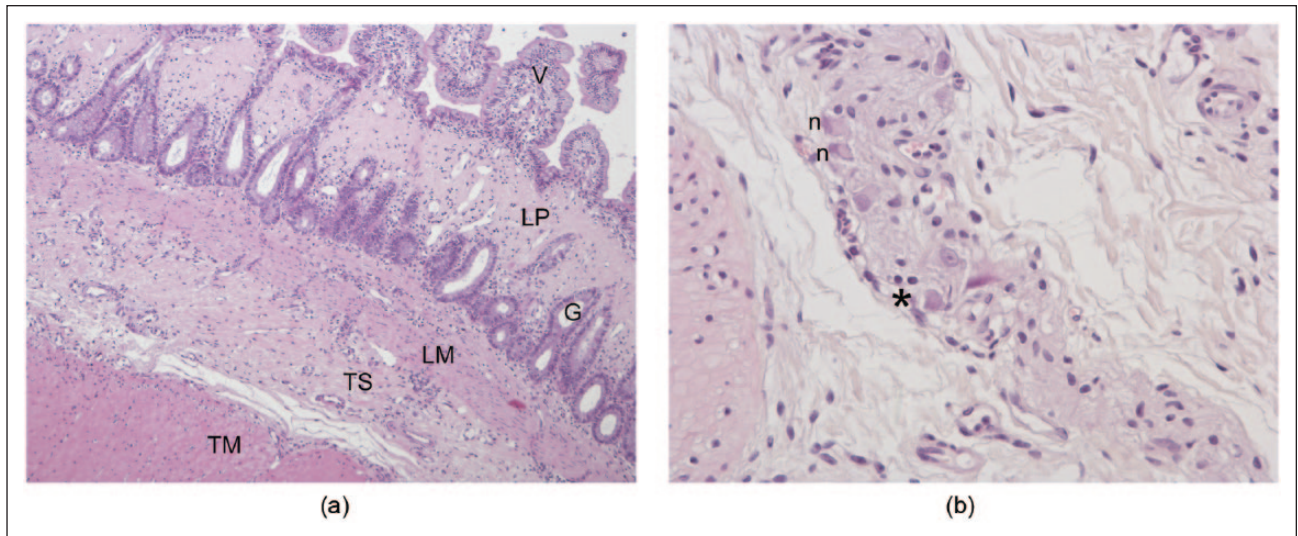
**Figure 1** Left lateral abdominal radiograph of the cat at presentation, showing gaseous distension of the oesophagus, stomach and intestinal loops



**Figure 2** Left lateral abdominal radiograph of the same cat the day after. Oesophagus dilation was no longer apparent, but pneumoperitoneum was present

During hospitalisation the cat received amoxicillin-clavulanate (20 mg/kg IV q8h), buprenorphine (Vetergesic 0.3 mg/ml, 10  $\mu\text{g/kg}$  IV q8h; Sogeval) and maintenance intravenous fluid therapy. Abdominal lavage with saline, using passive drains placed during surgery, was performed daily for 5 days. The cat remained anorexic and a nasoesophageal tube was placed for enteral feeding. Follow-up CBC on day 5 revealed a significant decrease in the number of band cells ( $0.56 \times 10^9/\text{l}$ ) and toxic neutrophils, lymphopenia ( $0.58 \times 10^9/\text{l}$ ; RI  $1.5\text{--}7.0 \times 10^9/\text{l}$ ) and monocytosis ( $2.93 \times 10^9/\text{l}$ ; RI  $0\text{--}0.85 \times 10^9/\text{l}$ ). Serum biochemistry showed hypoproteinaemia (49.4 g/l; RI 55–71 g/l) and hypoalbuminaemia (17.9 g/l; RI 27–39 g/l).

Biopsies were fixed in 10% neutral-buffered formalin and processed routinely for histopathology. Histological appearance was similar for the gastric, duodenal and



**Figure 3** (a) Jejunum (haematoxylin and eosin,  $\times 100$ ): severe glandular atrophy of the lamina propria. V = villi; LP = lamina propria; G = intestinal glands; LM = lamina muscularis; TS = tela submucosa; TM = tunica muscularis. (b) Jejunum, myenteric plexus in the tela submucosa (haematoxylin and eosin,  $\times 400$ ) showing reduced density of myenteric cells (neuronal degeneration [n]) and mild lymphocytic infiltrate (\*)

jejunal biopsies, but the severity of the lesions was more marked in the jejunum. At low magnification, the whole architecture was roughly preserved. The tunica muscularis was thicker than the tela submucosa, the lamina muscularis and the mucosa taken as a whole. The inner muscularis was thickened, whereas the intestinal villi were shortened. There was severe glandular atrophy of the upper half of the lamina propria, especially in the jejunum. In that area, the connective tissue appeared dense and brightly eosinophilic. Congo red stain ruled out amyloidosis and Masson's trichrome confirmed fibrosis. In most of the plexus, neuronal density was low to very low and severe neuronal degeneration was present. Furthermore, a mild lymphocytic infiltrate (with a few neutrophils) was focused on the myenteric plexus. These findings were consistent with an intestinal glandular atrophy presumably secondary to chronic ganglioneuritis of myenteric plexus (Figure 3a,b).

By day 5 (3 days after the surgery) the cat had not improved and abdominal distension was unchanged. Pyridostigmine bromide (Mestinon 60 mg; Meda Pharma), 0.5 mg/kg q12h PO, was initiated. After 3 days of therapy, the cat was much brighter, began to eat and the abdominal distension improved progressively. Repeat abdominal radiography showed significant decrease of the intestinal ileus and resolution of the pneumoperitoneum.

The cat was discharged with amoxicillin-clavulanate (20 mg/kg q12h PO) for 15 days and pyridostigmine bromide (0.5 mg/kg q12h PO) to be continued.

Over the next month the cat remained bright, without vomiting or diarrhoea, and had gained weight. However,

tympany and mild abdominal distension were still observed. Abdominal radiography revealed marked dilation of the stomach and colon. The pyridostigmine dosage was gradually increased to 1 mg/kg q12h and was well tolerated, but mild intestinal dilation was still present after dosage adjustment. Thirty months after admission, the cat is still asymptomatic and receives 1 mg/kg q12h pyridostigmine.

## Discussion

To our knowledge, this is the first report of chronic intestinal pseudo-obstruction (CIPO) due to ganglioneuritis in a cat and complicated with pneumoperitoneum, as well as the first report of a case of CIPO treated with pyridostigmine in animals.

The pneumoperitoneum may have been the cause of the syncope observed by the owner. Collapse has been infrequently reported in a retrospective study of 54 cases of non-traumatic pneumoperitoneum in dogs and cats.<sup>1</sup> Other clinical signs included lethargy (44%), vomiting (42%), abdominal discomfort and distension (37%), anorexia (35%) and retching (13%), as in our case. In veterinary medicine, as in human medicine, non-traumatic pneumoperitoneum is, in most cases (74%), due to digestive tract perforation.<sup>1</sup> Such a perforation was excluded, in our case, by coeliotomy. The pneumoperitoneum was considered to be a consequence of gas migration through damaged digestive wall during major digestive tract dilation, as it is supposed to occur in 7% of spontaneous pneumoperitoneum cases without digestive tract rupture.<sup>1</sup> Other causes of non-traumatic spontaneous pneumoperitoneum without intestinal rupture (septic peritonitis due



to *Clostridium* species, splenic or hepatic abscess, and rupture of the urinary bladder<sup>1,2</sup> were excluded. In our case, septic peritonitis due to *P. multocida* was observed on day 2. We suppose that these bacteria migrated through the intestinal wall together with the gas, as no clinical or biological signs of inflammation were observed on day 1, whereas band cells appeared on blood smears on day 2. In the dog, experimental pneumoperitoneum induces intraluminal bacterial colonisation of the caecum and lymphatic changes compatible with bacterial drainage as soon as 30 mins post-insufflation.<sup>3</sup>

CIPO is a syndrome characterised by chronic intestinal dilation without mechanical obstruction, caused by dysmotility of the intestinal loops.<sup>4</sup> It is well recognised in people, and has been described in the veterinary literature, mostly in dogs,<sup>5–16</sup> and also in three horses,<sup>17–19</sup> two cats<sup>20,21</sup> and a cow.<sup>22</sup>

One of the two cats reported with primary CIPO had visceral myopathy, with marked atrophy of the longitudinal muscle of the jejunal muscularis externa and replacement by fibroblasts in some portions of the jejunum. Myenteric plexus were normal.<sup>20</sup> The second cat reported had an intestinal leiomyopathy characterised by smooth muscle  $\alpha(\alpha)$ -actin deficiency.<sup>21</sup> In our case, the inner muscularis was hypertrophic, but there were no degenerative or inflammatory lesions in this tunica. A mild lymphocytic inflammation (with a few neutrophils) centred on the myenteric plexus and severe lesions of neuronal degeneration in the myenteric plexus were observed. No immunohistochemistry for smooth muscle  $\alpha$ -actin was performed.

Most lesions associated with CIPO in the literature have been described in dogs. Most often, they are fibrosis and inflammatory infiltration of the tunica muscularis.<sup>6–12,15,16</sup> Some other cases described an autonomous nervous system ganglioneuritis with inflammatory parietal lesions in a dog and two horses.<sup>13,18,19</sup> In the canine cases diagnosed with visceral myopathy,<sup>6,8,9,11,12</sup> leiomyositis<sup>7,10,15,16</sup> or sclerosing enteropathy,<sup>14</sup> the myenteric plexi were either normal<sup>6,7,9,12,14</sup> or exhibited some degree of lymphocytic inflammation,<sup>8,10,15</sup> considered less significant than the other lesions.

By comparison, in our case, the paucity of the mucosal infiltrate did not support the diagnosis of primary enteritis with secondary involvement of the plexus as the density of the infiltration was not significantly different from what is observed in the mucosa of asymptomatic cats. The severity of glandular atrophy and fibrosis without major mucosal lesions did not support this hypothesis either. Furthermore, the marked glandular atrophy combined with severe degenerative lesions of the myenteric plexus, and residual inflammation centred on the plexus, were consistent with chronic primary ganglioneuritis with secondary glandular atrophy; the intensity of neuronal degeneration exceeding by far that of the

leukocytic infiltrate fits with the chronicity of the lesions. Finally, the cat had no history of vomiting and diarrhoea and is free of clinical signs 6.5 years later without any change in diet or immunosuppressive treatment, making inflammatory bowel disease very unlikely.

In human medicine, ganglioneuritis is either idiopathic or associated with neoplasia (pulmonary carcinoma in particular), Chagas disease or infection with cytomegalovirus 5.<sup>4</sup> In animals, infection by simian immunodeficiency virus resulted in enteric ganglioneuritis in Macaques,<sup>23</sup> whereas equine herpesvirus-1 has recently been associated with ganglioneuritis and pseudo-obstruction in a horse.<sup>19</sup> No neoplasia was found in our cat and Chagas disease and infection with cytomegalovirus are very unlikely. The ganglioneuritis was supposed to be idiopathic in our case. However, it would have been interesting to search for FIV or herpesvirus within the lesions by PCR or immunohistopathology. Other neuropathies such as atypical dysautonomia or myasthenia gravis were considered, but the clinical signs were not consistent with dysautonomia and the cat was seronegative for antibodies against acetylcholine receptors. Amyloidosis was excluded by Congo red stain.

Treatment of primary CIPO is often disappointing in people, dogs and horses, and the prognosis is guarded to poor. Beside nutritional support, which can be long-term parenteral nutrition in human beings, prokinetic agents such as cisapride, neostigmine, ranitidine and bethanechol are the most commonly used.<sup>4–22</sup> In the case of ganglioneuritis in a dog, treatment with an immunosuppressive dose of prednisolone and cisapride led to a partial and transient improvement of the dog for a period of 2.5 months.<sup>13</sup> In another case, an immunosuppressive dosage of corticosteroids was successful and the dog remained free of clinical signs after discontinuation of the treatment.<sup>16</sup> Cisapride showed some positive effects in people and was successfully used to treat the cat with CIPO due to visceral myopathy. This cat was still alive 20 months later, receiving only cisapride (0.15 mg/kg PO q8h).<sup>20</sup> As cisapride was no longer available in our case, we chose to start treatment with pyridostigmine, a cholinesterase inhibitor.

Two trials in human medicine have studied the effect of pyridostigmine in people with CIPO.<sup>23,24</sup> The first one was a pilot study on 10 people with chronic constipation related to autonomic neuropathy. They received placebo for 2 weeks followed by an increasing dose of pyridostigmine for 6 weeks. Intestinal transit was accelerated in three patients, and four patients showed clinical improvement.<sup>23</sup> The second study tested the effect of pyridostigmine on seven patients with CIPO, and clinical improvement was observed in all patients.<sup>24</sup> This drug has never been used in small animal neurogenic CIPO before but was apparently effective in our case.

## Conclusions

To our knowledge, this case is the third CIPO described in the cat, and the first due to enteric ganglionitis. Two cats had a good response to parasympathomimetic agents, in contrast to what is observed in people or other animals. More clinical observations are warranted to confirm this trend.

**Acknowledgements** We thank Daniel Batchelor for his help with the editing of the manuscript

**Funding** The authors received no financial support for the research, authorship, and/or publication of this article.

**Conflict of interest** The authors declared no potential conflicts of interest with respect to the research, authorship, and/or publication of this article.

## References

- Smelstoys JA, Davis GJ, Learn AE, et al. **Outcome of and prognostic indicators for dogs and cats with pneumoperitoneum and no history of penetrating trauma: 54 cases (1988–2002).** *J Am Vet Med Assoc* 2004; 225: 251–255.
- Saunders WB and Tobias KM. **Pneumoperitoneum in dogs and cats: 39 cases (1983–2002).** *J Am Vet Med Assoc* 2003; 223: 462–468.
- Tug T, Tekeli A and Döseyen Z. **Does pneumoperitoneum cause bacterial translocation?** *J Laparoendosc Adv Surg Tech* 1998; 8: 401–407.
- Antonucci A, Fronzoni L, Cogliandro L, et al. **Chronic intestinal pseudo-obstruction.** *World J Gastroenterol* 2008; 14: 2953–2961.
- Aroch I, Nyska A, Gal R, et al. **Functional intestinal hypomotility in association with neuronal damage in a dog.** *J Small Anim Pract* 1997; 38: 119–123.
- Arrick RH and Kleine LJ. **Intestinal pseudoobstruction in a dog.** *J Am Vet Med Assoc* 1978; 172: 1201–1205.
- Couraud L, Jermyn K, Yam PS, et al. **Intestinal pseudo-obstruction, lymphocytic leiomyositis and atrophy of the muscularis externa in a dog.** *Vet Rec* 2006; 159: 86–87.
- Dvir E, Leisewitz AL and Van der Lugt JJ. **Chronic idiopathic intestinal pseudo-obstruction in an English bull-dog.** *J Small Anim Pract* 2001; 42: 243–247.
- Eastwood JM, McInnes EF, White RN, et al. **Caecal impaction and chronic intestinal pseudo-obstruction in a dog.** *J Vet Med Ser A Physiol Pathol Clin Med* 2005; 52: 43–44.
- Johnson CS, Fales-Williams AJ, Reimer SB, et al. **Fibrosing gastrointestinal leiomyositis as a cause of chronic intestinal pseudo-obstruction in an 8-month-old dog.** *Vet Pathol* 2007; 44: 106–109.
- Lamb WA and France MP. **Chronic intestinal pseudo-obstruction in a dog.** *Aust Vet J* 1994; 71: 84–86.
- Moore R and Carpenter J. **Intestinal sclerosis with pseudo-obstruction in three dogs.** *J Am Vet Med Assoc* 1984; 184: 830–833.
- Petrus DJ, Nicholls PK and Gregory SP. **Megacolon secondary to autonomic ganglioneuritis in a dog.** *Vet Rec* 2001; 148: 276–277.
- Swayne DE, Tyler DE, Farrell RL, et al. **Sclerosing enteropathy in a dog.** *Vet Pathol* 1986; 23: 641–643.
- Zacuto AC, Pesavento PA, Hill S, et al. **Intestinal leiomyositis: a cause of chronic intestinal pseudo-obstruction in 6 dogs.** *J Vet Intern Med* 2016; 30: 132–140.
- Murtagh K, Oldroyd L, Ressel L, et al. **Successful management of intestinal pseudo-obstruction in a dog.** *Vet Rec Case Rep*; 1: 1 e000025.
- Burns GA, Karcher LF and Cummings JF. **Equine myenteric ganglionitis: a case of chronic intestinal pseudo-obstruction.** *Cornell Vet* 1990; 80: 53–63.
- Chénier S, Macieira S, Sylvestre D, et al. **Chronic intestinal pseudo-obstruction in a horse: a case of enteric ganglionitis.** *Can Vet J* 2011; 52: 419–422.
- Pavone S, Sforna M, Gialletti R, et al. **Extensive myenteric ganglionitis in a case of equine chronic intestinal pseudo-obstruction associated with EHV-1 infection.** *J Comp Pathol* 2012; 148: 289–293.
- Harvey AM, Hall EJ, Day MJ, et al. **Chronic intestinal pseudo-obstruction in a cat caused by visceral myopathy.** *J Vet Intern Med* 2005; 19: 111–114.
- Imai DM, Miller JL, Leonard BC, et al. **Visceral smooth muscle alpha-actin deficiency associated with chronic intestinal pseudo-obstruction in a Bengal cat (*Felis catus* × *Prionailurus bengalensis*).** *Vet Pathol* 2014; 51: 612–618.
- Baker JS, Hullinger RL and Appel G. **Postpartum atony of the small and large intestine in a Holstein cow: a case of pseudo-obstruction.** *Cornell Vet* 1985; 75: 289–296.
- Bharucha AE, Low PA, Camilleri M, et al. **Pilot study of pyridostigmine in constipated patients with autonomic neuropathy.** *Clin Auton Res* 2008; 18: 194–202.
- O'Dea CJ, Brookes JH and Wattoo DA. **The efficacy of treatment of patients with severe constipation or recurrent pseudo-obstruction with pyridostigmine.** *Colorectal Dis* 2010; 12: 540–548.