



## Successful treatment of tracheal lymphoma in a Siamese cat

Authors: Bataller, Laura, Tamborini, Alice, L'Eplattenier, Henry, Necova, Slavka, and Robertson, Elise

Source: Journal of Feline Medicine and Surgery Open Reports, 3(2)

Published By: SAGE Publishing

URL: <https://doi.org/10.1177/2055116917742529>

---

BioOne Complete ([complete.BioOne.org](https://complete.BioOne.org)) is a full-text database of 200 subscribed and open-access titles in the biological, ecological, and environmental sciences published by nonprofit societies, associations, museums, institutions, and presses.

Your use of this PDF, the BioOne Complete website, and all posted and associated content indicates your acceptance of BioOne's Terms of Use, available at [www.bioone.org/terms-of-use](https://www.bioone.org/terms-of-use).

Usage of BioOne Complete content is strictly limited to personal, educational, and non - commercial use. Commercial inquiries or rights and permissions requests should be directed to the individual publisher as copyright holder.

---

BioOne sees sustainable scholarly publishing as an inherently collaborative enterprise connecting authors, nonprofit publishers, academic institutions, research libraries, and research funders in the common goal of maximizing access to critical research.



# Successful treatment of tracheal lymphoma in a Siamese cat

Laura Bataller, Alice Tamborini, Henry L'Eplattenier, Slavka Necova and Elise Robertson

*Journal of Feline Medicine and Surgery Open Reports*  
1–6

© The Author(s) 2017

Reprints and permissions:

sagepub.co.uk/journalsPermissions.nav

DOI: 10.1177/2055116917742529

journals.sagepub.com/home/jfmsopenreports

This paper was handled and processed

by the European Editorial Office (ISFM)

for publication in *JFMS Open Reports*



## Abstract

**Case summary** An 8-year-old female spayed Siamese indoor cat presented with a 3 week history of inspiratory dyspnoea, stridor and open-mouth breathing after exercise. Laryngoscopy, tracheoscopy, bronchoscopy and retroflexed nasopharyngoscopy were performed, and identified a multilobulated intraluminal mass within the trachea. Brush cytology was performed on the mass but was inconclusive in providing a definitive diagnosis. A CT scan of the neck failed to identify an obvious intraluminal mass and was negative to contrast uptake. Surgery was performed and seven rings of the trachea were removed to enable the complete excision of the mass. Histopathology of the excised mass was consistent with B cell lymphoma. After surgery, chemotherapy treatment was started. At the time of writing, 20 months since diagnosis, the cat remained clinically well, with no clinical signs or recurrence of macroscopic disease on endoscopic evaluation.

**Relevance and novel information** Upper airway endoscopy was considered to be an essential diagnostic tool in this case presenting with signs of upper respiratory dyspnoea. Moreover, combined surgery and chemotherapy were considered effective treatments and positively affected the long-term prognosis of this patient.

**Accepted:** 9 October 2017

## Case description

An 8-year-old female spayed Siamese indoor cat with suspected asthma was treated for 2 months with long-acting dexamethasone (Dexafort injectable 2 mg/ml; Intervet), inhaled fluticasone (Flixotide inhaler 125 µg; GSK) and salbutamol sulfate (Ventolin Evohaler 100 µg; GSK), and was re-presented to the primary veterinary surgeon with a 3 week history of inspiratory dyspnoea, stridor and open-mouth breathing.

A presumptive diagnosis of bacterial bronchopneumonia was made based on conscious thoracic radiographs and clinical presentation. Therefore, the cat was hospitalised and a combination of amoxicillin–clavulanic acid (Synulox palatable drops 50 mg/ml oral solution [Pfizer]; 12.5 mg/kg q12h PO for 7 days), a single injection of cefovecin (Convenia, antimicrobial for subcutaneous injection, 80 mg/ml [Pfizer]; 8 mg/kg SC) and furosemide (Dimazon 5 % w/v solution for injection diuretic [Intervet UK]; 1 mg/kg q8h IV for 3 days) was given. No major improvement was seen; thus, referral was arranged for further evaluation and investigation.

At presentation, the patient was bright, alert and responsive. On physical examination, heart rate was 180

bpm with no murmur, arrhythmias or palpable pulse deficits to suggest cardiac disease. There was noticeable tachypnoea (respiration rate ranged between 50 and 60 breaths/min) with mild inspiratory dyspnoea, stridor and hypothermia (36.7°C). Mucous membranes were pink and moist, the capillary refill time was <2 s, peripheral lymph nodes were not palpable and, on abdominal palpation, no abnormalities were detected.

Haematology, biochemistry and electrolytes were run to establish baseline health status. Haematology was unremarkable. Biochemistry showed a mild increase in alanine aminotransferase (ALT) activity (189 U/l; reference interval [RI] 12–130). Blood gas analysis revealed respiratory acidosis and metabolic alkalosis

Southfields Veterinary Specialists (formerly VRCC Veterinary Referrals), Laindon, UK

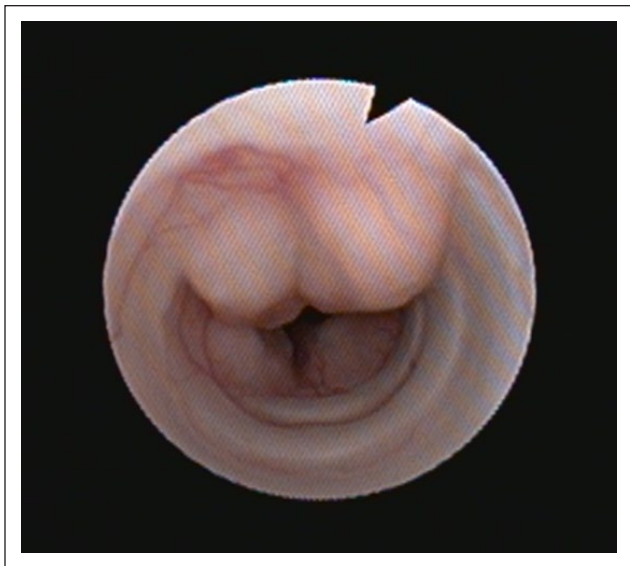### Corresponding author:

Henry L'Eplattenier Dr Med Vet, PhD, Dipl ECVS, MRCVS, Clinical Director, Southfields Veterinary Specialists, European Specialist in Small Animal Surgery, 1 Bramston Way, Laindon SS15 6TP, UK  
Email: henry.leplattenier@southfields.co.uk

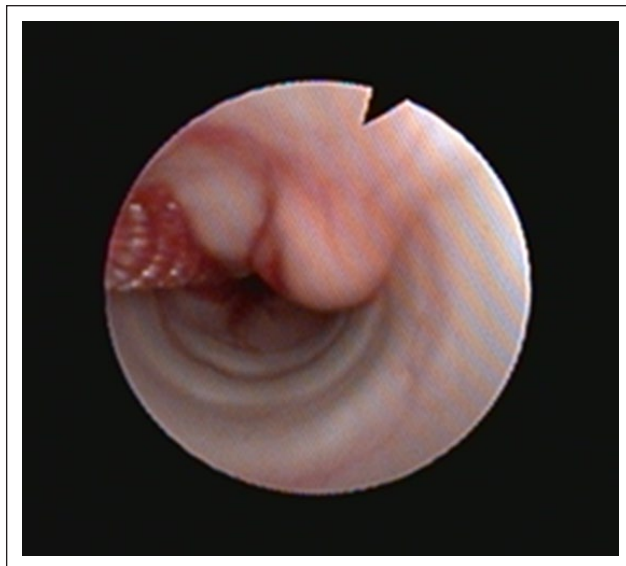

Creative Commons Non Commercial CC BY-NC: This article is distributed under the terms of the Creative Commons

Attribution-NonCommercial 4.0 License (<http://www.creativecommons.org/licenses/by-nc/4.0/>) which permits non-commercial use, reproduction and distribution of the work without further permission provided the original work is attributed as specified on the SAGE and Open Access pages (<https://us.sagepub.com/en-us/nam/open-access-at-sage>).



**Figure 1** Tracheoscopy: multilobulated intraluminal mass reducing intraluminal diameter to 4 mm in this section



**Figure 2** Brush cytology from the multilobulated intraluminal mass

(pH 7.57 [RI 7.24–7.40];  $\text{PCO}_2$  51 mmHg [RI 34–38];  $\text{HCO}_3^-$  42.9 mmol/l [RI 22–24]) and moderate-to-severe hypokalaemia (2.5 mmol/l; RI 3.5–5.8). The patient was also negative for feline leukaemia virus (FeLV) p27 antigen and feline immunodeficiency virus antibodies.

A Pro-BNP SNAP test was negative; therefore, tachypnoea and dyspnoea were more likely to be respiratory in origin. Conscious thoracic inspiratory views and neck radiographs were performed and found to be within normal limits.

Supportive treatment was initiated to correct the hypokalaemia with 20 mmol of potassium chloride (KCl 20 mmol/10 ml; Braun) added to 500 ml Hartmann's solution (Aqhp Pharm 11) administered at maintenance rate (2 ml/kg/h) as the hydration state was normal. The suspected underlying asthma was treated with inhaled salbutamol sulfate (Ventolin, Evohaler 100 µg [GSK]; 100 µg q8h) and dexamethasone (Dexadron 2 mg/ml solution for injection [Intervet]; 0.2 mg/kg q 24h IM). Treatment of possible *Mycoplasma* species bronchopneumonia was with pradofloxacin (Veraflox 25 mg/ml oral suspension [Bayer]; 5 mg/kg q 24h PO).

Twenty-four hours later, electrolytes and acid/base disturbances normalised. Stridor and wheezing were audible at times of stress; however, respiratory rate decreased to 24–36 breaths/min. The cat was premedicated with methadone (Comfortan 10 mg/ml solution for injection for dogs and cats [Dechra]; 0.2 mg/kg IV), pre-oxygenated for 10 mins and induced with alfaxalone (Alfaxan 10 mg/ml solution for injection for dogs and cats; Jurox) titrated to effect. Anaesthesia was maintained using isoflurane (Isocare 100% w/v Inhalation vapour, liquid; Animal Care). Terbutalin sulfate (Bricanyl 1.05 mg/ml solution for SC or IV injection [AstraZeneca];

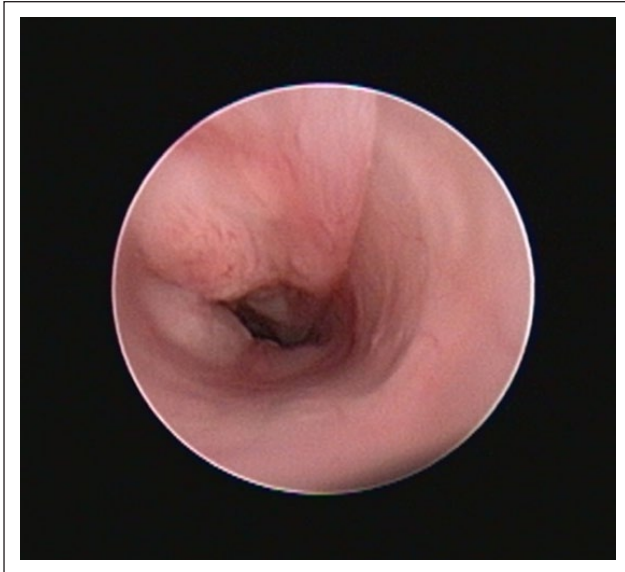0.0125 mg/kg IM) was also administered, prior to the procedure, to minimise the onset of bronchospasm. A 4 mm × 60 cm bronchoscope was used for laryngoscopy, tracheoscopy, bronchoscopy and retroflexed nasopharyngoscopy. The larynx was considered structurally and functionally normal. Tracheoscopy revealed a multilobulated intraluminal mass reducing the intraluminal diameter to 4 mm in this section (Figure 1). The endoscope could be passed beyond this lesion with no further masses identified to the level of the carina. Retroflexed nasopharyngoscopy ruled out concurrent nasopharyngeal mass, foreign body or nasopharyngeal stenosis.

Brush cytology, using a sterile cytology brush from a protective guard via the biopsy channel, was taken from the lesion (Figure 2). Bronchoalveolar lavage and biopsies were not performed owing to the high risk of developing bronchospasm and bleeding, respectively, which could adversely impact on the recovery of the patient from general anaesthesia.

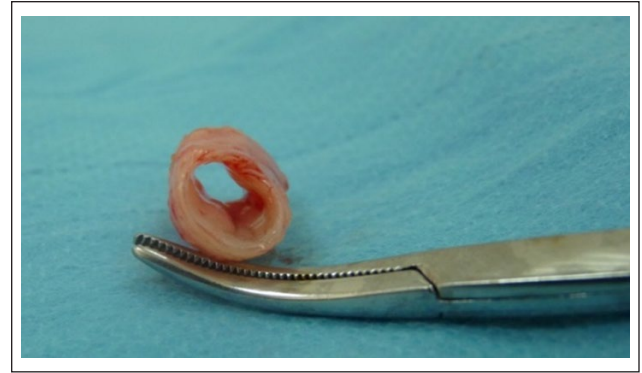While waiting for pending cytology results, the cat was discharged with a 1 week course of pradofloxacin (Veraflox 25 mg/ml oral suspension [Bayer]; 5 mg/kg q24h PO), inhaled salbutamol sulfate (Ventolin, Evohaler 100 µg [GSK]; 100 µg/cat q8h) and prednisolone (Prednicare 5 mg [Animal Care]; 1 mg/kg q24h PO) as treatment of possible concurrent asthma/*Mycoplasma* species bronchopneumonia.

Brush cytology of the mass described moderate numbers of erythrocytes, a low number of large angular superficial squamous epithelial cells and unremarkable columnar ciliated epithelial cells. No overtly neoplastic, inflammatory cells or infectious agents were seen.

During the following week, the patient was readmitted to the hospital with the aim of performing a helical



**Figure 3** Repeated tracheoscopy prior to surgery: mass slightly reduced in size



**Figure 4** Seven rings of the trachea removed, showing the intraluminal mass

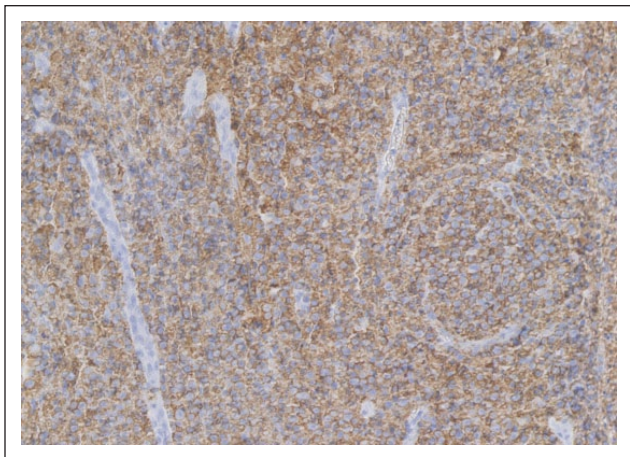
CT scan of the neck and thorax followed by surgical excision of the tracheal mass, owing to the inconclusive results from the brush cytology and the potential of being a neoplastic mass. The cat was premedicated with acepromazine (ACP 2 mg/ml injectable [Novartis]; 0.01 mg/kg IV) and methadone (Comfortan 10 mg/ml solution for injection for dogs and cats [Dechra]; 0.2 mg/kg IV), preoxygenated for 10 mins, induced with propofol (Vetofol 1.0 % w/v emulsion for injection; Norbrook) titrated to effect and maintained using isoflurane (Isocare 100% w/v Inhalation vapour, liquid; Animal Care). A CT scan (Somatom Spirit, 2-slice; Siemens) of the neck showed a poorly defined flattening/narrowing of the trachea ventral to C4–C5 vertebrae, but neither obvious mass nor abnormal contrast uptake were evident. Therefore, a 1.9 mm × 30° oblique telescope was used to repeat a tracheoscopy (Figure 3). The mass was slightly reduced in size but was still causing partial intraluminal occlusion.

During surgery, anaesthesia was maintained using alfaxalone (Alfaxan 10 mg/ml solution for injection for dogs and cats; Jurox) continuous rate infusion of 0.1 mg/kg/min instead of isoflurane, owing to the necessity of intubation and extubation of the patient during the procedure, making the maintenance of anaesthesia with isoflurane difficult. The skin was incised in the midline from the larynx to the manubrium sterni. After dissection through subcutaneous tissue, the trachea was exposed by separation of the paired sternohyoideous muscles. A transversal incision was made into the trachea cranial to the mass and the endotracheal tube was visualised. The latter was retracted cranially and about seven rings of the trachea were removed (Figure 4). The caudal part of the trachea was re-intubated, then the dorsal membrane of the trachea was sutured with four

pre-placed 4-0 polyglecaprone 25 sutures (Monocryl 4-0, 1.5 Ph. Eur; Ethicon), two on the right and two on the left. The rest of the anastomosis was completed with a simple interrupted pattern using the same suture material. All sutures were placed around the cartilage rings under visual control and pre-placed before being tied. In addition, two tension-relieving sutures were placed around the rings proximal and distal to the incision, one on each side of the trachea, in order to protect the anastomosis. The muscles and subcutaneous tissues were closed with a simple continuous pattern using 4-0 polyglecaprone 25 (Monocryl 4-0, 1.5 Ph Eur; Ethicon) and the skin with a simple interrupted pattern, using 4-0 nylon sutures (Ethilon 4-0, 1.5 metric; Ethicon).

On histopathology of the excised mass, a dense sheet of round cells with a moderate amount of eosinophilic cytoplasm and indistinct cell borders were seen. The nuclei were oval, approximately 2.5 times the diameter of adjacent erythrocytes with finely stippled chromatin and one prominent magenta nucleolus. There was moderate anisocytosis and anisokaryosis and an average of three mitoses per high power field were seen. There were scattered small areas of necrosis and aggregates of small lymphocytes and neutrophils. The neoplastic cells were confined to the submucosa but present within sections from the surgeon-cut tissue margins. Neoplastic cells exhibited strong cytoplasmic and membranous labelling for CD20 (Figure 5), there was rare faint labelling for Pax-5 and no labelling for CD3. The findings were consistent with B cell lymphoma. Complete staging was advised, including an abdominal ultrasound scan and fine-needle aspirates of abdominal organs if indicated but this was declined by the owner for financial reasons.

Chemotherapy treatment was elected owing to the fact that neoplastic cells were present within sections from the surgeon-cut tissue (incomplete margins) and consisted of a 6 week chemotherapy protocol (Table 1) alternating cyclophosphamide (Cyclophosphamide 10 mg oral capsules [The Specials Laboratory]; 10 mg/kg PO) and vincristine (Vincristine Sulphate 1 mg/ml IV



**Figure 5** Immunohistochemistry (CD20) of the tumour section confirms that the case was consistent with B cell lymphoma

injectable [Hospira UK]; 0.025 mg/kg IV) in conjunction with prednisolone (Prednicare 5 mg [Animal Care]; 1 mg/kg q 12 h PO) for 6 weeks (COP protocol). After the last chemotherapy treatment, the dose of prednisolone was tapered to 1 mg/kg q24h for 4 weeks and then suspended. The protocol was well tolerated and no signs of myelosuppression were noticed.

One month after the last chemotherapy and thereafter every 3 months, tracheoscopy was repeated and showed no signs of recurrent disease (Figures 6 and 7). ALT activity (104 U/l; RI 12–130 U/l) normalised during the chemotherapy protocol (within 3 months of diagnosis). At the time of the writing, 20 months since diagnosis, the cat is off medications and clinically well with no clinical signs or recurrence of the disease.

## Discussion

Lymphomas are a diverse group of neoplasms that have in common their origin from lymphoreticular cells and are among the most common feline malignancies,<sup>1</sup> representing >50% of all feline haemolymphatic malignancies in cats,<sup>2,3</sup> and account for 5–7% of all canine tumours.<sup>4</sup> Most studies have divided feline and canine lymphomas into four groups: gastrointestinal, mediastinal, multicentric or extranodal. The most common sites of lymphoma occurrence in cats are the gastrointestinal tract (30–50% of cases<sup>5</sup> vs 7% of cases in dogs<sup>6</sup>) and mediastinum. The multicentric

form with peripheral lymph node involvement is the most common form in dogs (80% of cases<sup>6</sup> vs 60% in feline leukaemia virus-positive cats).<sup>7</sup> The extranodal form might involve kidney, central nervous system, heart, nasal cavity, eye, trachea, skin and others sites but is thought to occur rarely in both canine and feline species.<sup>4,7,8</sup>

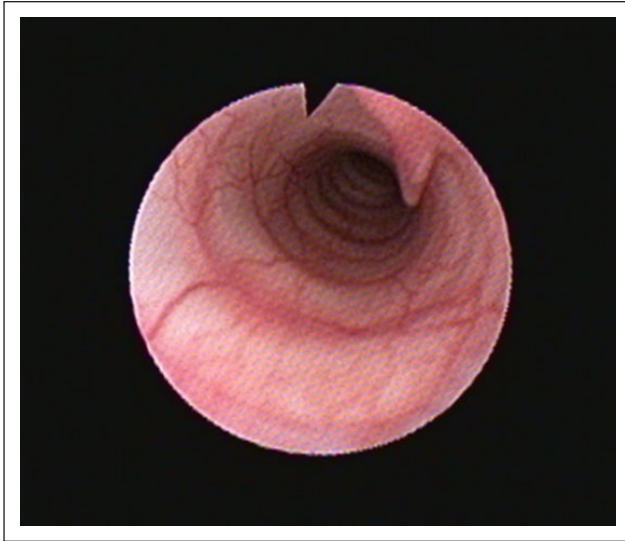
In humans, the incidence of tracheal malignancy has been reported to be approximately 0.1% of all malignancies, with most being squamous cell carcinoma or adenoid cystic carcinoma.<sup>9,10</sup> Primary nasal, nasopharyngeal and tracheal lymphomas represent rare extra-nodal manifestations, accounting for <1% of all feline tumours; however, this percentage has increased over the last few years.<sup>3</sup> The upper respiratory tract (URT) is considered a relatively rare site of lymphoma development in cats; however, the latter accounts for approximately 50% of primary URT mesenchymal tumours.<sup>2,3</sup> Some previous retrospective studies of laryngeal or tracheal masses have not identified a breed predisposition for mass types in cats.<sup>11,12</sup> However, one study found that Siamese cats had a significant association with lymphoma and that domestic longhair cats had a statistical correlation with adenocarcinomas and lymphomas. These breed correlations were based on a small number of cats, so whether a true association exists or not is unknown.<sup>13</sup>

Shortness of breath and wheezing unresponsive to bronchodilators should raise suspicion of a tracheal tumour in humans.<sup>14</sup> Cats with tracheal masses may present with dyspnoea, stridor, cyanosis, exercise intolerance, coughing and/or wheezing, as in the present case report. Haematology and biochemistry profiles are usually within the RIs but subject to individual variation.<sup>1,10</sup> In the present case, ALT activity was found to be increased and normalised after treatment. The increase may have been due to the hypoxia-induced hepatocellular damage; however, hepatic lymphoma could not be ruled out owing to incomplete staging. Blood gas analysis showed respiratory acidosis due to the partially obstructive tracheal mass-associated hypercapnia, and metabolic alkalosis likely represented renal compensation to chronic hypercapnia. Moreover, in the present case report, moderate-to-severe hypokalaemia was noticed and likely due to the previous furosemide administration.

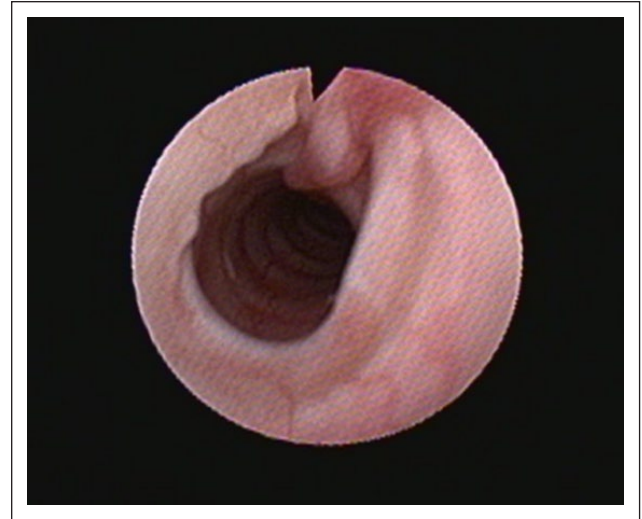In human medicine, conventional thoracic radiographs are rarely diagnostic and tumours can be easily overlooked.<sup>14</sup> CT is thought to be the most useful method

**Table 1** COP-based 6 week chemotherapy protocol used in the present case

Week 1	Cyclophosphamide 10 mg/kg PO	Prednicare 5 mg, 1 mg/kg q12h PO
Week 2	Vincristine sulfate 0.025 mg/kg IV	Prednicare 5 mg, 1 mg/kg q12h PO
Week 3	Cyclophosphamide 10 mg/kg PO	Prednicare 5 mg, 1 mg/kg q12h PO
Week 4	Vincristine sulfate 0.025 mg/kg IV	Prednicare 5 mg, 1 mg/kg q12h PO
Week 5	Cyclophosphamide 10 mg/kg PO	Prednicare 5 mg, 1 mg/kg q12h PO
Week 6	Vincristine sulfate 0.025 mg/kg IV	Prednicare 5 mg, 1 mg/kg q12h PO



**Figure 6** Repeated tracheoscopy 3 months after chemotherapy ended



**Figure 7** Another picture of the repeated tracheoscopy 3 months after chemotherapy ended

to assess tracheal tumours. In fact, one study reported a sensitivity of 66% for thoracic radiographs and of 91–97% for CT in detecting tracheal and bronchial disease.<sup>15,16</sup> Bronchoscopy is usually used to diagnose and stage tracheal tumours because it allows direct visualisation and tissue samples to be obtained from the tumours.<sup>14</sup> CT should be considered an appropriate and often necessary diagnostic modality in cats with inspiratory dyspnoea, if radiographs fail to demonstrate any obvious or conclusive abnormality.<sup>16</sup> However, as in this case report, where a CT scan of the neck failed to show the presence of the mass, it is advised that an upper airway tract endoscopy should be performed in cases with normal CT images.

In humans, primary benign and malignant tumours of the trachea are usually treated with surgery, endoscopic resection by laser surgery and radiotherapy.<sup>14</sup> It has been reported that surgery can cure benign and low-grade malignant tumours, achieve long-term survival in tracheal carcinomas, provide pathological confirmation of complete tumour removal and relieve airway obstruction permanently.<sup>14</sup> Laser surgery is an effective method for maintaining tracheobronchial ventilation as palliative treatment modality in obstructive tracheo-bronchial tumours.<sup>17</sup> In children, endoscopic resection, laser or electrocautery fulguration of benign lesions are usually used.<sup>14</sup> Radiotherapy is indicated as an adjuvant treatment after resection, for tumours that are unresectable or medically untreatable, and for palliative relief of severe symptoms.<sup>14</sup> Chemotherapy treatment has not yet been assessed prospectively in primary tracheal tumours.<sup>14</sup> However, a cyclophosphamide, doxorubicin, vincristine and prednisone (CHOP) protocol for secondary tracheo-bronchial lymphomas; doxorubicin, bleomycin and vinblastine dacarbazine (ABVD) protocol; doxorubicin,

CCNU, prednisone (ACP) protocol; or chlorambucil as sole agent for relapsed lymphomas have been described in humans.<sup>18</sup>

In feline patients, 12 primary feline tracheal tumours have been reported in the literature, representing lymphosarcomas ( $n = 4$ ), adenocarcinomas ( $n = 5$ ), carcinoma ( $n = 1$ ), squamous cell carcinoma ( $n = 1$ ) and seromucinous carcinoma ( $n = 1$ ). Moreover, a B cell lymphoma of the trachea has been recently described in a cat.<sup>19</sup> Treatment was reported in eight cats and included surgical excision, chemotherapy, radiotherapy or a combination of these modalities.<sup>10,20</sup> In one patient, corticosteroids were used as the sole agent, with recurrence of the dyspnoea after 35 days and the patient was euthanased.<sup>10</sup> Chemotherapy treatment using a CHOP protocol resulted in complete clinical remission at 19 months post-chemotherapy in another cat.<sup>10</sup> A COP protocol in combination with radiotherapy was attempted in another patient but discontinued as the cat developed systemic lymphosarcoma after 3 months; however, no recurrence of the respiratory signs was noted. Prednisone, vincristine and radiotherapy were elected in a cat, achieving complete resolution of the clinical signs for 17 months and remaining clinically normal at the time of the writing.<sup>10</sup> In another case report, 15 months of clinical remission were achieved with a CHOP protocol.<sup>16</sup> Surgery alone was described in two cases, of which one was diagnosed with systemic lymphoma 4 months after surgery and the other case re-presented with local recurrence 10 days after surgery; therefore, euthanasia was elected in both cases.<sup>10</sup> Surgery followed by a COP protocol has been described in another case and the cat was clinically in remission for 8 months, but no long-term follow-up was available.<sup>10,16</sup>

The limited number of reported cases and the lack of follow-up after treatment makes prognostication difficult. In fact, many factors, such as anatomical location, progression, delayed intervention and response to treatment might influence the short- and long-term prognosis. In the case described here, the patient underwent surgery and given the presence of neoplastic cells within the surgeon-cut tissue (incomplete margins) and the potential for recurrence of local disease and/or possible development of systemic lymphoma, a COP protocol was started as an adjuvant therapy. One week after surgery, the patient was clinically asymptomatic, with no signs of dyspnoea, wheezing or stridor. No signs of local recurrence of disease have been shown by endoscopic evaluation so far (15 months since last chemotherapy treatment). Therefore, based on this case report, a combination of excisional surgery and chemotherapy might be an effective treatment for tracheal lymphomas. Owing to the paucity of information on the subject, studies on a large cohort of cats are needed to establish the best treatment combination. It is interesting to note that, prior to presentation to our referral hospital, the patient was treated with glucocorticoid for suspected asthma and partial clinical remission lasted 2 months. It could be speculated that, in accordance with a previous report, glucocorticoids as a sole agent fail to achieve long-term remission in cats; however, glucocorticoids did not affect chemotherapy efficacy, as opposed to results recently reported in dogs.<sup>10,21</sup>

## Conclusions

Tracheal lymphoma should be considered as a possible differential diagnosis in adult cats presenting with upper airway signs. Physical examination combined with diagnostic imaging and endoscopy may allow early identification of tracheal masses. Biopsies are recommended to enable identification of the type of tumour and to commence the appropriate treatment. Combined surgery and chemotherapy could represent an effective treatment of tracheal lymphoma and might be associated with long-term survival. Studies on a large cohort of cats are needed to establish the best treatment combination and to identify prognostic factors for feline tracheal lymphomas.

**Conflict of interest** The authors declared no potential conflicts of interest with respect to the research, authorship, and/or publication of this article.

**Funding** The authors received no specific grant from any funding agency in the public, commercial or not-for-profit sectors for the preparation on this case report.

## References

1 Vail DM, Pinkerton ME and Young KM. **Hematopoietic Tumours**. In: Withrow SJ, Vail DM and Page RM (eds).

- Withrow & MacEwen's small animal clinical oncology. 5th ed. St Louis, Missouri: Elsevier, 2013, pp 608–678.
- 2 Jacobs RM, Messick JB and Valli VE. **Tumors of the hemolymphatic system: lymphoid tumors**. In: Meuten DJ (ed). *Tumors in domestic animals*. 4th ed. Ames, IA: Iowa State Press, 2002; 119–198.
- 3 Santagostino SF, Mortellaro CM, Boracchi P, et al. **Feline upper respiratory tract lymphoma: site, cyto-histology, phenotype, FeLV expression, and prognosis**. *Vet Pathol* 2015; 52: 250–259.
- 4 Ettinger SN. **Principles of treatment for canine lymphoma**. *Clin Tech Small Anim Pract* 2003; 18: 92–97.
- 5 North S and Banks T. *Small animal oncology: an introduction*. Philadelphia Saunders Elsevier, 2009, pp 225–234.
- 6 Dobson JM and Lascelles BDX. *BSAVA manual of canine and feline oncology*. 3rd ed. Gloucester: BSAVA.
- 7 Ettinger SN. **Principles of treatment for feline lymphoma**. *Clin Tech Small Anim Pract* 2003; 18: 98–102.
- 8 Gabor LJ, Malik R and Canfield PJ. **Clinical and anatomical features of lymphosarcoma in 118 cats**. *Aust Vet J* 1998; 76: 11.
- 9 Li WL, Ellerbroek NA and Libshitz HI. **Primary malignant tumors of the trachea. A radiologic and clinical study**. *Cancer* 1990; 66: 894–899.
- 10 Brown MR, Rogers KS, Mansell KJ, et al. **Primary intratracheal lymphosarcoma in four cats**. *J Am Anim Hosp Assoc* 2003; 39: 468–472.
- 11 Carlisle C, Biery D and Thrall D. **Tracheal and laryngeal tumors in the dog and cat: literature review and 13 additional patients**. *Vet Radiol Ultrasound* 1991; 32: 229–235.
- 12 Saik JE, Toll SL, Ditters RW, et al. **Canine and feline laryngeal neoplasia: a 10 year-survey**. *J Am Anim Hosp Assoc* 1996; 22: 359–365.
- 13 Janubiak MJ, Siedlecki CT, Zenger E, et al. **Laryngeal, laryngotracheal and tracheal masses in cats: 27 cases (1998–2003)**. *J Am Anim Hosp Assoc* 2005; 41: 310–316.
- 14 Macchiarini P. **Primary tracheal tumors**. *Lancet Oncology* 2006; 7: 83–91.
- 15 Kwong JS, Adler BD, Padley SP, et al. **Diagnosis of diseases of the trachea and main bronchi: chest radiography vs CT**. *AJR Am J Roentgenol* 1993; 161: 519–522.
- 16 Dugas B, Hoover J and Pechman R. **Computed tomography of a cat with primary intratracheal lymphosarcoma before and after systemic chemotherapy**. *Am Anim Hosp Assoc* 2011; 47: 131–136.
- 17 Sipilä J, Pulkkinen J, Hujala K, et al. **Endoscopic lasersurgery in obstructive tracheal and bronchial tumors. An update**. *Otolaryngol Pol* 2004; 58: 187–190.
- 18 Fidas P, Wright C, Harris NL, et al. **Primary tracheal non-Hodgkin's lymphoma. A case report and review of the literature**. *Am Cancer Soc* 1996; 77: 2332–2336.
- 19 Jelinek F and Hozmanova F. **Lymphoma of the trachea in a cat: a case report**. *Vet Med* 2012; 57: 150–153.
- 20 **Vet Med Today: What is your diagnosis?** *J Am Vet Med Assoc* 2010; 236: 953–954.
- 21 Zandvliet M, Rutteman GR and Teske E. **Prednisolone inclusion in a first-line multidrug cytostatic protocol for the treatment of canine lymphoma does not affect therapy results**. *Vet J* 2013; 3: 656–661.