



Successful treatment of *Providencia rettgeri* cholecystitis and neutrophilic cholangitis in a cat

Authors: Newton, Patricia L, and Fry, Darren R

Source: Journal of Feline Medicine and Surgery Open Reports, 4(1)

Published By: SAGE Publishing

URL: <https://doi.org/10.1177/2055116917750763>

BioOne Complete (complete.BioOne.org) is a full-text database of 200 subscribed and open-access titles in the biological, ecological, and environmental sciences published by nonprofit societies, associations, museums, institutions, and presses.

Your use of this PDF, the BioOne Complete website, and all posted and associated content indicates your acceptance of BioOne's Terms of Use, available at www.bioone.org/terms-of-use.

Usage of BioOne Complete content is strictly limited to personal, educational, and non - commercial use. Commercial inquiries or rights and permissions requests should be directed to the individual publisher as copyright holder.

BioOne sees sustainable scholarly publishing as an inherently collaborative enterprise connecting authors, nonprofit publishers, academic institutions, research libraries, and research funders in the common goal of maximizing access to critical research.



Successful treatment of *Providencia rettgeri* cholecystitis and neutrophilic cholangitis in a cat

Patricia L Newton and Darren R Fry

Journal of Feline Medicine and Surgery Open Reports
1–6

© The Author(s) 2018

Reprints and permissions:

sagepub.co.uk/journalsPermissions.nav

DOI: 10.1177/2055116917750763

journals.sagepub.com/home/jfmsopenreports

This paper was handled and processed by the European Editorial Office (ISFM) for publication in *JFMS Open Reports*



Abstract

Case summary A 15-year-old male neutered domestic shorthair cat was presented with a recent history of seizures, diarrhoea, lethargy, fever and jaundice. Marked elevation of liver enzyme activity was present and ultrasound examination was suggestive of cholecystitis and hepatitis. Neutrophilic cholangitis was confirmed on histopathology of liver biopsies. Bile culture identified a monomicrobial infection with *Providencia rettgeri*, which was resistant to multiple antimicrobial agents. The cat was treated with oral pradofloxacin for 4 weeks and remained well 4 months later.

Relevance and novel information *Providencia* species are rarely reported in the veterinary literature and are an uncommon cause of disease in humans. The significance of this species in humans relates to the high prevalence of antimicrobial resistance. This is the first report of *P rettgeri* causing clinical illness in a cat and highlights the importance of bile cultures in hepatic disease.

Accepted: 27 November 2017

Introduction

Ascending bacterial infection of the biliary tract has been implicated in the pathogenesis of neutrophilic cholangitis in the cat in several studies,^{1–3} and the disease parallels acute cholangitis in people. Enteric pathogens have been implicated in the pathogenesis of disease in both cats and people,^{1–7} and recent literature in humans suggests high rates of antimicrobial resistance.^{6–9}

Providencia rettgeri is an unusual pathogen in humans, mostly associated with urinary tract infections,^{10–12} and has been reported as the cause of a urinary tract infection in a dog.¹³

Other *Providencia* species have been reported in association with diarrhoea and skin disease in dogs.^{14,15} To our knowledge, this is the first report of a *Providencia* species causing clinical disease in a cat.

Case description

A 15-year-old male neutered domestic shorthair cat was presented after a generalised seizure was observed at home. A second seizure was observed after admission to hospital. Occasional vomiting and soft faecal consistency had been present over the previous week. The cat

had indoor and outdoor access, and was fed a commercial, complete and balanced cat food.

The cat's recent history was complex, presenting 5 months earlier with flea allergy dermatitis, a palatine ulcer, marked eosinophilia and mild, poorly regenerative anaemia. Weight loss, despite a good appetite, was also noted at the time. Serum biochemistry, abdominal ultrasound and endoscopic upper gastrointestinal biopsies had been normal on initial investigations, as was total thyroxine. Most signs improved after treatment with prednisolone (1.5 mg/kg q12h Pred-X; Apex Laboratories) and topical imidacloprid (Advantage; Bayer), but weight loss continued and mild hyporexia

Brisbane Veterinary Specialist Centre, Albany Creek, QLD, Australia

Corresponding author:

Patricia L Newton BVSc, MANZCVS, Brisbane Veterinary Specialist Centre, Cnr Old Northern Rd and Keong Rd, Albany Creek, QLD, 4035, Australia
Email: patrician@bvsc.com.au



Creative Commons Non Commercial CC BY-NC: This article is distributed under the terms of the Creative Commons

Attribution-NonCommercial 4.0 License (<http://www.creativecommons.org/licenses/by-nc/4.0/>) which permits non-commercial use, reproduction and distribution of the work without further permission provided the original work is attributed as specified on the SAGE and Open Access pages (<https://us.sagepub.com/en-us/nam/open-access-at-sage>).

was reported. Prednisolone therapy was ongoing at 1 mg/kg q12h.

Further investigations were pursued and serum cobalamin levels and feline trypsin-like immunoreactivity were normal. There was no improvement in body condition or reduced appetite after a strict dietary trial with a commercial hydrolysed protein diet (Hill's z/d). There had been no response to a metronidazole antibiotic trial (13.5 mg/kg q12h Metronide; Sanofi-Aventis). Abdominal ultrasound was normal when performed at the first presentation, but repeat examination 2 months later showed mild, diffuse small intestinal thickening. Intestinal layering was preserved, but thickening of the muscularis layer was noted. The cat was subsequently diagnosed with lymphoplasmacytic colitis on endoscopic biopsies of the colon, with suspicion of extension to the ileum, based on sonographic appearance and weight loss. Endoscopic ileal biopsies were attempted but were unsuccessful. Prednisolone (Pred-X) was initiated (1.5 mg/kg PO q12h) with an improved appetite and a mild increase in weight noted, although the cat's body condition score remained suboptimal at 3/9.

Urine specific gravity (USG) was repeatedly suboptimal at 1.020–1.024, even prior to corticosteroid treatment. The urine protein:creatinine ratio was normal at 0.08 (<0.4 indicative of no significant proteinuria). Early renal disease was suspected, with ongoing monitoring planned. Faecal PCR (Feline Diarrhoea Panel; IDEXX Laboratories) had been performed with a low-range positive result for *Clostridium perfringens* toxin gene (QPA₂), which was considered of doubtful clinical significance. The cat was negative for the other infectious agents in the panel, including *Giardia* species, *Campylobacter* species, *Salmonella* species, *Tritrichomonas foetus*, *Toxoplasma gondii*, feline coronavirus and feline panleukopenia virus.

Two weeks prior to presentation for the seizure, the cat had been presented for a superficial laceration, sustained in a fight, to the left hock. Cephalexin (20 mg/kg PO q12h Rilexine; Virbac) was prescribed at the time owing to concern about the immunosuppressive dose of prednisolone concurrently administered. The wound was surgically repaired and healed uneventfully.

Five months after initial presentation with weight loss, the cat presented for a generalised seizure at home. On physical examination, the cat appeared mentally dull, ambulatory with mild ataxia and remained responsive to external stimuli. Menace response and pupillary light reflexes were normal, and no abnormalities were noted apart from the ataxia and mental dullness. Systemic hypertension was present (systolic pressure 177 mmHg [Doppler Blood Pressure Monitor; Parks]) and phenobarbitone at 2 mg/kg (Phenobarbitone; Aspen Pharma) was administered intravenously after a second seizure was observed following admission to hospital. A complete neurological examination was not performed

on admission, but there were concerns about visual deficits after the second seizure.

Ophthalmic examination on day 2 identified focal left retinal detachment and the cat remained weak and mentally dull. Menace was present, and reduced and pupillary light reflex were present but reduced. Myotactic reflexes were normal and gait could not be assessed owing to persistent weakness. Hypertension was confirmed with high definition oscillometry (204/112 [VET HDO monitor; S+B medVet GmbH]). There was a mild hypokalaemia (3.1 mmol/l; reference interval [RI] 3.5–5.8 mmol/l) and hypochloraemia (110 mmol/l; RI 112–129 mmol/l), but blood urea nitrogen and creatinine were normal. USG remained poorly concentrated at 1.022. The cat's plasma appeared icteric, and serum bilirubin was 32 µmol/l (RI 0–15 µmol/l). Differential diagnoses for the seizures included hypertensive encephalopathy, an ischaemic or haemorrhagic infarct, structural intracranial disease and metabolic causes. The retinal detachment was presumed to be secondary to hypertension at this stage, with IRIS stage 1 chronic kidney disease suspected.¹⁶ This was based on inadequately concentrated urine and failure to identify other metabolic causes of hypertension such as diabetes mellitus or hyperthyroidism. Further investigations were planned to identify a cause for the hyperbilirubinaemia and the cat continued to eat and drink.

Amlodipine (Norvasc; Pfizer) was commenced at 1.25 mg q24h to treat hypertension. Intravenous (IV) fluid therapy with potassium supplementation was commenced overnight owing to increased depression and the development of complete anorexia.

By day 3, the cat was laterally recumbent and pyrexia with clinically apparent jaundice. Hypertension had resolved and the cat was normotensive. Ultrasound examination of the abdomen identified a hyperechoic and subjectively enlarged liver with a thickened gall bladder wall, echogenic sediment in the gall bladder and a tortuous bile duct (Figures 1 and 2)

There was a severe increase in alanine transferase (ALT) activity at 4166 U/l (RI 12–120 U/l) and a mild increase in alkaline phosphatase (ALP) activity at 133 (RI 14–111 U/l)

Core biopsies of the liver were obtained for histopathology with a 16 G biopsy needle (BARD Magnum device). Ultrasound-guided fine-needle aspiration of the gall bladder was performed with a 25 G 1.5" needle and 5 ml syringe. Bile aspirates identified neutrophilic inflammation and numerous intracellular and extracellular rod-shaped bacteria consistent with bacterial cholecystitis. Liver histopathology identified severe neutrophilic cholangitis with vasculitis and periportal coagulative necrosis. The bile cytology and liver histopathology were consistent with acute neutrophilic cholangitis and cholecystitis.^{17,18}

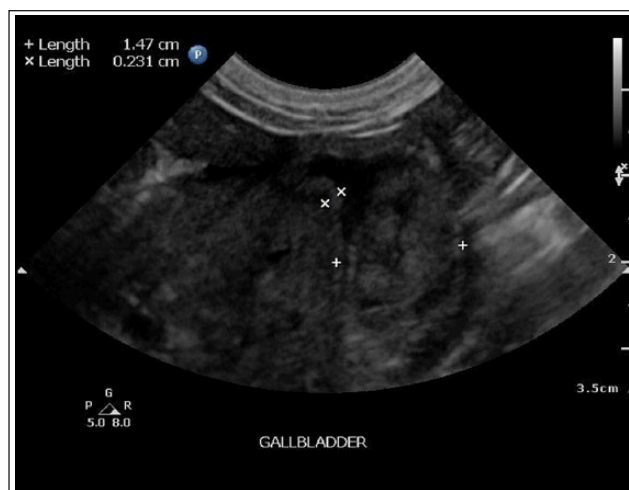

Figure 1 Ultrasound examination day 3. Gall bladder wall thickening is present (x) and there is echogenic material in the gall bladder lumen (+)

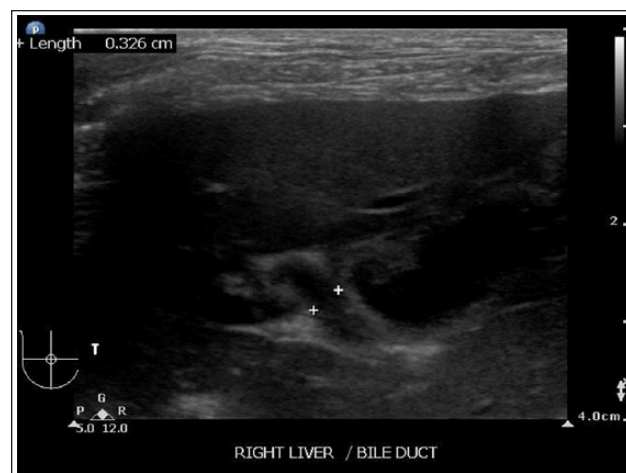

Figure 2 Ultrasound examination day 3. Tortuous bile duct

Table 1 Progressive change in liver enzyme activity over time

	Day 2	Day 3	Day 12	Day 15	Day 39	Day 67
ALT (RI 12–130 U/l)	NA	4166	1674	792	136	108
ALP (RI 14–111 U/l)	NA	133	303	144	69	73
TBil (RI 0–15 µmol/l)	32	NA	29	13	5	2

ALT = alanine transferase; NA = not available; ALP = alkaline phosphatase; TBil = total bilirubin

The cat was treated with IV Hartmann's solution with potassium supplemented at 20 mmol/l to correct dehydration and hypokalaemia, and continued at maintenance once fluid deficits were replaced. Buprenorphine analgesia (0.015 mg/kg q8h Butorgesic; Ileum) was provided and empiric antimicrobial therapy with IV amoxycillin (20 mg/kg q12h Amoxil; GlaxoSmithKline) and metronidazole (10 mg/kg q12h Metronidazole; Sandoz) commenced. Maropitant (Cerenia; Zoetis) was administered at 1 mg/kg once daily as needed.

Bile culture results were available on day 5 and a single organism, *P rettgeri*, was identified. The organism was resistant to β -lactam antimicrobials and tetracycline, with sensitivity to co-trimoxazole, enrofloxacin and gentamicin. Pradofloxacin sensitivity was confirmed with additional testing. Enrofloxacin was not used owing to concerns about pre-existing retinal changes and the potential for retinal toxicity with this drug. Co-trimoxazole was not considered appropriate owing to the severe hepatic dysfunction, and pradofloxacin (Veraflox; Bayer) was chosen for its retinal safety profile.¹⁹

Analgesia and IV fluids were continued until day 5 when the cat was eating and drinking. Pradofloxacin was continued for 4 weeks until gall bladder sediment had sonographically resolved and liver enzyme activity returned to normal values.

Liver enzyme activity returned to normal over subsequent weeks (Table 1), and remained normal after discontinuing pradofloxacin. No further seizures had been observed and asymptomatic hypertension had recurred but was well controlled after amlodipine was increased to 1.25 mg q12h.

There were persistent hepatobiliary changes with intrahepatic bile duct dilation in the right medial liver lobe and persistent gall bladder wall thickening several months later (Figures 3–5).

Discussion

Neutrophilic cholangitis is a significant cause of hepatic disease in cats and is characterised by neutrophilic inflammation of the biliary tract.^{1,2,20,21} Ascending bacterial infection from the gall bladder has been implicated in the development of neutrophilic cholangitis,^{1,2} and hepatic inflammation, when present, is an extension of this process. Current literature suggests an association with inflammatory bowel disease and pancreatitis,³ but it is not yet clear if there is a causative role between these conditions or the association represents concurrent disease in this population. An association with nephritis was also identified by Callahan-Clark et al,² but the clinical significance of this association is not yet known.

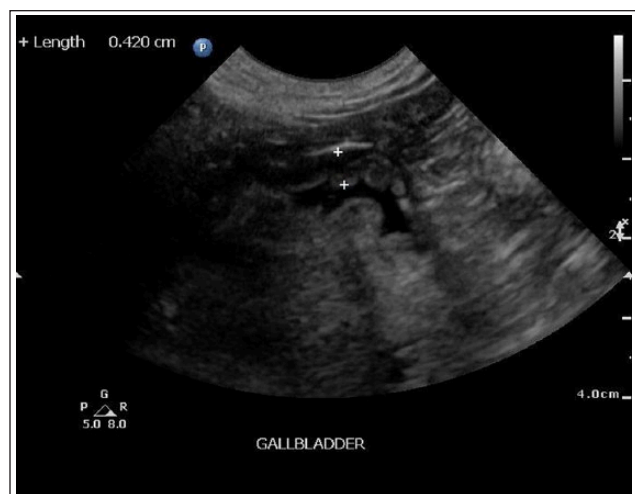

Figure 3 Ultrasound examination day 12. Gall bladder wall thickening persisted with mucosal irregularity noted. There was less echogenic material in the gall bladder lumen

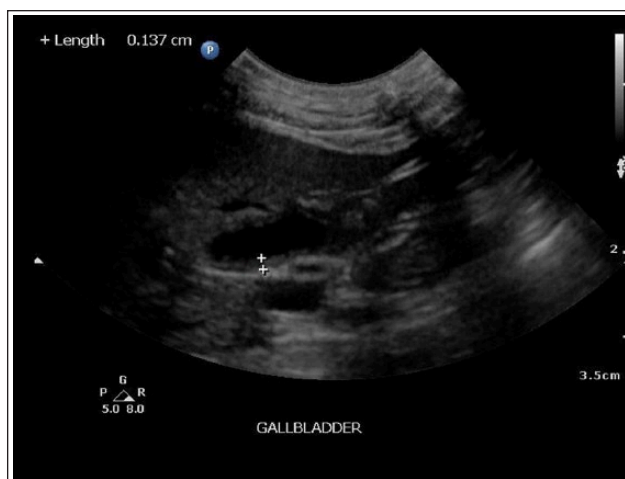

Figure 5 Ultrasound examination day 101. There was marked improvement in the gall bladder wall thickness and appearance with anechoic gall bladder contents

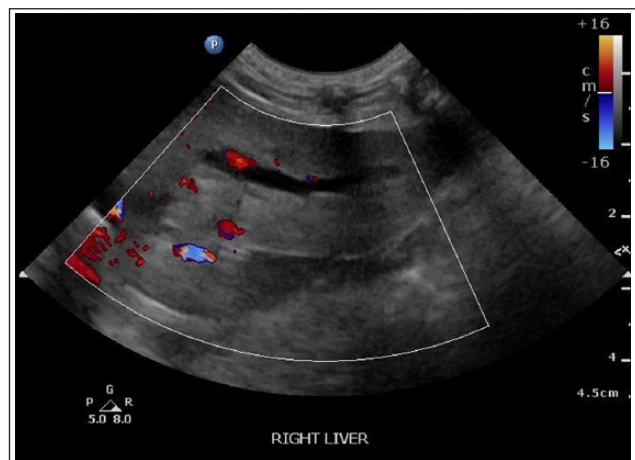


Figure 4 Ultrasound examination day 67. Dilation of intrahepatic bile ducts is evident

Clinical signs of neutrophilic cholangitis are non-specific and can include fever and lethargy, vomiting, anorexia and weight loss.^{1,20,21} Clinicopathological abnormalities are variable, but most cats have some degree of elevations in liver enzyme activity and bilirubin.^{1,2,21} Variable sensitivity is reported for aspartate transaminase and ALT, but these enzymes appear the most sensitive in the identification of neutrophilic cholangitis,^{1,2,21} and there was a marked increase in ALT activity in the current case.

There is no consensus with regards to an age predilection, with some authors reporting a younger median age for neutrophilic cholangitis than for lymphocytic cholangitis.^{1,2}

Sonographic changes suggestive of feline cholangitis include dilation of the bile ducts, hyperechoic hepatic

parenchyma and hepatic enlargement.^{1,2,21} In addition to these findings, the current case displayed gall bladder wall thickening and echogenic gall bladder sediment, similar to cats in a case series reported by Brain et al.¹ The presence of sonographic changes to the gall bladder has been demonstrated to be highly specific for gall bladder pathology, with cholecystitis and positive bile cultures identified in several studies.^{1,21–23}

Diagnosis of neutrophilic cholangitis requires liver biopsy and histopathology. Bile culture is recommended to identify a causative agent and yields higher positive culture rates than culture of hepatic tissue (36% vs 16%).⁴ The same study reported an increase in positive bile cultures to 64% when cholecystitis was present.⁴ Causative organisms are usually enteric opportunistic pathogens.^{1,4,22,23} The variable antimicrobial sensitivity of this group of organisms highlights the need for culture and sensitivity information. The identification of an unusual pathogen, *P. rettgeri*, in this cat further emphasises the role of appropriate culture samples.

Bacteria in the *Providencia* genus are considered gastrointestinal commensals and have been isolated from various animals, as well as soil and sewage water.¹⁰ Their clinical significance lies mostly as opportunistic and nosocomial pathogens.^{10–12} The organism belongs to the Enterobacteriaceae group, which consists of *Citrobacter*, *Enterobacter*, *Serratia* and *Providencia* (CESP) species, with *Morganella* and *Hafnia* species more recently included.

Providencia species are associated with sporadic nosocomial infections in humans, most commonly of the urinary tract in patients with indwelling urinary catheters.^{10,12,24} *Providencia stuartii*, *P. rettgeri* and *Providencia alcalifaciens* have been implicated as causative agents in human cases of diarrhoea, as well as ocular and neurological infections.^{10,11,25,26} Prior antibiotic

use was identified as a risk factor for extended spectrum β -lactamase-producing *P. stuartii* bacteraemia in humans,¹² but the role prior antibiotic therapy may have played in this cat is unknown. These organisms are rarely reported in the veterinary literature, but *Providencia* species have been reported as a cause of diarrhoea, skin infection and urinary tract infection in dogs.^{13–15}

The initial presentation of seizure activity as a primary complaint in this cat was unusual. The presence of retinal detachment and hypertension was consistent with target organ damage,¹⁶ and hypertensive seizures or hypertensive encephalopathy were initially suspected as the trigger for seizure activity.²⁷ The most common cause of retinal detachment in a geriatric cat is hypertension, with renal disease a common cause of secondary hypertension.¹⁶ IRIS stage 1 renal disease was suspected in our cat owing to the history of poorly concentrated urine, although blood urea nitrogen, creatinine and serum dimethylarginine remained normal. Acromegaly was considered as a differential for the hypertension, but apart from an initial mild hypokalaemia, there were no other clinical signs to support this and no subsequent signs developed. It is possible that hypertension was worsened by discomfort or pain associated with the cholangitis, precipitating a crisis.

Acute hepatic encephalopathy is another plausible differential for the development of seizures. When associated with acute liver failure, hyperammonaemia appears to play a crucial role in type A hepatic encephalopathy, with cerebral oedema and intracranial hypertension also implicated in the pathogenesis.²⁸ Serum albumin and glucose levels remained normal, but ammonia levels were not tested. Hepatic encephalopathy cannot be excluded in this cat, although acute hepatic encephalopathy is less common in veterinary patients.²⁸

Intracranial disease was considered unlikely after metabolic abnormalities and systemic hypertension were identified. There were no further seizures during hospitalisation or in the 8 months since discharge, supporting a metabolic or hypertensive cause for the seizures.

This case highlights the need for thorough metabolic evaluation in patients presenting with neurological signs.

Acute cholangitis in people is recognised as an infectious process, with the institution of appropriate antimicrobial therapy and management of biliary tract obstruction the cornerstones of treatment.¹⁵ Infection is polymicrobial in most bile cultures (62–78% of patients),^{6,8} in contrast to feline cholangitis where 83% of cats had a single bacterial isolate.⁴ Whether this relates to true differences in the bacterial population or less reliable culture results in cats is unclear.

High rates of antimicrobial resistance are common in human cholangitis, with variable resistance patterns reported.^{6–8} Reuken et al⁸ determined that 78% of human

patients with acute cholangitis had received antimicrobial therapy that did not appropriately cover all isolates later cultured from bile. While the polymicrobial nature of infection in many patients was a factor, 29% of patients had multidrug resistant bacteria isolated. In the same study, metronidazole was not found to be effective in 18/19 cases where it was commenced and, as a result, was not recommended as a first-line therapy. This may also have implications in veterinary medicine where metronidazole is commonly a first-line therapy for anaerobic infection, and where the success in culturing anaerobes may be affected by transport or processing delays where a remote laboratory is used.

The Tokyo guidelines for antimicrobial use in acute cholangitis in people recommend bile or blood cultures for all patients, short courses of antibiotics for low-grade cholangitis, and noted that polymicrobial infections with multidrug-resistant organisms were common, complicating treatment.⁹

Conclusions

The identification of *P. rettgeri* as a novel pathogen in a cat serves to highlight the role of bile culture in feline cholecystitis and cholangitis. Enteric pathogens are commonly cultured in cats as in other species, and identification of antimicrobial sensitivity patterns is essential to ensure appropriate antimicrobial therapy.

Feline neutrophilic cholangitis parallels acute cholangitis in people. The experience in human medicine lends important lessons regarding antimicrobial resistance patterns and demonstrates the challenges in selecting appropriate antimicrobials. Bile aspiration is a low-risk procedure,^{22,23} and is an important part of the diagnostic evaluation of cats with sonographic evidence of biliary tract disease to guide appropriate therapy.

Conflict of interest The authors declared no potential conflicts of interest with respect to the research, authorship, and/or publication of this article.

Funding The authors received no financial support for the research, authorship, and/or publication of this article.

ORCID ID Patricia L Newton  <https://orcid.org/0000-0002-0378-4416>

References

- 1 Brain PH, Barrs VR, Martin P, et al. **Feline cholecystitis and acute neutrophilic cholangitis: clinical findings, bacterial isolates and response to treatment in six cases.** *J Feline Med Surg* 2006; 8: 91–103.
- 2 Callahan-Clark JE, Haddad JL, Brown DC, et al. **Feline cholangitis: a necropsy study of 44 cats (1986–2008).** *J Feline Med Surg* 2011; 13: 570–576.
- 3 Twedt DC, Cullen J, McCord K, et al. **Evaluation of fluorescence in situ hybridization for the detection of bacteria in**

- feline inflammatory liver disease. *J Feline Med Surg* 2013; 162: 109–117.
- 4 Wagner KA, Hartmann FA and Trepanier LA. **Bacterial culture results from liver, gallbladder, or bile in 248 dogs and cats evaluated for hepatobiliary disease: 1998–2003.** *J Vet Int Med* 2007; 21: 417–424.
 - 5 Wah DLC, Christophi C and Muralidharan V. **Acute cholangitis: current concepts.** *ANZ J Surg* 2017; 87: 554–559.
 - 6 Sahu MK, Chacko A, Dutta AK, et al. **Microbial profile and antibiotic sensitivity pattern in acute bacterial cholangitis.** *Indian J Gastroenterol* 2011; 30: 204–208.
 - 7 Shenoy SM, Shenoy S, Gopal BV, et al. **Clinicomicrobiological analysis of patients with cholangitis.** *Indian J Med Microbiol* 2014; 32: 157–160.
 - 8 Reuken PA, Torres D, Baier M, et al. **Risk factors for multidrug resistant pathogens and failure of empiric first-line therapy in acute cholangitis.** *PLoS One* 2017; 12: e0169900. DOI: 10.1371/journal.pone.0169900.
 - 9 Tanaka A, Tadahiro T, Yoshifumi K, et al. **Antimicrobial therapy for acute cholangitis: Tokyo guidelines.** *J Hepatobiliary Pancreat Surg* 2007; 14: 59–67.
 - 10 dosSantos GS, Solidonio EG, Costa MC, et al. **Study of the Enterobacteriaceae group CESP (*Citrobacter*, *Enterobacter*, *Serratia*, *Providencia*, *Morganella* and *Hafnia*): a review.** In: Méndez-Vilas (ed). *The battle against microbial pathogens: basic science, technological advances and educational programs e-book*. Vol 2. Badajoz: Formatex, 2015, pp 794–805.
 - 11 Mohr O'Hara C, Brenner FW and Miller JM. **Classification, identification and clinical significance of *Proteus*, *Providencia*, and *Morganella*.** *Clin Microbiol Rev* 2000; 13: 534–546.
 - 12 Choi HK, Kim YK, Kim HY, et al. **Clinical and microbiological features of *Providencia* bacteremia: experience at a tertiary care hospital.** *Korean J Intern Med* 2015; 30: 219–225.
 - 13 Wong C, Epstein SE and Westropp JL. **Antimicrobial susceptibility patterns in urinary tract infections in dogs (2010–2013).** *J Vet Intern Med* 2015; 29: 1045–1052.
 - 14 Mohr AJ, Van Der Merwe LL, Van Der Lugt JJ, et al. **Primary bacterial enteritis caused by *Providencia alcalifaciens* in three dogs.** *Vet Rec* 2002; 150: 52–53.
 - 15 Papadogiannakis ED, Perimeni E, Velonakis V, et al. ***Providencia stuartii* infection in a dog with severe skin ulceration and cellulitis.** *J Small Anim Pract* 2007; 48: 343–345.
 - 16 Komáromy AM, Andrew SE, Denis HM, et al. **Hypertensive retinopathy and choroidopathy in a cat.** *Vet Ophthalmol* 2004; 7: 3–9.
 - 17 van den Ingh TSGAM, Cullen JC, Twedt DC, et al. **Morphological classification of biliary disorders of the canine and feline liver.** In: WSAVA standards for clinical and histological diagnosis of canine and feline liver diseases. Edinburgh: WB Saunders, 2006, pp 61–76.
 - 18 van den Ingh TSGAM, Van Winkle T, Cullen JM, et al. **Morphological classification of parenchymal disorders of the canine and feline liver: 2. Hepatocellular death, hepatitis and cirrhosis.** In: WSAVA standards for clinical and histological diagnosis of canine and feline liver diseases. Edinburgh: WB Saunders, 2006, pp 85–101.
 - 19 Messias A, Gekeler F, Wegener A, et al. **Retinal safety of a new fluoroquinolone, pradofloxacin, in cats.** *Doc Ophthalmol* 2008; 116: 177–191.
 - 20 Boland L and Beatty J. **Feline cholangitis.** *Vet Clin North Am Small Anim Pract* 2017; 47: 703–724.
 - 21 Marolf AJ, Leach L, Gibbons DS, et al. **Ultrasonographic findings of feline cholangitis.** *J Am Anim Hosp Assoc* 2012; 48: 36–42.
 - 22 Policelli-Smith R, Gookin JL, Smolski W, et al. **Association between gallbladder ultrasound findings and bacterial culture of bile in 70 cats and 202 dogs.** *J Vet Intern Med* 2017; 31: 1451–1458.
 - 23 Schiborra F, McConnell JF and Maddox TW. **Percutaneous ultrasound-guided cholecystocentesis: complications and association of ultrasonographic findings with bile culture results.** *J Small Anim Pract* 2017; 58: 389–394.
 - 24 Tumbarello M, Citton R, Spanu T, et al. **ESBL-producing multidrug-resistant *Providencia stuartii* infection in a university hospital.** *J Antimicrob Chemother* 2004; 53: 277–282.
 - 25 Shima A, Hinenoya A, Asakura M, et al. **Molecular characterizations of cytotoxic distending toxin produced by *Providencia alcalifaciens* strains isolated from patients with diarrhea.** *Infect Immun* 2012; 80: 1323–1332.
 - 26 Koreschi AF, Schechter BA and Karp CL. **Ocular infections caused by *Providencia rettgeri*.** *Ophthalmology* 2006; 113: 1463–1466.
 - 27 Brown CA, Munday JS, Mathur S, et al. **Hypertensive encephalopathy in cats with reduced renal function.** *Vet Pathol* 2005; 42: 642–649.
 - 28 Lidbury JA, Cook AK and Steiner JM. **Hepatic encephalopathy in dogs and cats.** *J Vet Emerg Crit Care* 2016; 26: 471–487.