



Extranodal non-B, non-T-cell lymphoma with bilateral tympanic bulla involvement in a cat

Authors: Kerns, Austin T, Brakel, Kelsey A, Premanandan, Christopher, Saffire, Ashlie, and Moore, Sarah A

Source: Journal of Feline Medicine and Surgery Open Reports, 4(1)

Published By: SAGE Publishing

URL: <https://doi.org/10.1177/2055116918756724>

BioOne Complete (complete.BioOne.org) is a full-text database of 200 subscribed and open-access titles in the biological, ecological, and environmental sciences published by nonprofit societies, associations, museums, institutions, and presses.

Your use of this PDF, the BioOne Complete website, and all posted and associated content indicates your acceptance of BioOne's Terms of Use, available at www.bioone.org/terms-of-use.

Usage of BioOne Complete content is strictly limited to personal, educational, and non - commercial use. Commercial inquiries or rights and permissions requests should be directed to the individual publisher as copyright holder.

BioOne sees sustainable scholarly publishing as an inherently collaborative enterprise connecting authors, nonprofit publishers, academic institutions, research libraries, and research funders in the common goal of maximizing access to critical research.



Extranodal non-B, non-T-cell lymphoma with bilateral tympanic bulla involvement in a cat

Austin T Kerns¹, Kelsey A Brakel²,
Christopher Premanandan², Ashlie Saffire³ and Sarah A Moore¹

Journal of Feline Medicine and Surgery Open Reports
1–5

© The Author(s) 2018

Reprints and permissions:

sagepub.co.uk/journalsPermissions.nav

DOI: 10.1177/2055116918756724

journals.sagepub.com/home/jfmsopenreports

This paper was handled and processed
by the American Editorial Office (AAFP)
for publication in *JFMS Open Reports*



Abstract

Case summary A 9-year-old spayed female domestic shorthair cat with clinical signs suggestive of chronic recurrent otitis media and recent seizures was presented with multifocal nervous system disease, including bilateral central and/or peripheral vestibular, cerebellar and forebrain deficits. Prior to presentation, there was inadequate improvement after 6 weeks of treatment for bilateral middle ear effusion from which a highly susceptible *Staphylococcus* species was cultured. This was followed by the development of seizures. Results of a complete blood count and serum chemistry were unremarkable, and a previous feline leukemia virus/feline immunodeficiency virus ELISA was negative. The cat was hospitalized overnight and had multiple seizures. The following morning the cat's mentation worsened, and the cat lost ventilatory drive after induction for anesthesia in preparation for MRI. A brain herniation event was suspected, and the cat was euthanized prior to further diagnostics. On post-mortem examination both tympanic bullae were filled with a soft, tan-colored material. Histologically, this material was composed of neoplastic lymphocytes. In addition, neoplastic lymphocytes were found in the leptomeninges, brain parenchyma, submandibular lymph nodes and pancreas. The neoplastic lymphocytes were negative for both B- and T-lymphocyte immunohistochemical markers and PCR for antigen receptor rearrangements failed to amplify target DNA, indicating non-B, non-T-cell lymphoma.

Relevance and novel information To our knowledge, this is the first report of lymphoma with confirmed bilateral tympanic bulla involvement in the human and veterinary literature. Neoplasia should be considered in cases of middle-ear effusion that do not improve adequately with appropriate antimicrobial therapy.

Accepted: 6 January 2018

Introduction

While lymphoma is the most common type of neoplasia in cats, lymphoma with tympanic bulla involvement is rare, with only three previous reports in the veterinary literature.^{1–3} Here we report a unique case of extranodal lymphoma involving both tympanic bullae in a cat and causing bilateral neoplastic middle-ear effusion that initially mimicked infectious otitis media interna.

Case description

A 9-year-old, spayed female, domestic shorthair cat was first presented to the primary veterinarian on 10 May 2016 for acute onset of ataxia and right head tilt, and a chronic history of recurrent otitis externa. The cat had been kept strictly indoors in a single-cat home. The cat

was administered cefovecin sodium (8 mg/kg SC once [Convenia; Zoetis]) and gentamicin sulfate 0.3%/beta-methasone valerate 0.1%/clotrimazole 1.0% (4 drops

¹Department of Veterinary Clinical Sciences, The Ohio State University College of Veterinary Medicine, Columbus, OH, USA

²Department of Veterinary Biosciences, The Ohio State University College of Veterinary Medicine, Columbus, OH, USA

³Cats Only Veterinary Clinic, Columbus, OH, USA

Corresponding author:

Sarah A Moore DVM, DACVIM-Neurology, The Ohio State University Veterinary Medical Center, 601 Vernon L Tharp St, Columbus, OH 43210, USA
Email: moore.2204@osu.edu



Creative Commons Non Commercial CC BY-NC: This article is distributed under the terms of the Creative Commons

Attribution-NonCommercial 4.0 License (<http://www.creativecommons.org/licenses/by-nc/4.0/>) which permits non-commercial use, reproduction and distribution of the work without further permission provided the original work is attributed as specified on the SAGE and Open Access pages (<https://us.sagepub.com/en-us/nam/open-access-at-sage>).

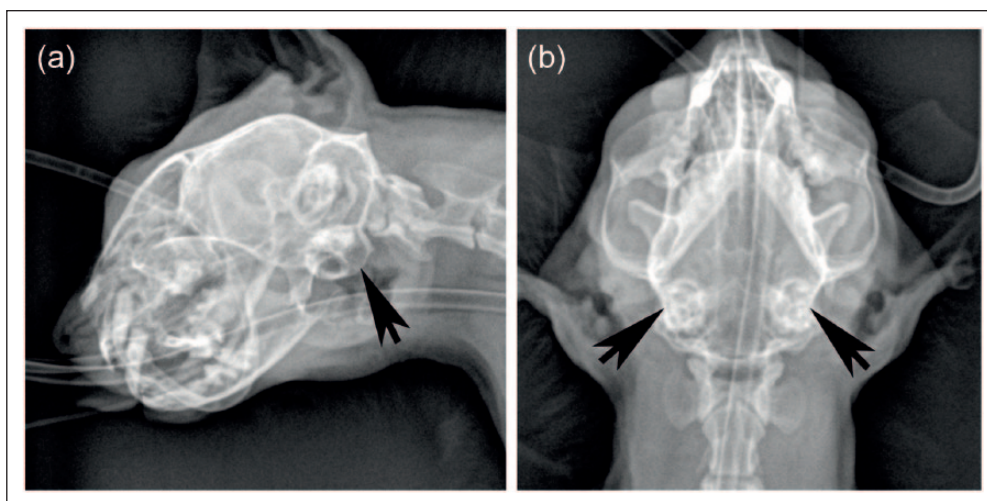


Figure 1 Radiographs of the tympanic bullae (arrows). (a) Left lateral oblique and (b) ventrodorsal images. The tympanic bullae are thickened and irregular, and filled with soft tissue-dense material

both ears [AU] q12h for 2 weeks [Otomax; Merck]) for presumptive recurrence of otitis media. The cat was presented again after 2 weeks, without improvement, following a suspected generalized seizure. An approximately 10 s episode was witnessed at home where the cat was laterally recumbent, body stiffened and legs extended, with inappropriate vocalization immediately preceding the episode. Results of a complete blood count (CBC) were within normal limits, and serum chemistry revealed elevated total protein (9.1 g/dl; reference interval [RI] 5.4–8.2 g/dl), with an albumin of 4.4 g/dl (RI 2.2–4.4 g/dl) and globulins of 4.7 g/dl (RI 1.5–5.7 g/dl). Results of feline leukemia virus (FeLV) antigen and feline immunodeficiency virus antibody testing (SNAP FeLV/FIV Combo Test; IDEXX Laboratories) performed in August 2015 were negative. Cefovecin sodium injection was repeated (8 mg/kg SC once [Convenia; Zoetis]) and orbifloxacin (6 mg/kg PO q24h for 1 week [Orbax; Merck]) was initiated.

The cat was presented to another general practice clinic on 27 May 2016 for a second opinion. Physical examination revealed a vestibular ataxia and right head tilt. A large amount of fluid was visible in both external ear canals on otoscopic examination. Anesthetized oral examination did not reveal any evidence of a nasopharyngeal polyp and was otherwise unremarkable. Radiographs showed that both tympanic bullae were thickened and irregular, and filled with soft tissue-dense material (Figure 1). A more in-depth otoscopic examination revealed fluid and brown, waxy debris in the external ear canal AU.

The fluid and wax were removed with suction, and both tympanic membranes were visualized and noted to be intact but thickened. A myringotomy was performed AU using a 3.5 Fr rigid polyurethane catheter (Tomcat;

MILA International). Approximately 1 ml sterile saline was injected and aspirated back from the tympanic bullae. The middle and external ears were flushed with sterile saline AU. Samples were submitted for cytology and bacterial culture. Cytology revealed mild mixed inflammation with neutrophils, macrophages, and rare mature lymphocytes, and a large number of bacterial cocci. Neoplastic cells were not identified. Bacterial culture grew a highly susceptible hemolytic *Staphylococcus* species. The cat's ataxia and head tilt improved after starting prednisone (1.3 mg/kg PO q24h [Prednisone tablets USP; West-Ward Pharmaceuticals]), enrofloxacin 0.5%/silver sulfadiazine 1.0% emulsion (3 drops AU q12h [Baytril Otic; Bayer]) and continuing orbifloxacin as previously prescribed, but the cat continued to have daily seizures, became lethargic, stopped grooming itself and had reduced food and water intake.

The cat was presented to the neurology service at The Ohio State University Veterinary Medical Center on 22 June 2016 for further evaluation. The cat was confirmed to have been fed a complete and balanced commercial diet. The cat was mildly obtunded with bilateral elevation of the third eyelids. The cat weighed 3.7 kg (body condition score 3/5). Rectal temperature was 98.4°F (37.0°C), and thoracic auscultation and abdominal palpation were within normal limits. There was moderate brown ceruminous debris AU. Peripheral lymph nodes were palpably within normal limits. The cat had ambulatory tetraparesis with a significant vestibular and cerebellar ataxia, had a tendency to circle to the right, had a right head tilt, low head carriage, intention tremors and occasional wide head excursions to both sides. Cranial nerve examination revealed bilateral facial paralysis with normal facial sensation, rhythmic constriction and dilation of the pupils (hippus) in response

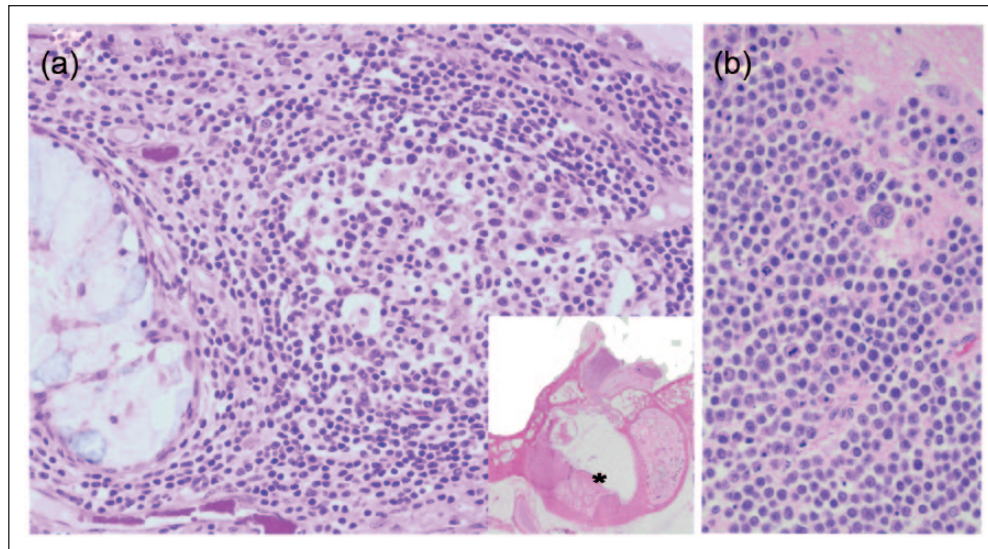


Figure 2 Histologic features of neoplastic lymphocytes. (a) Middle ear and (b) brain. There are neoplastic lymphocytes in the dorsolateral and ventromedial compartments of the middle ear, the semicircular canals, and eroding the petrous bone and tympanic bullae. Also filling the middle ear is abundant cellular debris, hemorrhage and acicular clefts. The ceruminous glands are hyperplastic. Neoplastic lymphocytes are frequently multinucleate, with marked anisocytosis and anisokaryosis, and display marked mitotic activity. Hematoxylin and eosin ($\times 400$). (Inset) Hematoxylin and eosin ($\times 20$); asterisk indicates the location where higher magnification image is taken from

to light in both eyes (OU), and an absent oculocephalic reflex. Menace response was normal OU, and the remainder of the cranial nerve examination was unremarkable. While there was bilateral elevation of the third eyelids, the cat did not appear enophthalmic or have miotic pupils (to suggest Horner's syndrome). Proprioception was decreased in all limbs. Segmental reflexes were normal. Neurologic abnormalities and a history of suspected seizures were consistent with multifocal nervous system involvement, including bilateral central and/or peripheral vestibular, cerebellar and forebrain disease. Primary differential diagnoses based on history, previous diagnostic results and initial patient evaluation were bilateral infectious otitis media interna with intracranial extension, or neoplasia.

Results of a CBC were within normal limits, and serum chemistry revealed elevated albumin (4.1 g/dl; RI 2.5–3.5 g/dl) and total calcium (10.7 mg/dl; RI 8.4–10.1 mg/dl), most consistent with dehydration. The cat was hospitalized in the intensive care unit for monitoring and isotonic crystalloid fluid support (14 ml/h IV [Plasma-Lyte A; Baxter]) and was initially given levetiracetam (60 mg/kg IV once [Levetiracetam injection, USP; AuroMedics Pharma]) after a seizure. A loading protocol for phenobarbital was initiated (3 mg/kg IV q8h for 24 h [Phenobarbital sodium injection, USP; West-Ward Pharmaceuticals]) and later a midazolam constant rate infusion (CRI) (0.25 mg/kg/h [Midazolam injection, USP; Gland Pharma]) after additional seizures occurred over the next several hours. No additional seizures

occurred after starting the midazolam CRI, and the cat's vital parameters and previous neurologic status remained static.

The following morning the neurologic examination was unchanged compared with presentation. Later that morning the cat was noted to be more obtunded with normal vital parameters when examined in preparation for general anesthesia for MRI and cerebrospinal fluid (CSF) collection. No premedication was administered, the cat was induced with propofol (4 mg/kg IV [Diprivan; NovaPlus]) and intubated with a 4.0 mm endotracheal tube. The cat immediately became apneic, and was then maintained with total intravenous anesthesia using propofol (0.4 mg/kg/min), 100% oxygen and mechanical ventilation. The propofol CRI was decreased and then stopped without return of ventilation. The sudden deterioration in mentation just prior to anesthesia and the lack of ventilatory drive after induction were suggestive of a brain herniation event. After discussion with the owner, humane euthanasia was elected without MRI or CSF collection.

On post-mortem examination, the submandibular lymph nodes were subjectively moderately enlarged, and both tympanic bullae were filled with a soft, tan-colored material that appeared to be cerumen and suppurative exudate. A preliminary diagnosis of severe suppurative bilateral otitis media was made based on gross findings. However, histologically the soft material in both bullae was composed primarily of neoplastic lymphocytes (Figure 2).

The bullae were filled with sheets of round cells that exhibited scant-to-moderate amphiphilic cytoplasm with marked anisocytosis and moderate anisokaryosis. Nuclei were centrally located, with coarsely stippled chromatin and a single prominent central nucleolus. Cells were frequently multinucleate, and there were 85 mitotic figures per ten \times 400 fields. The neoplastic lymphocytes partially effaced cranial nerves in the bullae bilaterally, and were also found in the leptomeninges, brain parenchyma, submandibular lymph nodes and pancreas, supporting a diagnosis of extranodal lymphoma (Figure 2). Neoplastic lymphocytes labeled negative for CD3, CD18, CD20, CD45, CD79a, CD204, Pax5, cytokeratin, chromogranin and vimentin. Molecular clonality analysis with PCR for antigen receptor rearrangements (PARR) was performed using highly cellular paraffin-embedded tissue scrolls from all affected tissues. PARR failed to amplify in most tissues and was weakly polyclonal or pseudoclonal in others. Based on the negative immunohistochemical labeling and PARR, and the cellular morphology, the neoplasm was diagnosed as non-B, non-T-cell lymphoma.

Discussion

Feline middle-ear disease is uncommon relative to other species, with diseases reported to affect the middle ear in cats including infectious otitis media, inflammatory polyps and neoplasia.¹ A recent publication described a cholesterol granuloma associated with otitis media in a cat, which had not previously been documented in cats but is common in people.⁴ Bulla effusion has also been found to be relatively common in cats with sinonasal disease, with some affected cats having bilateral bulla effusion.⁵ Bulla effusion in these cases is thought to be secondary to auditory tube dysfunction, and the significance of this finding is currently unknown.

Neoplasia of the middle ear is uncommon in any species and typically a result of extension from the external ear canal. Squamous cell carcinoma is the most common malignancy affecting the middle ear in dogs and cats.⁶ Lymphoma affecting the feline tympanic bullae appears to be extremely rare, with only three previously reported cases.¹⁻³ Two of these cats were immunophenotyped, which confirmed T-cell lymphoma.^{2,3} One cat with T-cell lymphoma was euthanized approximately 1 week after diagnosis prior to starting radiation therapy and systemic chemotherapy,² and the other died a week after starting radiation therapy.³ In people, there are <30 cases of lymphoma of the middle ear reported in the medical literature.⁷⁻¹³ Review of these cases suggests that non-Hodgkin lymphoma is most common, with an approximately equal distribution of B-cell and T-cell neoplasms. There are no reports of lymphoma affecting the middle ear in dogs.¹⁴

Our cat was initially presumed and eventually confirmed to have bacterial otitis media/interna that had

not responded appropriately to antimicrobial therapy. Middle-ear neoplasia can result in secondary otitis media or directly mimic the common clinical signs of otitis media/interna, including aural discomfort, ipsilateral peripheral vestibular signs, facial nerve deficits and Horner's syndrome. Indeed, this appears to be a key historical component in nearly all previously reported cases of middle-ear lymphoma in cats and people.^{1-3,6,7,10-12} A large majority of people entered remission once an accurate diagnosis was made and treatment was initiated. Thus, cases with presumed or confirmed chronic otitis media/interna that lack adequate response to antimicrobial therapy warrant further investigation to limit delay of appropriate treatment and prevent further progression of disease.

The majority of feline lymphomas are extranodal,¹⁵ with the most common extranodal site being gastrointestinal.¹⁶ Other extranodal subtypes include mediastinal, cutaneous, nasal, renal, laryngeal, tracheal, central nervous system and ocular lymphoma. Mediastinal lymphoma associated with FeLV infection was previously the most recognized extranodal subtype but is now uncommon owing to effective vaccination programs.¹⁷

The most important prognostic factor in feline lymphoma is response to treatment, regardless of anatomic location.¹⁵ In a study of 110 cats with extranodal lymphoma, those cats that entered complete remission had a median survival of 11.2 months compared with cats with incomplete or no response having a median survival of 2 months.¹⁸ Other prognostic factors include stage, substage, FeLV status, grade and anatomic site.¹⁹⁻²¹ The contribution of immunophenotype to prognosis in feline lymphoma is poorly understood because few treated cats are immunophenotyped. For example, in the previously referenced study of 110 cats with extranodal lymphoma, none was immunophenotyped.¹⁸ The paucity of reported cases of lymphoma involving the middle ear in the human and veterinary literature makes it difficult to draw any specific conclusions about treatment and prognosis.

In people, non-B, non-T-cell lymphomas are recognized by the expression of common lymphocyte antigens and a lack of B-cell- or T-cell-specific antigens.²² Immunohistochemical investigation of the neoplastic cells collected from multiple tissues in this case revealed that they were negative for all available B-cell, T-cell, round cell, epithelial cell and mesenchymal cell markers but were morphologically consistent with lymphocytes. Lack of clonality with PARR also supported the diagnosis of non-B, non-T-cell lymphoma. Although low yield of target DNA due to the low lymphocyte frequency in the sample could produce similar PARR results, the tissue scrolls used were highly cellular making this unlikely. While it is unusual to have a lack of any cell marker, we suspect that these lymphocytes were so

poorly differentiated that they lacked expression of any normal immunohistochemical markers.

Ante-mortem palpation of our cat's lymph nodes did not reveal any lymphadenopathy, but post-mortem moderate submandibular lymphadenomegaly was noted and neoplastic cells were subsequently found in these lymph nodes. If this was discovered on initial physical examination, fine-needle aspiration or biopsy of the submandibular lymph nodes may have achieved an ante-mortem diagnosis and allowed for initiation of treatment.

Infectious disease testing, including tests for cryptococcosis and toxoplasmosis, were not performed in this case. Given the cat's condition and expected delay in infectious disease testing results, we elected to pursue MRI and CSF collection to help confirm a diagnosis, guide treatment and select appropriate infectious disease testing for submission the day of the scheduled MRI.

While we elected to place the cat under general anesthesia for a brain MRI, other imaging modalities may have been utilized to reduce the risk associated with general anesthesia. For example, a conscious or sedated CT scan may have provided adequate imaging detail to determine the extent of disease, including submandibular lymphadenopathy, allowing for fine-needle aspiration to confirm a diagnosis and initiate treatment.

Conclusions

Lymphoma affecting the middle ear is exceedingly rare in cats, dogs and people, and this report represents the fourth cat described with lymphoma of the middle ear. Although uncommon, middle-ear neoplasia should be considered in cases of middle-ear effusion, particularly when disease does not respond to appropriate antimicrobial therapy. Because of the limited number of cases and lack of attempted treatment in cats, prognosis associated with treatment for lymphoma of the feline middle ear is currently unknown.

Conflict of interest The authors declared no potential conflicts of interest with respect to the research, authorship, and/or publication of this article.

Funding The authors received no financial support for the research, authorship, and/or publication of this article.

References

- 1 Trevor PB and Martin RA. **Tympanic bulla osteotomy for treatment of middle-ear disease in cats: 19 cases (1984–1991).** *J Am Vet Med Assoc* 1993; 202: 123–128.
- 2 Lorimier LP, Alexander SD and Fan TM. **T-cell lymphoma on the tympanic bulla in a feline leukemia virus-negative cat.** *Can Vet J* 2003; 44: 987–989.
- 3 Santagostino SF, Mortellaro CM, Buchholz J, et al. **Primary angiocentric/angioinvasive T-cell lymphoma of the**

- tympanic bulla in a feline leukemia virus-positive cat.** *JFMS Open Rep* 2015; 1: 2055116915593966.
- 4 Van der Heyden S, Butaye P and Roels S. **Cholesterol granuloma associated with otitis media and leptomeningitis in a cat due to *Streptococcus canis* infection.** *Can Vet J* 2013; 54: 72–73.
- 5 Detweiler DA, Johnson LR, Kass PH, et al. **Computed tomographic evidence of bulla effusion in cats with sinonasal disease: 2001–2004.** *J Vet Intern Med* 2006; 20: 1080–1084.
- 6 Sula MJ. **Tumors and tumorlike lesions of dog and cat ears.** *Vet Clin North Am Small Anim Pract* 2012; 42: 1161–1178.
- 7 Merkus P, Copper MP, Van Oers MHJ, et al. **Lymphoma in the ear.** *J Otorhinolaryngol Relat Spec* 2000; 62: 274–277.
- 8 Solanellas J, Esteban F, Soldado L, et al. **Hodgkin's disease of middle ear and mastoid.** *J Laryngol Otol* 1996; 110: 869–871.
- 9 Ho TP, Carrie S, Meikle KM, et al. **T-cell lymphoma presenting as acute mastoiditis with a facial palsy.** *Int J Ped Otor* 2004; 68: 1199–1201.
- 10 Siddiahgari SR, Yerukula P, Lingappa L, et al. **Rare clinical presentation of diffuse large B-cell lymphoma as otitis media and facial palsy.** *J Ped Neurosci* 2016; 11: 58–60.
- 11 Kanzaki S, Saito H, Mori T, et al. **Thirteen-month-old boy with malignant lymphoma having symptoms mimicking acute otitis media and mastoiditis with facial palsy.** *ORL J Otorhinolaryngol Relat Spec* 2011; 73: 266–270.
- 12 Lang EE, Walsh RM and Leader M. **Primary middle-ear lymphoma in a child.** *J Laryngol Otol* 2003; 117: 205–207.
- 13 Li B, Liu S, Yang H, et al. **Primary T-cell lymphoblastic lymphoma in the middle ear.** *Int J Ped Otor* 2016; 82: 19–22.
- 14 Fan TM and de Lorimier LP. **Inflammatory polyps and aural neoplasia.** *Vet Clin North Am Small Anim Pract* 2004; 34: 489–509.
- 15 Moore A. **Extranodal lymphoma in the cat: prognostic factors and treatment options.** *J Feline Med Surg* 2013; 15: 379–390.
- 16 Barrs VR and Beatty JA. **Feline alimentary lymphoma: 1 Classification, risk factors, clinical signs and non-invasive diagnostics.** *J Feline Med Surg* 2012; 14: 182–190.
- 17 Stutzer B, Simon K, Lutz H, et al. **Incidence of persistent viraemia and latent feline leukaemia virus infection in cats with lymphoma.** *J Feline Med Surg* 2011; 13: 81–87.
- 18 Taylor SS, Goodfellow MR, Browne WJ, et al. **Feline extranodal lymphoma: response to chemotherapy and survival in 110 cats.** *J Small Anim Pract* 2009; 50: 584–592.
- 19 Mooney SC and Hayes AA. **Lymphoma in the cat: an approach to diagnosis and management.** *Semin Vet Med Surg (Small Anim)* 1986; 1: 51–57.
- 20 Vail DM, Moore AS, Ogilvie GK, et al. **Feline lymphoma (145 cases): proliferation indices, cluster of differentiation 3 immunoreactivity, and their association with prognosis in 90 cats.** *J Vet Intern Med* 1998; 12: 349–354.
- 21 Moore PF, Rodriguez-Bertos A and Kass PH. **Feline gastrointestinal lymphoma: mucosal architecture, immunophenotype, and molecular clonality.** *Vet Pathol* 2012; 49: 658–668.
- 22 Karube K, Ohshima K, Tsuchiya T, et al. **Non-B, non-T neoplasms with lymphoblast morphology further clarification and classification.** *Am J Surg Pathol* 2003; 27: 1366–1374.