



Traumatic L7 articular processes fracture and spondylolisthesis following dorsal lumbosacral laminectomy in a cat

Authors: Suñol, Anna, Montoliu, Patricia, López, Marta, Mascort, Joan, and Morales, Carles

Source: Journal of Feline Medicine and Surgery Open Reports, 4(1)

Published By: SAGE Publishing

URL: <https://doi.org/10.1177/2055116918760652>

BioOne Complete (complete.BioOne.org) is a full-text database of 200 subscribed and open-access titles in the biological, ecological, and environmental sciences published by nonprofit societies, associations, museums, institutions, and presses.

Your use of this PDF, the BioOne Complete website, and all posted and associated content indicates your acceptance of BioOne's Terms of Use, available at www.bioone.org/terms-of-use.

Usage of BioOne Complete content is strictly limited to personal, educational, and non - commercial use. Commercial inquiries or rights and permissions requests should be directed to the individual publisher as copyright holder.

BioOne sees sustainable scholarly publishing as an inherently collaborative enterprise connecting authors, nonprofit publishers, academic institutions, research libraries, and research funders in the common goal of maximizing access to critical research.



Traumatic L7 articular processes fracture and spondylolisthesis following dorsal lumbosacral laminectomy in a cat

Journal of Feline Medicine and Surgery Open Reports
1–6

© The Author(s) 2018

Reprints and permissions:

sagepub.co.uk/journalsPermissions.nav

DOI: 10.1177/2055116918760652

journals.sagepub.com/home/jfmsopenreports

This paper was handled and processed by the European Editorial Office (ISFM) for publication in *JFMS Open Reports*



Anna Suñol , Patricia Montoliu, Marta López, Joan Mascort and Carles Morales

Abstract

Case summary A 12-year-old neutered male domestic shorthair cat was presented to our referral hospital with a chronic history of tenesmus and lumbosacral pain. A diagnosis of degenerative lumbosacral stenosis (DLSS) was made and a standard dorsal L7–S1 laminectomy was performed uneventfully, with complete recovery within 1 month. The cat was brought back 4 months later for investigation of lumbosacral pain after having suffered a minor traumatic event. Neurological examination identified a low tail carriage, weakness, exercise intolerance, left pelvic limb lameness and diminished withdrawal reflexes in both pelvic limbs with severe sacrocaudal pain. A traumatic facet fracture of the L7 articular processes and subsequent spondylolisthesis was diagnosed. A second surgery was performed to stabilise the region. The cat was normal on neurological examination 1 month later and no further clinical signs were noted.

Relevance and novel information This is the first description of a fracture and spondylolisthesis as a possible postoperative complication after L7–S1 dorsal laminectomy in a cat. The case highlights the importance of postoperative changes in the supportive structures of the lumbosacral spine in cats after surgical treatment of DLSS.

Accepted: 23 January 2018

Introduction

Degenerative lumbosacral stenosis (DLSS) is a complex and multifactorial syndrome characterised by Hansen type II disc protrusion, hypertrophied soft tissues (ligamentous and synovial structures), osteophytosis of the lumbosacral joint, lumbosacral ventral spondylosis, spondylolisthesis and instability.¹ In contrast to dogs, clinically significant DLSS has been infrequently seen in cats.^{2–4}

Treatment options described for DLSS in cats include conservative or surgical management.² The most utilised surgical technique to treat DLSS is a dorsal laminectomy with dorsal annulectomy and nuclear extirpation of the affected intervertebral disc.³ Several reports have described this technique either alone or followed by lumbosacral stabilisation.^{2–4} Objective criteria to aid in deciding between medical and surgical management in cats are lacking. Moreover, once surgical management

has been decided upon, the need for subsequent lumbosacral stabilisation following dorsal laminectomy in animals is currently not standardised and depends on subjective evaluation of the severity of the clinical signs, the diagnostic imaging findings, in-surgery assessment of the stability of the affected region and the neurosurgeon's preference.

Postoperative complications of DLSS in cats have scarcely been reported. In dogs, perioperative

Neurology and Neurosurgery Department, Ars Veterinary Hospital, Barcelona, Spain

Corresponding author:

Anna Suñol Lda Vet, Ars Veterinary Hospital, Carrer Cavallers n°37, Barcelona, Catalunya 08034, Spain
Email: annasunoliniesta@gmail.com



Creative Commons Non Commercial CC BY-NC: This article is distributed under the terms of the Creative Commons

Attribution-NonCommercial 4.0 License (<http://www.creativecommons.org/licenses/by-nc/4.0/>) which permits non-commercial use, reproduction and distribution of the work without further permission provided the original work is attributed as specified on the SAGE and Open Access pages (<https://us.sagepub.com/en-us/nam/open-access-at-sage>).

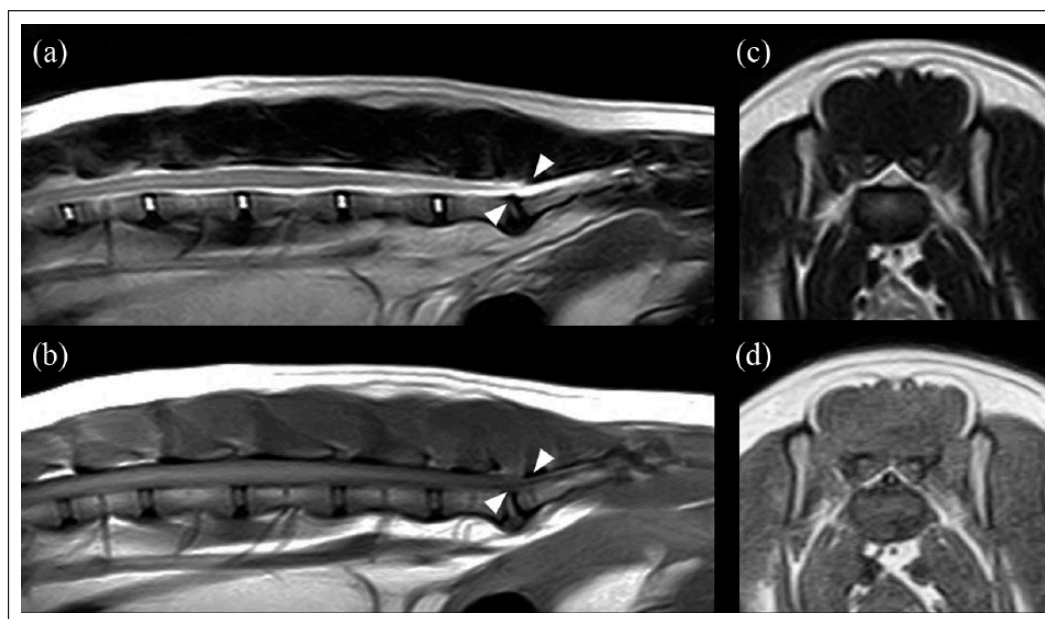


Figure 1 MRI of the lumbosacral vertebral column was performed using a 0.2 Tesla unit (Esaote Grande, Genova). (a) T2-weighted sagittal plane, (b) T1-weighted sagittal plane, (c) T2-weighted transverse plane and (d) T1-weighted transverse plane. The L7–S1 intervertebral disc had low signal intensity in T2-weighted images, consistent with mild disc degeneration. Slight protrusion of the disc was also present. There was downward elongation of the sacral lamina into the vertebral canal. Dorsal and ventral stenosis of the vertebral canal with compression of the nerve roots at the level of the sacrum was also observed (arrowheads). New bone formation observed bilaterally and ventrally to the lumbosacral joint indicated the presence of spondylosis deformans. A diagnosis of degenerative lumbosacral stenosis was made

complications include seroma formation,⁵ iatrogenic trauma to the cauda equina,⁵ chronic urinary incontinence (in most cases, already present before surgery),^{5,6} recurrent herniation of the operated and adjacent intervertebral discs,^{5,6} and fractures of the articular processes.^{7–9}

In humans, complications following laminectomy are well described,¹⁰ including secondary instability due to excessive excision of the posterior ligamentous complex (PLC) during lumbar decompression.¹¹ Moreover, fracture of the remaining osseous structures due to traumatic events or stress fractures have also been reported, although uncommonly.^{11–14}

This case report describes a traumatic bilateral fracture of L7 articular processes and spondylolisthesis in a cat, 4 months after a dorsal lumbosacral laminectomy for DLSS, with subsequent surgery for stabilisation.

Case description

A 12-year-old neutered male domestic shorthair cat was presented to the Neurology and Neurosurgery Service of the Hospital **ArS Veterinaria** with a chronic history of tenesmus and lumbosacral pain. At initial presentation, the neurological examination was normal except from a low tail carriage and marked pain at the lumbosacral region. Radiography and MRI (0.2 Tesla unit; Esaote Grande) of the lumbosacral vertebral column were

consistent with mild DLSS (Figure 1), and lumbosacral decompressive surgery was recommended.

Methadone (0.3 mg/kg [Metasedin; Esteve]), alfaxalone (1 mg/kg [Alfaxan; Dechra]) and midazolam (0.2 mg/kg [Midazolam; Normon]) were administered intravenously as premedication. Anaesthesia was induced with alfaxalone (1 mg/kg [Alfaxan; Dechra]) and midazolam (0.2 mg/kg IV [Midazolam; Normon]) and maintained with inhaled isoflurane (Isovet; Braun) and 100% oxygen. Cephalexin (25 mg/kg [Cefazolina Normon; Normon Laboratories]) and meloxicam (0.1 mg/kg SC [Metacam; Boehringer Ingelheim]) were administered intravenously after induction. A standard dorsal L7–S1 laminectomy preserving the articular facet joints with subsequent annulectomy and discectomy were performed uneventfully.¹⁵ A mild intervertebral disc protrusion was also evident. Moderate dorsal compression of the spinal roots secondary to hypertrophy of the ligament and ventral deviation of the dorsal aspect of the sacrum were also noticed. The laminectomy site was covered with a moisture-stable collagen haemostatic foam sponge (Lyostypt; B.Braun Vetcare, Terrassa). Meloxicam (0.1 mg/kg PO q24h for 5 days [Metacam; Boehringer Ingelheim]), gabapentin (10 mg/kg PO q8h for 10 days [Gabapentina; Teva]) and 4 weeks of strict rest were recommended.

At re-examination 1 week later, the neurological examination was normal and the lumbosacral pain had resolved.

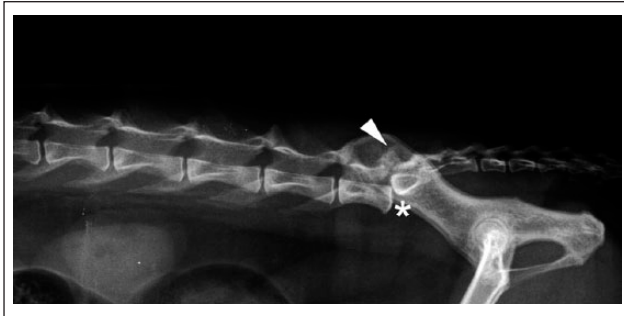


Figure 2 Laterolateral radiography of the lumbosacral region. Notice L7–S1 spondylolisthesis (*), shortening of the lamina of L7 and fracture of the L7 articular facets (arrowhead)

Three weeks later, the owners reported that the cat had completely recovered the ability to defaecate normally.

Four months later, the cat was examined again following a traumatic event at home. The owner had been holding the cat as it had tried to jump, resulting in the cat falling backwards and landing on the floor, after which the cat vocalised. Since then it appeared painful and had been reluctant to ambulate. Neurological examination showed low tail carriage, weakness, exercise intolerance, left pelvic limb lameness and diminished withdrawal reflexes in both pelvic limbs. Severe sacrocaudal pain was also apparent on clinical examination. A lateral radiograph identified L7–S1 traumatic spondylolisthesis, shortening of the lamina of L7 and fracture of the L7 articular facets (Figure 2). A second MRI was performed using a 1.5 Tesla unit (Toshiba Medical EDAN; Japan). T2-weighted (T2W), T1-weighted (T1W) and short tau inversion recovery (STIR) images were acquired in the sagittal plane. Transverse T2W, T1W and T2* images, and dorsal STIR images were also obtained. Post-contrast T1W images were acquired in the sagittal and transverse planes after intravenous administration of gadolinium (0.1 mmol/kg [Gadoteridol; Pro-Hance]). MRI confirmed the abnormalities observed in the radiographs and demonstrated compression of the cauda equina roots. A second surgery to stabilise the vertebrae was recommended but declined by the owners. The cat was discharged with meloxicam (0.1 mg/kg PO q24h for 7 days [Metacam; Boehringer Ingelheim]), gabapentin (10 mg/kg PO q8h for 10 days [Gabapentina; Teva]) and 4 weeks of strict rest. One month later, the owners reported progressive worsening of clinical signs (lumbosacral pain, reluctance to jump and tenesmus). At this point, they agreed to perform the surgical procedure. Anaesthesia was induced using the same protocol described in the first surgery. The surgical approach was made through the previous dorsal access. The residual scar tissue found in the previous surgical area was partially debrided. Once the vertebral canal and nerve roots were identified and exposed, the facet fractures were

localised. The fractures were considered to be unstable and surgical stabilisation was then attempted. Four 1.5 mm screws (Aesculap; Instrumevet) were placed across each L7–S1 facet joint in a cranio-lateral direction. The surgical field was irrigated with sterile solution and dried using gauze sponges in preparation for the application of polymethylmethacrylate (PMMA). A 20 ml aliquot of gentamicin PMMA (Palamed G; Heraeus) in semi-liquid phase was applied dorsally to enshroud all pins, avoiding contact with the dorsal laminectomy site and cauda equine nerve roots. Modelling of the cement bolus was undertaken while performing copious irrigation. Routine closure was performed. Postoperative radiographs showed appropriate placement of screws and PMMA and vertebral realignment (Figure 3).

The cat was discharged 2 days later with a residual, moderate ambulatory paraparesis and mild lumbar pain. Meloxicam (0.1 mg/kg PO q24h for 5 days [Metacam; Boehringer Ingelheim]), gabapentin (10 mg/kg PO q8h for 10 days [Gabapentina; Teva]), cephalexin (25 mg/kg PO q12h for 5 days [Rilexine; Virbac]) and 4 weeks of strict rest were recommended. One month later, the neurological examination was repeated and found to be normal. A telephone follow-up with the owner 4 months later confirmed that no further clinical signs had been observed.

Discussion

The case presented here, similar to what has been previously described in human medicine and dogs,^{8,11} shows a clinical scenario in which the lumbosacral spinal supportive structures become altered following a dorsal laminectomy, with the patient suffering from a traumatic injury to the remaining osseous structures with subsequent fracture and spondylolisthesis.

Spinal anatomy and the elements that guarantee its stability are complex. The PLC is defined in human literature as a functional anatomical unit formed by a group of supportive structures that stabilise the vertebral column. Structurally, it consists of the supraspinous ligament, interspinous ligament, facet capsule ligament and the ligamentum flavum. These then interconnect with the fascia and musculature, acting as an integrated unit.¹⁶ This complex acts by holding the facet joints of the adjacent vertebrae in fixed relation to each other.¹¹ Spondylolisthesis is the slippage or displacement of one vertebra vs another. There are many causes of spondylolisthesis described in humans, including congenital, isthmic (lesion of the pars interarticularis), degenerative (associated with age), traumatic (causing fracture of any part other than the pars interarticularis), pathological (infection or neoplasia) and postoperative (iatrogenic lumbar instabilities).¹⁷ Although this classification is not used in veterinary medicine, in the case reported here isthmic or postoperative spondylolisthesis would be the most probable causes.

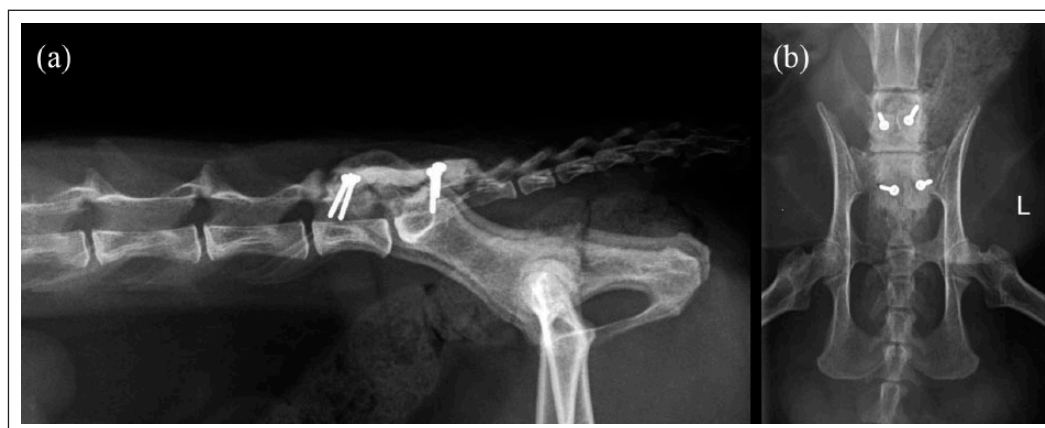

Figure 3 Postoperative (a) laterolateral and (b) ventrodorsal radiographs of the lumbosacral region. Vertebral stabilisation has been achieved using screws and polymethylmethacrylate

Currently, a general consensus about indications for surgery in DLSS is not well established in animals. For those cases with moderate-to-severe neurological deficits or that fail to respond to conservative management, surgical intervention is typically recommended.^{1,18} In human medicine, there is also uncertainty regarding the treatment of lower back pain attributable to degenerative intervertebral disc disease.^{19,20} Furthermore, definitive proof of treatment efficacy for both surgical and non-surgical management in people is lacking.^{20,21} In the case described here, imaging changes of DLSS were mild. However, this cat had a 1 year history of recurrent tenesmus and back pain; therefore, surgery was considered necessary. After the subsequent traumatic event, exercise intolerance was evident. A similar situation known as neurogenic claudication has also been described in humans with DLSS.^{11,12}

There are limited reports describing surgical treatments for DLSS in cats.²⁻⁴ In one retrospective study,³ six cases underwent dorsal laminectomy for lumbosacral intervertebral disc disease without fixation. Owners' surveys reported 'excellent' outcomes in four cats and 'fair' in the remaining two cats.³ In 2008, Cariou et al² described a case of lumbosacral non-traumatic hypermobility or instability treated by dorsal stabilisation using screws and PMMA in a cat. Another retrospective study of five cases reported excellent and good outcomes in cats treated by dorsal laminectomy followed by stabilisation with positive profile pins.⁴ However, an objective method for evaluating vertebral instability at the level of the lumbosacral joint is lacking; as such, the indications for surgical stabilisation in cats have not been reported.⁴

In dogs, surgical management of DLSS encompasses various techniques, with the ultimate goal of all the procedures being to decompress the nerve roots of the cauda equina. It has been stated that additional stabilisation of

the lumbosacral joint improves clinical outcome by elimination or reduction of motion in the lumbosacral articulation, preventing further degeneration from occurring.²² Several articles have reported differing outcomes in the treatment of DLSS with similar results when comparing laminectomy alone (overall improvement ranging from 69% to 96%)^{6,23-26} with laminectomy and further fixation (overall improvement of 76%).²⁷ Nevertheless, in 2007 Suwankong demonstrated continued impaired propulsive forces in the pelvic limbs of dogs treated with dorsal laminectomy alone.²⁶ Based on this report, additional support of the lumbosacral junction using stabilising procedures has been suggested. Currently, studies comparing results of force plate analysis in dogs treated with dorsal laminectomy alone or in combination with transarticular fixation are lacking.²⁷

Results observed in dogs with this same condition may not necessarily be extrapolated to cats. Lifestyle differences between dogs and cats may have to be taken into consideration. Owners should be educated to completely prevent the animal from running or jumping in the postoperative period, as this may predispose cats to traumatic fractures, especially in the presence of mild neurological deficits.

Descriptions of long-term follow-up after DLSS surgical treatment are available for dogs,^{6,27,28} although they provide little information on postoperative complications, and focus mainly on clinical improvement and recurrence of clinical signs.^{5,6} In veterinary medicine, relatively few reports have described articular fractures in dogs as a complication after laminectomy.⁷⁻⁹ One study described postoperative CT and MRI findings in dogs with DLSS treated by dorsal laminectomy.⁹ Four of 13 dogs in this study developed fissures or fractures of the articular processes, although none of these was clinically significant.⁹ Another case report described an L7 articular and pedicle fracture in a dog, with no traumatic event


reported, which occurred 2 weeks after a dorsal laminectomy.⁸ In human medicine, there is one retrospective study that evaluated postoperative complications arising 1–2 years after surgery.¹⁰ Of 5876 patients included, none developed a postoperative vertebral fracture.¹⁰ The complication we have described appears to be unusual, as fractures of the remaining osseous structures following decompression due to traumatic events or stress fractures have been infrequently described in individual case reports in the canine or human literature^{8,11–14,27}, and had not been previously reported in the cat.

Conclusions

To our knowledge, this is the first report of a traumatic L7–S1 fracture and luxation with subsequent fixation in a cat after a dorsal laminectomy. In our opinion, it is likely that weakening of the lumbosacral spinal supportive structures following dorsal laminectomy predisposed this cat to fracture after a relatively minor trauma. This case report highlights the importance of the PLC and describes a possible complication after DLSS surgery in cats. Further studies regarding lumbosacral stability in small animals suffering from DLSS, with and without surgical correction, are warranted.

Conflict of interest The authors declared no potential conflicts of interest with respect to the research, authorship, and/or publication of this article.

Funding The authors received no financial support for the research, authorship, and/or publication of this article.

ORCID iD Anna Suñol  <https://orcid.org/0000-0003-0985-6959>

References

- Meij BP and Bergknut N. **Degenerative lumbosacral stenosis in dogs.** *Vet Clin North Am Small Anim Pract* 2010; 40: 983–1009.
- Cariou MP, Störk CK, Petite AF, et al. **Cauda equine syndrome treated by lumbosacral stabilisation in a cat.** *Vet Comp Orthop Traumatol* 2008; 21: 462–466.
- Harris JE and Dhupa S. **Lumbosacral intervertebral disk disease in six cats.** *J Am Anim Hosp Assoc* 2008; 44: 109–115.
- Danielski A, Bertran J and Fitzpatrick N. **Management of degenerative lumbosacral disease in cats by dorsal laminectomy and lumbosacral stabilization.** *Vet Comp Orthop Traumatol* 2013; 26: 69–75.
- Fossum TW. **Surgery of the lumbosacral spine.** In: Fossum TW (ed.) *Small animal surgery*. 4th ed. St Louis, MO: Mosby, 2012, pp 1131–1149.
- De Risio L, Sharp NJ, Olby NJ, et al. **Predictors of outcome after dorsal decompressive laminectomy for degenerative lumbosacral stenosis in dogs: 69 cases (1987–1997).** *J Am Vet Med Assoc* 2001; 219: 624–628.
- Adams WH, Daniel GB, Pardo AD, et al. **Magnetic resonance imaging of the caudal lumbar and lumbosacral spine in 13 dogs (1990–1993).** *Vet Radiol Ultrasound* 1995; 36: 3–13.
- Moens NMM and Runyon CL. **Fracture of L7 vertebral articular facets and pedicles following dorsal laminectomy in a dog.** *J Am Vet Med Assoc* 2002; 221: 807–810.
- Rapp M, Ley CJ, Hansson K, et al. **Postoperative computed tomography and low-field magnetic resonance imaging findings in dogs with degenerative lumbosacral stenosis treated by dorsal laminectomy.** *Vet Comp Orthop Traumatol* 2017; 30: 143–152.
- Grainger J, Hammett T, Isaacs R, et al. **Influence of peri-operative complication severity on 1- and 2-year outcomes of low back surgery.** *J Orthop Traumatol* 2017; 18: 127–134.
- Yadhavi A, Kurra S, Tallarico AR, et al. **Lumbar vertebral body and pars fractures following laminectomy.** *J Surg Case Rep* 2017; 2: 1–3.
- Rothman SLG, Glenn WV, Jr and Kerber CW. **Postoperative fracture of lumbar articular facets: occult cause of radiculopathy.** *AJR Am Roentgenol* 1985; 145: 779–784.
- Rosen C, Rothman S, Zigler J, et al. **Lumbar facet fracture as a possible source of pain after lumbar laminectomy.** *Spine* 1991; 16: S234–S238.
- Sheehan JP, Helm GA, Sheehan JM, et al. **Stress fracture of the pedicle after extensive decompression and contralateral posterior fusion for lumbar stenosis.** *Neurosurg Focus* 2002; 13: E9.
- Bebchuk T. **Lumbosacral decompression and foraminotomy.** In: Shores A and Brisson BA (eds). *Current techniques in canine and feline neurosurgery*. Hoboken, NJ: John Wiley, 2017, pp 223–234.
- Vaccaro AR, Lee JY, Schweitzer KM, Jr, et al. **Assessment of injury to the posterior ligamentous complex in thoracolumbar spine and trauma.** *Spine J* 2006; 6: 524–528.
- Logroscino G, Mazza O, Aulisa AG, et al. **Spondylolysis and spondylolisthesis in the pediatric and adolescent population.** *Child's Nerv Syst* 2001; 17: 644–655.
- Sharp NJH and Wheeler SJ. **Lumbosacral disease.** In: Sharp NJH and Wheeler SJ (eds). *Small animal spinal disorders: diagnosis and surgery*. 2nd ed. St Louis, MO: Elsevier Mosby, 2004, pp 181–209.
- Postacchini F. **Spine update: results of surgery compared with conservative management for lumbar disc herniations.** *Spine* 1996; 21: 1383–1387.
- Chou R, Baisden J, Carragee EJ, et al. **Surgery for low back pain. A review of the evidence for an American Pain Society Clinical Practice Guideline.** *Spine* 2009; 34: 1094–1109.
- Carreon LY, Glassman SD and Howard J. **Fusion and non-surgical treatment for symptomatic lumbar degenerative disease: a systematic review of Oswestry disability index and MOS short form-36 outcomes.** *Spine J* 2008; 8: 747–755.
- Bagley R. **Surgical stabilization of the lumbosacral joint.** In: Slatter D (ed). *Textbook of small animal surgery*. 3rd ed. Philadelphia, PA: Saunders, 2003, pp 1238–1243.
- Janssens L, Moens Y, Coppens P, et al. **Lumbosacral degenerative stenosis in the dog: the results of dorsal decompression with dorsal anulectomy and nucleotomy.** *Vet Comp Orthop Traumatol* 2000; 13: 97–103.

- 24 Linn LL, Bartels KE, Rochat MC, et al. **Lumbosacral stenosis in 29 military working dogs: epidemiologic findings and outcome after surgical intervention (1990–1999).** *Vet Surg* 2003; 32: 21–29.
- 25 Kinzel S, Koch J, Stopinski T, et al. **Cauda equina compression syndrome (CECS): retrospective study of surgical treatment with partial dorsal laminectomy in 86 dogs with lumbosacral stenosis.** *Berl Munch Tierarztl Wochenschr* 2004; 117: 334–340.
- 26 Suwankong N, Meij BP, Van Klaveren NJ, et al. **Assessment of decompressive surgery in dogs with degenerative lumbosacral stenosis using force plate analysis and questionnaires.** *Vet Surg* 2007; 36: 423–431.
- 27 Golini L, Kircher PR, Lewis FI, et al. **Trans articular fixation with cortical screws combined with dorsal laminectomy and partial discectomy as surgical treatment of degenerative lumbosacral stenosis in 17 dogs: clinical and computed tomography follow-up.** *Vet Surg* 2014; 43: 405–413.
- 28 Suwankong N, Meij BP, deBoer AH, et al. **Review and retrospective analysis of degenerative lumbosacral stenosis in 156 dogs treated by dorsal laminectomy.** *Vet Comp Orthop Traumatol* 2008; 21: 258–293.