

Diabetes mellitus remission in a cat with pituitary-dependent hyperadrenocorticism after trilostane treatment

Authors: Muschner, Adriana Cunha, Varela, Fernanda Venzon, Hazuchova, Katarina, Niessen, Stijn JM, and Pöpl, Álan Gomes

Source: Journal of Feline Medicine and Surgery Open Reports, 4(1)

Published By: SAGE Publishing

URL: <https://doi.org/10.1177/2055116918767708>

BioOne Complete (complete.BioOne.org) is a full-text database of 200 subscribed and open-access titles in the biological, ecological, and environmental sciences published by nonprofit societies, associations, museums, institutions, and presses.

Your use of this PDF, the BioOne Complete website, and all posted and associated content indicates your acceptance of BioOne's Terms of Use, available at www.bioone.org/terms-of-use.

Usage of BioOne Complete content is strictly limited to personal, educational, and non - commercial use. Commercial inquiries or rights and permissions requests should be directed to the individual publisher as copyright holder.

BioOne sees sustainable scholarly publishing as an inherently collaborative enterprise connecting authors, nonprofit publishers, academic institutions, research libraries, and research funders in the common goal of maximizing access to critical research.



Diabetes mellitus remission in a cat with pituitary-dependent hyperadrenocorticism after trilostane treatment

Journal of Feline Medicine and Surgery Open Reports
1–7

© The Author(s) 2018

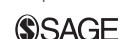Reprints and permissions:

sagepub.co.uk/journalsPermissions.nav

DOI: 10.1177/2055116918767708

journals.sagepub.com/home/jfmsopenreports

This paper was handled and processed by the American Editorial Office (ISFM) for publication in *JFMS Open Reports*



Adriana Cunha Muschner¹, Fernanda Venzon Varela¹,
Katarina Hazuchova², Stijn JM Niessen² and Álan Gomes Pöpl¹

Abstract

Case summary An 8-year-old male neutered Persian cat was presented with polyuria, polydipsia, polyphagia and muscle weakness associated with a 7 month history of diabetes mellitus (DM). The cat had initially been treated with neutral protamine Hagedorn (NPH) insulin 2 U q12h, followed by porcine lente insulin 2 U q12h and, most recently, 3 U glargine insulin q12h, without improvement of clinical signs. The cat also suffered from concurrent symmetrical bilateral alopecia of thorax and forelimbs, abdominal distension and lethargy. Hyperadrenocorticism (HAC), specifically pituitary-dependent HAC, was suspected and confirmed through abdominal ultrasonography demonstrating bilateral adrenal enlargement, and a low-dose dexamethasone suppression test using 0.1 mg/kg dexamethasone intravenously. Trilostane treatment (initially 10 mg/cat PO q24h then increased to 10 mg/cat PO q12h) was started and insulin sensitivity gradually improved, ultimately leading to diabetic remission after an increased in trilostane dose to 13mg/cat PO q12h, 14 months after the DM diagnosis and 7 months after the initiation of trilostane therapy.

Relevance and novel information DM in cats with HAC is a difficult combination of diseases to treat. To our knowledge this is the first reported case of diabetic remission in a feline patient with HAC as a result of treatment with trilostane. Further work should focus on whether fine-tuning of trilostane-treatment protocols in cats with concurrent DM and HAC could lead to a higher proportion of diabetic remissions in this patient group.

Accepted: 27 February 2018

Case description

An 8-year-old male neutered Persian cat, weighing 3 kg, with a body condition score of 3/5 was referred to a dedicated veterinary endocrinology clinic (PetEndocrine, Brazil) for uncontrolled diabetes mellitus (DM). The cat had initially been treated with neutral protamine Hagedorn (NPH) insulin (up to 2 U q12h SC [Humulin N; Lilly]), was then switched to porcine lente insulin (up to 2 U q12h SC [Caninsulin; MSD]) and, most recently, the cat had been receiving 3 U glargine insulin (q12h SC [Lantus; Aventis]). There had not been any significant improvement in diabetic clinical signs and the cat continued to suffer from polyuria and polydipsia, polyphagia, muscle weakness and lethargy.

On physical examination, the cat displayed abdominal distension, fragile/thin skin and symmetrical bilateral alopecia predominantly affecting the thorax and

limbs (Figure 1). The clinical signs and lack of response to treatment gave rise to a suspicion of concurrent

¹Department of Animal Medicine, Faculty of Veterinary Medicine, Federal University of Rio Grande do Sul (UFRGS), Porto Alegre, Rio Grande do Sul, Brazil

²Diabetic Remission Clinic, Department of Clinical Science and Services, Royal Veterinary College, University of London, North Mymms, UK

Corresponding author:

Álan G Pöpl DVM, MSc, DSc, Department of Animal Medicine, Veterinary Clinics Hospital, Endocrinology Service (PetEndocrine), Federal University of Rio Grande do Sul 9090 Bento Gonçalves Av, Agronomia, Porto Alegre, RS 91540-000, Brazil

Email: alan.poppl@ufrgs.br, gomespoppl@hotmail.com



Creative Commons Non Commercial CC BY-NC: This article is distributed under the terms of the Creative Commons

Attribution-NonCommercial 4.0 License (<http://www.creativecommons.org/licenses/by-nc/4.0/>) which permits non-commercial use, reproduction and distribution of the work without further permission provided the original work is attributed as specified on the SAGE and Open Access pages (<https://us.sagepub.com/en-us/nam/open-access-at-sage>).

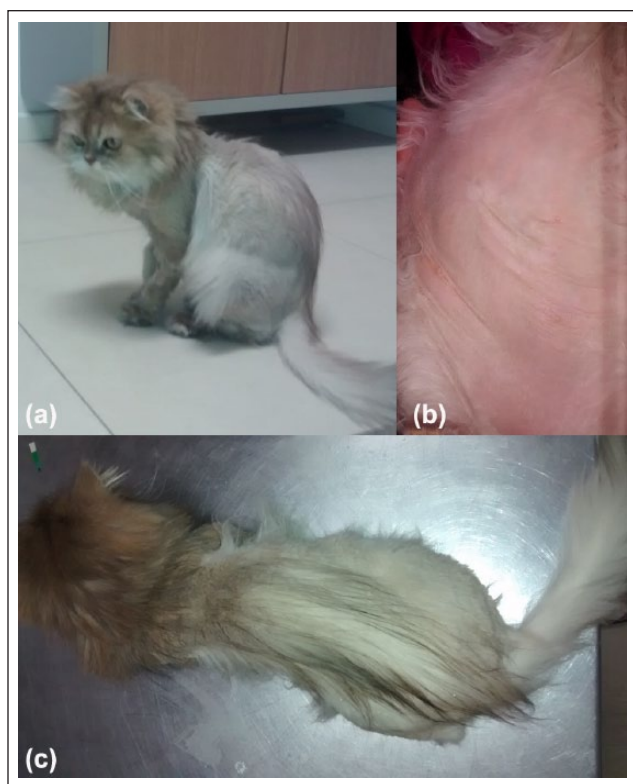

Figure 1 (a) Emaciation, muscle loss, unkempt haircoat and alopecia. (b) Fragile thin inelastic skin. (c) Bilateral symmetrical alopecia, unkempt haircoat, and potbellied abdomen

hyperadrenocorticism (HAC). Blood work and urine analysis results are shown in Table 1. A serum fructosamine concentration suggested good control ($369 \mu\text{mol/l}$; reference interval [RI] for good diabetic control established by the employed laboratory $350\text{--}400 \mu\text{mol/l}$). However, given the persistence of clinical signs and the results of serial blood glucose evaluation (Table 1, Figure 2), the glargine dose was increased to 4 U q12h SC . One week later, a low-dose dexamethasone suppression test (LDDST; using 0.1 mg/kg dexamethasone IV) was conducted, the results of which proved compatible with pituitary-dependent HAC (PDH): basal cortisol 143.7 nmol/l (RI $10\text{--}138 \text{ nmol/l}$), 4 h post-dexamethasone 64.6 nmol/l and 8 h post-dexamethasone 49.4 nmol/l (normal response $<38 \text{ nmol/l}$). Additionally, bilateral adrenomegaly was present on abdominal ultrasonography (US), further supporting this diagnosis (Figure 3). The liver appeared a little heterogeneous on US, whereas the gall bladder showed thickened walls (0.25 cm), suggesting cholecystitis.

Treatment with trilostane (Vetoryl; Dechra) at a dose of 10 mg q24h PO was initiated. Over the next 2 weeks, the cat showed weight gain and increased activity, as well as normalization of interaction with the owners. Additionally, glycemic control improved, as demonstrated

by subsequent resolution of diabetic signs, as well as serial blood glucose assessment (Figure 2). Fourteen days after the start of therapy, an adrenocorticotrophic hormone (ACTH) stimulation test was performed 6 h after trilostane administration, using 0.125 mg/cat intravenous synthetic ACTH (Synacthen; Novartis). Based on a post-ACTH cortisol concentration of 136.8 nmol/l (suggested target range $55\text{--}165 \text{ nmol/l}$), the trilostane dose was increased to 10 mg q12h PO , in an effort to optimize glycemic and HAC control. One month later (40 days after starting trilostane), the cat was once again presented, this time with clinical signs compatible with hypoglycemia (prostration), at which stage a blood glucose of 2.4 mmol/l was recorded. Furthermore, serum fructosamine concentration was consistent with chronic hypoglycemia ($257 \mu\text{mol/l}$; RI for possible chronic hypoglycemia $<300 \mu\text{mol/l}$). The insulin dose was therefore reduced to 2 U q12h and an ACTH stimulation test was performed. The 1 h post-ACTH cortisol concentration (146.2 nmol/l) rendered hypocortisolism contributing to the hypoglycemia unlikely. The trilostane dose was therefore kept unaltered (10 mg/cat q12h).

Two months later (100 days after starting trilostane) the cat was reported to show no clinical signs of DM, demonstrated an increased weight of 3.4 kg , complete fur re-growth (Figure 4) and fair control of blood glucose concentrations. This prompted a further decrease in insulin dose to 1 U q12h SC . The post-ACTH cortisol concentration obtained at this point suggested effective adrenal suppression (116.4 nmol/l). However, the cat was also reported to show behavioral changes, including aggression, vocalization at night, hypersexuality and increased libido. After 200 days of trilostane treatment, the post-ACTH cortisol concentration was 137.1 nmol/l (tests performed 8 h after trilostane administration); trilostane was readjusted to the dose of 13 mg q12h PO by compounding capsules at a veterinary pharmacy certified by the Brazilian Ministry of Agriculture, Livestock, and Food. Given the lack of clinical signs of DM and the serum fructosamine concentration (Table 1), the insulin dose was reduced to 0.5 U q12h SC . Two weeks later, the cat showed absence of glycosuria and once again a serum fructosamine concentration was consistent with chronic hypoglycemia ($205 \mu\text{mol/l}$; RI for possible chronic hypoglycemia $<300 \mu\text{mol/l}$), prompting complete insulin withdrawal and subsequent testing for diabetic remission. To test for diabetic remission, the cat was closely monitored by its owners for the recurrence of clinical signs, as well as regular blood glucose tests for the next 4 weeks . Diabetic remission was confirmed; monitoring of the cat was continued for the following 20 months . Relapse of DM did not occur.

Discussion

This report describes the first case of diabetic remission in a cat with underlying HAC while being treated with

Table 1 Serum biochemical parameters and urinalysis of the cat at initial consultation and during follow-up visits

	First consult	14 days	40 days	100 days	200 days	214 days	274 days	574 days	RI
Trilostane dose (mg/cat)	0	10 (q24h)	10 (q12h)	10 (q12h)	10 (q12h)	13 (q12h)	13 (q12h)	13 (q12h)	
Glargine dose (U/cat)	3 (q12h)	4 (q12h)	4 (q12h)	2 (q12h)	1 (q12h)	0.5 (q12h)	28	23.3	21–39
Albumin (g/l)	26.1	26.7	24	22	21	24	79	67	6–83
ALT (μ/l)	72	183	114	83	85	–	46	28	25–93
ALP (μ/l)	134	30	160	60	60	–	244	272	219–340
Fructosamine (μmol/l)	369	283	257	228	210	205	106.1	108.7	53–159.1
Creatinine (μmol/l)	106.9	–	–	–	132.6	119.3	–	22.5	3.57–21.43
Urea (mmol/l)	16.7	–	–	–	21.43	17.5	0.62	0.27	0.56–1.13
Triglycerides (mmol/l)	2.21	–	–	–	–	–	2.35	2.04	2.45–3.36
Cholesterol (mmol/l)	4.93	–	–	–	–	–	–	4.2	3.80–4.51
Potassium (mmol/l)	–	4.2	4	4	4.2	–	–	142	145–157
Sodium (mmol/l)	–	147	145	145	142	–	–	1.020	≥1.035
USG	1.020	1.030	1.025	1.030	1.020	1.020	–	0.44	<0.4
UP:CR	–	0.17	0.19	0.17	0.2	0.14	–	0	0
Glycosuria (mg/dl)	2000	2000	0	1000	0	0	–	–	–
Glargine adjustments (U/cat)	↑ 4 U (q12h)	–	↓ 2 U (q12h)	↓ 1 U (q12h)	↓ 0.5 U (q12h)	Glargine withdrawal	–	–	–
Trilostane adjustments (mg/cat)	–	↑ 10 (q12h)	–	–	↑ 13 (q12h)	–	–	–	–

The time points represent days in treatment with trilostane. Moreover, trilostane and glargine dose in use at each time point, and adjustments made based on cat's clinical evaluation are shown
RI = reference interval; ALT = alanine aminotransferase; ALP = alkaline phosphatase; USG = urine specific gravity; UP:CR = urinary protein:creatinine ratio; ↑ = dose increase to; ↓ = dose reduction to

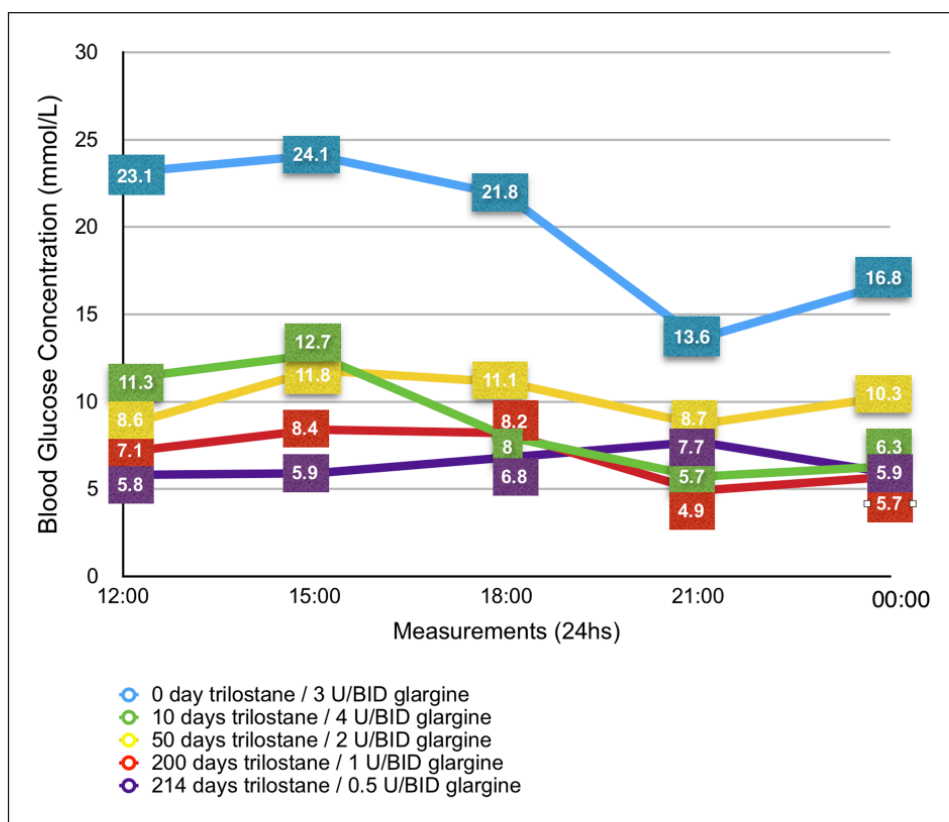


Figure 2 Home-generated serial blood glucose measurements before diabetic remission. The curves are shown in relation to glargine insulin dose modifications and days on trilostane treatment. All curves started at midday and finished at midnight

trilostane. Given that HAC is a difficult disease to treat and the treatment effect of trilostane, specifically, has been noted to be variable in diabetic cats with HAC,^{1,2} the current report highlights that satisfactory results can be obtained in individual cats.

Naturally occurring HAC is an uncommon disorder in cats, arising from either adrenocortical (ACTH-independent HAC) or pituitary hyperfunction leading to excess cortisol production; PDH due to corticotroph adenoma is thought to be the most usual form.²⁻⁷

Excess cortisol production by adrenal glands induces insulin antagonistic and catabolic effects.^{2,5} Specifically, the excessive exposure to glucocorticoids has been associated with DM in cats and dogs.⁵⁻¹¹ Cats seem particularly vulnerable to HAC-induced DM with 80% of HAC cats developing secondary DM; in contrast only 8–16% of dogs with HAC have concurrent DM.^{5,9,12,13}

The described case showed characteristics previously associated with feline HAC-induced DM, including insulin resistance, dermatological changes such as symmetrical alopecia, as well as some non-specific clinical pathological changes such as hypercholesterolemia, hypertriglyceridemia and increased alkaline phosphatase.^{1,2,10,11} Although the condition is thought to be relatively rare, the presence of these more characteristic

clinical signs in conjunction with a DM diagnosis should give rise to a suspicion of HAC in cats.¹⁴ The most commonly recommended diagnostic tests for HAC in cats include the LDDST (in cats, using a dose of 0.1 mg/kg of dexamethasone), the ACTH stimulation test (though suggested to be lacking in sensitivity) and the urine cortisol:creatinine ratio (though suggested to be lacking specificity).^{7,14,15}

In this case, diabetic remission (defined as absence of clinical signs suggestive of DM, normal blood glucose and fructosamine concentrations, while not receiving exogenous insulin for at least 1 month)¹⁶ is thought to have been achieved by a reduction of insulin resistance through reduction of endogenous cortisol concentrations, as well as concurrent recovery of beta cells function, through reduction of glucotoxicity (structural and functional damage in pancreatic beta cells and the target tissues of insulin caused by chronic hyperglycemia).⁹ This would, perhaps, be similar to the situation in cats with DM associated with previous exogenous glucocorticoid administration. Interestingly, diabetic cats with a previous history of exogenous glucocorticoid treatment have been shown to benefit from a greater chance of diabetic remission.¹⁶ This suggests that effective treatment of HAC in diabetic cats could

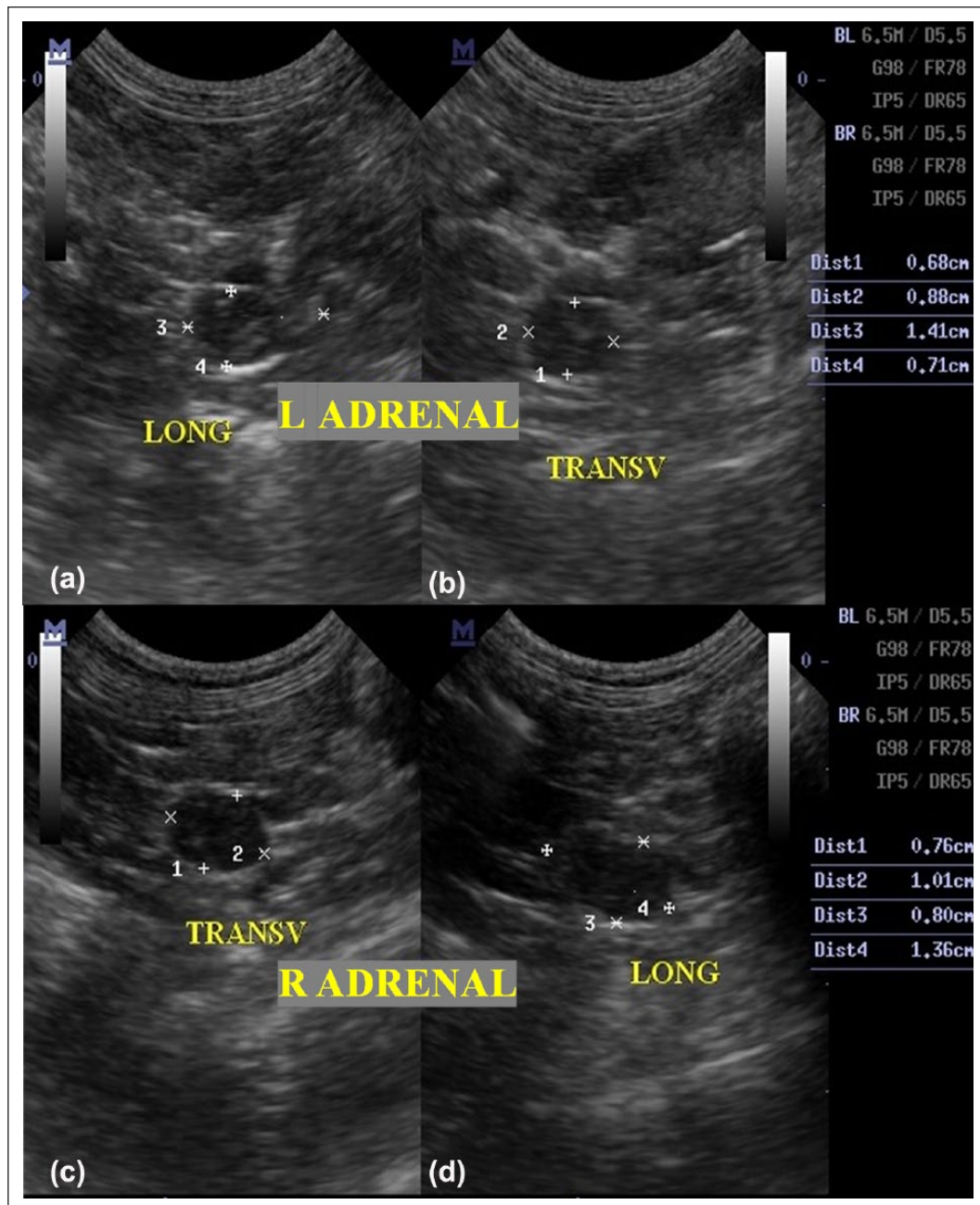


Figure 3 Ultrasonographic appearance showing bilateral enlargement of the adrenal glands. (a) Left (L) adrenal longitudinal section (1.41 × 0.71 cm). (b) Left adrenal transverse (transv) section (0.68 × 0.88 cm). (c) Right (R) adrenal transverse section (0.76 × 1.01 cm). (d) Right adrenal longitudinal section (1.36 × 0.8 cm)

also carry such increased potential of diabetic remission. Diabetic remission through medical pituitary inhibition has also recently been shown to be possible in another form of pituitary-induced feline secondary DM, hypersomatotropism-induced DM.¹⁷ Gostelow et al¹⁸ described 25% of cats with this condition to show diabetic remission through use of the pituitary inhibitor pasireotide (a somatostatin analogue [Signifor LAR; Novartis]).

In cases of type 2 feline DM, diabetic remission is suggested to occur most commonly within the first 6 months after diagnosis and more rarely thereafter.¹⁹ Diabetic remission of the cat in this report occurred 14 months after diagnosis. This is, however, not a contradiction, as the cat's DM was of a different kind, occurring secondarily to HAC and thus likely more amenable to remission, as long as the underlying inducing disease, HAC, is treated effectively. The late occurrence of remission after

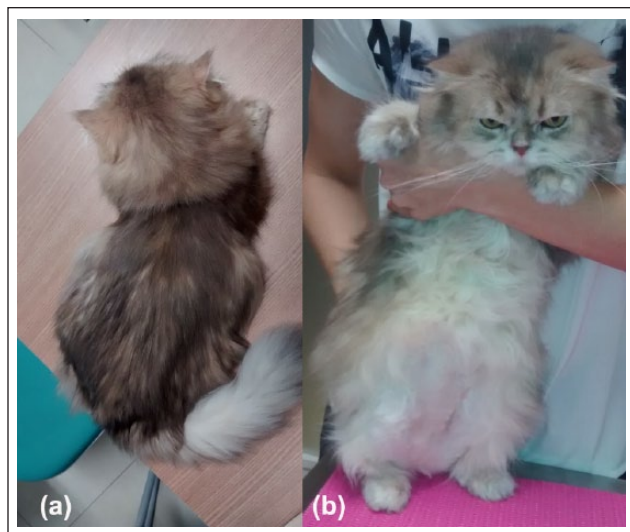

Figure 4 (a) Weight and muscle mass gain, complete haircoat re-growth and re-pigmentation. (b) Loss of potbellied appearance and ventral abdominal haircoat re-growth

months of trilostane treatment emphasizes the need for careful monitoring of insulin-treated diabetic cats with underlying HAC treated with trilostane, as iatrogenic hypoglycemia can pose a danger if the onset of remission is missed.¹³ Indeed, in the current case, it would have been indicated to have checked the cat's glucose concentrations more frequently and/or for the owner to have conducted more intense monitoring at home (home blood glucose or urine glucose monitoring); unfortunately, this was not possible for the owner in question. Moreover, this cat might have been able to stop insulin even earlier, once normal fructosamine values and absence of glycosuria were detected at some time points before insulin withdrawal.

The reason(s) why this particular case achieved diabetic remission, whereas other, seemingly similar, cats do not remain(s) unknown. Trilostane treatment was not started more promptly than in other reported cases; the employed trilostane dose was not significantly different nor were the attained post-ACTH cortisol concentrations superior than in previously reported cases.^{1–3} Diabetic remission has previously been suggested to occur more frequently in glargine-treated diabetic cats,²⁰ although this was subsequently questioned in a systematic review of the topic, particularly given the small size of that study and several included biasing factors.¹⁹ Additionally, cats previously treated with both trilostane and glargine have failed to enter diabetic remission.¹ Nevertheless, remission-associated factors that should be considered are the influence of trilostane frequency and dose, target post-ACTH cortisol concentrations and the influence of the concurrent insulin treatment regimen.

Conclusions

This report details the first case of diabetic remission in a cat with HAC treated with trilostane. Further work should focus on whether fine-tuning of trilostane-treatment protocols in patients with DM- associated with HAC could lead to a higher proportion of cats achieving diabetic remission. Treatment success should be compared to alternative treatment options, including hypophysectomy.

Conflict of interest The authors declared no potential conflicts of interest with respect to the research, authorship, and/or publication of this article.

Funding The authors received no financial support for the research, authorship, and/or publication of this article.

References

- 1 Mellett Keith AM, Bruyette D and Stanley S. **Trilostane therapy for treatment of spontaneous hyperadrenocorticism in cats: 15 cases (2004–2012).** *J Vet Intern Med* 2013; 27: 1471–1477.
- 2 Valentin S, Cortright C, Nelson R, et al. **Clinical findings, diagnostic test results, and treatment outcome in cats with spontaneous hyperadrenocorticism: 30 cases.** *J Vet Intern Med* 2014; 28: 481–487.
- 3 Cross E, Moreland R and Wallack S. **Feline pituitary-dependent hyperadrenocorticism and insulin resistance due to a plurihormonal adenoma.** *Top Comp Anim Med* 2012; 27: 8–20.
- 4 Peterson ME. **Feline hyperadrenocorticism.** In: Mooney CT and Peterson ME (eds). *BSAVA manual of canine and feline endocrinology*. 4th ed. Gloucester: British Small Animal Veterinary Association, 2012, pp 190–198.
- 5 Gunn-Moore D and Simpson K. **Hyperadrenocorticism in cats.** In: Rand J, Behrend EN, Gunn-Moore D, et al (eds). *Clinical endocrinology of companion animals*. Chichester: Wiley-Blackwell, 2013, pp 71–79.
- 6 Chiaramonte D and Greco D. **Feline adrenal disorders.** *Clin Tech Small Anim Pract* 2007; 22: 26–31.
- 7 Niessen SJM, Church DB and Forcada Y. **Hypersomatotropism, acromegaly, and hyperadrenocorticism and feline diabetes mellitus.** *Vet Clin North Am Small Anim Pract* 2013; 43: 319–350.
- 8 Scott-Moncrieff J. **Insulin resistance in cats.** *Vet Clin North Am Small Anim Pract* 2010; 40: 241–257.
- 9 Gillor C, Niessen SJM, Furrow E, et al. **What's in a name? Classification of diabetes mellitus in veterinary medicine and why it matters.** *J Vet Intern Med* 2016; 30: 927–940.
- 10 Rand J. **Feline diabetes mellitus.** In: Mooney CT and Peterson ME (eds). *BSAVA manual of canine and feline endocrinology*. 4th ed. Gloucester: British Small Animal Veterinary Association, 2012, pp 133–147.
- 11 Rand J. **Feline diabetes mellitus.** In: Rand J, Behrend EN, Gunn-Moore D, et al (eds). *Clinical endocrinology of companion animals*. Chichester: Wiley-Blackwell, 2013, pp 169–190.

- 12 Pöppel AG, Coelho IC, Da Silveira CA, et al. **Frequency of endocrinopathies and characteristics of affected dogs and cats in Southern Brazil (2004–2014).** *Acta Sci Vet* 2016; 44: Pub1379.
- 13 Sparkes A, Cannon M, Church D, et al. **ISFM consensus guidelines on the practical management of diabetes mellitus in cats.** *J Feline Med Surg* 2015; 17: 235–250.
- 14 Gunn-Moore D. **Feline endocrinopathies.** *Vet Clin North Am Small Anim Pract* 2005; 35: 171–210.
- 15 Niessen S, Forcada Y, Mantis P, et al. **Studying cat (*Felis catus*) diabetes: beware of the acromegalic imposter.** *PLoS One* 2015; 10: e0127794.
- 16 Sieber-Ruckstuhl NS, Kley S, Tschuor F, et al. **Remission of diabetes mellitus in cats with diabetic ketoacidosis.** *J Vet Intern Med* 2008; 22: 1326–1332.
- 17 Scudder C, Gostelow R, Forcada Y, et al. **Pasireotide for the medical management of feline hypersomatotropism.** *J Vet Intern Med* 2015; 29: 1074–1080.
- 18 Gostelow R, Scudder C, Keyte S, et al. **Pasireotide long-acting release treatment for diabetic cats with underlying hypersomatotropism.** *J Vet Intern Med* 2017; 31: 335–364.
- 19 Gostelow R, Forcada Y, Graves T, et al. **Systematic review of feline diabetic remission: separating fact from opinion.** *Vet J* 2014; 202: 208–221.
- 20 Marshall RD, Rand JS and Morton JM. **Treatment of newly diagnosed diabetic cats with glargine insulin improves glycaemic control and results in higher probability of remission than protamine zinc and lente insulins.** *J Feline Med Surg* 2009; 11: 683–691.