



Oesophageal obstruction due to trichobezoars in two cats

Authors: Woerde, Dennis J, Hoffmann, Karon L, Kicinski, Anne, and Brown, Narelle L

Source: Journal of Feline Medicine and Surgery Open Reports, 5(1)

Published By: SAGE Publishing

URL: <https://doi.org/10.1177/2055116918823581>

BioOne Complete (complete.BioOne.org) is a full-text database of 200 subscribed and open-access titles in the biological, ecological, and environmental sciences published by nonprofit societies, associations, museums, institutions, and presses.

Your use of this PDF, the BioOne Complete website, and all posted and associated content indicates your acceptance of BioOne's Terms of Use, available at www.bioone.org/terms-of-use.

Usage of BioOne Complete content is strictly limited to personal, educational, and non - commercial use. Commercial inquiries or rights and permissions requests should be directed to the individual publisher as copyright holder.

BioOne sees sustainable scholarly publishing as an inherently collaborative enterprise connecting authors, nonprofit publishers, academic institutions, research libraries, and research funders in the common goal of maximizing access to critical research.



Oesophageal obstruction due to trichobezoars in two cats

Dennis J Woerde¹ , Karon L Hoffmann^{1,2}, Anne Kicinski¹ and Narelle L Brown¹

Journal of Feline Medicine and Surgery Open Reports
1–5

© The Author(s) 2019

Article reuse guidelines:

sagepub.com/journals-permissions

DOI: 10.1177/2055116918823581

journals.sagepub.com/home/jfmsopenreports

This paper was handled and processed by the European Editorial Office (ISFM) for publication in *JFMS Open Reports*



Abstract

Case series summary This case series describes two cats diagnosed with oesophageal obstruction due to trichobezoars. Both cases presented for acute dyspnoea, with thoracic radiographs revealing changes consistent with oesophageal foreign material causing ventral displacement of the trachea. Endoscopic removal was unsuccessful and both cases required surgical intervention. Case 1 died within 24 h of trichobezoar removal, likely from aspiration pneumonia. Case 2 developed laryngeal collapse 10 days after trichobezoar removal and required a permanent tracheostomy. Case 2 has been followed up for >1 year without any further complications.

Relevance and novel information There is minimal published information on oesophageal trichobezoars in cats. These cases provide information on presentation, radiographic findings and complications associated with oesophageal trichobezoars. The intention of this case series is to increase the index of suspicion for this syndrome among clinicians treating feline patients.

Keywords: Oesophageal; trichobezoar; hair ball; fur ball; obstruction

Accepted: 14 December 2018

Introduction

Trichobezoars or 'hair balls' are concretions of hair within the gastrointestinal tract.¹ Ingestion of large amounts of hair is considered normal physiology in cats due to their grooming habits² and barbed tongue structure.^{3,4} Normally this hair is passed through the gastrointestinal tract and expelled in the faeces.² Vomiting of hair balls can occur when hair accumulates excessively in the stomach, with vomiting considered a normal clearance mechanism.⁵ Trichobezoars can occasionally become entrapped within the gastrointestinal tract.³ Entrapment of trichobezoars has been reported in the nasopharynx,⁶ oesophagus^{7–13} and intestines,^{4,5} causing either partial or complete obstruction. Despite these case series and reports, there is still limited information on the underlying cause and overall incidence of feline trichobezoars.³ This case series reports two cats that presented for dyspnoea and were ultimately diagnosed with oesophageal trichobezoars.

acutely, which then progressed to hypersalivation and increased respiratory rate and effort.

The cat was obtained at 5 months of age and housed both indoors and outdoors. Commercial supermarket wet and dry food was fed. The cat lived with two other siblings from the same litter. Vaccination and worming status were current. Topical flea control (Revolution; Bayer) was applied monthly. The cat's feline immunodeficiency virus (FIV)/feline leukaemia virus (FeLV) status was negative. The cat had a history of chewing grass and 'bringing up' hairballs every few weeks. The owner reported no other major health concerns.

On presentation, a respiratory rate of 64 breaths per minute was recorded with an increase in both inspiratory and expiratory effort. Hypersalivation was also noted. No other abnormalities were noted on physical examination. Within minutes of presentation the cat

Case series description

Case 1

A 6-year-old female spayed Birman cat presented to the clinic following acute onset of dyspnoea. The cat was observed 20 mins prior to presentation to gag/retch

¹Animal Referral Hospital, Homebush, NSW, Australia

²Imaging Vets, Putney, NSW, Australia

Corresponding author:

Dennis Woerde BVSc (Hons), Animal Referral Hospital, 250 Parramatta Road Homebush, NSW 2140, Australia
Email: dennis.woerde@gmail.com



Creative Commons Non Commercial CC BY-NC: This article is distributed under the terms of the Creative Commons

Attribution-NonCommercial 4.0 License (<http://www.creativecommons.org/licenses/by-nc/4.0/>) which permits non-commercial use, reproduction and distribution of the work without further permission provided the original work is attributed as specified on the SAGE and Open Access pages (<https://us.sagepub.com/en-us/nam/open-access-at-sage>).

became cyanotic and was given alfaxalone 2 mg/kg IV to facilitate endotracheal intubation. Excess saliva was suctioned from the mouth and pharynx immediately. The larynx appeared moderately inflamed. Dexamethasone 0.1 mg/kg IV was given after intubation. The cat was subsequently maintained on an alfaxalone constant rate infusion anaesthesia (2 mg/kg/h) and inhalational oxygen to facilitate further diagnostics.

A three-view thoracic radiographic study was performed, which showed a widened cranial mediastinum (Figure 1). Dorsal to the trachea and extending caudally to the diaphragm there was increased diameter and fluid opacity in the region of the dorsal mediastinum consistent with the location of the oesophagus. There was also ventral deviation of the trachea and tracheal narrowing (Figure 2). An increased alveolar opacity was present in the left and right cranial lung lobes and a generalised increased unstructured interstitial pattern was present throughout all lung lobes (Figure 1).

Routine haematology and biochemistry were performed and were within normal limits. The cat was able to be extubated approximately 2 h after presentation. The cat received supplemental oxygen via an oxygen cage overnight. Further treatment included IV fluid therapy, ticarcillin/clavulanic acid 50 mg/kg IV q8h and enrofloxacin 5 mg/kg IV q24h for suspected secondary aspiration pneumonia.

The following day the cat was sedated with butorphanol 0.2 mg/kg IV and anaesthesia was induced with alfaxalone 1 mg/kg IV. The cat was intubated and general anaesthesia was maintained with isoflurane inhalation. Oesophagoscopy was performed. A large amount of hair consistent with a trichobezoar was found to be occluding the oesophageal lumen. Full visualisation of the length of the oesophagus was not possible. Endoscopic removal was attempted using long grasping forceps under visualisation. This was unsuccessful as the hair fragmented making the removal process markedly prolonged so was abandoned after approximately 2 h.

The abdomen was subsequently approached surgically via a ventral midline incision. A 20 mm gastrotomy was performed in the proximal body of the stomach and a forcep was passed through the cardia into the oesophagus. Traction with the forceps allowed to the trichobezoar to move caudally through the lower oesophageal sphincter and be removed via the gastrotomy site. The gastrotomy site and abdominal wall were closed routinely. Repeat oesophagoscopy was not performed.

Postoperative analgesia was provided by methadone 0.2 mg/kg intramuscularly (IM) q4–6h. IV fluid therapy, ticarcillin/clavulanic acid 50 mg/kg IV q8h and enrofloxacin 5 mg/kg IV q24h were continued postoperatively. The cat continued to receive supplemental oxygen via an oxygen cage.

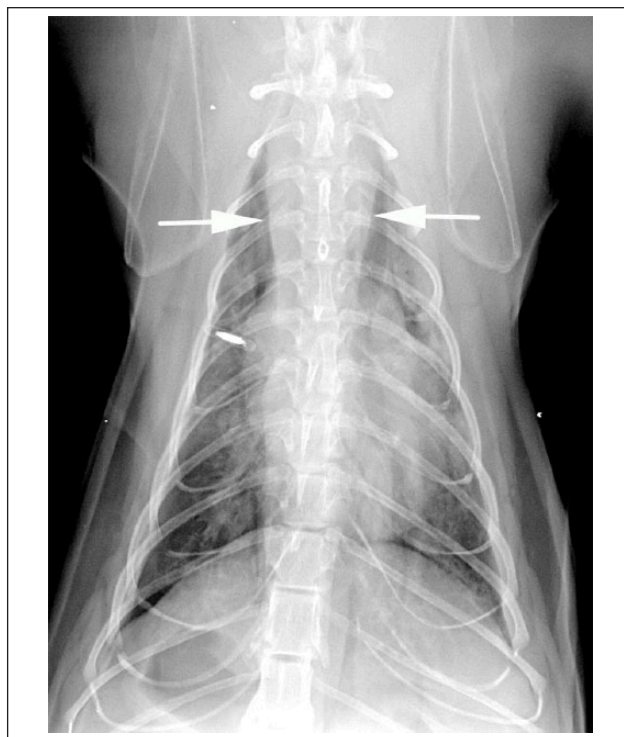

Figure 1 A dorsoventral radiographic view of the thorax under general anaesthesia. There is widening of the cranial mediastinum to greater than one vertebral body width (arrows). There is increased opacity of the cranial lung lobes with alveolar opacity and unstructured interstitial pattern in the remaining parenchyma

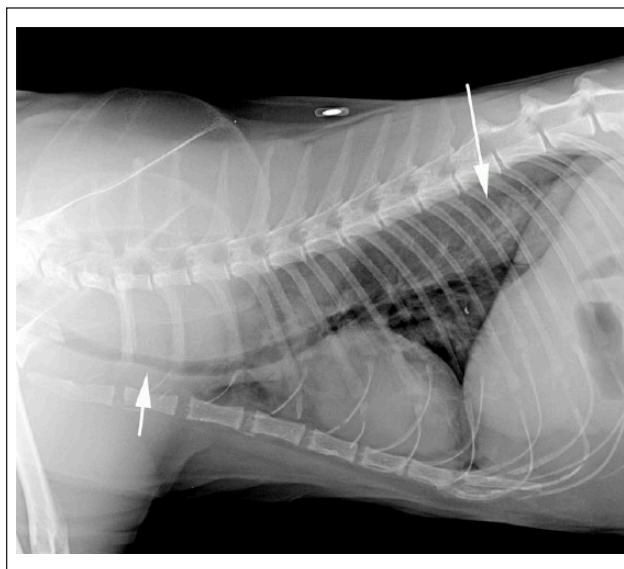


Figure 2 Right lateral radiograph. There is ventral deviation and narrowing of the trachea, most notably at the thoracic inlet (short arrow). Dorsal to the trachea and extending caudally to the diaphragm there is increased diameter and fluid opacity in the dorsal mediastinum consistent with the location of the oesophagus (long arrow)

The following day the cat became acutely tachypnoeic and cyanotic. The cat was intubated but arrested soon after intubation. A large amount of purulent material was present in the endotracheal tube on extubation. No post-mortem examination was performed.

Case 2

A 2-year-old female spayed Ragdoll cat presented to the clinic following acute onset of dyspnoea and hypersalivation. The cat was obtained at 2 months of age and was housed strictly indoors. Commercial supermarket dry food was fed. The cat's FIV/FelV status was negative. Vaccination and worming status were current. Flea prevention was not up to date. The cat was reported to be fine prior to this episode, with no other major health concerns reported by the owner.

On presentation, there was marked hypersalivation and an obstructive breathing pattern. A heavy flea burden was also noted. The cat was sedated with butorphanol 0.2 mg/kg IV, the mouth was suctioned and supplemental oxygen was administered via a face mask. The owners declined further diagnostics and treatment and the cat was discharged against medical advice. The cat was prescribed an empirical 14 day course of amoxicillin/clavulanic acid (Clavulox; Zoetis Animal Health) at 15 mg/kg PO q12h for possible aspiration pneumonia.

The cat re-presented 19 days later for re-assessment. Since discharge the cat had become progressively more lethargic and inappetent and had developed productive regurgitation/vomiting of fluid and foam-like material several times daily. The cat had been completely anorectic for 2 days prior to presentation. On re-presentation, the cat was notably emaciated, having lost one-third of its body weight since initial presentation. The cat was estimated to have a body condition score of 1–2/9. The cat was weak, dehydrated and hypothermic (36.5°C). The previously noted heavy flea burden was still present. In-house haematology demonstrated a regenerative anaemia (haematocrit 0.21 l/l; reference interval [RI] 0.27–0.45 l/l) and eosinopenia ($0.02 \times 10^9/l$; RI $0.17\text{--}1.57 \times 10^9/l$). Serum biochemistry revealed hyperalbuminemia (42 g/l; RI 22–40 g/l) and elevated urea (32.3 mmol/l; RI 5.7–12.9 mmol/l). The biochemistry changes were likely secondary to dehydration. The regenerative anaemia was suspected to be due to the ongoing flea burden.

The cat responded well to initial active warming and fluid resuscitation using lactated Ringer's solution. Once stable, three-view thoracic radiographs were performed and revealed a widened mediastinum. There was a generalised dilated oesophagus containing fluid or soft tissue opacity with fine vesicular gas opacities within it. The intrathoracic trachea was markedly displaced ventrally and was narrowed to the level of carina (Figure 3).

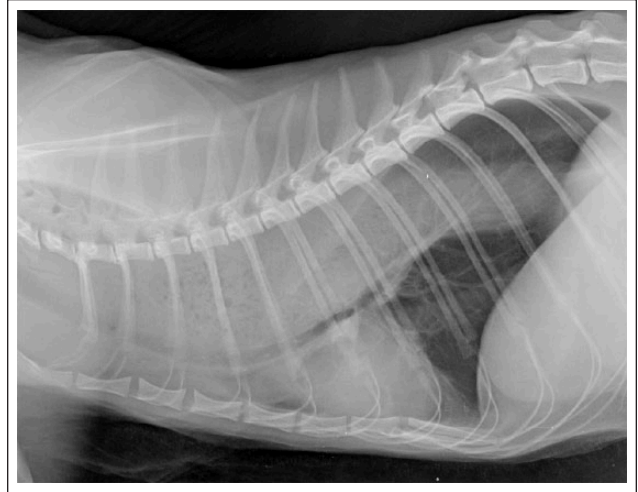


Figure 3 Right lateral recumbent view of the thorax. There is ventral deviation and narrowing of the trachea, most notably at the level of the fourth rib. Dorsal to the trachea and extending caudally to the diaphragm there is increased fluid opacity with fine vesicular gas opacities in the dorsal mediastinum consistent with the oesophagus

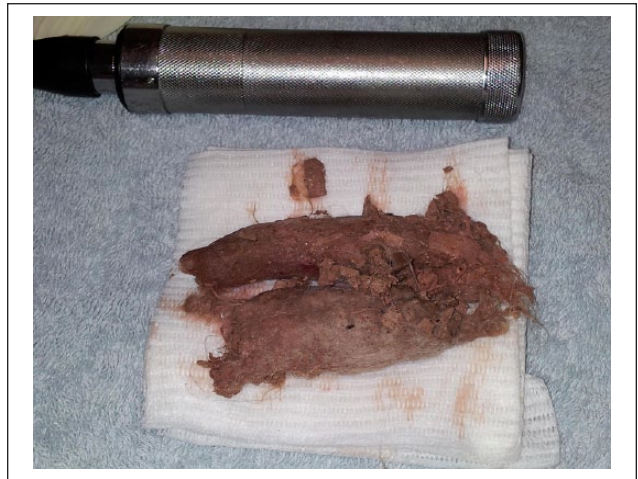


Figure 4 Trichobezoar after removal

The cat was maintained overnight on IV fluid therapy, cephazolin 22 mg/kg IV q8h and metronidazole 10 mg/kg IV q12h for suspected secondary aspiration pneumonia. Topical flea control (Advocate; Bayer) was also applied.

The following day oesophagoscopy was performed. The cat received a typed blood transfusion (15 ml/kg IV) over 4 h prior to the procedure without any complications. The cat was sedated with methadone 0.2 mg/kg IV and anaesthetised with alfaxalone 1.5 mg/kg IV to facilitate oesophagoscopy. The cat was intubated and general anaesthesia was maintained with isoflurane inhalation. Oesophagoscopy revealed a large trichobezoar present in

the mid-oesophagus. Several attempts of endoscopic removal failed. The abdomen was subsequently approached surgically via a ventral midline incision. A 15 mm gastrotomy was performed near the cardia. Using forceps through the gastrotomy site and extending into the distal oesophagus, the trichobezoar was pushed orally, occurring simultaneously with endoscopic pulling. The trichobezoar was removed via the mouth as a single piece (Figure 4). There was marked inflammation present diffusely along the oesophageal mucosa after trichobezoar removal.

A 14 G gastrostomy tube was placed in the greater curvature of the stomach and a gastropexy was performed. The gastrostomy site and abdominal wall were closed routinely and recovery was uneventful.

Postoperative analgesia was provided by buprenorphine 0.01 mg/kg SC q8h. IV fluid therapy, ticarcillin/clavulanic acid 50 mg/kg IV q8h and metronidazole 10 mg/kg IV q12h were continued postoperatively. The cat continued to receive supplemental oxygen via an oxygen cage.

Blended commercial cat food was fed through the gastrostomy tube postoperatively, with a gradual increase to resting energy requirement over 3 days. At day 3 postoperatively the cat regurgitated during feeding through the gastrostomy tube. Repeat thoracic radiographs confirmed suspected aspiration pneumonia. Over the following 7 days the cat developed progressively worsening inspiratory stridor. This progressed into marked upper respiratory distress at day 10 postoperatively. The cat was subsequently anaesthetised with alfaxalone 1.5 mg/kg IV and examination of the larynx revealed complete laryngeal collapse. A permanent tracheostomy was performed in a routine fashion.¹⁴ Recovery was uneventful.

The cat was discharged several days later without any complications. The cat has been well with no other complications for >18 months post-surgery.

Discussion

This report presents two cases of oesophageal trichobezoars. Both cats in this series presented with an acute onset of dyspnoea, likely secondary to aspiration of saliva/regurgitant material or to the physical pressure of the trichobezoar on the trachea. These cases did not have prior clinical signs of oesophageal disease such as regurgitation, as has been reported in other case reports on oesophageal trichobezoars.^{7,8,10,13} Oesophageal foreign bodies presenting solely as acute dyspnoea have been reported in people.¹⁵

Both cases presented had radiographic features of a generalised megaesophagus. Widening of the cranial mediastinum and ventral deviation of the trachea were also noted in both cases radiographically. Acquired causes of generalised megaesophagus were considered

and caudal oesophageal obstruction from a foreign body, stricture or mass was considered likely. General anaesthesia may have contributed to the degree of oesophageal dilation observed with case 1.

Barium was used in a previous case report to highlight the presence of foreign material in the oesophagus.⁷ It is worth noting, however, that if this material is used there is a higher risk of serious complications should aspiration occur. An iodine-based contrast agent offers a safer alternative.¹⁶

A prior history of hair ball expulsion may help direct the clinician to the possibility of trichobezoar entrapment. This is not always the case though, with case 2 in this series having no prior history of vomiting hair balls. Excessive grooming and/or underlying gastrointestinal disease are considered the underlying mechanisms for hair accumulation.⁵ Case 2 had a significant flea burden present, which may have contributed to excessive grooming and subsequent hair ingestion. Flea infestation has also been implicated in another case report of feline oesophageal trichobezoar.⁷ Despite having a history of vomiting hair balls every few weeks, no underlying cause was diagnosed in case 1. A full diagnostic work-up and investigation was not performed however. Both cats in this study were long-haired, which is a reported risk factor in the literature.^{3,4}

A review of the literature revealed only seven case reports involving oesophageal trichobezoars in cats.^{7–13} The majority of the previously reported oesophageal trichobezoars have occurred secondary to underlying oesophageal pathology or dysfunction.^{8,10–13} Both cases in this series had no prior clinical signs or history consistent with oesophageal disease. A full investigation to assess oesophageal motility was not performed in either case, however.

Unfortunately, endoscopic removal was unsuccessful in both cases and surgical intervention was required. Surgery is not always a necessity, however, with endoscopic retrieval successful in other cases of oesophageal trichobezoars.^{7,8} Both cases in this study had severe complications associated with their trichobezoar entrapment.

Case 1 died <24 h postoperatively, likely secondary to aspiration pneumonia. No post-mortem examination was performed. Aspiration pneumonia has been a concomitant finding in other cases of oesophageal trichobezoars.⁸

Case 2 developed severe laryngeal collapse and required a permanent tracheostomy to be performed. The authors suspect, given the duration of time the trichobezoar was present and owing to the downward pressure of the distended oesophagus onto the trachea, that a degree of tracheal collapse occurred resulting in increased airway resistance. Increased airway resistance is a primary component of laryngeal collapse.¹⁷

The cat did surprisingly well post-tracheostomy, having no complications >18 months postoperatively. In the study by Guenther-Yenke and Rozanski,¹⁸ which looked at 23 cases of tracheostomy in cats, the median survival time was 42 days after permanent tracheostomy. Case 2 in our series survived significantly longer than this; however, the majority of cases in the study of Guenther-Yenke and Rozanski had malignant laryngeal neoplasia,¹⁸ which likely negatively impacted on survival time. While not a complication in the surviving case in this report, oesophageal strictures secondary to trichobezoars is a major concern; with several studies on strictures reporting trichobezoars as the causative aetiology.^{19–21}

Prevention of trichobezoars primarily involves management of the underlying disease leading to hair accumulation in the gastrointestinal tract.³ Management can include regular grooming or shaving of hair and appropriate ectoparasite control. A commercial hair ball diet may also be considered, although there is lack of published data available regarding their efficacy.³

Case 2 in our report received routine topical flea control and regular coat management post-discharge.

Conclusions

Although uncommon, oesophageal trichobezoars should be suspected as a differential for any cat that presents with acute dyspnoea, with or without a prior history of hair ball disease.

Conflict of interest The authors declared no potential conflicts of interest with respect to the research, authorship, and/or publication of this article.

Funding The authors received no financial support for the research, authorship, and/or publication of this article.

ORCID iD Dennis J Woerde  <https://orcid.org/0000-0003-1511-8231>

References

- Gonuguntla V and Joshi D-D. **Rapunzel syndrome: a comprehensive review of an unusual case of trichobezoar.** *J Clin Med Res* 2009; 7: 99–102.
- Panaman R. **Behaviour and ecology of freeranging farm cats (*Felis catus*).** *Z Tierpsychol* 1981; 56: 59–73.
- Cannon M. **Hair balls in cats: a normal nuisance or a sign that something is wrong?** *J Feline Med Surg* 2013; 15: 21–29.
- Barrs VR, Beatty JA, Tisdall PL, et al. **Intestinal obstruction by trichobezoars in five cats.** *J Feline Med Surg* 1999; 1: 199–207.
- Crystal MA. **Trichobezoars.** In: Norsworthy GD, Crystal MA, Grace SF, et al (eds). *The feline patient*. 3rd ed. Ames, IA: Blackwell, 2006, pp 314–315.
- Haynes KJ, Anderson SE and Laszlo MP. **Nasopharyngeal trichobezoar foreign body in a cat.** *J Feline Med Surg* 2010; 12: 878–881.
- Squires RA. **Oesophageal obstruction by a hairball in a cat.** *J Small Anim Pract* 1989; 30: 311–314.
- Durocher L, Johnson SE and Green E. **Esophageal diverticulum associated with a trichobezoar in a cat.** *J Am Anim Hosp Assoc* 2009; 45: 142–146.
- Court EA, Cole C, Allan GS, et al. **An unusual oesophageal foreign body in a cat.** *Aust Vet Pract* 1994; 24: 198–202.
- Owen MC, Morris PJ and Bateman RS. **Concurrent gastro-oesophageal intussusception, trichobezoar and hiatal hernia in a cat.** *NZ Vet J* 2005; 53: 371–374.
- Regnier A. **Megaesophagus with intraesophageal hairball and esophagitis in a cat.** *Feline Pract* 1985; 15: 22–26.
- Van Stee EW, Ward CW and Duffy ML. **Recurrent esophageal hairballs in a cat (a case report).** *Vet Med Small Anim Clin* 1980; 75: 1873–1878.
- Clifford DH, Soifer FK and Freeman RG. **Stricture and dilatation of the esophagus in the cat.** *J Am Vet Med Assoc* 1970; 156: 107–114.
- Nelson WA. **Diseases of the trachea and bronchi.** In: Slatyer D (ed). *Textbook of small animal surgery*. Philadelphia, PA: Saunders, 2003, pp 858–880.
- Singh A, Panda SS, Panda M, et al. **Upper oesophageal foreign body with acute respiratory distress.** *BMJ Case Rep* 2013; 2013. DOI:10.1136/bcr-2013-010342.
- Beckett KR, Moriarity AK and Langer JM. **Safe use of contrast media: what the radiologist needs to know.** *Radiographics* 2015; 35: 1738–1750.
- MacPhail C. **Laryngeal disease in dogs and cats.** *Vet Clin North Am Small Anim Pract* 2014; 44: 19–31.
- Guenther-Yenke CL and Rozanski EA. **Tracheostomy in cats: 23 cases (1998–2006).** *J Feline Med Surg* 2007; 9: 451–457.
- Bissett SA, Davis J, Subler K, et al. **Risk factors and outcome of bougienage for treatment of benign esophageal strictures in dogs and cats: 28 cases (1995–2004).** *J Am Vet Med Assoc* 2009; 235: 844–850.
- Leib MS, Dinnel H, Ward DL, et al. **Endoscopic balloon dilation of benign esophageal strictures in dogs and cats.** *J Vet Intern Med* 2001; 15: 547–552.
- Harai BH, Johnson SE and Sherding RG. **Endoscopically guided balloon dilatation of benign esophageal strictures in 6 cats and 7 dogs.** *J Vet Intern Med* 1995; 9: 332–335.