

Distinct mutation in the feline coronavirus spike protein cleavage activation site in a cat with feline infectious peritonitis-associated meningoencephalomyelitis

Authors: André, Nicole M, Cossic, Brieuc, Davies, Emma, Miller, Andrew D, and Whittaker, Gary R

Source: Journal of Feline Medicine and Surgery Open Reports, 5(1)

Published By: SAGE Publishing

URL: <https://doi.org/10.1177/2055116919856103>

BioOne Complete (complete.BioOne.org) is a full-text database of 200 subscribed and open-access titles in the biological, ecological, and environmental sciences published by nonprofit societies, associations, museums, institutions, and presses.

Your use of this PDF, the BioOne Complete website, and all posted and associated content indicates your acceptance of BioOne's Terms of Use, available at www.bioone.org/terms-of-use.

Usage of BioOne Complete content is strictly limited to personal, educational, and non - commercial use. Commercial inquiries or rights and permissions requests should be directed to the individual publisher as copyright holder.

BioOne sees sustainable scholarly publishing as an inherently collaborative enterprise connecting authors, nonprofit publishers, academic institutions, research libraries, and research funders in the common goal of maximizing access to critical research.



Distinct mutation in the feline coronavirus spike protein cleavage activation site in a cat with feline infectious peritonitis-associated meningoencephalomyelitis

Journal of Feline Medicine and Surgery Open Reports
1–7

© The Author(s) 2019

Article reuse guidelines:

sagepub.com/journals-permissions

DOI: 10.1177/2055116919856103

journals.sagepub.com/home/jfmsopenreports

This paper was handled and processed by the American Editorial Office (AAFP) for publication in *JFMS Open Reports*



Nicole M André¹, Brieuc Cossic², Emma Davies³, Andrew D Miller² and Gary R Whittaker¹

Abstract

Case summary This report describes a cat with chronic, progressive, non-painful, non-lateralizing multifocal neurologic clinical signs associated with feline infectious peritonitis (FIP). The cat initially presented as underweight, despite a good appetite, and a complete blood count showed non-regenerative anemia. Three months later the cat was returned having developed ataxia and paraparesis, which then progressed over 2 months to tetraparesis, tail plegia, urinary and fecal incontinence, and titubation. Histologic examination of the tissues with subsequent immunohistochemistry confirmed FIP-associated meningoencephalomyelitis following necropsy. Molecular analysis of the coronavirus spike protein within the tissues identified a specific, functionally relevant amino acid change (R793M), which was only identified in tissues associated with the central nervous system (ie, brain and spinal cord).

Relevance and novel information This case report describes an early presentation of a cat with primarily neurologic FIP, with molecular characterization of the virus within various tissues.

Keywords: Feline infectious peritonitis; feline coronavirus; spike protein; neurologic; meningoencephalomyelitis

Accepted: 13 May 2019

Introduction

Feline infectious peritonitis (FIP) is caused by feline coronavirus (FCoV) and is widely considered to be one of the most significant infectious diseases to affect the feline population.^{1–3} It is the most common infectious disease of the central nervous system (CNS) of cats.⁴ FCoV have been reported to exist as two distinct serotypes: type I (more common) and type II viruses,⁵ each with distinct biological properties.^{5,6} Both FCoV serotypes have distinct ‘biotypes’. These are typically classified as either feline enteric coronavirus (FECV) or feline infectious peritonitis virus (FIPV), with the biotypes differing based on the severity of infection in cats.^{7–9}

Infection with FCoV is common, especially in high-density housing situations such as animal shelters and breeding facilities.¹⁰ The FECV biotype transmits readily and causes only a mild infection, with transmission

occurring via fecal–oral and possibly other routes.^{7,11} If the viral infection worsens and becomes systemic (typically infecting macrophages), then the virus is classified

¹Department of Microbiology & Immunology, Cornell University College of Veterinary Medicine, Ithaca, NY, USA

²Department of Biomedical Sciences, Section of Anatomic Pathology, Cornell University College of Veterinary Medicine, Ithaca, NY, USA

³Department of Clinical Sciences, Cornell University College of Veterinary Medicine, Ithaca, NY, USA

Corresponding author:

Gary R Whittaker BSc, PhD, Departments of Microbiology and Immunology, Cornell University College of Veterinary Medicine, 930 Campus Rd, Ithaca, NY 14853, USA
Email: grw7@cornell.edu



Creative Commons Non Commercial CC BY-NC: This article is distributed under the terms of the Creative Commons

Attribution-NonCommercial 4.0 License (<http://www.creativecommons.org/licenses/by-nc/4.0/>) which permits non-commercial use, reproduction and distribution of the work without further permission provided the original work is attributed as specified on the SAGE and Open Access pages (<https://us.sagepub.com/en-us/nam/open-access-at-sage>).

as the FIPV biotype.⁸ Such viruses are believed to contain an 'internal mutation' that accounts for the altered tropism, although the nature of this mutation is not well understood.¹²

Clinical signs associated with the FIPV biotype can be quite variable and non-specific, and can include fever, lethargy, anorexia, pica, vomiting and diarrhea.¹³ These clinical signs can be present in either the 'wet', 'dry' or 'mixed' presentations.¹⁴ The wet form of FIP is characterized by an effusion in the abdominal and/or thoracic or pericardial cavities, and the 'dry' form by the presence of pyogranulomatous lesions. The 'mixed' form may present with an array of clinical signs. Most commonly, neurologic clinical signs are associated with the 'dry' form but can occur with all presentations and may be the sole clinical sign observed.^{12,13}

Clinical features of neurologic FIP can include, but are not limited to, ataxia, head tremors, seizures and/or paresis.^{12,13,15} Ocular lesions may be present with or without lesions in the CNS. FIP-associated pathologic changes to the CNS include meningitis, encephalitis, ependymitis and choroid plexitis, often with concurrent vasculitis.^{12,13} FIP presenting with predominantly neurologic clinical signs provides a diagnostic challenge and definitive ante-mortem diagnosis is difficult. MRI has been identified as a sensitive method of diagnosis in conjunction with clinical signs and cerebrospinal fluid analysis results such as elevated protein levels and neutrophilic pleocytosis.¹⁶ However, such findings are still not specific to FIP and may be financially prohibitive. FIP may also be considered a diagnosis of exclusion, following evaluation of clinical signs, history and physical examination findings and biochemical values.^{12,13}

This case report describes a cat with neurologic FIP that progressed over several months. The observations and findings obtained in this case provide support that FIP can present predominantly in the CNS. When molecular techniques are applied to the virus, a propensity for certain mutations can be associated with specific clinical presentations or pathologic changes.

Case description

An intact female 8-week-old domestic shorthair cat was taken into a foster/rescue home and cohabited a house with approximately nine other cats. The facility had a periodic history of FIP cases, including two deaths in the previous 4 months. The cat was co-housed in a large open sunroom containing seven litterboxes, which were cleaned once daily. The diet consisted of commercially available dry and canned food, which was separately offered in individual dishes. The cat was not rabies vaccinated, but had obtained two feline viral rhinotracheitis, calicivirus and panleukopenia vaccinations.

At 14 weeks of age, the cat was presented to a general practitioner for evaluation of poor weight gain, soft stool

and upper respiratory tract infection. The cat was under-conditioned and weighed 2.5 lb (1.1 kg), with a body condition score (BCS) of 2/5, despite being active, alert and having a good appetite. Conjunctivitis and a yellow mucopurulent discharge from the nares were noted, and the cat had a fever of 102.6°F (39.2°C). A fecal flotation was performed owing to the soft but formed stool, and no ova or parasites were detected. A complete blood count (CBC) and chemistry profile were performed (Tables 1 and 2). The chemistry profile showed marked elevations in alkaline phosphatase, alanine transferase and phosphorus levels. A decrease in creatinine and albumin was also noted (Table 1), along with mild anemia and monocytosis. Amoxicillin clavulanic acid (Clavamox drops; Zoetis) 62.5 mg/ml was dispensed and administered at 15.6 mg (12 mg/kg) PO q12h for 10 days. Blood parameters were re-evaluated at 20 weeks of age using a less defined panel and values were within the normal range (Table 1).

At approximately 6 months of age, the cat returned to the general practitioner for evaluation of pelvic limb gait abnormalities that had progressed over the previous 2 weeks. Examination revealed symmetric pulses in both hindlimbs and the presence of a pain response; however, less of a response was noted on the right side. Paresis was observed in the right hindlimb. When the forelimbs were lifted, the cat was able to walk minimally on the hindlimbs. The cat had severe non-ambulatory paraparesis, with more severe deficits on the right side. No information about spinal reflexes was available. A CBC and chemistry panel were performed (Tables 1 and 2). The chemistry panel revealed hypoalbuminemia, a decrease in the albumin:globulin (A:G) ratio, low creatinine values and hyperphosphatemia. The CBC revealed a slight anemia, monocytosis and thrombocytopenia. Platelet clumping was noted upon microscopic evaluation. Meloxicam (Metacam oral suspension) was dispensed and a single 0.2 mg dose was administered orally.

At 8 months of age, the cat was returned to the general practitioner due to progression of the paraparesis. The client noted further deterioration of the pelvic limb paresis, and now identified 'stiffness' in the thoracic limbs. There was no information about the pelvic limb reflexes; however, the cat had started to have occasional urinary and fecal incontinence. Appetite seemed normal; however, the cat remained thin. Physical examination revealed a temperature of 101.5°F (38.6°C), heart rate of 170 beats per min and respiratory rate of 30 breaths per min. BCS was 3/9; however, the weight was not noted. Abdominal palpation revealed a large, easily expressible urinary bladder. Neurologic examination findings revealed normal mentation with no involuntary movements such as tremors. The cat was still very ataxic and ambulatory but now tetraparetic, which was much

Table 1 Summary of the chemistry profiles performed at 14, 20 and 29 weeks of age

Test	Age 14 weeks	Age 20 weeks	Age 29 weeks
Sodium (RI 147–155 mmol/l)	148		150
Potassium (RI 3.7–5.2 mmol/l)	4.8		4.4
Chloride (RI 114–126 mmol/l)	117		116
TCO ₂ (bicarbonate; RI 12–22 mmol/l)	16		18
Anion gap (RI 12–25 mmol/l)	20		20
Sodium:potassium ratio (RI 29–42)	31		34
BUN (RI 16–37 mg/dl)	22	24 (RI 16–33 mg/dl)	23
Creatinine (RI 0.9–2.5 mg/dl)	0.5	0.9	0.6
BUN/creatinine ratio	44	27	38.3
Calcium (RI 8.2–11.2 mg/dl)	10		9.3
Phosphorus (RI 2.9–6.3 mg/dl)	7.7		6.7
Total protein (RI 6.3–8.8 g/dl)	7.4		8.2
Albumin (RI 2.6–3.9 g/dl)	2.5	2.7	2.5
Globulin (RI 3.0–5.9 g/dl)	4.9		5.7
Albumin:globulin ratio (RI 0.5–1.2)	0.5	0.5	0.4
Glucose (RI 72–175 mg/dl)	87	95 (RI 77–153 mg/dl)	91
ALT (RI 27–158 U/l)	272		71
AST (RI 16–67 U/l)	68		33
ALP (RI 12–59 U/l)	101	48 (RI 14 – 192 U/l)	58
GGT (RI 0–6 U/l)	2		3
Total bilirubin (RI 0.0–0.3 mg/dl)	0.1		0.1
Bilirubin conjugated (RI 0.0–0.2 mg/dl)	<0.1		<0.1
Bilirubin unconjugated (RI 0.0–0.2 mg/dl)	0		0
Amylase (RI 623–2239 U/l)	1086		1210
Lipase (RI 11–242 U/l)	41		57
Cholesterol (RI 91–305 mg/dl)	133		96
Creatine kinase (RI 64–440 U/l)	166		73
SDMA (0–14 µg/dl)	9		12

RI = reference interval; BUN = blood urea nitrogen; ALT = alanine transferase; AST = aspartate aminotransferase; ALP = alkaline phosphatase; GGT = gamma-glutamyl transferase; SDMA = symmetric dimethylarginine

worse in the pelvic limbs. There was no information about cranial nerve abnormalities, and the eyes and retinas were within normal limits. From a video provided by the owner (see supplementary material), tail paresis was identified. The lesion was considered to affect the CNS and was localized as multifocal. A fecal flotation and direct smear were evaluated, with no ova or parasites seen. *Cryptococcus* and *Toxoplasma* antibody titers were performed and were negative.

The tetra-ataxia and paresis significantly worsened over the next few months. Additionally, the cat now had titubation, tail plegia (see video in the supplementary material) and consistent urinary and fecal incontinence. Owing to the grave prognosis, the client elected humane euthanasia, at which time the cat was 10 months (40 weeks) of age. A necropsy was performed at the Animal Health Diagnostic Center, Cornell University College of Veterinary Medicine, and this revealed no significant gross abnormalities outside of mild mesenteric lymphadenomegaly. Representative sections of all organs, including the entire brain and spinal cord, were fixed in 10% neutral buffered formalin from which sections were

cut, stained with hematoxylin and eosin, and analyzed via light microscopy. Immunohistochemistry for FCoV was carried out using monoclonal antibody FIPV3-70 (1:1000), AP-Anti-Mouse IgG and Bond Polymer Refine Red Detection (Leica Microsystems).

Histologic examination revealed lesions typical of FCoV infection within the CNS. In the spinal cord, the leptomeninges were diffusely expanded by moderate numbers of predominantly plasma cells, admixed with fewer lymphocytes and macrophages, and surrounded by a moderate amount of edema. The underlying white matter was multifocally vacuolated with numerous dilated myelin sheaths, digestion chambers and rare spheroids (Figure 1a). At the level of the lateral aperture, the choroid plexus was expanded by large numbers of plasma cells, lymphocytes and macrophages (Figure 1b). The ependyma lining the ventricular system was effaced by a similar inflammatory population, admixed with fibrin, edema and was also forming thick perivascular cuffs often disrupting the sub-ependymal parenchyma (Figure 1c). Immunohistochemistry revealed strong intracytoplasmic immunoreactivity within macrophages

Table 2 Summary of the complete blood counts performed at 14 weeks and 29 weeks of age

	Age 14 weeks	Age 29 weeks
Hematocrit (RI 28.2–52.7%)	27.8	31.9
Hemoglobin (RI 10.3–16.2 g/dl)	8.4	10.7
RBCs (7.12–11.46 M/ μ l)	5.88	7.01
MCV (RI 39–56 fl)	47	46
MCH (RI 12.6–16.5 pg)	14.3	15.3
MCHC (RI 28.5–37.8 g/dl)	30.2	33.5
Reticulocytes (RI 3–50 K/ μ l)	41	14
% Reticulocyte	0.7	0.2
Reticulocyte comment	Inadequate bone marrow response	Inadequate bone marrow response
WBCs (RI 3.9–19.0 K/ μ l)	15.2	9.7
Neutrophils (RI 2620–15,150/ μ l)	10,017	5471
Lymphocytes (RI 850–5850/ μ l)	4119	3259
Monocytes (RI 40–530/ μ l)	775	301
Eosinophils (RI 90–2180/ μ l)	274	660
Basophils (RI 0–100/ μ l)	15	10
% Neutrophils	65.9	56.4
% Lymphocytes	27.1	33.6
% Monocytes	5.1	3.1
% Eosinophils	1.8	6.8
% Basophils	0.1	0.1
Platelets (RI 155–641 K/ μ l)	63	103

RI = reference interval; RBCs = red blood cells; MCV = mean cell volume; MCH = mean cell hemoglobin; MCHC = mean cell hemoglobin concentration; WBCs = white blood cells

associated with the inflammation (Figure 1d). No FIP-associated lesions were present in other organs. Non-FCoV comorbid histologic findings were chronic enteritis with mid-mucosal fibrosis and mesenteric lymphoid hyperplasia.

Molecular analysis of the viral spike protein was performed at several time points during the study. Fecal samples were collected at 5 months of age (feces #1) and at 8 months of age (feces #2). Following euthanasia (at 10 months of age) tissue samples were collected, along with a fecal sample (feces #3). A central 156 base pair region of the spike protein gene, including the critical S1/S2 activation site of the virus, was PCR amplified and sequenced as described in Licitra et al,¹⁷ with the following modifications: 25 μ l reverse transcription PCRs were performed with qScript XLT 1-Step RT PCR kit (Quantbio). PCR conditions were 20 mins at 50°C, 3 mins at 95°C and 40 cycles of 10 s at 95°C, 20 s at 55°C, 40 s at 72°C, then 10 mins at 72°C. PCR products were purified using Diffinity RapidTips (Diffinity Genomics).

PCR and sequencing showed the presence of a type I FCoV, based on a sequence alignment with reference genomes. The sequence information obtained from this cat is shown in Figure 2. The viral sequences from the CNS (brain and spinal cord) contained specific amino acid changes compared with other samples (feces, small intestine, mesenteric lymph node and kidney). The most notable change was an arginine to methionine (R-M)

substitution at the critical P1 activation position,¹⁷ corresponding to residue 793. Other changes that correlated with viruses present in the CNS were present in two other positions: 770 alanine to valine (A-V); and 786 threonine to alanine (T-A).

Discussion

Here we report clinicopathologic findings and molecular analysis of a cat with progressive neurologic clinical signs associated with FIP. The cat initially presented to the referring veterinarian with respiratory signs and fever, and with abnormal liver enzyme function and anemia. At this time FIP was not suspected. These initial signs resolved but were replaced by progressing neurologic signs, which led ultimately to euthanasia and submission to the study for evaluation of FCoV involvement. Upon euthanasia, FCoV was found in various tissues in the cat, including the CNS. However, histologic examination revealed FCoV-associated pathology only within the CNS, where there was meningoencephalomyelitis, ependymitis, choroid plexitis and vasculitis. Histological lesions were compatible with a recent report describing meningoencephalitis in four cats with FIP.¹⁸

Molecular analysis of the viral spike protein within the tissues identified a specific, functionally relevant amino acid change (R793M), which was only identified in tissues associated with the CNS (ie, brain and spinal

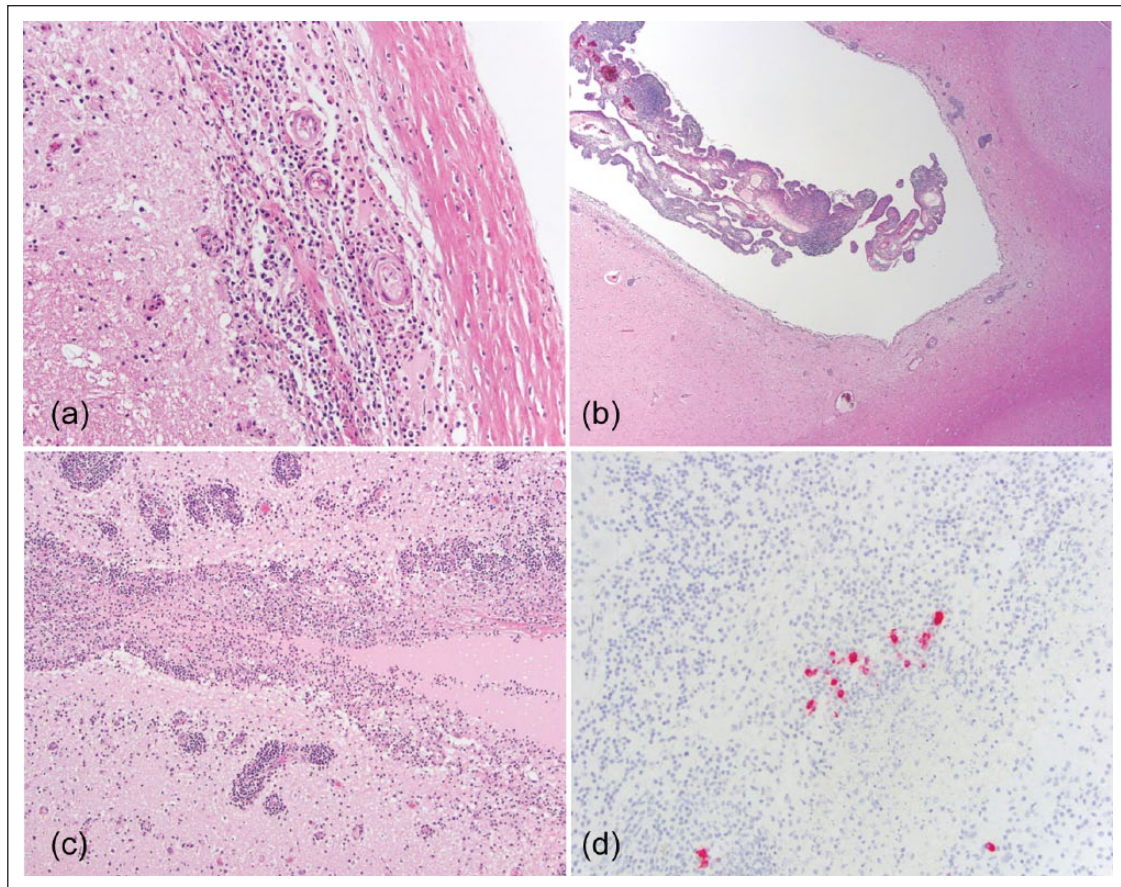


Figure 1 Feline infectious peritonitis (FIP)-associated meningoencephalomyelitis. (a) Spinal cord. The meninges are expanded by large numbers of plasma cells, lymphocytes and macrophages ($\times 200$, hematoxylin and eosin). (b) Telencephalon, lateral ventricle. The choroid plexus is markedly expanded by inflammation, which extends into the surrounding periventricular tissue ($\times 20$, hematoxylin and eosin). (c) Mesencephalon. The mesencephalic aqueduct is obliterated by inflammation, which extends in the adjacent tissue ($\times 200$, hematoxylin and eosin). (d) Rhombencephalon, fourth ventricle. Numerous macrophages have a strong intracytoplasmic positive immunoreactive signal ($\times 40$, FIP virus immunohistochemistry)

[illegible]

Figure 2 Molecular analysis of the spike gene. A 156 base pair region of the feline coronavirus (FCoV) spike protein gene is shown and represented in single amino acid code, with variant residues from the central nervous system sample colored and amino acid positions noted. The activation site between the S1 and S2 domains (S1/S2) is indicated and boxed. Amino acid positions are based on that for FCoV RM spike (Genbank accession #ACT10854.1) as a prototype sequence. Sequences were analyzed using Geneious v. 10.1.2

cord). The R793M mutation in the spike protein S1/S2 cleavage-activation site is a major chemical change from a basic to a hydrophobic residue, and is consistent with an elimination of furin-mediated proteolytic processing

of the S protein, as seen by Licitra et al,¹⁷ and a proposed change in the activation properties and entry pathway of the virus. It is interesting to note that the R793M mutation was not present in other tissues tested in this cat at

Table 3 Summary of the molecular analysis performed on the viral genome in various samples

	Spike S1/S2	Spike position 1058	3c gene
Feces #1	SKRLRRS	M	Intact
Feces #2	SKRLRRS	M	Intact
Feces #3	SKRLRRS	M	Intact
Small intestine	SKRLRRS	—*	—*
Mesenteric lymph node	SKRLRRS	—*	—*
Kidney	SKRLRRS	M	Premature termination [†]
Brain	SKRLRMS	L	Premature termination [†]
Spinal cord	SKRLRMS	L	Premature termination [†]

*Not determined

[†]Individual sequences were terminated in different ways

M = methionine; L = leucine

the time of necropsy but was found in our previous study (cat ID #08-153990),¹⁷ where samples were of neural origin. While biological confirmation is not available, we consider that the other changes found in the viral spike protein from central nervous tissue of this cat (A770V and T786A) are not related to changes in the activation properties and entry pathway of the virus, as they are not in defined functional regions of the spike protein and are not markedly different in their chemistry. Interestingly, all samples tested from this cat contained a distinct leucine residue at position 791 (the P3 position of the furin cleavage site, typically serine or alanine as defined in Licitra et al).¹⁷ The relevance of this is currently unclear. Overall, our results provide evidence that mutation of the viral spike protein is linked to FIP outcome, specifically in the S1/S2 cleavage-activation site (residues 789–794).

Mutations leading to FIP have also been linked to changes in other areas of the spike gene (position 1058)¹⁹ and in the 3c gene.^{20,21} To compare our findings for the S1/S2 region to other proposed FIP-linked mutations, we performed additional sequencing, which is summarized in Table 3. All fecal samples, as well as a kidney sample, contained methionine (M) at spike position 1058, indicating that an 'enteric' form of FCoV²² was present in the cat throughout our study. In contrast, samples from the brain and spinal cord contained leucine (L) at position 1058, indicating an FIP virus. An intact 3c gene was found in feces, with the 3c gene in neural and other tissues truncated and/or deleted depending on the sample tested.

Conclusions

This case report describes a young cat with neurologic FIP in which detailed clinical and molecular characterization of the associated FCoV infection was performed. While the etiology of FIP remains complex and likely involves multiple mutations in the viral genome, our

results indicate that a specific mutation of the viral spike protein can be associated with infection of the CNS, which may explain the tropism to the CNS as opposed to other organ systems.

Acknowledgements We thank Wendy Wingate for help with sample collection, all members of the Whittaker lab for helpful comments and support, and Dr John Loftus for clinical consultation and critical reading of the manuscript.

Supplementary material Video of cat at 8 months and 10 months of age.

Conflict of interest The authors declared no potential conflicts of interest with respect to the research, authorship, and/or publication of this article.

Funding This work was funded by the Cornell Feline Health Center.

Ethical approval This study involved the use of client-owned animal(s) only, and followed internationally recognized high standards ('best practice') of individual veterinary clinical patient care. Ethical Approval from a committee was not therefore needed.

Informed consent Informed consent (either verbal or written) was obtained from the owner or legal guardian of all animal(s) described in this study for the procedure(s) undertaken. For any animals or humans individually identifiable within this publication, Informed Consent for their use in the publication (verbal or written) was obtained from the people involved.

ORCID iD Nicole M André  <https://orcid.org/0000-0002-3703-5026>

References

- 1 Pedersen NC. An update on feline infectious peritonitis: diagnostics and therapeutics. *Vet J* 2014; 201: 133–142.

- 2 Pedersen NC. **An update on feline infectious peritonitis: virology and immunopathogenesis.** *Vet J* 2014; 201: 123–132.
- 3 Gunn-Moore DA and Reed N. **CNS disease in the cat: current knowledge of infectious causes.** *J Feline Med Surg* 2011; 13: 824–836.
- 4 Marioni-Henry K, Vite CH, Newton AL, et al. **Prevalence of diseases of the spinal cord of cats.** *J Vet Intern Med* 2004; 18: 851–858.
- 5 MacLaughlan NJ and Dubovi EJ. *Fenner's veterinary virology*. 5th ed. New York: Academic Press, 2017.
- 6 Whittaker GR, Andre NM and Millet JK. **Improving virus taxonomy by recontextualizing sequence-based classification with biologically relevant data: the case of the Alphacoronavirus 1 species.** *mSphere* 2018; 3. DOI: 10.1128/mSphereDirect.00463-17.
- 7 Addie DD. **Feline coronavirus infections.** In: Greene CE (ed). *Infectious diseases of the dog and cat*. St Louis, MO: Elsevier Saunders, 2012, pp 92–108.
- 8 Foley JE and Leutenegger C. **A review of coronavirus infection in the central nervous system of cats and mice.** *J Vet Intern Med* 2001; 15: 438–444.
- 9 Ives EJ, Vanhaesebrouck AE and Cian F. **Immunocytochemical demonstration of feline infectious peritonitis virus within cerebrospinal fluid macrophages.** *J Feline Med Surg* 2013; 15: 1149–1153.
- 10 Gingrich E and Lappin M. **Practical overview of common infectious disease agents.** In: Miller L and Zawistowski S (eds). *Shelter medicine for veterinarians and staff*. Chichester: John Wiley & Sons, 2013, pp 297–328.
- 11 Timoney JF, Gillespie JH, Scott FW, et al. *Hagan and Brunner's microbiology and infectious diseases of domestic animals*. 8th ed. New York: Cornell University Press, 1988.
- 12 Diaz JV and Poma R. **Diagnosis and clinical signs of feline infectious peritonitis in the central nervous system.** *Can Vet J* 2009; 50: 1091–1093.
- 13 Rissi DR. **A retrospective study of the neuropathology and diagnosis of naturally occurring feline infectious peritonitis.** *J Vet Diagn Invest* 2018; 30: 392–399.
- 14 Kline KL, Joseph RJ and Averill DR. **Feline infectious peritonitis with neurologic involvement: clinical and pathological findings in 24 cats.** *J Am Animal Hospital Assoc* 1994; 30: 111–118.
- 15 Legendre AM and Whitenack DL. **Feline infectious peritonitis with spinal cord involvement in two cats.** *J Am Vet Med Assoc* 1975; 167: 31–32.
- 16 Crawford AH, Stoll AL, Sanchez-Masian D, et al. **Clinicopathologic features and magnetic resonance imaging findings in 24 cats with histopathologically confirmed neurologic feline infectious peritonitis.** *J Vet Intern Med* 2017; 31: 1477–1486.
- 17 Licitra BN, Millet JK, Regan AD, et al. **Mutation in spike protein cleavage site and pathogenesis of feline coronavirus.** *Emerg Infect Dis* 2013; 19: 1066–1073.
- 18 Wang H, Hirabayashi M, Chambers JK, et al. **Immunohistochemical studies on meningoencephalitis in feline infectious peritonitis (FIP).** *J Vet Med Sci* 2018; 80: 1813–1817.
- 19 Chang HW, Egberink HF, Halpin R, et al. **Spike protein fusion peptide and feline coronavirus virulence.** *Emerg Infect Dis* 2012; 18: 1089–1095.
- 20 Pedersen NC, Liu H, Dodd KA, et al. **Significance of coronavirus mutants in feces and diseased tissues of cats suffering from feline infectious peritonitis.** *Viruses* 2009; 1: 166–184.
- 21 Chang HW, de Groot RJ, Egberink HF, et al. **Feline infectious peritonitis: insights into feline coronavirus pathobiogenesis and epidemiology based on genetic analysis of the viral 3c gene.** *J Gen Virol* 2010; 91: 415–420.
- 22 Porter E, Tasker S, Day MJ, et al. **Amino acid changes in the spike protein of feline coronavirus correlate with systemic spread of virus from the intestine and not with feline infectious peritonitis.** *Vet Res* 2014; 45: 49. DOI: 10.1186/1297-9716-45-49.