

Aneurysmal bone cyst in the pelvis of a cat: successful outcome of partial iliectomy with limb preservation

Authors: Winbladh, Kajsa, Fransson, Boel A, Svensson, Gustaf, Karlstam, Erika, and Uhlhorn, Margareta

Source: Journal of Feline Medicine and Surgery Open Reports, 6(2)

Published By: SAGE Publishing

URL: <https://doi.org/10.1177/2055116920974984>

BioOne Complete (complete.BioOne.org) is a full-text database of 200 subscribed and open-access titles in the biological, ecological, and environmental sciences published by nonprofit societies, associations, museums, institutions, and presses.

Your use of this PDF, the BioOne Complete website, and all posted and associated content indicates your acceptance of BioOne's Terms of Use, available at www.bioone.org/terms-of-use.

Usage of BioOne Complete content is strictly limited to personal, educational, and non - commercial use. Commercial inquiries or rights and permissions requests should be directed to the individual publisher as copyright holder.

BioOne sees sustainable scholarly publishing as an inherently collaborative enterprise connecting authors, nonprofit publishers, academic institutions, research libraries, and research funders in the common goal of maximizing access to critical research.



Aneurysmal bone cyst in the pelvis of a cat: successful outcome of partial iliectomy with limb preservation

Journal of Feline Medicine and Surgery Open Reports
1–7

© The Author(s) 2020

Article reuse guidelines:

sagepub.com/journals-permissions

DOI: 10.1177/2055116920974984

journals.sagepub.com/home/jfmsopenreports

This paper was handled and processed by the European Editorial Office (ISFM) for publication in *JFMS Open Reports*



Kajsa Winbladh¹ , Boel A Fransson², Gustaf Svensson¹, Erika Karlstam³ and Margareta Uhlhorn⁴

Abstract

Case summary A 3-year-old spayed female domestic shorthair indoor cat presented with a 3-week history of pain from the pelvic region. Physical examination revealed pain elicited on palpating the pelvic area and right hip. Radiographs and CT showed an expansile, osteolytic process with intact cortex in the right wing of the ilium. CT revealed a monostotic and soft tissue-attenuating process with clear margins. Preoperative histopathological diagnosis of aneurysmal bone cyst was made from incisional biopsies. The cyst was removed en bloc with limb-sparing partial iliectomy. Histopathology confirmed the diagnosis of aneurysmal bone cyst. Recovery from surgery was uneventful. At re-examination 8 weeks and 8 months postoperatively, the cat was pain free and physical examinations were within normal limits.

Relevance and novel information Feline aneurysmal bone cysts are rare and reported cases are few. To our knowledge, this is the first report describing the CT appearance of a pelvic aneurysmal bone cyst and partial iliectomy with limb preservation in a cat with successful short-term outcome.

Keywords: Aneurysmal bone cyst; bone cyst; CT; limb preservation; iliectomy; internal hemipelvectomy

Accepted: 27 October 2020

Introduction

Aneurysmal bone cysts (ABCs) are rarely reported in cats.^{1–3} They are benign but often locally aggressive, with lytic bone lesions. Malignant transformation is unlikely, but a few cases have been reported in people and there is one case report in a dog.^{4–7} The clinical signs of pain, swelling and functional impairment are frequently reported. Few ABCs are discovered as an incidental finding.^{8–12} In cats, solitary pelvic, scapular and rib^{1–3} ABCs are not true cysts but blood-filled cavities in the bone separated by connective tissue septa.¹³ The aetiology and pathogenesis are poorly understood. In humans, they are suggested to be either a primary neoplasm or a secondary reaction to another bone lesion, often a benign neoplasm.^{14,15} Diagnostic imaging provides a probable diagnosis,^{1,4,16} but histopathology is required to differentiate ABC from unicameral bone cyst and malignant bone neoplasms, especially telangiectatic osteosarcoma.^{1,2}

Standard treatment in people is cyst wall curettage combined with bone graft for structural support;¹⁷ standard treatment in cats has not yet been reported. Because of variations in recurrence rate, curettage is often combined with adjuvant therapy such as cryotherapy, sclerotherapy,

¹Department of Surgery, Blue Star Small Animal Hospital, Gothenburg, Sweden

²Department of Veterinary Clinical Sciences, Washington State University, Pullman, WA, USA

³Department of Pathology and Wildlife Diseases, Swedish National Veterinary Institute, Uppsala, Sweden

⁴University Animal Hospital, Swedish University of Agricultural Sciences Uppsala, Sweden

Corresponding author:

Kajsa Winbladh DVM, Department of Surgery, Blue Star Small Animal Hospital, Gjutjärnsgatan 4, Gothenburg 41707, Sweden
Email: kajsa.winbladh@blastjarnan.se



Creative Commons Non Commercial CC BY-NC: This article is distributed under the terms of the Creative Commons

Attribution-NonCommercial 4.0 License (<https://creativecommons.org/licenses/by-nc/4.0/>) which permits non-commercial use, reproduction and distribution of the work without further permission provided the original work is attributed as specified on the SAGE and Open Access pages (<https://us.sagepub.com/en-us/nam/open-access-at-sage>).

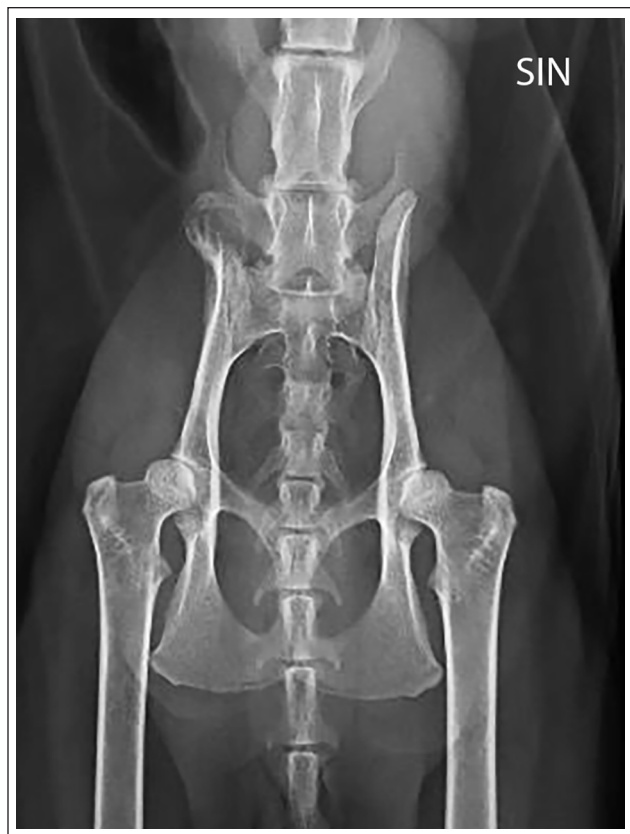

Figure 1 Ventrodorsal view of the pelvis. A mildly expansile, 10 mm diameter circular osteolytic lesion with a thin cortex and an internal 'soap bubble' appearance in the most cranial part of the right ilium wing

argon beam coagulation, bone cement or the mechanical effect of a high-speed burr.^{1,18–20} However, efficacy between adjuvants differ, with some having substantial adverse effects. Furthermore, availability may be inconsistent.^{1,17,18} In people, the prognosis for ABC is regarded as good.^{1,2} Iliectomy, that is, cranial internal hemipelvectomy, removes the wing of the ileum, parts of the ileal body caudal to the sacroiliac (SI) articulation and preserves the pelvic limb.²¹ This report describes partial iliectomy as a viable surgical method for an ABC in the wing of the ilium of a cat, with a successful short-term outcome.

Case description

A 3-year-old spayed female domestic shorthair indoor cat, weighing 4.7 kg (body condition score 5/9) was presented with a 3-week history of pain from the pelvic region. There was no history of trauma. Signs noted by the owner included vocalisation and difficulties jumping up. At presentation, the cat was bright and alert but showed an aggressive temperament. Orthopaedic examination revealed a moderate pain reaction palpating the lumbar back and the right hip, and a bilateral non-painful grade 1 medial patellar luxation. Lameness or

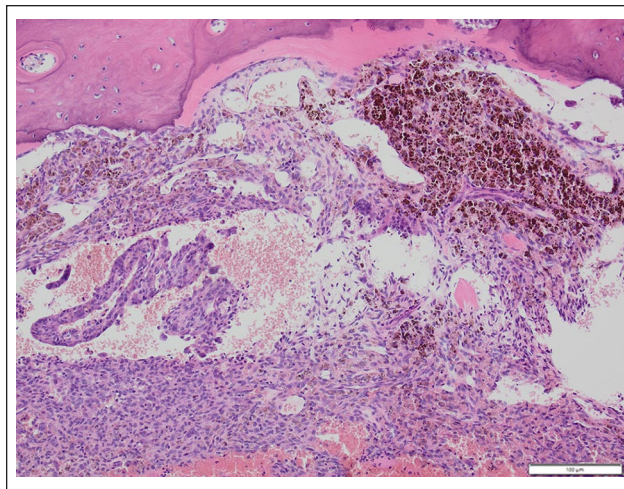


Figure 2 Preoperative biopsy specimen showing intraosseous cavernous vascular spaces, in close association with bone tissue. Vascular spaces are filled with blood and outlined by flat, endothelial-like cells. Vascular spaces are separated by strands of monomorphic, spindle-shaped mesenchymal cells. Multifocal accumulation of macrophages filled with hemosiderin is also seen. Haematoxylin and eosin, $\times 100$

gait abnormality was not noted. Physical examination was otherwise unremarkable.

Orthogonal pelvic radiographs illustrated a mildly expansile, 10 mm in diameter circular osteolytic lesion with a thin cortex and an internal 'soap bubble' appearance in the most cranial part of the right wing of the ilium (Figure 1). Thoracic radiographs were unremarkable. Three bone biopsies were taken from the right wing of the ilium using a Rongeur and sent for histopathological examination. Awaiting the histopathology report, conservative treatment was prescribed, including rest, buprenorphine (0.001 mg/kg q8h for 10 days for application on the sublingual mucosa [Bupaq Vet; Salfarm Scandinavia]) and meloxicam (0.05 mg/kg PO q24h [Metacam; Boehringer Ingelheim Animal Health]). At recheck 3 weeks later, the owner reported that the cat was still reluctant to jump, and that its fearful temperament was unchanged. Clinical examination revealed pain palpating the right hip and lumbar area. Histology from the bone biopsies was consistent with an ABC (Figure 2).

For surgical planning, CT (Revolution EV; GE Medical Systems) of the pelvis and lumbar spine, with and without contrast, was done. A lesion that consisted of an expansile monostotic soft tissue-attenuating process was visible in the cranial part of the right wing of the ilium from the cranial level of the right SI joint. The caudal transitional zone was short and the peripheral surrounding compact bone was thinner and missing in some aspects, indicating the destruction of bone. Several thin mineral density septa divided the cyst, and irregularly shaped formations of

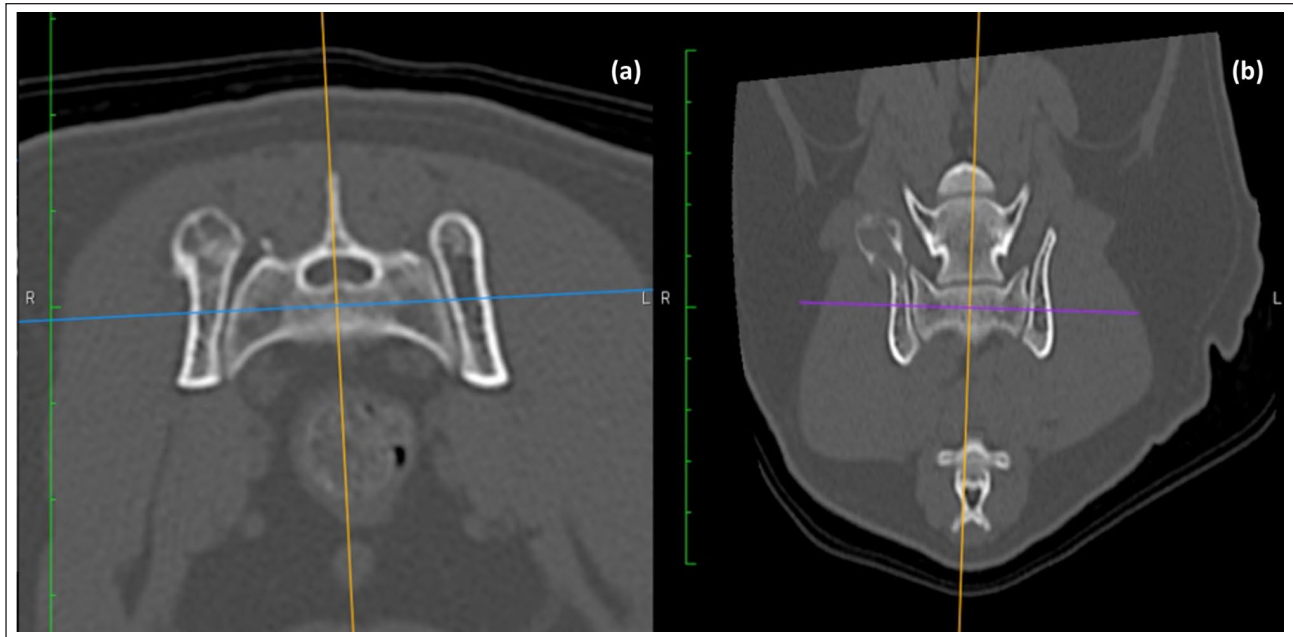


Figure 3 (a) Axial and (b) dorsal view of the pelvis showing an expansile monostotic soft tissue-attenuating process in the cranial part of the right ilium wing with several thin mineral density septa dividing the cyst

new bone were seen along the cranial margin of the lesion. The SI joints, as well as the other parts of the pelvis, were unremarkable. The lesion was mildly contrast attenuating, particularly in the periphery. The medial and internal iliac lymph nodes were within normal limits (Figure 3). With a histopathological diagnosis of an ABC and clear cyst margins in the right wing of the ilium on CT, the cat was scheduled for a partial ilectomy.

Under general anaesthesia, the cat was positioned in left lateral recumbency. With the right leg aseptically prepared and draped, a standard approach to the wing of the ilium was made.²² Elevation of the middle gluteal muscle from its origin on the cranioproximal ilium was made with sharp and blunt dissection. A Freer elevator was used to elevate the muscle from the thin bony wall of the cyst on the lateral side of the ilium to the point of the caudal dorsal iliac spine. Haemostasis of the iliolumbar artery and vein was achieved with bipolar cautery. Caudal landmarks indicating a completed dissection, included visualisation of the gluteal artery, nerve and vein caudoventral to the sacroiliac joint. The insertion of the iliacus muscle was elevated from the ventral border of the ilium before completely freeing the ABC by blunt dissection of the sacrospinal muscles on the medial side. Extra care was taken to stay close to the ilium and lateral to the intermediate crest of the sacrum, to avoid damaging the dorsal nerve roots exiting the dorsal foramina of the sacrum (Figure 4).

The hemipelvectomy cut in the ilium was made in a dorsoventral direction at the caudal border of the SI joint, premeasured on CT, using an oscillating saw (Colibri; DePuy Synthes) with a 10mm blade. During

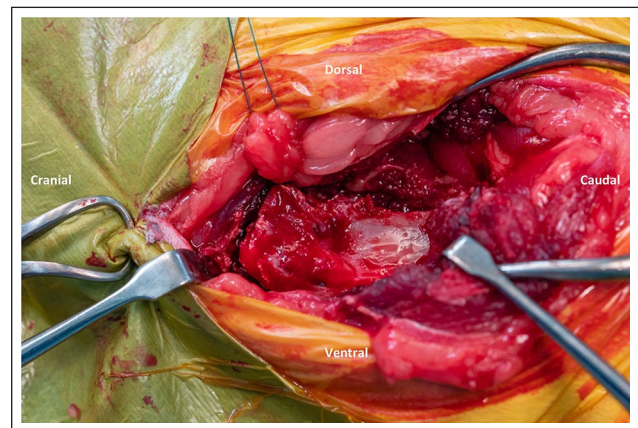


Figure 4 The middle gluteal muscle is elevated from its origin on the cranioproximal ilium. A Freer elevator was used to elevate the muscle from the thin bony wall of the cyst on the lateral side of the ilium to the point of the caudal dorsal iliac spine

the osteotomy, a malleable ribbon retractor was placed medial to the ilium to protect the sciatic nerve. Disarticulation of the SI joint was made from a dorsal approach with an osteotome and mallet, permitting removal of the osteotomized bone fragment containing the bone cyst (Figures 5 and 6). Remaining tendino-muscular attachments of the iliacus and medial gluteal muscle were sutured using simple horizontal mattress sutures to the fascia and periosteum of the remaining ilium with absorbable suture (3-0 polyglyconate). Closing of the remaining layers were routine.

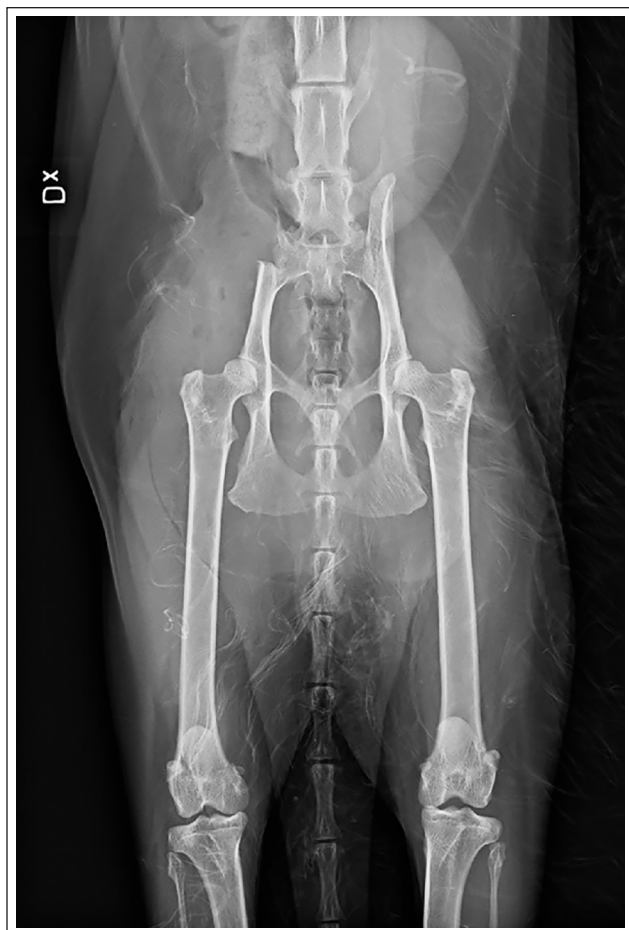

Figure 5 Postoperative ventrodorsal view of the pelvis. The osteotomy was made 5 mm cranial to the caudal border of the sacrum, at the caudal border of the sacroiliac joint, pre-measured on CT

Immediate postoperative analgesia was provided with methadone (0.3 mg/kg IM q12h [Semfortan Vet; Dechra Veterinary Products]). The day after the surgery the cat had an appetite, was urinating voluntarily and was ambulating. The cat was discharged from the hospital 1 day postoperatively, and analgesia provided by buprenorphine (0.001 mg/kg q8h for 10 days for application on the sublingual mucosa [Bupaq Vet; Salfarm Scandinavia]). Eight weeks of exercise restriction was also recommended, which consisted of the cat being kept indoors but otherwise moving freely.

Re-examination was carried out 8 weeks and 8 months postoperatively. At 8 weeks, there were no signs of fearful temperament or any pain when palpating the surgery site. The previously noted pain in the right hip, and the lumbar spine area had completely resolved. There was no visible lameness or gait abnormality, and the cat was considered to be clinically sound. At follow-up re-examination 8 months later, the cat was reported by the owner to be in good health, pain-free, social and interactive,

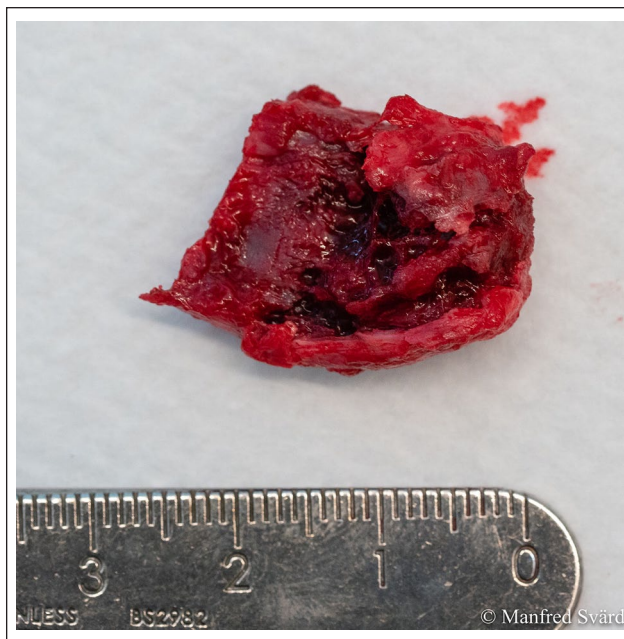

Figure 6 A 2.5 × 1.5 cm piece of the cranial part of the ilium wing was removed en bloc

and showed no signs of aggressive behaviour; the clinical examination was within normal limits.

Discussion

To our knowledge, this is the first report to describe total resection of an ABC in the pelvis of a cat with an excellent outcome. This treatment was different from the gold standard in people where intralesional curettage with or without bone grafting is the predominantly used therapy. However, curettage for ABCs carry a local recurrence rate of about 20%.^{8,9}

For evaluation of the cyst extent and surgical planning of hemipelvectomy, cross-sectional imaging is considered necessary, in both humans and cats.^{17,21,23} In this case, we performed a CT. In people, MRI is by some regarded as the examination of choice both to complement radiographs for diagnostics and for postoperative follow-up.^{10,12} Benamou et al¹ described a case report of an ABC in the scapula of a cat. An MRI of the lesion was performed, which was useful in characterising the structure of the mass and its relationship with surrounding tissues, as well as in planning for surgical resection.¹ In our cat, the lesion had a short transitional zone on CT, that is, the zone between affected and healthy bone was distinct and clear. This is typical for non-aggressive lesions, for example cysts, whereas a longer and not well marginated zone is more typical for aggressive lesions (eg, osteosarcoma and osteomyelitis). In this case, CT provided clear visible cyst margins in the ilium, and facilitated surgical planning. In

addition, biopsies are considered mandatory in people, as other bone cysts and neoplasms can demonstrate the same radiological, CT and MRI features as ABCs.²³ A preoperative diagnosis of ABC was obtained by incisional biopsies, although CT-guided fine-needle aspiration (FNA) or needle core biopsy could have been considered, as they are less invasive techniques. However, FNA is not recommended as a diagnostic tool for ABCs in human beings because of low specificity,²⁴ and little has been documented regarding the accuracy of needle core biopsy in diagnosing ABCs in both cats and people.²³

In people, the standard treatment for ABC consists of intralesional curettage and grafting. However, a variety of therapeutic methods have been described and optimal treatment for ABC is still being debated as local recurrence often occurs after curettage.^{8–10,17,18}

Although the reported recurrence rate after resection is low (0–5%), en bloc resection is usually not considered to be an option in most human cases because of anatomical location, the size of the lesion, and high morbidity and complication rates.^{9,10,17} Given the significant morbidity of en bloc resection, this procedure is mainly considered in cases of recurrent lesions refractory to less invasive treatment. In addition, excision is primarily considered for lesions in locations in which function is not compromised with such a resection.^{17,23} Curettage and grafting was considered a surgical option for the cat in our report. However, the anatomical location of the cyst and the reported potential risk of local recurrence led us to the decision to remove the cyst by partial ileiotomy. To our knowledge, this is the first report of a partial ileiotomy with limb preservation in a cat.

Earlier methods of sparing the ipsilateral limb have been described with a caudal hemipelvectomy or with a subtotal hemipelvectomy combined with a femoral head and neck ostectomy.^{25–27} According to the human Enneking classification, and in the veterinary literature modified by Bray,²⁸ hemipelvectomy can be either internal (ileiotomy) or external, depending on whether the pelvic limb is spared or not.¹⁹ Most cat owners and veterinary surgeons consider amputation of a pelvic limb to have an acceptable functional outcome,²⁹ and a study in 16 cats indicated that they tolerate hemipelvectomy equally well.³⁰ Nevertheless, hemipelvectomy with or without limb amputation can be a technical challenge and profound knowledge of anatomy is required. Fortunately, reports of major intraoperative complications such as bleeding and damage to the nerves, rectum and urethra are few.^{23,30} One of the modifications carried out by Bray²¹ entails muscles and related soft tissues transected at either their origin, insertion or removal in total without disruption, maintaining removal of one fascial plane around the tumour. This compartmental and anatomical dissection differs from

the traditional approach to hemipelvectomy used for veterinary surgical oncology, where wide resection is used and muscles are transected ideally ≥ 2 cm and one fascial plane away from the tumour.^{21,27} In this case, the origin of the muscles could be transected and dissection could stay marginal to the cyst, which left us with minimal dead space. Anatomical dissection may have contributed to the uneventful recovery of the cat in this report.

In a recent case report, an ileiotomy was described in a 10-year-old Rottweiler.³¹ The dog subsequently suffered a postoperative ischial fracture that led to transient pelvic limb lameness, but with severe permanent narrowing of the pelvic canal.³¹ However, in the canine case report,³¹ the ileiotomy included a considerably larger portion of the ilium and included elimination of the SI joint, destabilising the weightbearing axis of the ipsilateral pelvic limb. Conversely, in our case, the caudal portion of the SI joint remained intact and so the expected forces and outcome would be different, apart from our patient being considerably smaller. These two patients, and the surgical procedures/outcomes therefore cannot be directly compared. The result of a limb-sparing procedure associated with less extensive ileiotomy and in a smaller patient, as in our case, seems encouraging. Whether cats are at risk for ischial fractures after a larger ileiotomy than in our case needs to be further evaluated. In people, reconstruction of the pelvis is sometimes performed after ileiotomy.³² It remains unknown if body weight is a risk factor for fracture of the os ischii. If so, cats may be less susceptible and reconstruction not required. However, the potential need for pelvic reconstruction after ileiotomy in cats, is a topic for further studies.

In this case, radiographs of the pelvis were recommended at the 8-week postoperative re-examination. Such imaging could have shown complications such as ischial fracture with possible pelvic canal narrowing, but the owner declined. This is a limitation to the report and we suggest that radiographs should be included in a postoperative follow-up after ileiotomy.

Another limitation is the lack of postoperative follow-up for recurrence of the ABC with cross-sectional imaging. Hauschild et al¹⁰ found that most cases reoccurred within 2 years and proposed, irrespective of treatment, a follow-up regime including clinical survey and imaging. MRI was recommended at 3 months, 6 months and at half-yearly intervals within the first 2 years and thereafter annual MRI through the fifth postoperative year.¹⁰ In our cat we carried out a clinical examination 8 weeks and 8 months postoperatively, but we did not perform any imaging. The authors suggest that cross-sectional imaging, preferably by MRI, should be included in the postoperative follow-up after ABC treatment, similar to the recommendations in people. Whether the time interval recommended in humans can be directly applied to cats needs to be further evaluated.

Conclusions

Marginal resection of an ABC with anatomical dissection and partial iliectomy was well tolerated in this cat with a successful short-term outcome. Partial iliectomy can be considered for selected masses in the wing of the ilium when pelvic limb preservation is desired. CT proved itself as a valuable tool in surgical planning, but preoperative histopathology diagnosis from the incisional biopsy was mandatory.

Conflict of interest The authors declared no potential conflicts of interest with respect to the research, authorship, and/or publication of this article.

Funding The publication cost of this study was supported by an unrestricted gift from the Blue Star Small Animal Hospital Personnel Fund (grant number 7123).

Ethical approval This work involved the use of non-experimental animals only (including owned or unowned animals and data from prospective or retrospective studies). Established internationally recognised high standards ('best practice') of individual veterinary clinical patient care were followed. Ethical approval from a committee was therefore not necessarily required.

Informed consent Informed consent (either verbal or written) was obtained from the owner or legal custodian of all animal(s) described in this work (either experimental or non-experimental animals) for the procedure(s) undertaken (either prospective or retrospective studies). For any animals or humans individually identifiable within this publication, informed consent (either verbal or written) for their use in the publication was obtained from the people involved.

ORCID iD Kajsa Winbladh  <https://orcid.org/0000-0002-4691-8613>

References

- Benamou J, Lussier B, Alexander K, et al. **Use of magnetic resonance imaging and histopathologic findings for diagnosis of an aneurysmal bone cyst in the scapula of a cat.** *J Am Vet Med Assoc* 2012; 240: 69–74.
- Biller DS, Johnson GC, Birchard SJ, et al. **Aneurysmal bone cyst in a rib of a cat.** *J Am Vet Med Assoc* 1987; 190: 1193–1195.
- Saunders, et al. **Aneurysmal bone cyst in the pelvis of a cat.** *Vlaams Diergeneeskundig Tijdschrift* 2003; 73: 424–428.
- Barnhart MD. **Malignant transformation of an aneurysmal bone cyst in a dog.** *Vet Surg* 2002; 31: 519–524.
- Kyriakos M and Hardy D. **Malignant transformation of aneurysmal bone cyst, with an analysis of the literature.** *Cancer* 1991; 68: 1770–1780.
- Brindley GW, Greene JF and Frankel LS. **Case reports: malignant transformation of aneurysmal bone cysts.** *Clin Orthop Relat Res* 2005; 438: 282–287.
- Janevska V, Spasevska L, Samardziski M, et al. **From aneurysmal bone cyst to telangiectatic osteosarcoma with metastasis in inguinal lymph nodes – case report.** *Med Pregl* 2015; 68: 127–132.
- Mankin HJ, Hornicek FJ, Ortiz-Cruz E, et al. **Aneurysmal bone cyst: a review of 150 patients.** *J Clin Oncol* 2005; 23: 6756–6762.
- Grahneis F, Klein A, Baur-Melnyk A, et al. **Aneurysmal bone cyst: a review of 65 patients.** *J Bone Oncol* 2019; 18: 100255. DOI: 10.1016/j.jbo.2019.100255.
- Hauschild O, Lüdemann M, Engelhardt M, et al. **Aneurysmal bone cyst (ABC): treatment options and proposal of a follow-up regime.** *Acta Orthop Belg* 2016; 82: 474–483.
- Sarierler M, Cullu E, Yurekli Y, et al. **Bone cement treatment for aneurysmal bone cyst in a dog.** *J Vet Med Sci* 2004; 66: 1137–1142.
- Mascard E, Gomez-Bouchet A and Lambot K. **Bone cysts: unicameral and aneurysmal bone cyst.** *Orthop Traumatol Surg Res* 2015; 101: S119–S127.
- Mangham DC. **World Health Organisation classification of tumours: pathology and genetics of tumours of soft tissue and bone.** *J Bone Joint Surg* 2004; 86-B: 466.
- Oliveira AM and Chou MM. **USP6-induced neoplasms: the biologic spectrum of aneurysmal bone cyst and nodular fasciitis.** *Hum Pathol* 2014; 45: 1–11.
- Ye Y, Pringle LM, Lau AW, et al. **TRE17/USP6 oncogene translocated in aneurysmal bone cyst induces matrix metalloproteinase production via activation of NF-κB.** *Oncogene* 2010; 29: 3619–3629.
- Mahnken AH, Nolte-Ernsting CCA, Wildberger JE, et al. **Aneurysmal bone cyst: value of MR imaging and conventional radiography.** *Eur Radiol* 2003; 13: 1118–1124.
- Flont P, Kolacinska-Flont M and Niedzielski K. **A comparison of cyst wall curettage and en bloc excision in the treatment of aneurysmal bone cysts.** *World J Surg Oncol* 2013; 11: 109. DOI: 10.1186/1477-7819-11-109.
- Tsagozis P and Brosjö O. **Current strategies for the treatment of aneurysmal bone cysts.** *Orthop Rev* 2015; 7: 6182. DOI: 10.4081/or.2015.6182.
- Wang EHM, Marfori ML, Serrano MVT, et al. **Is curettage and high-speed burring sufficient treatment for aneurysmal bone cysts?** *Clin Orthop Relat Res* 2014; 472: 3483–3488.
- Brosjö O, Pechon P, Hesla A, et al. **Sclerotherapy with polidocanol for treatment of aneurysmal bone cysts.** *Acta Orthop* 2013; 84: 502–505.
- Bray JP. **Hemipelvectomy: modified surgical technique and clinical experiences from a retrospective study.** *Vet Surg* 2014; 43: 19–26.
- Johnson KA. **Piermattei's atlas of surgical approaches to the bones and joints of the dog and cat.** 5th ed. St Louis, MO: Elsevier Health Sciences, 2014.
- Park HY, Yang SK, Sheppard WL, et al. **Current management of aneurysmal bone cysts.** *Curr Rev Musculoskelet Med* 2016; 9: 435–444.
- Creager AJ, Madden CR, Bergman S, et al. **Aneurysmal bone cyst: fine-needle aspiration findings in 23 patients with clinical and radiologic correlation.** *Am J Clin Pathol* 2007; 128: 740–745.
- Barbur LA, Coleman KD, Schmiedt CW, et al. **Description of the anatomy, surgical technique, and outcome of hemipelvectomy in 4 dogs and 5 cats.** *Vet Surg* 2015; 44: 613–626.

- 26 DeGroot W, Gibson TWG, Reynolds D, et al. **Internal hemipelvectomy for treatment of obstipation secondary to pelvic malunion in 3 cats.** *Can Vet J* 2016; 57: 955–960.
- 27 Kramer A, Walsh PJ and Seguin B. **Hemipelvectomy in dogs and cats: technique overview, variations, and description.** *Vet Surg* 2008; 37: 413–419.
- 28 Bray JP. **Hemipelvectomy: modified surgical technique and clinical experiences from a retrospective study.** *Vet Surg* 2014; 43: 19–26.
- 29 Withrow SJ and Hirsch VM. **Owner response to amputation of a pet's leg.** *Vet Med Small Anim Clin* 1979; 74: 332–334.
- 30 Bray JP, Worley DR, Henderson RA, et al. **Hemipelvectomy: outcome in 84 dogs and 16 cats. A veterinary society of surgical oncology retrospective study.** *Vet Surg* 2014; 43: 27–37.
- 31 Oramas A, Boston SE and Skinner OT. **Iliectomy with limb preservation for a dog with ilial osteosarcoma: surgical description and case report.** *Vet Surg* 2020; 49: 607–613.
- 32 Traub F, Andreou D, Niethard M, et al. **Biological reconstruction following the resection of malignant bone tumors of the pelvis.** *Sarcoma* 2013; 2013: 745360. DOI: 10.1155/2013/745360.