

A case of behavioral changes in a castrated male cat due to a functional adrenocortical adenoma producing testosterone and androstenedione

Authors: Reche Junior, Archivaldo, Ramos, Daniela, Ferreira, Mariana, Da Silva, Luís Artur GP, Hirai, Yumi, et al.

Source: Journal of Feline Medicine and Surgery Open Reports, 7(1)

Published By: SAGE Publishing

URL: <https://doi.org/10.1177/2055116920981247>

BioOne Complete (complete.BioOne.org) is a full-text database of 200 subscribed and open-access titles in the biological, ecological, and environmental sciences published by nonprofit societies, associations, museums, institutions, and presses.

Your use of this PDF, the BioOne Complete website, and all posted and associated content indicates your acceptance of BioOne's Terms of Use, available at www.bioone.org/terms-of-use.

Usage of BioOne Complete content is strictly limited to personal, educational, and non - commercial use. Commercial inquiries or rights and permissions requests should be directed to the individual publisher as copyright holder.

BioOne sees sustainable scholarly publishing as an inherently collaborative enterprise connecting authors, nonprofit publishers, academic institutions, research libraries, and research funders in the common goal of maximizing access to critical research.



A case of behavioral changes in a castrated male cat due to a functional adrenocortical adenoma producing testosterone and androstenedione

Journal of Feline Medicine and Surgery Open Reports
1–8

© The Author(s) 2021

Article reuse guidelines:

sagepub.com/journals-permissions

DOI: 10.1177/2055116920981247

journals.sagepub.com/home/jfmsopenreports

This paper was handled and processed by the American Editorial Office (AAFP) for publication in *JFMS Open Reports*



Archivaldo Reche Junior^{1,2}, Daniela Ramos³ ,
Mariana Ferreira² , Luís Artur GP da Silva⁴,
Yumi Hirai² and Pedro V Horta²

Abstract

Case summary This case report describes a 9-year-old neutered male cat with a functional adrenal tumor showing aggression toward other cats in the household, excessive meowing and urine spraying. The diagnosis was made based on the clinical signs, an enlarged right adrenal gland on ultrasound, penile spines and elevated sex hormones on an adrenocorticotrophic hormone stimulation test. The cat was submitted to celiotomy and adrenalectomy. Histopathological examination confirmed the adrenocortical adenoma. Three months after surgery the penile spines disappeared and urine spraying, as well as excessive meowing, had greatly decreased; however, aggressive behavior took much longer to stop and required behavior therapy.

Relevance and novel information Functional adrenal tumors producing only sex hormones and behavioral changes are uncommon. The cat reported herein started showing behavioral changes before spines appeared on the penis, and structural alterations in the adrenal gland at the abdominal ultrasonography were detected. Considering all the possible implications resulting from severe behavior problems such as cat–cat aggression, from a permanent separation of the cats to relinquishment, a detailed investigation of underlying medical mechanisms in these animals is crucial from the start. Examinations may need to be repeated later in the course.

Keywords: Adrenal tumor; behavioral changes; aggression; sex hormones; testosterone

Accepted: 24 November 2020

Introduction

Hyperadrenocorticism (HAC), hypoadrenocorticism, functional adrenal tumors secreting catecholamine and/or sex hormones and/or aldosterone are some of the adrenal diseases reported in cats. HAC (Cushing syndrome), the most common of the adrenal disorders in cats, can occur because of excessive function of either the pituitary or adrenal glands. Less frequently, HAC in cats can be secondary or iatrogenic due to the use of synthetic glucocorticoids. There is no sex predilection and most cats with HAC are middle-aged to older. The most common clinical signs observed in cats with HAC are polyuria, polydipsia, polyphagia, pendulous abdomen and skin fragility. Some cats with HAC also have concomitant diabetes mellitus.^{1–3}

Adrenal neoplasia is rare in cats, accounting for 0.2% of all feline tumors.⁴ Hyperaldosteronism is the most frequent clinical syndrome observed in cats with adrenal tumors.^{5,6}

¹Department of Internal Medicine, University of São Paulo, São Paulo, Brazil

²Vetmasters and 4 Cats Hospital, São Paulo, Brazil

³Psicovet, São Paulo, Brazil

⁴Tatuapet Veterinary Clinic, São Paulo, Brazil

Corresponding author:

Archivaldo Reche Junior DVM, MSc, PhD, Department of Internal Medicine, School of Veterinary Medicine, University of São Paulo, 4 Cats Hospital and Vetmasters, Avenida Pacaembu, 1166, SP 01234-000, Brazil

Email: valdorec@usp.br



Creative Commons Non Commercial CC BY-NC: This article is distributed under the terms of the Creative Commons

Attribution-NonCommercial 4.0 License (<https://creativecommons.org/licenses/by-nc/4.0/>) which permits non-commercial use, reproduction and distribution of the work without further permission provided the original work is attributed as specified on the SAGE and Open Access pages (<https://us.sagepub.com/en-us/nam/open-access-at-sage>).

In a retrospective study where 33 cats with adrenal tumors were evaluated, 30 cats were diagnosed with adrenocortical tumors. The most frequent clinical sign in these cats was weakness. At least one endocrine testing was performed in 25/33 cats. The results showed that 19/25 of the cats had a functional tumor. The diagnosis included hyperaldosteronism ($n = 16$), hypercortisolism ($n = 1$), high estradiol concentration ($n = 1$) and hypersecretion of more than one hormone (aldosterone, estradiol and progesterone; $n = 1$).⁷

Cases of adrenal tumors in cats secreting sex hormones have been published since 1999 and in most of these cases, the tumors were secreting more than one adrenal hormone.^{8–11}

Functional adrenal tumors secreting only sex hormones are even more uncommon in cats, with only six cases reported so far. Two of these cats had tumors producing sole testosterone, three cats had tumors producing only estradiol and one cat developed an adrenal tumor, which produced androstenedione and testosterone. All the six cats had behavioral problems as the major complaint (urine spraying, aggression and mounting).^{9,10,12,13}

Inter-cat aggression and inappropriate urination are the two most frequent feline behavior problems seen by veterinary behaviorists worldwide and are common reasons for relinquishment of cats to rehoming centers.^{14–20} Aggression and inappropriate urination can also be manifestations of medical problems. For instance, aggression can be a manifestation of pain,²¹ and urine spraying is observed in cats with lower urinary tract diseases.^{22–24} However, previous papers have claimed that spraying is less likely to be linked to a medical condition.²⁵ Before establishing a sole behavior diagnosis, is always recommended to exclude medical causes of aggression and/or urine spraying. For this, a complete history and a physical examination are necessary. Screening tests include a complete blood count (CBC), urinalysis, biochemistry profile, imaging (ultrasound and/or radiography) and others, depending on each case. Moreover, before beginning the behavioral investigation, one must determine if the cat is castrated or has a retained testicle or ovarian remnant.²⁶

Case description

A 9-year-old neutered male domestic shorthair cat weighing 5.4 kg was evaluated for a major complaint of a 3-month history of urine spraying, excessive meowing and aggression toward other cats in the household. The cat had always lived in the same multi-cat group but had never shown any behavioral problems before. Conflicts with the other cats were so intense that the owners had to separate several fights, and had suffered severe bites as redirected aggression by the cat. At the time of the consultation the owners were keeping the cat separated from the rest of the group. Vocalization was also very

intense, mainly during the night, such that the owners had been unable to sleep; urine marks were deposited everywhere in the household.

The cat had been taken to a general practice 2 months previously, when the behavioral signs increased. The veterinarian detected pain in the sacral vertebrae during physical examination. A presumptive diagnosis of degenerative joint disease was made, and the cat was treated with meloxicam (0.02 mg/kg q24h for 10 days) without any improvement. A neurologist was then consulted, followed by a veterinary behaviorist who considered the behavior manifestations inconsistent with a sole behavioral problem, and then referred the case to a specialized clinic.

At the first consultation with the feline specialist, after a complete history was taken, the owner emphasized the cat 'was showing an intact male behavior' and aggression was her major concern. The cat was alert, difficult to manage and showing signs of aggression when restrained. The physical examination was suspended and rescheduled for the next day. The owner was instructed to premedicate the cat at home with gabapentin (100 mg per cat PO) 2 h before arrival. At the physical examination spines were not detected on the cat's penis and an abdominal ultrasound did not show any alteration. As the behavioral problems persisted, a second appointment was scheduled for 2 months later. At that time spines were noted on examination of the penis (Figure 1). A second abdominal ultrasound was then performed, which showed an enlarged right adrenal gland (1.11×0.42 cm) and a hyperechoic nodule in the cranial pole (Figure 2); the left adrenal gland was within the reference interval (RI) for cats (0.86×0.33 cm). A CT scan was performed 3 days after the second appointment, and the right adrenal nodule was confirmed.

The following tests were also performed: CBC, biochemistry profile, urinalysis, total thyroxine (T4)/thyroid-stimulating hormone (TSH) and adrenal panel (University of Tennessee Veterinary Medical Center Diagnostic Laboratory Services, Knoxville, TN, USA). Hormones assessed with an adrenal panel included pre- and post-adrenocorticotrophic hormone (ACTH; 60 mins after synthetic ACTH administration) concentrations of cortisol, androstenedione, estradiol, progesterone, 17-OH progesterone, aldosterone and testosterone. A low-dose dexamethasone suppression test was also performed to rule out hyperadrenocorticism. No alterations were observed in the CBC, biochemistry profile, urinalysis, total T4, TSH and low-dose dexamethasone suppression tests. Results of the adrenal panel revealed a high baseline serum concentration of androstenedione (1.63 ng/ml RI 0.1–0.6 ng/ml), and remained elevated after ACTH administration (3.88 ng/ml; RI 0.5–2.8 ng/ml). Baseline testosterone concentration was high (2.58 ng/ml; expected <0.4 ng/ml) and remained elevated after ACTH administration (3.82 ng/ml; expected

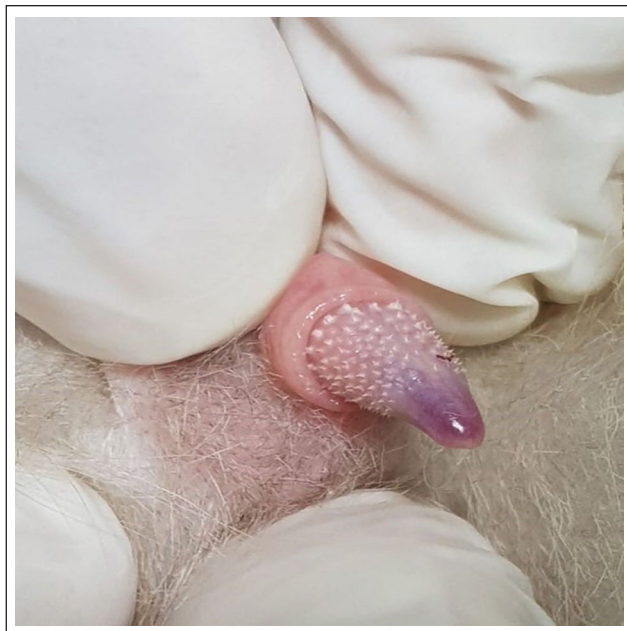


Figure 1 Penile spines before adrenalectomy

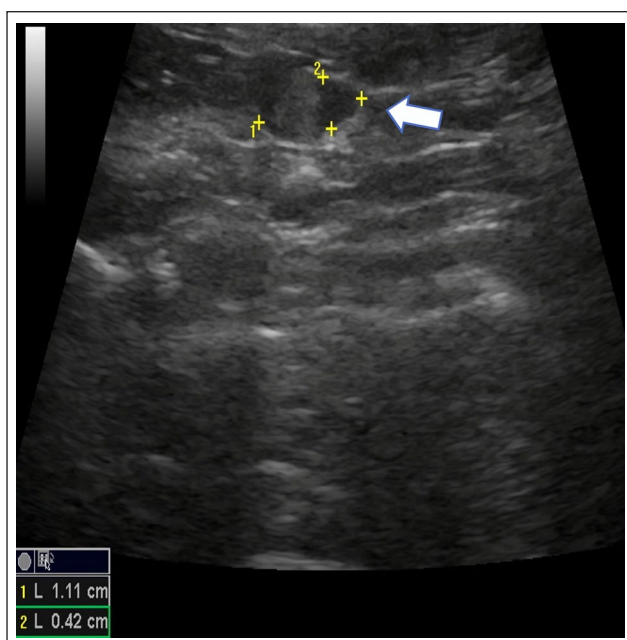


Figure 2 Ultrasound image of a right adrenal gland with a hyperechoic nodule in the cranial pole (arrow). Margins of the nodule are demarcated by plus signs (one longitudinal and two transversal measurements = 1.11 × 0.42 cm)

<0.4ng/ml). Baseline and after ACTH administration concentrations of the other hormones (cortisol, estradiol, progesterone, 17-OH progesterone and aldosterone) were within the RIs (Table 1).

Results of the low-dose dexamethasone suppression test revealed a baseline serum cortisol level (1.1 µg/dl; RI 0.8–3.7 µg/dl) within the RIs, and concentrations remained normal after dexamethasone administration (0.3 µg/dl; expected <0.8 µg/dl).

A presumptive diagnosis of sex hormone-secreting adrenal tumor was made.

The owner was informed of the diagnosis and that an adrenalectomy was indicated to treat the aberrant sex hormone production. Seeking a solution for the behavioral problem and expecting to stop the fights among the cats, the owner accepted the adrenalectomy.

Abdominal exploratory surgery was undertaken to remove the right adrenal gland. After a midline celiotomy was performed, the right adrenal gland was dissected carefully from the caudal vena cava and completely removed from its anatomic location (Figures 3 and 4). To avoid possible cortisol deficiency, dexamethasone (0.2 mg/kg IV) was administered prior to manipulation of the right adrenal gland. The abdominal wall was closed and after recovering from anesthesia the patient was sent to an intensive care unit for pain control. Electrolytes, blood pressure, temperature and signs of abdominal hemorrhage were also monitored during hospitalization. Seventy-two hours after surgery, another ACTH test was performed to evaluate the cortisol levels. Results revealed baseline serum concentration of cortisol (1.4 µg/dl; RI 0.8–3.7 µg/dl) within the normal RI and remained normal after ACTH administration (7.3 µg/dl; RI 4–14.5 µg/dl). Histopathologic analysis of the right adrenal confirmed the diagnosis of adrenocortical adenoma.

Ten days after surgery, the cat was fully recovered, but the owner had not noticed any changes in its behavior. She was informed that despite the surgery the problematic behavior could take longer to improve.

Another adrenal panel was performed 3 months post-operatively and the results showed a significant reduction in the previously elevated sex hormones (androstenedione and testosterone). The baseline serum concentration of androstenedione (0.23 ng/ml; RI 0.1–0.6 ng/ml) was normal and remained normal after ACTH administration (1.09 ng/ml; RI 0.5–2.8 ng/ml). The baseline serum concentration of testosterone (0.04 ng/ml; expected <0.4 ng/ml) was normal and remained normal after ACTH administration (0.05 ng/ml; expected <0.4 ng/ml) (Table 2). At this time, the penile spines were not observed (Figure 5).

At this point, the owners reported that the cat had greatly decreased urine spraying and excessive meowing, but its aggressive behavior persisted. On a couple of occasions, they allowed the cat to interact with the other cats in the household, but this did not last more than a few minutes as the cat rushed toward the others to fight. Furthermore, severe attacks from one particular cat in

Table 1 Results of the measurement of adrenal hormone concentrations before (T0) and 60 mins (T60) after administration of synthetic adrenocorticotrophic hormone (ACTH)

Test	Result (baseline)	RI	Result (post-ACTH)	RI
Hormone	T0		T60	
Cortisol ($\mu\text{g/dl}$)	0.95	0.8–3.7	7.3	4–14.5
Androstenedione (ng/ml)	1.63	0.1–0.6	3.88	0.5–2.8
Estradiol (pg/ml)	48.2	39.1–89.3	56.5	38.3–84
Progesterone (ng/ml)	0.1	<0.7	1.67	0.7–4.6
17-OH progesterone (ng/ml)	0.09	0.08–0.3	0.69	0.2–1.6
Aldosterone (pg/ml)	21.8	3.3–261.3	143.5	38.8–474.5
Testosterone (ng/ml)	2.58	<0.4	3.82	<0.4

Results obtained before adrenalectomy

RI = reference interval

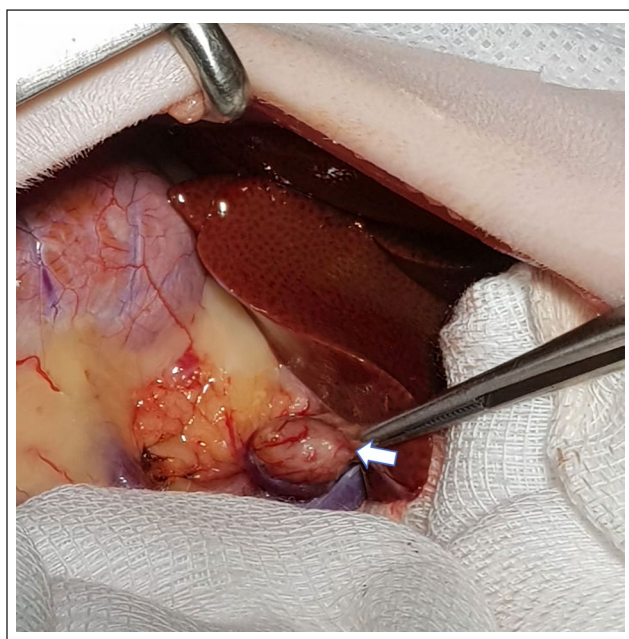


Figure 3 Enlarged right adrenal (arrow) during laparotomy

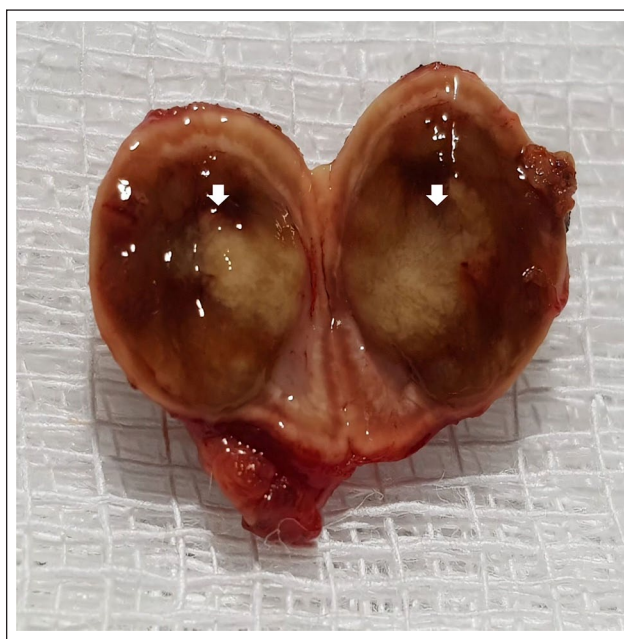

Figure 4 Sagittal section of the right adrenal gland with the nodule in the cranial pole (arrows)

the group occurred. Permanent separation was recommended, and the case was referred to the veterinary behaviorist who had seen the cat prior to surgery.

Behavior therapy was carried out, including the use of an antidepressant agent (fluoxetine 1 mg/kg q24h) for the patient and for the other cat that was attacking it. The aim was to add impulse control for both cats in order to make behavior modification possible. There was an environmental management plan according to which the cat continued to be separated from the group the whole time except for the behavior modification sessions, which were performed several days a week. These consisted of successive approximations between the cat and the others, using exclusive toys and treats as positive reinforcers. Sessions progressed through three phases – visual contact, physical contact, together for

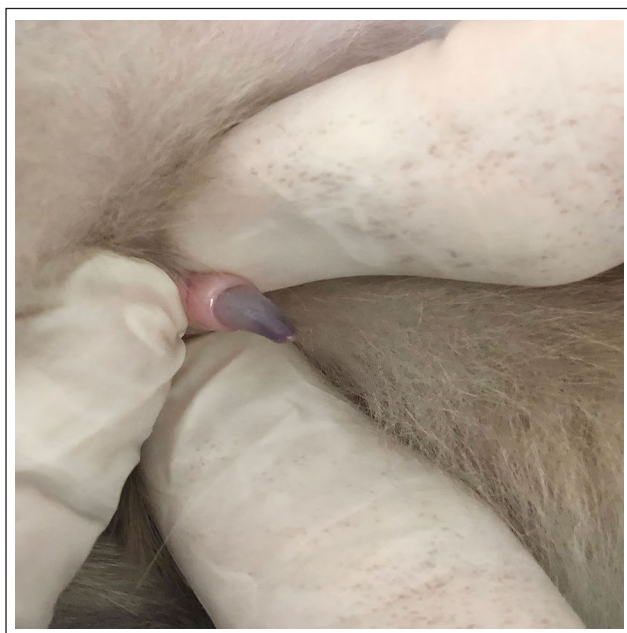long periods – according to the protocol proposed by Ramos.¹⁶ Sessions took about 15–20 mins and were conducted in the TV room and balcony as there was a glass door dividing the two areas that served as a barrier for the visual contact phase. During this phase toys were scattered on both sides and owner stayed for a time on one side playing with the patient while the others played on their own on the other side of the door; the owner then swapped to the other side and repeated the same process. Sessions ended with the offer of a delicious treat to all cats in the two areas. The two cats were then habituated to wear a harness and leash in order to add safety for the physical contact phase during which they started to get close to each other. Praise, as well as treats or play, were provided by the owner whenever

Table 2 Results of the measurement of adrenal hormone concentrations before (T0) and 60 mins (T60) after administration of a synthetic adrenocorticotrophic hormone (ACTH).

Test	Result (baseline)	RI	Result (post-ACTH)	RI
Hormone	T0		T60	
Cortisol (µg/dl)	3.61	0.8–3.7	6.7	4–14.5
Androstenedione (ng/ml)	0.23	0.1–0.6	1.09	0.5–2.8
Estradiol (pg/ml)	49	39.1–89.3	57.1	38.3–84
Progesterone (ng/ml)	0.22	<0.7	1.19	0.7–4.6
17-OH progesterone (ng/ml)	0.08	0.08–0.3	0.39	0.2–1.6
Aldosterone (pg/ml)	26.3	3.3–261.3	103.5	38.8–474.5
Testosterone (ng/ml)	0.04	<0.4	0.05	<0.4

Results obtained 3 months post-adrenalectomy

RI = reference interval

**Figure 5** Penis without spines, 3 months after adrenalectomy

they got close and showed no aggression. When any aggressive behavior occurred, the owner blocked the interaction by placing a cushion between the two or distracting one of them with play while placing the other further apart. This way fights were always prevented. Reprimands or any other form of positive punishment were never used. In the final phase, after playing and eating closely as in the previous phase, the owner extended the session by keeping the cats in the same area while only monitoring them. A leash and harness were no longer used, and session by session this time together was increased until the cats could stay together in the same room for long periods. A Feliway Friends diffuser was used during most of the behavior therapy.

From the start of the behavior therapy, the owner was scared of fights and being injured, and thus progression

of the behavior sessions was very slow. She went back and forth, struggling to perform the sessions, having to overcome her fears, and not believing the cats would end up living together again. She even considered relinquishing the cat but eventually abandoned the idea. During these difficult times, she decreased or even stopped practicing the behavior sessions. Two years after surgery the cat group was living together peacefully again. The behaviorist helped the owner for the entire time until both cats were weaned off the medication. The cats are now living in the same house and even showing occasional affiliative behaviors such as sleeping close together and displaying no signs of cat-cat aggression.

Discussion

The diagnosis of an adrenal tumor producing sexual hormones is based on a history of behavioral changes and detection of penile spines in a neutered male with no other remarkable findings. This is the second published case of a cat with an adrenal gland tumor producing androstenedione and testosterone. The patient reported here showed several behavioral changes, including urine spraying, excessive meowing and aggression toward other cats. It was only after 5 months of showing such behavior that spines were seen in the cat's penis and an enlarged adrenal was seen during a second abdominal ultrasound. Clearly, behavior changes can appear much earlier than physical signs. Therefore, medical causes should be always considered in any behavior case, even when there is a sole behavior complaint. It may be that the physical signs are subtle or, as in this case, they have not yet appeared. When the behavior problem is not manifested in its usual forms as it was perceived by the veterinary behaviorist in this case, it is worth repeating medical examinations.

Together with other clinical findings and alterations in the adrenal panel, a presumptive diagnosis of adrenal tumor producing sex hormones was made. Physical and behavioral changes can be the only clinical manifestations

in cats with functional adrenal tumors producing sex hormones. This is a rare condition, with only six cases reported in the literature. The differential diagnosis for cats showing signs of aggression toward owners and other cats, urine spraying, mounting, rolling on the ground, pacing and weight loss include adrenal tumors producing sexual hormones, retained gonadal tissue, administration of exogenous sources of hormones or hyperthyroidism.^{9,10,12,13} At the two abdominal ultrasound examinations performed in the patient here, an ectopic testicle was not detected. Anti-Müllerian hormone could also be used to exclude retained gonadal tissue as this assay is 100% sensitive and specific for cats. Even though this test was not performed in the patient, an ectopic testicle had been considered unlikely from the start as the cat was castrated at a very young age and had not demonstrated any behavior signs of an intact male since castration. Exogenous hormones had never been administered to the cat and the normal total T4 and TSH levels ruled out hyperthyroidism.

Ultrasonography has been used as a diagnostic tool for adrenal tumors in dogs and cats; however, as seen in the cat reported herein, depending on the magnitude of the adrenal mass it may pass undetected on ultrasound. The abdominal CT scan is indicated to evaluate whether there is invasion of the caudal vena cava, which is an important prognostic factor.^{27–29}

Adrenalectomy, done by laparotomy or laparoscopy, is the treatment of choice in cats with adrenal gland tumors. There is no study comparing both procedures in cats, but when survival rates are used to evaluate the outcomes, cats submitted to laparoscopy have a higher survival rate than those submitted to laparotomy. Nevertheless, if intravascular invasion is suspected, a laparoscopy is contraindicated.^{7,30,31} The patient reported here had no signs of caudal vena cava invasion at CT scan, and thus should have been a candidate for laparoscopy. However, the surgeon decided for laparotomy as he was more familiar with this technique. Moreover, the patient was in an excellent clinical condition, with a low risk of post-laparotomy complications.

The survival rates of cats that undergo adrenalectomy is variable. Some patients died in shortly after surgery, while others lived longer.^{7,13,32,33} There are certainly many variants that can interfere in the prognosis of these cats, including clinical condition at the time of surgery, comorbidities, hemorrhage and metabolic complications.³⁴ Prognosis did not change by histopathologic classification of adrenocortical tumor in the study where 33 cats with adrenal tumors were evaluated.⁷ The patient reported here was still alive 3 years after surgery.

The baseline serum concentrations of androstenedione and testosterone of the cat reported here had decreased to within the respective RIs 3 months after surgery. Of note, the levels of these hormones should

have decreased much sooner. In a previous published case of a cat with an adrenal tumor producing androstenedione and testosterone, the authors observed a decrease in hormone levels 2 weeks after surgery.⁹

The testosterone-driven behavior of an intact male observed in the cat reported here was probably due to excessive testosterone production and secretion by the adrenal tumor or to the conversion of the androstenedione to testosterone in peripheral tissues.⁹ High levels of androstenedione and testosterone were, indeed, detected at the adrenal panel performed in the patient. Aggression – to the point of the owner considering relinquishing the cat – was the most prominent clinical sign observed in the cat presented here.

Aggression between cats is the number one feline behavior problem seen by behaviorists in Brazil, with treatment being a real challenge for most owners.^{16–18} The more severe the conflicts the worse the deterioration of the cat–cat relationships and the poorer the prognosis.³⁵ Correction of the medical condition does not always fix the behavior problem either immediately or in the long term as while the disease causes the behavior several other factors sustain it, such as learning processes. This being said, in cases where a medical component is detected, the patient's behavior should be closely monitored, and behavior therapy considered whenever the problem persists.

Whereas urine spraying and meowing involved only the cat manifesting the behavior, cat–cat aggression is manifested by two or more individuals. Surgery decreased hormones as triggers for the attacks by the patient, but the behavior from the others involved in the fights were likely the same after surgery of the patient. In other words, cats that were recipients of the aggressive behavior of the patient exhibited behavior changes (ie, aggression) themselves thus contributing to sustaining the problem after the surgery. Additional behavior therapy for the other cats was therefore required. Indeed, urine spraying and meowing stopped soon after surgery, but restoring the cat's harmony in the household took nearly 2 years and depended upon a behavior modification plan and psychoactive agents. Inter-cat aggression, even when there is a medical cause, must be addressed and treated.

Conclusions

Considering all the possible implications resulting from a household with cats showing severe behavior problems such as cat–cat aggression, from a permanent separation of the cats to relinquishment, a detailed investigation of underlying medical mechanisms is crucial from the start and examinations may need to be repeated later in the course. Owners also need to be clearly advised that even when a medical problem is detected, treatment does not necessarily mean behavior signs will soon disappear.

Acknowledgements The authors acknowledge Dr Márcia Jericó and Dr Denise Simões for their contribution to this work.


Conflict of interest The authors declared no potential conflicts of interest with respect to the research, authorship, and/or publication of this article.

Funding The authors received no financial support for the research, authorship, and/or publication of this article.

Ethical approval This work involved the use of non-experimental animals only (including owned or unowned animals and data from prospective or retrospective studies). Established internationally recognized high standards ('best practice') of individual veterinary clinical patient care were followed. Ethical approval from a committee was therefore not necessarily required.

Informed consent Informed consent (either verbal or written) was obtained from the owner or legal custodian of all animal(s) described in this work (either experimental or non-experimental animals) for the procedure(s) undertaken (either prospective or retrospective studies). For any animals or humans individually identifiable within this publication, informed consent (either verbal or written) for their use in the publication was obtained from the people involved.

ORCID IDs Daniela Ramos  <https://orcid.org/0000-0002-2564-9055>

Mariana Ferreira  <https://orcid.org/0000-0003-3003-2970>

References

- Duesberg C and Peterson ME. **Adrenal disorders in cats.** *Vet Clin North Am Small Anim Pract* 1997; 27: 321–347.
- Hoenig M. **Feline hyperadrenocorticism – where are we now?** *J Feline Med Surg* 2002; 4: 171–174.
- Peterson ME and Baral RM. **Adrenal gland disorders.** In: Little SE (ed). *The cat: clinical medicine and management.* St Louis, MO: Saunders Elsevier, 2012, pp 592–610.
- Lunn KF and Page RL. **Tumors of the endocrine system.** In: Withrow SJ and Vail DM (eds). *Withrow and McEwen's small animal clinical oncology.* 5th ed. St Louis, MO: Saunders Elsevier, 2013, pp 504–531.
- Djajadiningrat-Laanen S, Galac S and Kooistra H. **Primary hyperaldosteronism: expanding the diagnostic net.** *J Feline Med Surg* 2011; 13: 641–650.
- Ash RA, Harvey AM and Tasker S. **Primary hyperaldosteronism in the cat: a series of 13 cases.** *J Feline Med Surg* 2005; 7: 173–182.
- Daniel G, Mahony OW, Markovich JE, et al. **Clinical findings, diagnostics and outcome in 33 cats with adrenal neoplasia (2002–2013).** *J Feline Med Surg* 2016; 18: 77–84.
- Boord M and Griffin C. **Progesterone secreting adrenal mass in a cat with clinical signs of hyperadrenocorticism.** *J Am Vet Med Assoc* 1999; 214: 666–669.
- Millard RP, Pickens EH and Wells KL. **Excessive production of sex hormones in a cat with an adrenocortical tumor.** *J Am Vet Med Assoc* 2009; 15: 505–508.
- Meler EN, Scott-Moncrieff JC, Peter AT, et al. **Cyclic estrous-like behavior in a spayed cat associated with excessive sex-hormone production by an adrenocortical carcinoma.** *J Feline Med Surg* 2011; 13: 473–478.
- Boag AK, Neiger R and Church DB. **Trilostane treatment of bilateral adrenal enlargement and excessive sex steroid hormone production in a cat.** *J Small Anim Pract* 2004; 45: 263–266.
- Nadolski AC, Markovich JE, Jennings SH, et al. **Mammary development, hyperestrogenemia, and hypocortisolemia in a male cat with an adrenal cortical carcinoma.** *Can Vet J* 2016; 57: 1077–1080.
- Sumner JP, Hulsebosch SE, Dudley RM, et al. **Sex-hormone producing adrenal tumors causing behavioral changes as the sole clinical sign in 3 cats.** *Can Vet J* 2019; 60: 305–310.
- Amat M and Manteca X. **Common feline behaviours: owner-directed aggression.** *J Feline Med Surg* 2019; 21: 245–255.
- Denenberg S, Landsberg GM, Horwitz D, et al. **A comparison of cases referred to behaviorists in three different countries.** In: Mills D, Levine E, Landsberg G et al (eds). *Current issues and research in veterinary behavioral medicine. Papers presented at the Fifth International Veterinary Behavior Meeting.* West Lafayette, IN: Purdue University Press, 2005, pp 56–62.
- Ramos D. **Common feline problem behaviors – aggression in multi-cat households.** *J Feline Med Surg* 2019; 21: 221–233.
- Ramos D and Mills DS. **Human directed aggression in Brazilian domestic cats: owner reported prevalence, contexts and risk factors.** *J Feline Med Surg* 2009; 11: 835–841.
- Ramos D, Reche-Junior A, Hirai Y, et al. **Feline behaviour problems in Brazil: a review of 155 referral cases.** *Vet Rec* 2020; 186. DOI: 10.1136/vr.105462.
- Amat M, Manteca X, Le Brech S, et al. **Evaluation of inciting causes, alternative targets, and risk factors associated with redirected aggression in cats.** *J Am Vet Med Assoc* 2008; 233: 586–589.
- Salman MD, New JG, Jr, Scarlett JM, et al. **Human and animal factors related to relinquishment of dog and cats in 12 selected animal shelters in the United States.** *J Appl Anim Welf Sci* 1998; 1: 207–226.
- Mills DS, Demontigny-Bédard I, Gruen M, et al. **Pain and problem behavior in cats and dogs.** *Animals* 2020; 10: 318: 1–20.
- Ramos D, Reche-Junior A, Mills DS, et al. **A closer look at the health of cats showing urinary house-soiling (periuria): a case-control study.** *J Feline Med Surg* 2019; 21: 772–779.
- Frank DF, Erb HN and Houpt KA. **Urine spraying in cats: presence of concurrent disease and effects of a pheromone treatment.** *Appl Anim Behav Sci* 1999; 61: 263–272.
- Westropp JL, Delgado M and Buffington CAT. **Chronic lower urinary tract signs in cats: current understanding of pathophysiology and management.** *Vet Clin North Am Small Anim Pract* 2019; 49: 187–209.
- Tynes VV, Hart BL, Pryor PA, et al. **Evaluation of the role of lower urinary tract disease in cats with urine-marking behavior.** *J Am Vet Med Assoc* 2003; 223: 457–461.
- Horwitz DF. **Common feline problem behaviors: urine spraying.** *J Feline Med Surg* 2019; 21: 209–219.

- 27 Rijnberk A, Voorhout G, Kooistra HS, et al. **Hyperaldosteronism in a cat with metastasized adrenocortical tumor.** *Vet Q* 2001; 23: 38–43.
- 28 Combes A, Pey P, Paepe D, et al. **Ultrasonographic appearance of adrenal glands in healthy and sick cats.** *J Feline Med Surg* 2012; 15: 445–457.
- 29 Moore LE, Biller DS and Smith TA. **Use of abdominal ultrasonography in the diagnosis of primary hyperaldosteronism in a cat.** *J Am Vet Med Assoc* 2000; 217: 213–215.
- 30 Mitchell JW, Mayhew PD, Culp WTN, et al. **Outcome of laparoscopic adrenalectomy for resection of unilateral noninvasive adrenocortical tumors in 11 cats.** *Vet Surg* 2017; 46: 714–721.
- 31 Lo AJ, Holt DE, Brown MD, et al. **Treatment of aldosterone-secreting adrenocortical tumors in cats by unilateral adrenalectomy: 10 cases (2002–2012).** *J Vet Intern Med* 2014; 28: 137–143.
- 32 Briscoe K, Barrs VR, Foster DF, et al. **Hyperaldosteronism and hyperprogesteronism in a cat.** *J Feline Med Surg* 2009; 11: 758–762.
- 33 Patnaik AK, Erlandson RA, Lieberman PH, et al. **Extraadrenal pheochromocytoma (paraganglioma) in a cat.** *J Am Vet Med Assoc* 1990; 197: 104–106.
- 34 Galvão JFB and Chew DJ. **Metabolic complications of endocrine surgery in companion animals.** *Vet Clin North Am Small Anim Pract* 2011; 41: 847–868.
- 35 Ramos D and Reche-Junior A. **Prevention and management of stress and distress in multi-cat households.** In: Sparkes A and Ellis S (eds). *ISFM guide to feline stress and health*. Tisbury: International Cat Care, 2016, pp 129–144.