



## **CT and MRI characteristics of presumptive hypervitaminosis A in a cat**

Authors: Yu, Yoshihiko, Sugiyama, Atsushi, Kuniya, Takashi, and Hasegawa, Daisuke

Source: Journal of Feline Medicine and Surgery Open Reports, 7(1)

Published By: SAGE Publishing

URL: <https://doi.org/10.1177/2055116921990301>

---

BioOne Complete ([complete.BioOne.org](https://complete.BioOne.org)) is a full-text database of 200 subscribed and open-access titles in the biological, ecological, and environmental sciences published by nonprofit societies, associations, museums, institutions, and presses.

Your use of this PDF, the BioOne Complete website, and all posted and associated content indicates your acceptance of BioOne's Terms of Use, available at [www.bioone.org/terms-of-use](https://www.bioone.org/terms-of-use).

Usage of BioOne Complete content is strictly limited to personal, educational, and non - commercial use. Commercial inquiries or rights and permissions requests should be directed to the individual publisher as copyright holder.

---

BioOne sees sustainable scholarly publishing as an inherently collaborative enterprise connecting authors, nonprofit publishers, academic institutions, research libraries, and research funders in the common goal of maximizing access to critical research.



# CT and MRI characteristics of presumptive hypervitaminosis A in a cat

Yoshihiko Yu<sup>1</sup>, Atsushi Sugiyama<sup>2</sup>, Takashi Kuniya<sup>3</sup> and Daisuke Hasegawa<sup>1,4</sup> 

*Journal of Feline Medicine and Surgery Open Reports*  
1–7

© The Author(s) 2021

Article reuse guidelines:

sagepub.com/journals-permissions

DOI: 10.1177/2055116921990301

journals.sagepub.com/home/jfmsopenreports

This paper was handled and processed by the European Editorial Office (ISFM) for publication in *JFMS Open Reports*



## Abstract

**Case summary** A rescued stray cat with an unknown history was examined for non-ambulatory paraparesis in the hindlimbs. Survey radiographs revealed typical findings of hypervitaminosis A, characterised by vertebral exostoses and extensive osteophytes, mainly in the cervicothoracic spine. CT findings were consistent with the radiographic findings, and CT-based volume rendering and virtual endoscopy into the vertebral canal were created for three-dimensional visualisation of the lesion. MRI revealed a focal and mild dilation of the central canal of the spinal cord. Although the clinical diagnosis of hypervitaminosis A is based on an unusual dietary history and characteristic radiographic findings, the history of this cat was unknown and serum concentrations of vitamin A were unremarkable, when measured >1 month after rescue. However, other possible differential diagnoses were thought to be unlikely and clinical signs never worsened, and thus, hypervitaminosis A was presumed.

**Relevance and novel information** To our knowledge, this is the first report to present the CT and MRI characteristics of a cat with suspected hypervitaminosis A.

**Keywords:** Vertebral ankylosis; skeletal deformities; spondylosis; veterinary radiology

**Accepted:** 1 January 2021

## Case description

An adult spayed female domestic shorthair cat was found crouching down in a yard of a private house. The cat was rescued as it was non-ambulatory in the pelvic limbs and had seemingly been abandoned. The cat was taken to the local veterinary clinic. Therefore, its age and history were unknown except that it had an operation scar on its abdomen. Its body weight was 3.1 kg. Screening tests for feline immunodeficiency virus antibody and feline leukaemia virus antigen were negative. Flea parasites were seen and the haircoat was matted throughout the body. Pain was not obvious when palpating the body. Episodes of head and neck scratching were elicited by palpating the upper cervical region (see Video 1 in the supplementary material), and resembled phantom scratching commonly seen in canine syringomyelia. It was sometimes accompanied by urination. The skin of this region was unremarkable.

At the time of the rescue, complete blood count (CBC) and serum chemistry indicated dehydration and

inflammation or infection. Under sedation, the haircoat was cut short. The general condition of the cat improved with nutrition support and a flea treatment using a topical formulation of selamectin (Revolution 6%; Zoetis JP). Prior to advanced diagnostic imaging that was conducted 1 month later, CBC and serum chemistry were performed again and the results were unremarkable.

<sup>1</sup>Laboratory of Veterinary Radiology, Nippon Veterinary and Life Science University, Musashino, Tokyo, Japan

<sup>2</sup>Suruga Animal Hospital, Shizuoka, Japan

<sup>3</sup>Kaba Veterinary Clinic, Hamamatsu, Shizuoka, Japan

<sup>4</sup>The Research Center for Animal Life Science, Nippon Veterinary and Life Science University, Musashino, Tokyo, Japan

## Corresponding author:

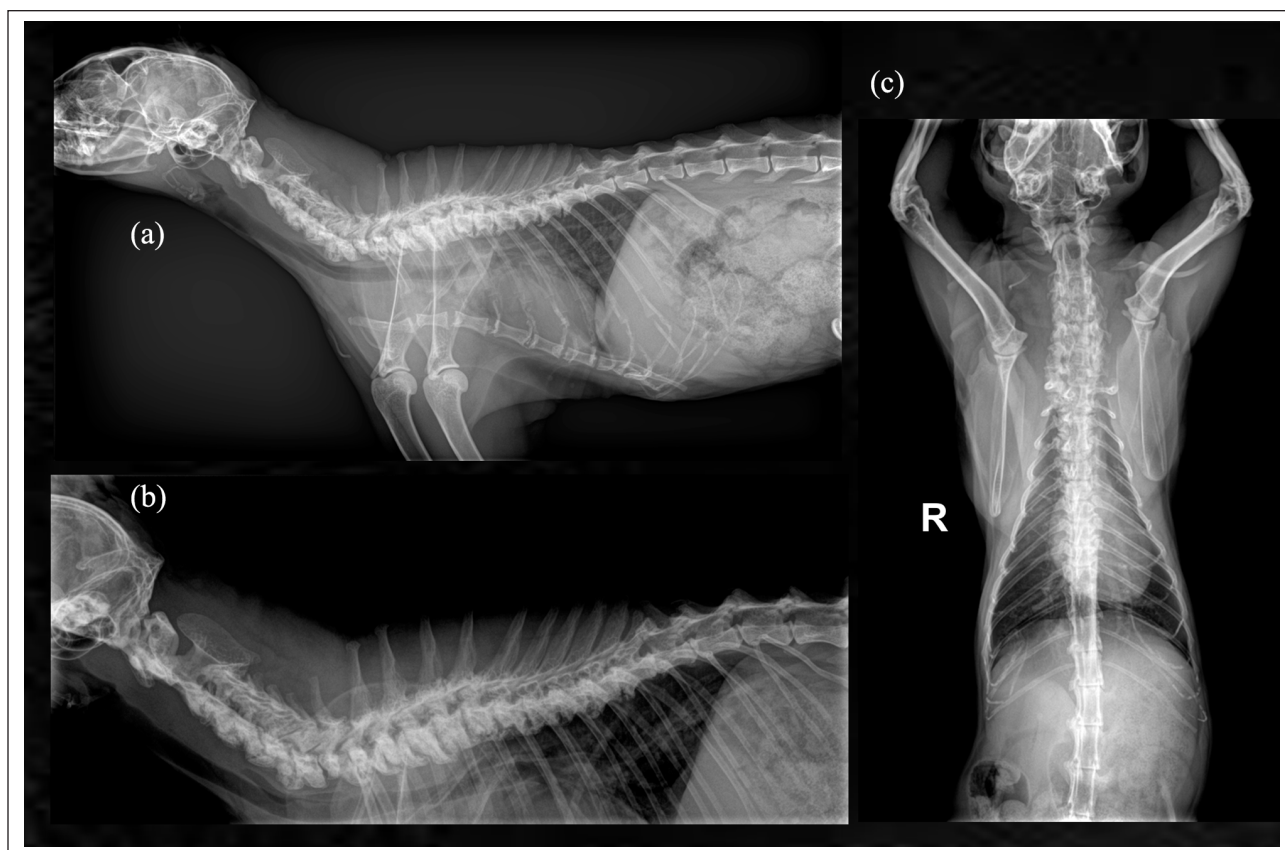
Daisuke Hasegawa DVM, PhD, AiCVIM (Neurology), Laboratory of Veterinary Radiology, Nippon Veterinary and Life Science University, 1-7-1 Kyouunan cho, Musashino, Tokyo 180-8602, Japan

Email: disk-hsgw@nvlu.ac.jp



Creative Commons Non Commercial CC BY-NC: This article is distributed under the terms of the Creative Commons

Attribution-NonCommercial 4.0 License (<https://creativecommons.org/licenses/by-nc/4.0/>) which permits non-commercial use, reproduction and distribution of the work without further permission provided the original work is attributed as specified on the SAGE and Open Access pages (<https://us.sagepub.com/en-us/nam/open-access-at-sage>).



**Figure 1** Radiograph of the cervicothoracic spine. (a) Lateral radiograph of the cervicothoracic region of the cat. (b) Expanded lateral radiograph targeting the affected region. (c) Ventrodorsal view of the cervicothoracic region of the cat

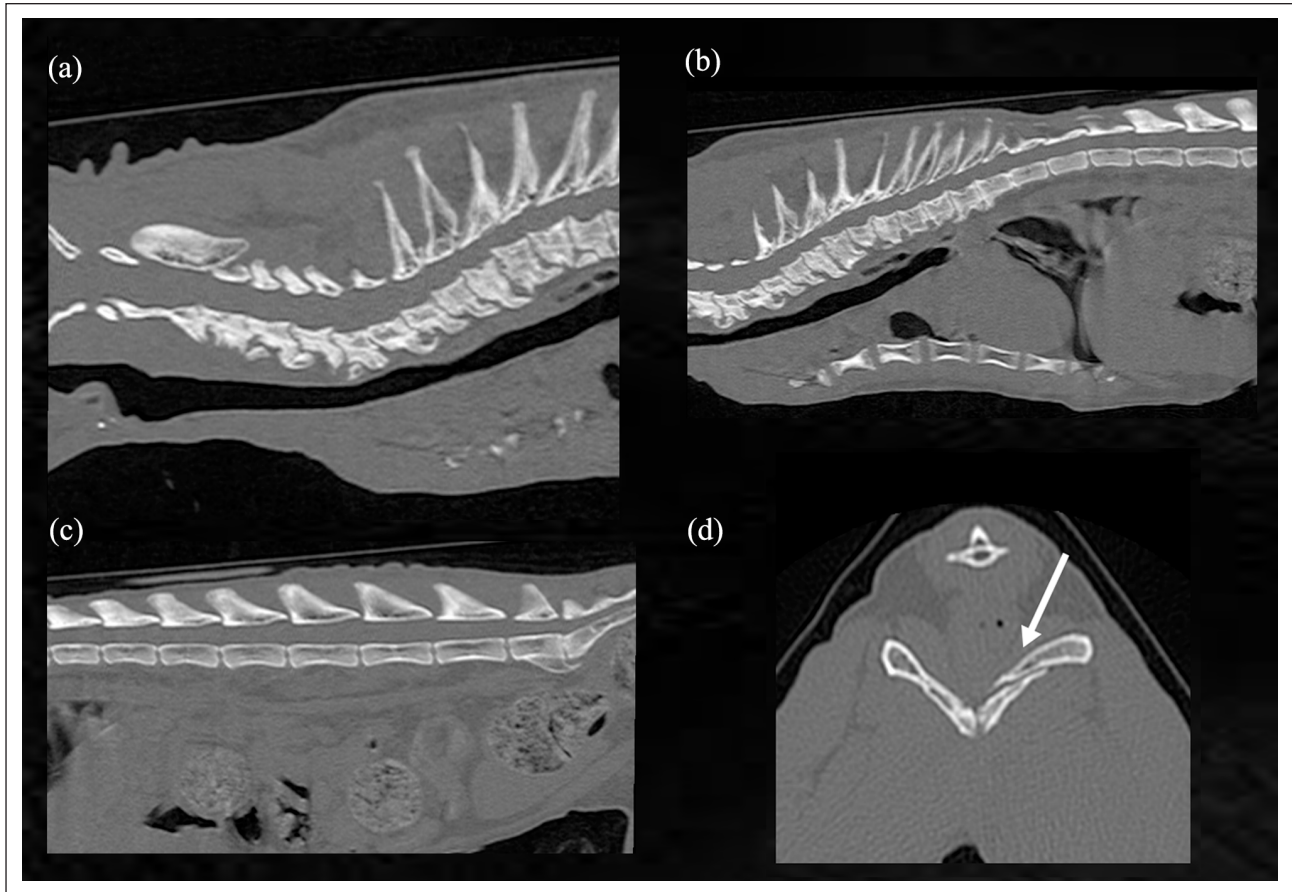
Neurological examination was performed before advanced diagnostic imaging. Mentation was normal. The cat had non-ambulatory paraparesis in the pelvic limbs without urinary or faecal incontinence (see Video 2 in the supplementary material). Postural reaction of all four limbs was decreased. Spinal reflexes were normal in the thoracic limbs and hyper-reflexia was seen in the pelvic limbs. Nociception was normal in all four limbs. The perineal reflex was intact. Cranial nerve examinations were unremarkable. Neuroanatomical localisation revealed multifocal lesions, including in the C1–C5, C6–T2 and T3–L3 segments of the spinal cord, and/or brain.

Skeletal survey radiography revealed vertebral exostoses and extensive osteophytes from the upper cervical vertebra to the lower thoracic vertebra (C2–T10) (Figure 1). Changes were more severe at the ventral aspect of the spine, although changes were also found at the dorsal aspect. Morphological asymmetry of the pelvis was also found. No scoliosis or kyphosis was found, but dorsal extension of the neck was observed. Ultrasonography of the abdomen was performed and findings were unremarkable except for the absence of ovaries.

Furthermore, CT and MRI were performed under general anaesthesia to investigate the causes of the pelvic limb paresis and episodes of head and neck scratching.

CT of the axial skeleton was conducted using a 16-slice scanner (Supria; Hitachi Medical Systems). CT confirmed vertebral exostoses and extensive osteophytes between C2 and T10 and at the L7–S1 junction with higher CT values (Figure 2a–c), as well as radiographs. A pelvic fracture was also identified (Figure 2d), although this was not considered to be the cause of the pelvic limb paraparesis. CT-based three-dimensional volume rendering (Figure 3) and virtual endoscopy (see Video 3 in the supplementary material) were generated using an imaging workstation (AZE Virtual Place; AZE). CT-based virtual endoscopy revealed stenosis of the vertebral canal of the cervical and the rostral thoracic spine caused by hyperostosis along the spinal canal and protruded calcified intervertebral discs that may have been involved in hyperostosis (see Video 3 in the supplementary material). No ovaries were seen with CT in addition to ultrasonography.

MRI of the brain and spinal cord was performed with a 0.3-Tesla MRI scanner (AIRIS Vento; Hitachi Medical Systems). Sagittal T2-weighted (T2W) and transverse T2W imaging were obtained for brain MRI. Spinal MRI included the spinal cord between C2 and T11 for the sagittal T2W imaging, and between T2 and T7 for the transverse T2W, T1-weighted (T1W) and subsequent contrast-enhanced



**Figure 2** CT imaging of the cat. Sagittal plane of CT of the (a) cervical, (b) thoracic and (c) lumbar spine. Vertebral exostoses and extensive osteophytes were seen in the cervical and thoracic spine. Spondylosis was also seen at the lumbosacral junction. (d) Transverse CT image of the pelvis. A bone fracture was seen (indicated by the arrow)

T1W imaging. Intravenous administration of a gadolinium-based MRI contrast agent, gadoteridol (0.15mmol/kg [ProHance; Bracco Diagnostic]), was used for the contrast enhancement.

Brain MRI showed normal findings. Spinal MRI of the cervicothoracic region revealed a mild dilation of the central canal of the spinal cord with T2 hyperintensity and T1 hypointensity without contrast enhancement at the T4–T5 region (Figure 4). In addition, multiple intervertebral disc protrusions and decreased T2 signal intensities of intervertebral discs were observed in the cervical and thoracic spine.

Based on the radiographic findings, differential diagnoses included hypervitaminosis A, mucopolysaccharidosis (MPS), diffuse idiopathic skeletal hyperostosis (DISH), osteochondromatosis (also known as multiple cartilaginous exostoses) and infectious spondylitis. However, MPS, DISH, osteochondromatosis and infectious spondylitis were thought to be unlikely for the reasons described in the discussion. Therefore, hypervitaminosis A was considered the most likely diagnosis.

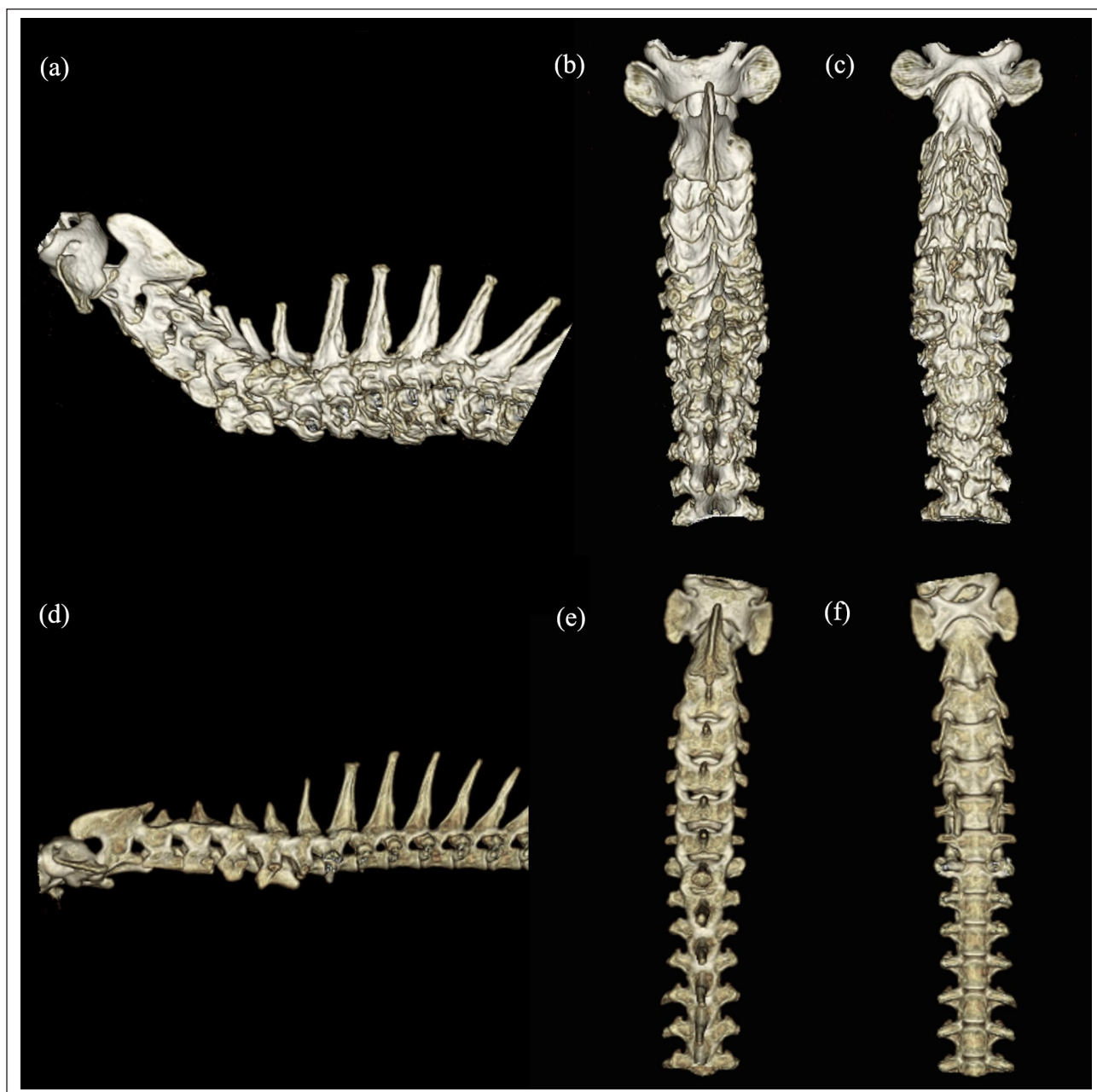
After CT and MRI examination, serum concentrations of vitamin A from the affected cat, as well as two healthy

cats used as controls, were measured using high-performance liquid chromatography by a commercial laboratory (Sanritsu Zelkova). The serum vitamin A concentrations of the affected cat and two healthy cats were 1.04, 0.46 and 0.66  $\mu\text{mol/l}$ , respectively, all of which were unremarkable. The reference interval (RI) for serum vitamin A in cats was not available from the laboratory. The serum vitamin A RI in cats is reported to be 1.75–6.77  $\mu\text{mol/l}$ ,<sup>1</sup> and plasma vitamin A levels of cats receiving liver diets ranged from 15.74 to 44.71  $\mu\text{mol/l}$  in a study by Seawright et al.<sup>2</sup>

The progression of clinical signs such as neurological deficits and pain was not seen in 7 months of follow-up after the rescue, at the time of manuscript submission. Because non-ambulatory paraparesis in the pelvic limbs remained, a wheelchair for cats was put on, which assisted the cat with walking (see Video 2 in the supplementary material).

For the treatment of episodes of head and neck scratching that were elicited by palpating the upper cervical region, pregabalin (2.5mg/kg PO q24h for 1 week and q12h for 1 week [Lyrica; Pfizer]) was used; however, the therapeutic effect was not obvious. Then, oclacitinib





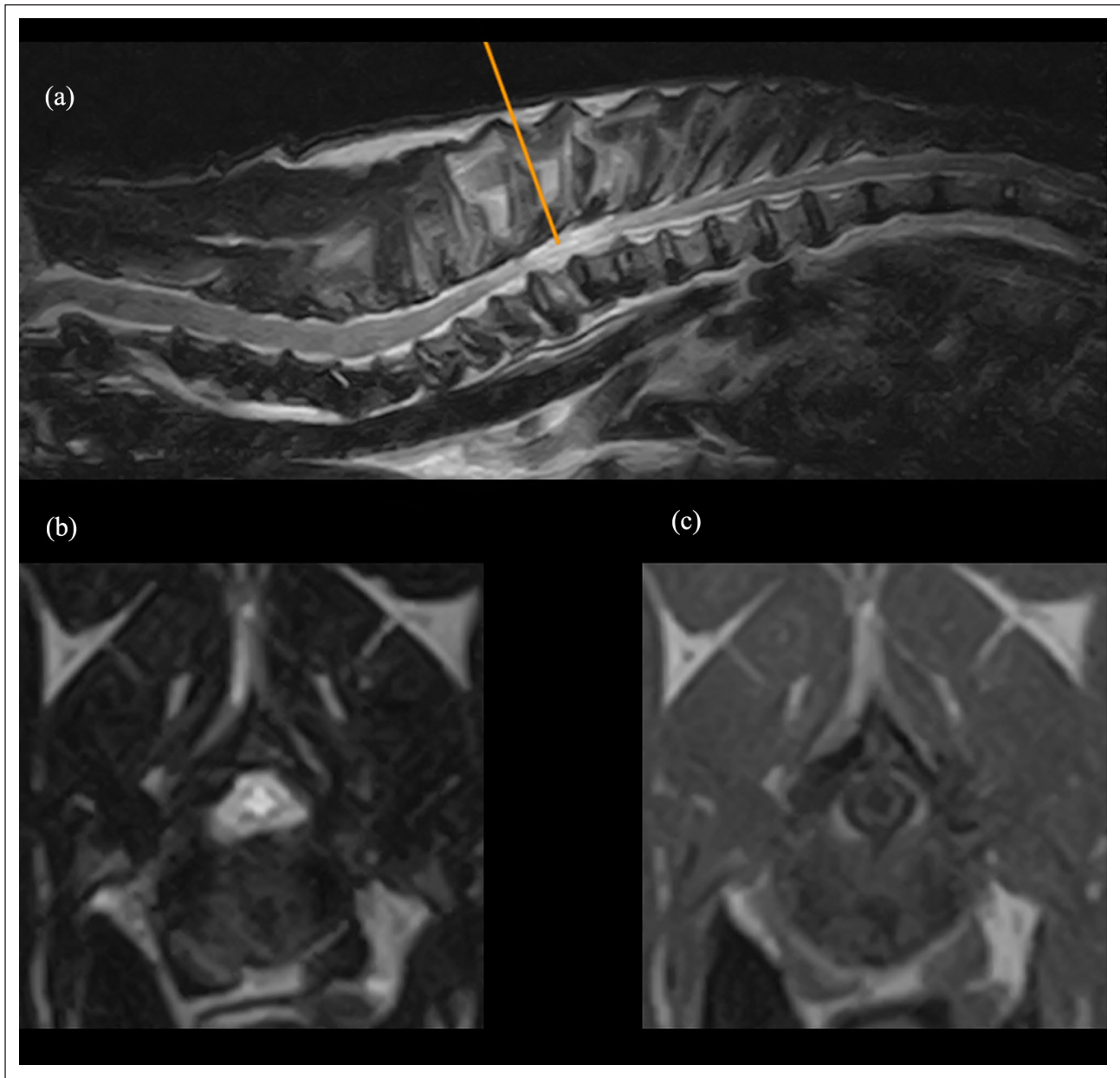
**Figure 3** (a–c) CT three-dimensional volume rendering reconstruction of the cervical and the rostral thoracic spine of the affected cat and (d–f) a cat with idiopathic epilepsy as a control. (a,d) Lateral, (b,e) dorsoventral and (c,f) ventrodorsal views are shown. Drastic vertebral exostoses and extensive osteophytes were seen in the affected cat (a–c) vs the control cat (d–f). Owing to the higher CT value of the affected spine, three-dimensional volume rendering with the same colour contrast from the affected and unaffected cats was difficult to generate

(1.3mg/kg PO q12h [Apoquel; Zoetis JP]) was initiated and clinical improvement was achieved (see Video 1 in the supplementary material). After discontinuing the drug, the sign recurred; thus, it was used as a maintenance treatment for the episodes.

## Discussion

To our knowledge, this is the first report to document the CT and MRI findings of a cat with a typical radiographic

finding of hypervitaminosis A, in which the diagnosis was presumptive owing to the unknown dietary history. Hypervitaminosis A in cats has long been recognised in veterinary medicine.<sup>3–6</sup> The clinical diagnosis of hypervitaminosis A is based almost entirely on an unusual dietary history of feeding with vitamin A-rich diets, such as raw liver, as well as characteristic radiographic findings. The radiographic feature of feline hypervitaminosis A is frequently characterised by exostoses of the



**Figure 4** MRI of the cervicothoracic spinal cord. (a) Sagittal plane of T2-weighted imaging. T2-hyperintensity lesion was identified at the T4–T5 region. Multiple intervertebral disc protrusions and decreased T2 signal intensities of intervertebral discs were also seen. (b) Transverse plane of T2-weighted imaging. The image was obtained along the orange line indicated in (a). (c) Transverse plane of T1-weighted imaging after contrast enhancement at the same level of (b). (b,c) On transverse planes, a mild dilation of the central canal of the spinal cord with T2-hyperintensity and T1-hypointensity without contrast enhancement at the T4–T5 region was identified

cervicothoracic vertebrae.<sup>6,7</sup> Elevated serum levels of vitamin A confirms the diagnosis. Clinical signs include lameness and hyperaesthesia.<sup>5</sup> CT findings of this case corresponded to radiographic findings. In addition to radiographic and CT findings, MRI revealed a mild dilation of the central canal of the spinal cord between T4 and T5 and decreased T2 signal intensities of intervertebral discs between the cervical and thoracic regions

(Figure 4). A mild dilation of the central canal of the spinal cord was considered to have resulted from extensive body formation of thoracic vertebrae (T4–T5) (Figure 2). Furthermore, CT-based virtual endoscopy of the thoracic spinal canal showed protruded calcified intervertebral discs that may have been involved in hyperostosis, as well as hyperostosis of the spinal canal (see Video 3 in the supplementary material). These lesions were

considered to be cause of the non-ambulatory paraparesis in the pelvic limbs.

Potential differential diagnoses, other than hypervitaminosis A, included MPS, DISH, osteochondromatosis and infections of the spine. Abnormal brain MRI findings of presumptive MPS in a cat have been reported,<sup>8</sup> and resembled those recognised in human MPS, such as white matter lesions and brain atrophy.<sup>9</sup> However, the brain MRI of this cat was normal. No other abnormalities reported in feline MPS, such as corneal clouding or facial dysmorphism, were found in this cat.<sup>10</sup> Furthermore, the radiographic findings of this cat did not fulfil criteria that are well known as the gold standard,<sup>11,12</sup> which are the striking characteristics of DISH, including the flowing and contiguous ossification of the ventral longitudinal ligament in at least four contiguous vertebral bodies. Infections of the spine, such as vertebral osteomyelitis<sup>13</sup> or discospondylitis,<sup>14</sup> were also considered; however, the cat's condition did not worsen in the absence of antibiotic treatment, despite the extensive lesions, and characteristic imaging findings of infectious spondylitis such as bony lysis were not detected. Furthermore, sessile or pedunculated protuberances from bone surfaces radiographically characterise osteochondromatosis, and the lesions exhibit an aggressive natural behaviour.<sup>15</sup> The radiographic findings of this cat were not compatible with those of osteochondromatosis. Therefore, other differential diagnoses, apart from hypervitaminosis A, are unlikely.

Incidentally, this cat had episodes of head and neck scratching that were elicited by palpating the upper cervical region. The cause and mechanism of this clinical sign seen in this cat remained unknown. Although the skin appeared normal, oclacitinib – a Janus kinase inhibitor – showed clinical improvement.

In cats, clinical signs of vitamin A toxicosis have been reported to occur 3–4 months after an experimental vitamin A-rich diet.<sup>4</sup> Reportedly, radiographic manifestations of new bone formation may be recognised, at the earliest, 10 weeks after the introduction of a vitamin A-rich diet, and by week 20 exostoses are radiographically visible in most experimental cats.<sup>4</sup> Therefore, it can occur easily when a cat is fed a diet rich in vitamin A. Furthermore, in one case report, the plasma concentration of vitamin A was reportedly around normal ( $7.75 \mu\text{mol/l}$ ) 3 weeks after liver had been removed from a cat's diet.<sup>6</sup> The serum vitamin A concentration of this cat may have returned to normal levels before this cat was rescued and had clinical examinations likewise. Besides, 2/3 affected cats were reported to show an approximately normal level of plasma vitamin A after removing liver from the diet for 3 years, although there are no longitudinal data.<sup>16</sup> Furthermore, one report presumed that a very high turnover rate of vitamin A in cats given very high doses of vitamin A may be associated with the more severe effects

of intoxication, and plasma levels of vitamin A may be relatively low.<sup>2</sup> Therefore, the decreased rate of circulating vitamin A concentration may vary depending on the condition. However, vitamin A concentration in the liver has been documented to be markedly elevated in affected cats<sup>16</sup> and anecdotally reported to remain at an elevated level 2 years after an affected cat had been fed with a diet low in vitamin A.<sup>6</sup> In one report, a marked reduction of vitamin A level in the liver was reported after 3 years without the diet containing liver.<sup>16</sup> Therefore, a surgical biopsy of the liver to measure the concentration of vitamin A might help the diagnosis.

The main limitation of this report is a lack of a dietary history because this cat was a stray animal. Its ovaries were not identified by CT or ultrasonography. The cat also had an operation scar on its abdomen but lacked a clipped ear, which, in city of Shizuoka where this cat was found and rescued, signifies a neutered feral cat,<sup>17,18</sup> suggesting this cat was not neutered by trap–neuter–return and therefore this cat may have once been a household pet. Pathological evaluation was not available as this cat is alive and did not show worsened clinical signs. Pathological evaluation of the liver,<sup>19</sup> in addition to bone lesions and/or measurement of vitamin A concentration in the liver,<sup>6,16</sup> may support a diagnosis of hypervitaminosis A. However, other possible differential diagnoses were unlikely and the radiographic findings indicated the diagnosis of hypervitaminosis A.

## Conclusions

Although hypervitaminosis A in cats has been well known for a long time and the use of radiographic findings to diagnose hypervitaminosis A in cats is well established, there is no report on the CT and MRI findings of this disease. The current report provides CT and MRI findings, as well as CT-based three-dimensional volume rendering and virtual endoscopy, to strengthen the diagnosis of a cat with presumptive hypervitaminosis A. CT findings were consistent with radiographic findings. Of note, CT-based three-dimensional volume rendering and virtual endoscopy provided clear visualisation of the affected spine. Furthermore, MRI showed a focal and mild dilation of the central canal of the spinal cord due to the spinal canal stenosis, which was suspected to be caused by hypervitaminosis A. This report may be valuable as a reference for this feline disorder.

**Conflict of interest** The authors declared no potential conflicts of interest with respect to the research, authorship, and/or publication of this article.

**Funding** The authors received no financial support for the research, authorship, and/or publication of this article.

**Ethical approval** This work involved the use of non-experimental animals only (including owned or unowned

animals and data from prospective or retrospective studies). Established internationally recognized high standards ('best practice') of individual veterinary clinical patient care were followed. Ethical approval from a committee was therefore not specifically required for publication in *JFMS Open Reports*.

**Informed consent** Informed consent (either verbal or written) was obtained from the owner or legal custodian of all animal(s) described in this work (either experimental or non-experimental animals) for the procedure(s) undertaken (either prospective or retrospective studies). No animals or humans are identifiable within this publication, and therefore additional informed consent for publication was not required.

**ORCID iD** Daisuke Hasegawa  <https://orcid.org/0000-0002-7554-9108>

**Supplementary material** The following files are available online:

Video 1: The cat had episodes of head and neck scratching that were elicited by palpating the upper cervical region. This sign was relieved after the administration of oclacitinib; however, the cause and actual mechanism of this clinical sign remained unknown

Video 2: The cat had non-ambulatory paraparesis in the pelvic limbs at the time of presentation. Although progression of clinical signs was not seen, the cat still had non-ambulatory paraparesis in the pelvic limbs over the 7 months of follow-up after the rescue. A wheelchair allowed the cat more mobility

Video 3: CT virtual endoscopy of the thoracic spinal canal of the affected cat, as well as a normal cat. Virtual endoscopy videos were recorded from the first thoracic vertebra to the middle of the thoracic spine

## References

- 1 Kaneko JJ, Harvey JW and Bruss ML (eds). **Appendixes**. In: Clinical biochemistry of domestic animals. St Louis, MO: Elsevier, 2008, pp 873–904.
- 2 Seawright AA, English PB and Gartner RJW. **Hypervitaminosis A and deforming cervical spondylosis of the cat**. *J Comp Pathol* 1967; 77: 29–39.
- 3 Clark L. **Hypervitaminosis a: a review**. *Aust Vet J* 1971; 47: 568–571.
- 4 Clark L, Seawright AA and Hrdlicka J. **Exostoses in hypervitaminotic A cats with optimal calcium-phosphorus in takes**. *J Small Anim Pract* 1970; 11: 553–561.
- 5 Seawright AA, English PB and Gartner RJW. **Hypervitaminosis A and hyperostosis of the cat**. *Nature* 1965; 206: 1171–1172.
- 6 English PB. **Clinical communication: a case of hyperostosis due to hypervitaminosis A in a cat**. *J Small Anim Pract* 1969; 10: 207–212.
- 7 Goldman AL. **Hypervitaminosis A in a cat**. *J Am Vet Med Assoc* 1992; 200: 1970–1972.
- 8 Fernandes R, Cherubini GB, Caine A, et al. **Magnetic resonance findings in a domestic short-hair cat with presumptive mucopolysaccharidosis**. *Vet Rec Case Rep* 2013; 1: e000013. DOI: 10.1136/vetreccr-2013-000013.
- 9 Reichert R, Campos LG, Vairo F, et al. **Neuroimaging findings in patients with mucopolysaccharidosis: what you really need to know**. *Radiographics* 2016; 36: 1448–1462.
- 10 Center SA. **The liver, biliary tract, and exocrine pancreas**. In: Peterson ME and Kutzler MA (eds). Small animal pediatrics. St Louis, MO: Elsevier, 2011, pp 368–390.
- 11 Greatting HH, Young BD, Pool RR, et al. **Diffuse idiopathic skeletal hyperostosis (DISH)** [letter]. *Vet Radiol Ultrasound* 2011; 52: 472–473.
- 12 Resnick D and Niwayama G. **Radiographic and pathologic features of spinal involvement in diffuse idiopathic skeletal hyperostosis (DISH)**. *Radiology* 1976; 119: 559–568.
- 13 Rapoport K, Shamir M, Bibring U, et al. **Epidural spinal empyema and vertebral osteomyelitis in a cat**. *Isr J Vet Med* 2016; 71: 41–44.
- 14 Gomes SA, Behr S, Garosi LS, et al. **Imaging features of discospondylitis in cats**. *J Feline Med Surg* 2020; 22: 631–640.
- 15 Poirier VJ and Steffen F. **Tumors of the musculoskeletal system**. In: Montavon PM, Voss K and Langley-Hobbs SJ (eds). Feline orthopedic surgery and musculoskeletal disease. St Louis, MO: Elsevier, 2009, pp 97–104.
- 16 Seawright AA, English PB and Gartner RJ. **Hypervitaminosis A of the cat**. *Adv Vet Sci Comp Med* 1970; 14: 1–27.
- 17 City of Shizuoka. <https://www.city.shizuoka.lg.jp/index.html> (accessed August 4, 2020).
- 18 Shizuoka-shi Veterinarian Society. <http://www.shizuoka-shi-juuishikai.gr.jp/index.html> (accessed August 4, 2020).
- 19 Guerra JM, Daniel AGT, Aloia TPA, et al. **Hypervitaminosis A-induced hepatic fibrosis in a cat**. *J Feline Med Surg* 2014; 16: 243–248.