



## **Transient myocardial thickening associated with acute myocardial injury and congestive heart failure in two *Toxoplasma gondii*-positive cats**

Authors: Romito, Giovanni, Fracassi, Federico, and Cipone, Mario

Source: Journal of Feline Medicine and Surgery Open Reports, 8(2)

Published By: SAGE Publishing

URL: <https://doi.org/10.1177/20551169221131266>

---

BioOne Complete ([complete.BioOne.org](https://complete.BioOne.org)) is a full-text database of 200 subscribed and open-access titles in the biological, ecological, and environmental sciences published by nonprofit societies, associations, museums, institutions, and presses.

Your use of this PDF, the BioOne Complete website, and all posted and associated content indicates your acceptance of BioOne's Terms of Use, available at [www.bioone.org/terms-of-use](https://www.bioone.org/terms-of-use).

Usage of BioOne Complete content is strictly limited to personal, educational, and non - commercial use. Commercial inquiries or rights and permissions requests should be directed to the individual publisher as copyright holder.

---

BioOne sees sustainable scholarly publishing as an inherently collaborative enterprise connecting authors, nonprofit publishers, academic institutions, research libraries, and research funders in the common goal of maximizing access to critical research.



# Transient myocardial thickening associated with acute myocardial injury and congestive heart failure in two *Toxoplasma gondii*-positive cats

Journal of Feline Medicine and Surgery Open Reports  
1–6

© The Author(s) 2022

Article reuse guidelines:

sagepub.com/journals-permissions

DOI: 10.1177/20551169221131266

journals.sagepub.com/home/jfmsopenreports

This paper was handled and processed by the European Editorial Office (ISFM) for publication in *JFMS Open Reports*



Giovanni Romito , Federico Fracassi and Mario Cipone

## Abstract

**Case series summary** In this report, we provide detailed clinical, laboratory, electrocardiographic and echocardiographic descriptions of two *Toxoplasma gondii*-positive cats diagnosed with transient myocardial thickening (TMT) and acute myocardial injury (MI). In both cases, aetiological diagnosis was based on the antibody screening test (all cats had IgM titres  $\geq 1:64$ ) and MI was demonstrated by a concomitant severe increase of the serum concentration of cardiac troponin I (5.1–23.6 ng/ml; upper hospital limit  $<0.2$  ng/ml). In both cats, TMT and MI were aggravated by left atrial dilation and dysfunction, as well as congestive heart failure. In one cat, atrial standstill was also documented, while the other cat showed an intracardiac thrombus. Both cats underwent an extensive diagnostic work-up aimed at excluding additional comorbidities that could contribute to TMT and MI, and received appropriate antiprotozoal (ie, clindamycin) and cardiovascular therapy (eg, furosemide, pimobendan and clopidogrel). This was followed by a simultaneous decline in *T gondii* serology titres, normalisation of troponin level and the resolution of clinical, electrocardiographic, radiographic and echocardiographic abnormalities. In the light of these results, therapies were interrupted and subsequent controls ruled out any disease relapse.

**Relevance and novel information** Although *T gondii* represents an often-cited cause of myocarditis in feline medicine, the existing literature on the demonstration of *T gondii*-associated cardiac compromise in cats is extremely limited. Accordingly, this report provides a useful contribution to pertinent scientific literature since it describes TMT and acute MI in two *T gondii*-positive cats.

**Keywords:** Cardiac troponin I; echocardiography; electrocardiography; intracardiac thrombus; toxoplasmic myocarditis

**Accepted:** 20 September 2022

## Introduction

In cats, transient myocardial thickening (TMT) represents a recently described clinical entity characterised by reversible left ventricular myocardial thickening (LVMT) mimicking primary hypertrophic cardiomyopathy.<sup>1,2</sup> Transient left atrial (LA) dilation and dysfunction leading to congestive heart failure (CHF) and increased cardiac troponin I (cTnI), indicating ongoing myocardial injury (MI),<sup>3,4</sup> represent additional common features of feline TMT.<sup>1,2</sup> Although the mechanism of this condition is still a subject of debate in veterinary medicine,<sup>1,2</sup> interstitial oedema due to myocarditis represents the main

explanation of reverse remodelling of human TMT.<sup>5–8</sup> The term myocarditis refers to inflammatory myocardial infiltration associated with cardiomyocyte damage of

Department of Veterinary Medical Sciences, Alma Mater Studiorum – University of Bologna, Ozzano dell'Emilia, Italy

### Corresponding author:

Giovanni Romito DVM, MSc, PhD, Dipl ECVIM-CA (Cardiology), Department of Veterinary Medical Sciences, Alma Mater Studiorum – University of Bologna, via Tolara di Sopra 50, Ozzano dell'Emilia 40064, Italy  
Email: giovanni.romito2@unibo.it



Creative Commons Non Commercial CC BY-NC: This article is distributed under the terms of the Creative Commons

Attribution-NonCommercial 4.0 License (<https://creativecommons.org/licenses/by-nc/4.0/>) which permits non-commercial use, reproduction and distribution of the work without further permission provided the original work is attributed as specified on the SAGE and Open Access pages (<https://us.sagepub.com/en-us/nam/open-access-at-sage>).

non-ischæmic origin.<sup>9</sup> Both infectious and non-infectious diseases can cause myocarditis and TMT.<sup>9,10</sup> Infective agents documented during feline myocarditis and/or TMT include *Bartonella henselae*, *Streptococcus canis*, *Sarcocystis felis*, feline immunodeficiency virus, panleukopenia virus, feline coronavirus and *Toxoplasma gondii*.<sup>2,9,11–15</sup> Interestingly, although the last pathogen represents an often-cited cause of feline myocarditis and cats with TMT are often tested for *T. gondii* infection,<sup>1,2</sup> only one previous case report has described cardiac compromise in a cat concurrently diagnosed with clinical toxoplasmosis,<sup>13</sup> and published investigations on this topic are largely limited to necropsy reports.<sup>16,17</sup>

This report provides detailed in vivo data on two *T. gondii*-positive cats with TMT complicated by acute MI and CHF, thus expanding our knowledge on the clinical features and natural history of naturally acquired cardiac compromise that may be observed in cats with serological evidence of toxoplasmosis.

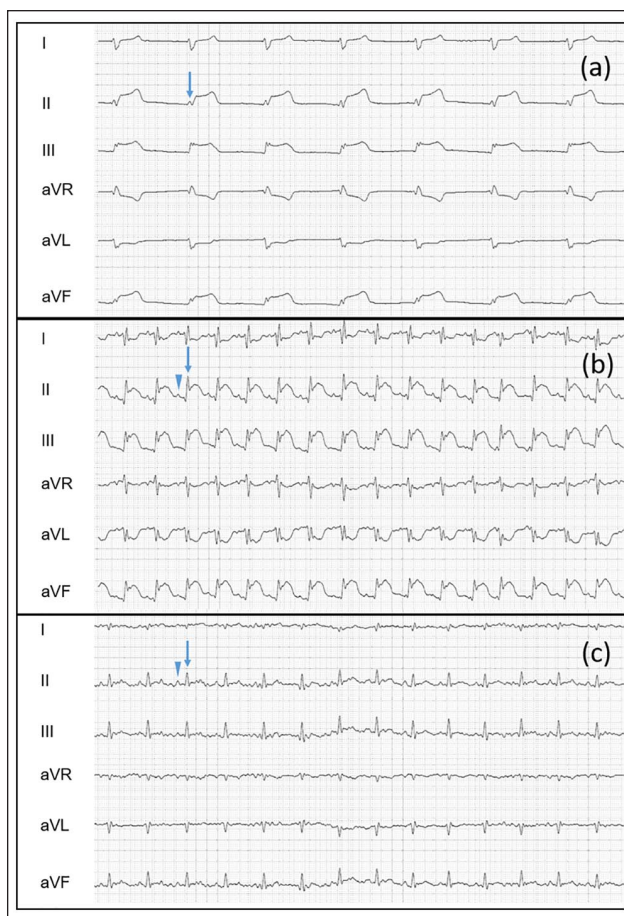
## Case series description

### Case 1

A young adult female domestic shorthair cat weighing 2.3 kg from the north of Italy was presented with a 2-day history of weakness and anorexia. One month prior, the cat had been diagnosed with hyperthyroidism and started on methimazole (2.2 mg/cat PO q12h). The cat lived indoors but had free access to the outside and was reported to hunt mice.

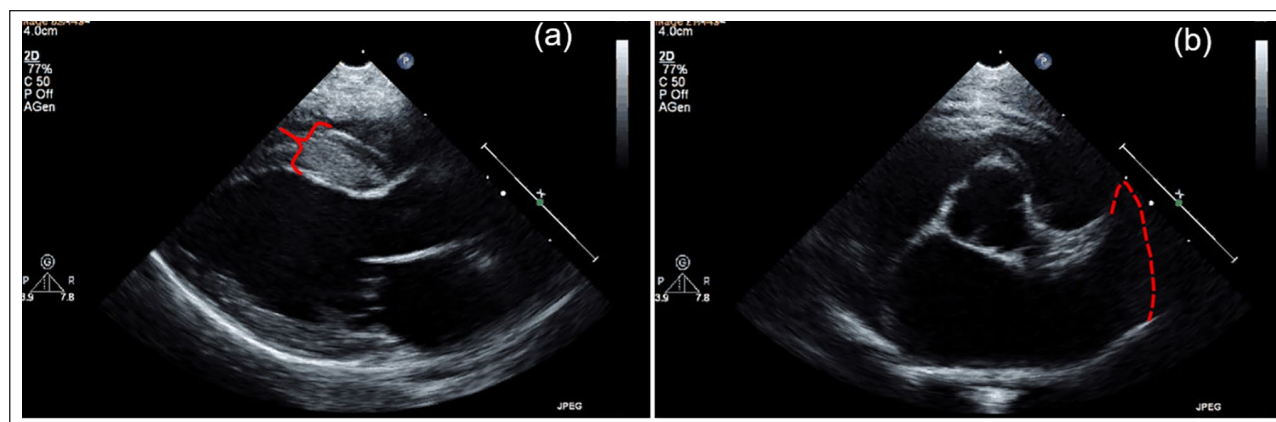
At admission, physical abnormalities included mental obtundation, bradycardia (heart rate 90 beats/min), hypotension (systolic blood pressure [SBP] 98 mmHg) and mild respiratory effort. On thoracic- and abdominal-focused ultrasonographic assessment, mild pleural and abdominal effusion, and subjective LA enlargement were documented. A six-lead surface electrocardiogram showed atrial standstill associated with a ST-segment elevation, suggestive of possible concomitant myocardial ischaemia (Figure 1).<sup>18</sup> Transthoracic echocardiography was subsequently performed (Figure 2, Table 1), which showed diffuse asymmetric LVMT, LA dilation with decreased LA fractional shortening, and an enlarged and hypokinetic LA appendage.<sup>19–21</sup>

The cat was hospitalised under continuous electrocardiographic monitoring and treated with furosemide (1 mg/kg IV q8h), pimobendan (0.25 mg/kg PO q12h) and clopidogrel (18.75 mg/cat PO q24h). This approach led to progressive clinical improvement within 12 h (the cat became brighter, appetite improved, respiratory effort decreased and SBP gradually increased [110 mmHg]). Moreover, the electrocardiogram documented spontaneous cardioversion showing a sinus rhythm with a normal heart rate, although the ST-segment elevation was still present (Figure 1). At that time, blood and urine were collected for tests aimed to assess the cat's systemic



**Figure 1** (a) Initial six-lead electrocardiography tracing from case 1. Notice the lack of sinus P waves, the slow and regular ventricular rhythm (QRS complex duration 70 ms; heart rate 90 beats/min [bpm]) and the elevated ST segment (0.4 mV). These findings are suggestive of atrial standstill and myocardial ischaemia. (b) First electrocardiographic control. Note the re-establishment of sinus rhythm, the normal heart rate (200 bpm) and the persistence of ST-segment elevation. (c) Last electrocardiographic control. Note that sinus rhythm is still present and ST-segment elevation has disappeared. Motion and muscle artefact is also present. In each panel, the blue arrows help to identify QRS complexes. In the last two panels, blue arrowheads help to identify the sinus P waves. In each panel paper speed = 50 mm/s; 2 cm = 1 mV

condition (serological test for feline leukaemia virus and feline immunodeficiency virus, complete blood count [CBC], serum biochemistry, urinalysis) and to further investigate its cardiac status (cTnI). The cat tested negative for the aforementioned pathogens. Blood work showed increased alanine aminotransferase (189 U/l; hospital reference interval [HRI] 20–72), urea (139 mg/dl; HRI 30–65), creatine kinase (CK; 1427 IU/l; HRI 91–326), serum amyloid A (10 µg/ml; HRI 0–5) and cTnI (5.1 ng/ml; HRI 0–0.2). In the light of the ongoing MI and the history of hunting mice,<sup>3,4</sup> further blood samples were subsequently obtained and sent for toxoplasmosis indirect



**Figure 2** Transthoracic echocardiography obtained at the time of presentation of case 1. (a) Right parasternal long axis five-chamber view. Note the left ventricular wall thickening, particularly evident at the interventricular septum level (red brace). (b) Right parasternal short-axis view at the aortic root level. Note the dilation of the left atrium and left atrial appendage (red dotted lines allow appreciation of the left atrial appendage size)

**Table 1** Selected echocardiographic findings of cases 1 and 2

Parameter	Case 1		Case 2		Comparison intervals	Reference
	Admission	Control	Admission	Control		
IVSd (mm)	6.2	4.5	6	4.6	4.5*/5.2†	19
LVFWd (mm)	5.6	4	5.8	4.6	4.4*/5.1†	19
LAD	23	15	18	15	16	20
LA:Ao	2.1	1.5	1.8	1.5	<1.6	21
LAFS (%)	13	30	15	30	26 ± 10.1	20

IVSd = end-diastolic interventricular septum; LVFWd = end-diastolic left ventricular free wall; LAD = maximal left atrial anteroposterior diameter; LA:Ao = left atrial-to-aortic root ratio; LAFS = left atrial fractional shortening

\*Reference intervals for a 2.5 kg cat

†Reference intervals for a 5 kg cat

fluorescence antibody titres (IgM and IgG) and *Bartonella* PCR. The cat tested positive exclusively for *T gondii* (IgM and IgG titres 1/80 and 1/1280, respectively)<sup>22</sup> and was started on clindamycin (9.5mg/kg PO q12h). From day 3 onwards, the cat's SBP was normal (130 mmHg) and effusions were not detectable. The cat was therefore discharged from the hospital on oral furosemide (1 mg/kg PO q12h) and pimobendan, clopidogrel and clindamycin (unchanged dosages). Daily control of resting respiratory rate and regular rechecks were recommended to the owners.

After 2 months, physical examination revealed no abnormalities. Electrocardiographic (Figure 1) and echocardiographic measurements (Figure 3, Table 1), as well as cTnI concentration (0.13ng/ml), were normalised. Moreover, although the IgG titre was unchanged, the IgM titre was halved (1:40). Clindamycin and clopidogrel were interrupted, and the furosemide dose was halved. After 1 month, the cat was clinically and echocardiographically normal. Furosemide was discontinued. After 3

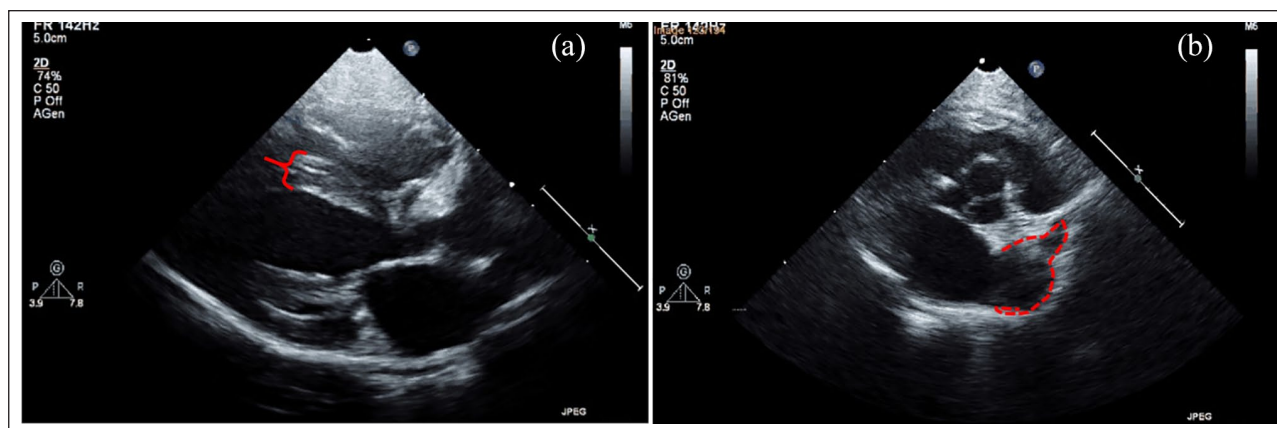
months, the cat was clinically and cardiologically stable compared to the previous examination. Pimobendan was interrupted. The cat continued to do well despite the interruption of cardiovascular drugs and was still alive 10 months after presentation.

### Case 2

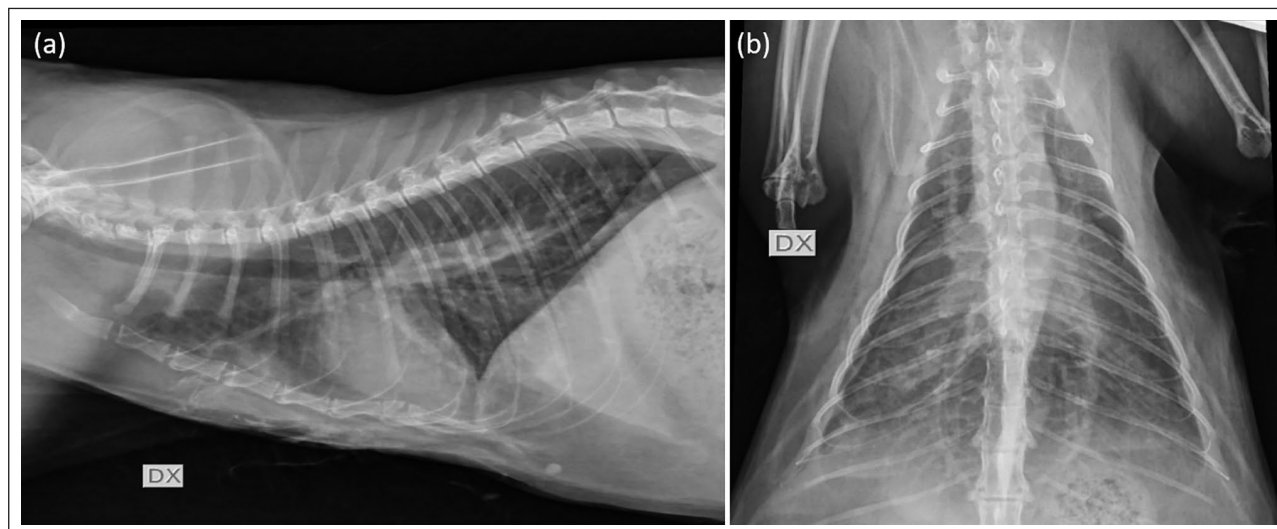
A 5-year-old neutered female domestic shorthair cat weighing 4.8kg from the north of Italy was presented with a 1-day history of respiratory distress. Previous medical history included an episode of anticoagulant rodenticide intoxication that was successfully treated medically. The cat lived indoors but had free access to the outside and hunted mice.

Upon presentation, clinical abnormalities were limited to tachypnoea (respiratory rate 72 breaths/min) and rapid, shallow breathing. Thoracic- and abdominal-focused ultrasonographic assessment revealed mild pleural and abdominal effusion, diffuse lung B lines and subjective LA enlargement. Thoracic radiographs showed





**Figure 3** Transthoracic echocardiography obtained approximately 2 months after presentation of case 1. (a) Right parasternal long axis five-chamber view. Compared to Figure 2(a), note the reduction of the interventricular septum thickness (red brace). (b) Right parasternal short-axis view at the aortic root level. Compared to Figure 2(b), note the reduction of the size of left atrium and its appendage (red dotted lines allow appreciation of the left atrial appendage size)



**Figure 4** Thoracic radiographs obtained in Case 2. (a) Laterolateral radiograph acquired in right recumbency. (b) Dorsoventral radiograph. In both projections, enlarged pulmonary veins, increased cardiac silhouette, mild pleural effusion and interstitial pulmonary pattern are evident

enlarged pulmonary veins, increased cardiac silhouette, mild pleural effusion and mild interstitial pulmonary pattern (Figure 4).

The cat was hospitalised and treated with furosemide (1 mg/kg IV q4h), pimobendan (0.2 mg/kg PO q12h) and oxygen (nasal oxygen catheter at 0.5–1 l/min). This approach led to a progressive clinical improvement within 24 h, which, in turn, allowed us to obtain blood samples (CBC, biochemistry and cTnI) and to perform a transthoracic echocardiography. Blood abnormalities included elevated CK (754 IU/l) and cTnI (23.6 ng/ml). Echocardiogram showed diffuse symmetric LVMT, LA dilation with decreased LA fractional shortening, an enlarged and hypokinetic LA appendage, spontaneous echo-contrast and an intra-auricular hyperechoic

density suggestive of a thrombus (Table 1). Accordingly, clopidogrel (18.75 mg/cat PO q24h) and unfractionated heparin (250 UI/kg SC q8h) were started. Moreover, in the light of the echocardiographic findings and cTnI level, additional blood samples were sent to investigate the same infective diseases tested in Case 1. The cat showed positivity exclusively for toxoplasmosis (IgM and IgG titres 1:80 and 1:640, respectively). Therefore, clindamycin (10 mg/kg PO q12h) was prescribed. Within 5 days, the cat was clinically stable, free fluids and lung B lines were undetectable; cTnI was significantly decreased (1.7 ng/ml). Accordingly, the cat was discharged with an unchanged dose of pimobendan, clopidogrel and heparin, and a dose of oral furosemide of 1.7 mg/kg q12h. Daily control of resting respiratory rate and regular

rechecks were recommended to the owners. After 2 months, the cat was clinically normal, the cTnI was within the HRI (0.02 ng/ml) and the IgG and IgM titres were halved (1:40 and 1:320, respectively). Moreover, echocardiography demonstrated normalisation of cardiac dimension and functional parameters (Table 1), as well as lack of spontaneous echocontrast and intracardiac thrombus. Clopidogrel, heparin and clindamycin were interrupted, furosemide dose was reduced to 1 mg/kg q12h and rechecks were organised for every 1–2 months. At each clinical recheck, neither physical nor echocardiographic abnormalities were found. Furosemide dose was progressively decreased until interruption. Despite this, the cat continued to do well and was still alive 10 months after presentation.

## Discussion

The true incidence of toxoplasmic myocarditis (TM) in the general feline population is unknown,<sup>22</sup> mainly because definitive diagnosis requires histological confirmation, obtainable at post-mortem examination or with endomyocardial biopsy. Since the latter is an invasive procedure rarely employed in feline medicine,<sup>23</sup> the in vivo diagnosis of myocarditis is often presumptive in cats and based on anamnestic and clinical data combined with findings from non-invasive examinations, such as blood tests and echocardiography.<sup>9</sup> Unfortunately, both toxoplasmosis and myocarditis are diseases characterised by great variability in clinical presentation; therefore, no consistently recognisable clinical syndrome exists.<sup>9,22</sup> Similarly, no laboratory or echocardiographic finding can be considered specific for myocarditis, especially if interpreted individually.<sup>9</sup> Accordingly, a rational approach considering all the available findings from initial evaluation and rechecks is needed to provide convincing evidence of TM and guide treatment. In the cats in this paper cats, the hypothesis of TMT eventually due to TM was based on: (1) the clinical presentation characterised by LVMT with CHF and elevated cTnI; (2) an aetiological diagnosis (ie, all cats had IgM titres  $\geq$  1:64)<sup>22</sup> indicating ongoing toxoplasmosis; (3) the lack of other obvious causes of such a cardiac compromise; (4) a favourable disease course characterised by resolution of clinical signs, cTnI normalisation with concomitant decline of *T gondii* serology titres, cardiac reverse remodelling and a good long-term follow-up without cardiovascular medications; and (5) the fact that the aforementioned results were achieved only after anti-protozoal therapy administration. A similar diagnostic approach has been described for clinical diagnosis of human,<sup>24,25</sup> canine<sup>26</sup> and feline TM,<sup>13</sup> as well as for the diagnosis of feline TMT.<sup>1</sup>

In TM, myocardial compromise is predominantly the result of tachyzoite replication within cardiomyocytes. In the short term, this leads to myocardial inflammation;

however, in the long term, myocardial necrosis, as well as myocardial and interstitial fibrosis, may also develop.<sup>22,24,25,27</sup> As several factors play a role in TM pathogenesis (eg, host species, its immune response, degree of virulence of the *T gondii* strain and extension of cardiomyocyte infection/injury), the clinical course is almost unpredictable.<sup>13,24,25</sup> It may range from subclinical changes (eg, myocardial morphological/functional abnormalities and ST-segment deviation) to life-threatening complications. Concerning life-threatening complications, both cats in this report experienced CHF and one cat also showed an intracardiac thrombus.

The main limitation of this report is intrinsically related to the fact that only two subjects were included. The second limitation is the lack of histopathology (due to the improvement of the cats, which survived the disease state thanks to our management, thus precluding post-mortem evaluation) to conclusively confirm TM. Although the outcome of these cases was favourable and supported our diagnostic and therapeutic choices, it could be hypothesised that the *T gondii* infection was incidental and did not represent the primary cause of TMT in these cases. However, this presupposes that some comorbidities had arisen previously/concomitantly and had triggered MI. Nevertheless, in the light of the extensive diagnostic work-up, this theory may be considered unlikely. Indeed, apart from toxoplasmosis, only medically controlled hyperthyroidism was found in one case, which is unlikely to cause a rapidly evolving TMT complicated by CHF and severely increased cTnI (ie, 5.1 ng/ml).<sup>28–32</sup>

## Conclusions

This case report describes two cats with TMI and serological evidence of toxoplasmosis.

**Conflict of interest** The authors declared no potential conflicts of interest with respect to the research, authorship, and/or publication of this article.


**Funding** The authors received no financial support for the research, authorship, and/or publication of this article.

**Ethical approval** The work described in this manuscript involved the use of non-experimental (owned or unowned) animals. Established internationally recognised high standards ('best practice') of veterinary clinical care for the individual patient were always followed and/or this work involved the use of cadavers. Ethical approval from a committee was therefore not specifically required for publication in *JFMS Open Reports*. Although not required, where ethical approval was still obtained, it is stated in the manuscript.

**Informed consent** Informed consent (verbal or written) was obtained from the owner or legal custodian of all animal(s) described in this work (experimental or non-experimental animals, including cadavers) for all procedure(s) undertaken

(prospective or retrospective studies). No animals or people are identifiable within this publication, and therefore additional informed consent for publication was not required.

**ORCID ID** Giovanni Romito  <https://orcid.org/0000-0003-3927-1601>

Federico Fracassi  <https://orcid.org/0000-0003-3121-2199>

## References

- Novo Matos J, Pereira N, Glaus T, et al. **Transient myocardial thickening in cats associated with heart failure.** *J Vet Intern Med* 2018; 32: 48–56.
- Joseph JL, Oxford EM and Santilli RA. **Transient myocardial thickening in a *Bartonella henselae*-positive cat.** *J Vet Cardiol* 2018; 20: 198–203.
- Langhorn R and Willesen JL. **Cardiac troponins in dogs and cats.** *J Vet Intern Med* 2016; 30: 36–50.
- Romito G and Cipone M. **Deep and huge transient negative T waves in dogs with myocardial injury.** *J Vet Cardiol* 2021; 36: 131–140.
- Hauser AM, Gordon S, Cieszkowski J, et al. **Severe transient left ventricular “hypertrophy” occurring during acute myocarditis.** *Chest* 1983; 83: 275–277.
- Hiramitsu S, Morimoto S, Kato S, et al. **Transient ventricular wall thickening in acute myocarditis: a serial echocardiographic and histopathologic study.** *Jpn Circ J* 2001; 65: 863–866.
- Zagrosek A, Wassmuth R, Abdel-Aty H, et al. **Relation between myocardial edema and myocardial mass during the acute and convalescent phase of myocarditis – a CMR study.** *J Cardiovasc Magn Reson* 2008; 10: 19.
- Wittlieb-Weber CA, Harris MA and Rossano JW. **Transient left ventricular wall thickening in a 14-year-old girl with influenza A myocarditis.** *Cardiol Young* 2015; 25: 187–190.
- Schober KE. **Myocarditis.** In: Bonagura JD and Twedt DC (eds). *Kirk’s current veterinary therapy XV*. St Louis, MO: Elsevier Saunders, 2014, pp 303–308.
- Sharpe AN, Gunther-Harrington CT, Epstein SE, et al. **Cats with thermal burn injuries from California wildfires show echocardiographic evidence of myocardial thickening and intracardiac thrombi.** *Sci Rep* 2020; 10. DOI:10.1038/s41598-020-59497-z.
- Elsheikha HM, Kennedy FA, Murphy AJ, et al. **Sarcocystosis of *Sarcocystis felis* in cats.** *J Egypt Soc Parasitol* 2006; 36: 1071–1085.
- Matsuu A, Kanda T, Sugiyama A, et al. **Mitral stenosis with bacterial myocarditis in a cat.** *J Vet Med Sci* 2007; 69: 1171–1174.
- Simpson KE, Devine BC and Gunn-Moore D. **Suspected toxoplasma-associated myocarditis in a cat.** *J Feline Med Surg* 2005; 7: 203–208.
- Rolim VM, Casagrande RA, Wouters ATB, et al. **Myocarditis caused by feline immunodeficiency virus in five cats with hypertrophic cardiomyopathy.** *J Comp Path* 2016; 154: 3–8. DOI: 10.1016/j.jcpa.2015.10.180.
- Ernandes MA, Cantoni AM, Armando F, et al. **Feline coronavirus-associated myocarditis in a domestic longhair cat.** *JFMS Open Rep* 2019 10; 5. DOI: 10.1177/2055116919879256.
- Dubey JP and Carpenter JL. **Histologically confirmed clinical toxoplasmosis in cats: 100 cases (1952–1990).** *J Am Vet Med Assoc* 1993; 203: 1556–1566.
- Dubey JP, Mattix ME and Lipscomb TP. **Lesions of neonatally induced toxoplasmosis in cats.** *Vet Pathol* 1996; 33: 290–295.
- Romito G, Castagna P, Pelle NG, et al. **Retrospective evaluation of the ST segment electrocardiographic features in 180 healthy dogs.** *J Small Anim Pract* 2022; 63: 756–762.
- Häggström J, Andersson ÅO, Falk T, et al. **Effect of body weight on echocardiographic measurements in 19,866 pure-bred cats with or without heart disease.** *J Vet Intern Med* 2016; 30: 1601–1611.
- Linney CJ, Dukes-McEwan J, Stephenson HM, et al. **Left atrial size, atrial function and left ventricular diastolic function in cats with hypertrophic cardiomyopathy.** *J Small Anim Pract* 2014; 55: 198–206.
- Kittleson MD and Côté E. **The feline cardiomyopathies: 2. Hypertrophic cardiomyopathy.** *J Feline Med Surg* 2021; 23: 1028–1051.
- Dubey JP and Lappin MR. **Toxoplasmosis and neosporosis.** In: Greene CE (ed). *Infectious diseases of dog and cat*. 4th ed. St Louis, MO: Elsevier Saunders, 2012, pp 806–820.
- Rush JE, Keene BW and Eicker SW. **Endomyocardial biopsy in cats.** *Am J Vet Res* 1990; 51: 1765–1768.
- Leak D and Meghji M. **Toxoplasmic infection in cardiac disease.** *Am J Cardiol* 1979; 43: 841–849.
- Mary AS and Hamilton M. **Ventricular tachycardia in a patient with toxoplasmosis.** *Br Heart J* 1973; 35: 349–352.
- Romito G, Venturelli E, Tintorri V, et al. **Reversible myocardial injury aggravated by complex arrhythmias in three *Toxoplasma gondii*-positive dogs.** *J Vet Med Sci* 2022; 84: 289–295.
- Henry L and Beverley JK. **Experimental toxoplasmic myocarditis and myositis in mice.** *Br J Exp Pathol* 1969; 50: 230–238.
- Moise NS and Dietze AE. **Echocardiographic, electrocardiographic, and radiographic detection of cardiomegaly in hyperthyroid cats.** *Am J Vet Res* 1986; 47: 1487–1494.
- Bond BR, Fox PR, Peterson ME, et al. **Echocardiographic findings in 103 cats with hyperthyroidism.** *J Am Vet Med Assoc* 1988; 192: 1546–1549.
- Connolly DJ, Guitian J, Boswood A, et al. **Serum troponin I levels in hyperthyroid cats before and after treatment with radioactive iodine.** *J Feline Med Surg* 2005; 7: 289–300.
- Sangster JK, Panciera DL, Abbott JA, et al. **Cardiac biomarkers in hyperthyroid cats.** *J Vet Intern Med* 2014; 28: 465–472.
- Watson N, Murray JK, Fonfara S, et al. **Clinicopathological features and comorbidities of cats with mild, moderate or severe hyperthyroidism: a radioiodine referral population.** *J Feline Med Surg* 2018; 20: 1130–1137.