



Common bile duct perforation due to choledocholithiasis in a cat with gallbladder agenesis

Authors: Noguchi, Aki, Iwanaga, Tomoko, Miura, Naoki, Sogawa, Takeshi, and Fujiki, Makoto

Source: Journal of Feline Medicine and Surgery Open Reports, 9(1)

Published By: SAGE Publishing

URL: <https://doi.org/10.1177/20551169221146513>

BioOne Complete (complete.BioOne.org) is a full-text database of 200 subscribed and open-access titles in the biological, ecological, and environmental sciences published by nonprofit societies, associations, museums, institutions, and presses.

Your use of this PDF, the BioOne Complete website, and all posted and associated content indicates your acceptance of BioOne's Terms of Use, available at www.bioone.org/terms-of-use.

Usage of BioOne Complete content is strictly limited to personal, educational, and non - commercial use. Commercial inquiries or rights and permissions requests should be directed to the individual publisher as copyright holder.

BioOne sees sustainable scholarly publishing as an inherently collaborative enterprise connecting authors, nonprofit publishers, academic institutions, research libraries, and research funders in the common goal of maximizing access to critical research.



Common bile duct perforation due to choledocholithiasis in a cat with gallbladder agenesis

Aki Noguchi¹, Tomoko Iwanaga² , Naoki Miura¹, Takeshi Sogawa¹ and Makoto Fujiki¹

Journal of Feline Medicine and Surgery Open Reports
1–7

© The Author(s) 2023

Article reuse guidelines:

sagepub.com/journals-permissions

DOI: 10.1177/20551169221146513

journals.sagepub.com/home/jfmsopenreports

This paper was handled and processed by the European Editorial Office (ISFM) for publication in *JFMS*



Abstract

Case summary An 8-year-old neutered male domestic shorthair cat was presented for further investigation of anorexia, vomiting and lethargy. Abdominal ultrasonography and contrast-enhanced CT revealed choledocholithiasis with suspected bacterial peritonitis and non-visualisation of the gallbladder. During surgery, the common bile duct was noted to be perforated, and a cholelith was found in the abdominal cavity. No gallbladder was confirmed during surgery. Three months postoperatively, the cat underwent CT cholangiography and absence of the gallbladder with a vestigial duplicated gallbladder was diagnosed.

Relevance and novel information Gallbladder agenesis is extremely rare in cats, with only one previous report, but several dogs have been diagnosed based on CT cholangiography and laparoscopy. This report describes gallbladder agenesis concurrent with choledocholithiasis in an adult cat and represents the first report of CT cholangiography in a cat with gallbladder agenesis.

Keywords: Gallbladder agenesis; choledocholithiasis; bile duct perforation; CT cholangiography

Accepted: 1 December 2022

Introduction

Gallbladder agenesis is a rare congenital anomaly of the biliary tract known in humans as congenital absence of the gallbladder.¹ In animal species, this pathology has been most frequently reported in dogs.^{2–5} In cats, congenital gallbladder anomalies such as duplex gallbladder are relatively common, but gallbladder agenesis is extremely rare, with only one reported case.⁶ The diagnosis of gallbladder agenesis can be challenging, and advanced imaging such as CT cholangiography and magnetic resonance cholangiopancreatography (MRCP) are needed to diagnose gallbladder agenesis in humans.^{7–10} In veterinary medicine, CT cholangiography is a useful diagnostic tool for detecting absence of the gallbladder in dogs.² To the best of our knowledge, this is the first case report to describe the clinical and surgical findings and postoperative CT cholangiography findings from a cat showing bile duct perforation secondary to choledocholithiasis with gallbladder agenesis.

Case description

An 8-year-old neutered male domestic shorthair cat was presented with a 1-week history of anorexia, vomiting

and lethargy. On presentation, the cat weighed 5.7 kg with a body condition score of 7/9; rectal temperature was 39.2°C (102.5°F). The cat had no history of surgical procedures other than castration. Physical examination was unremarkable and it showed no signs of icterus. Mild leukocytosis was noted in the complete blood count, and mild hypoalbuminemia and elevated serum amyloid A were observed on serum biochemistry (Table 1).

Abdominal ultrasonography revealed ascites, and a hyperechoic structure that was suspicious for cholelith. No gallbladder could be identified. Ascites was collected by ultrasound-guided abdominocentesis from the caudal abdomen and identified as exudative with degenerate

¹Veterinary Teaching Hospital, Kagoshima University, Kagoshima, Japan

²Koganei Animal Medical Emergency Center, Tokyo University of Agriculture and Technology, Koganei, Tokyo, Japan

Corresponding author:

Tomoko Iwanaga DVM, PhD, Koganei Animal Medical Emergency Center, Tokyo University of Agriculture and Technology, 2-24-16 Nakamachi, Koganei, Tokyo 1848588, Japan
Email: k4622767@kadai.jp



Creative Commons Non Commercial CC BY-NC: This article is distributed under the terms of the Creative Commons

Attribution-NonCommercial 4.0 License (<https://creativecommons.org/licenses/by-nc/4.0/>) which permits non-commercial use, reproduction and distribution of the work without further permission provided the original work is attributed as specified on the SAGE and Open Access pages (<https://us.sagepub.com/en-us/nam/open-access-at-sage>).

Table 1 Complete blood count (CBC) and serum biochemistry values at the primary veterinary clinic (3 days before referral) and initial presentation (day 0)

CBC values		Serum biochemistry values							
Variable		3 days before referral	Day 0	RI	Variable	3 days before referral	RI	Day 0	RI
RBCs ($\times 10^{12}/l$)		8.22	8.08	6.54–12.20	Total protein (g/l)	64	57–89	61	57–78
Haemoglobin (g/dl)		12.4	12.0	9.8–16.2	Albumin (g/l)	25	23–39	21*	23–35
HCT (%)		44.0	42.9	30.3–52.3	Glucose (mmol/l)	10.6*	3.9–8.8	7.7	3.9–8.2
Platelets ($\times 10^9/l$)		241	439	151–600	ALT (IU/l)	<10*	12–130	26	22–84
WBCs ($\times 10^9/l$)		9.44	18.61*	2.87–17.02	ALP (IU/l)	<10*	14–111	24	0–58
Neutrophils ($\times 10^9/l$)		0.51*	14.65*	1.48–10.29	Total bilirubin (mg/dl)	<0.1	0.0–0.9		
Lymphocytes ($\times 10^9/l$)		7.26*	2.69	0.92–6.88	Total cholesterol (mmol/l)	3.6	1.7–5.8		
Monocytes ($\times 10^9/l$)		0.61	0.58	0.05–0.67	BUN (mmol/l)	10	5.7–12.9		
Eosinophils ($\times 10^9/l$)		0.80	0.63	0.17–1.57	Creatinine (μ mol/l)	106.1	70.7–212.2		
Basophils ($\times 10^9/l$)		0.26	0.06	0.01–0.26	Amylase (U/l)	1031	500–2000		
					Calcium (mmol/l)	2.0	1.95–2.8		
					Phosphorus (mmol/l)	1.3	1.0–2.4		
					Lipase (U/l)	269	100–1400		
					Sodium (mmol/l)			156	147–156
					Potassium (mmol/l)			4.1	3.4–4.6
					Chloride (mmol/l)			122*	107–120
					SAA (μ g/ml)			150.4*	<5.49

*Abnormal value
RI = reference interval; RBC = red blood cells; HCT = haematocrit; ALT = alanine transaminase; WBCs = white blood cells; ALP = alkaline phosphatase; BUN = blood urea nitrogen; SAA = serum amyloid A

neutrophils, macrophages and intracellular bacteria (cell count 71,890/ μ l). Bilirubin concentration was normal (0.1 mg/dl). Bacterial culture of ascites was positive for *Enterococcus faecalis* with scant growth and sensitivity to ampicillin and enrofloxacin.

Sixteen-slice contrast-enhanced CT (Aquilion; Canon Medical Systems) revealed two choleliths in the common bile duct (CBD) and duodenum. The diameters of the choleliths were 8 mm and 6 mm, with attenuation values of 242 Hounsfield units (HU) and 265 HU, respectively. Ascites was seen surrounding the liver, which appeared normal. No gallbladder was apparent in the cranial abdominal region.

On day 1, exploratory laparotomy was performed because bacterial peritonitis was suspected, based on examination findings. General anaesthesia was induced with propofol (7 mg/kg IV [Propoflo; Zoetis]) and maintained with sevoflurane (Sevoflo; Zoetis) in oxygen. Analgesia was provided by robenacoxib (2 mg/kg SC [Onsior; Novartis Animal Health]) and a continuous rate infusion of fentanyl (20 μ g/kg/h [Fentanyl; Terumo]) and ketamine (0.6 mg/kg/h [KETALAR; Daiichi Sankyo]) intraoperatively and buprenorphine (0.02 mg/kg IV q12h [Lepetan; Otsuka Pharmaceutical]) postoperatively. During surgery, a perforation of the CBD approximately 5 mm in diameter was identified, and a 6 mm yellow cholelith was found in the peritoneal cavity. Bile ascites (bilirubin; 3.1 mg/dl) was detected in the perihepatic space, and the distal part of the CBD from the rupture site was dilated and tortuous. No gallbladder structures or ectopic gallbladder were visualised around the gallbladder fossa (Figure 1).

Catheter insertion was attempted from the rupture in the CBD, but passage into the duodenum proved impossible, so choledochotomy of the dilated part was performed to insert a 6 F catheter; duct patency was confirmed by antegrade flushing of the CBD with saline. The rupture site and the incision in the dilated CBD were closed in a simple interrupted suture pattern with 4-0 polydioxanone (Monodiox; Alfresa Pharma) and 7-0 polydioxanone (PDSII; Ethicon) (Figure 2).

The liver appeared normal, but a liver biopsy was not performed. The cat recovered uneventfully and was eating well on day 2. The cat was discharged 6 days postoperatively and was treated with ampicillin (20 mg/kg IV q12h [Viccillin; Meiji Seika Pharma]), enrofloxacin (5 mg/kg SC q24h [Baytril; Bayer]) and prednisolone (0.5 mg/kg SC q24h [Prednisolone KS; Kyoritsu Seiyaku]), to reduce the postoperative inflammatory response from day 2. Orbifloxacin (3.5 mg/kg PO q24h [VICTAS SS; Sumitomo Pharma Animal Health]), prednisolone (0.2 mg/kg PO q24h [Predonine; Shionogi Pharma]) and ursodeoxycholic acid (8.9 mg/kg PO q24h [URSO; Mitsubishi Tanabe Pharma]) were continued for 7 days after discharge. Cholelith analysis showed a composition

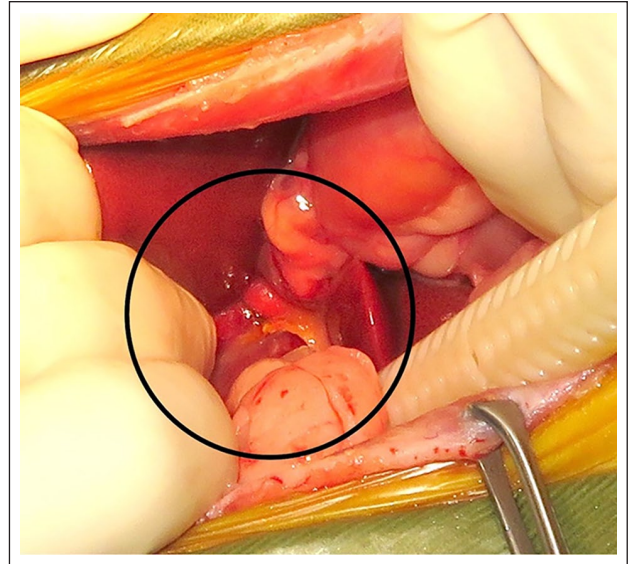


Figure 1 Intraoperative photograph: note the absence of the gallbladder around the gallbladder fossa (circle)

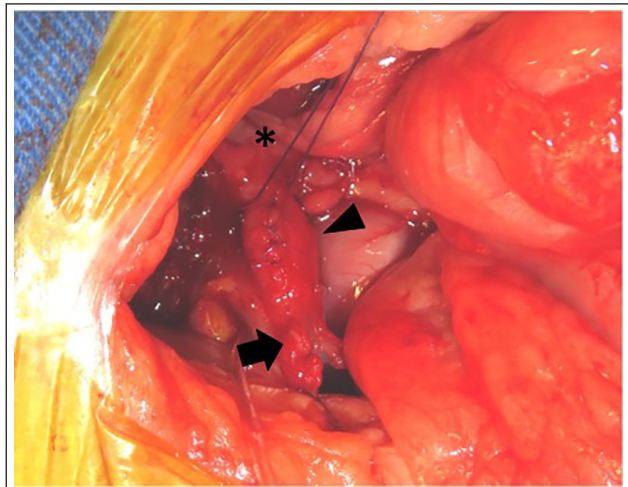


Figure 2 Rupture site (arrow) and dilated region (arrowhead) of the common bile duct (CBD). The duodenum is indicated by the asterisk. The incision at the dilated CBD had already been closed with a simple interrupted suture pattern using 7-0 polydioxanone

of 55% cholesterol, 10% calcium carbonate and 35% other material.

Three months postoperatively, CT cholangiography was performed without anaesthesia to confirm gallbladder agenesis and evaluate bile duct patency. Meglumine iotroxate (100 mgI/kg [Biliscopin DIC 50; Bayer]) was administered over a 30 min period, as described by Tanaka et al.¹¹ CT was performed 45 and 60 mins after the start of contrast medium injection and analysed using DICOM imaging software (Osirix version 3.9.2 64-bit open-source DICOM viewer; Osirix Imaging

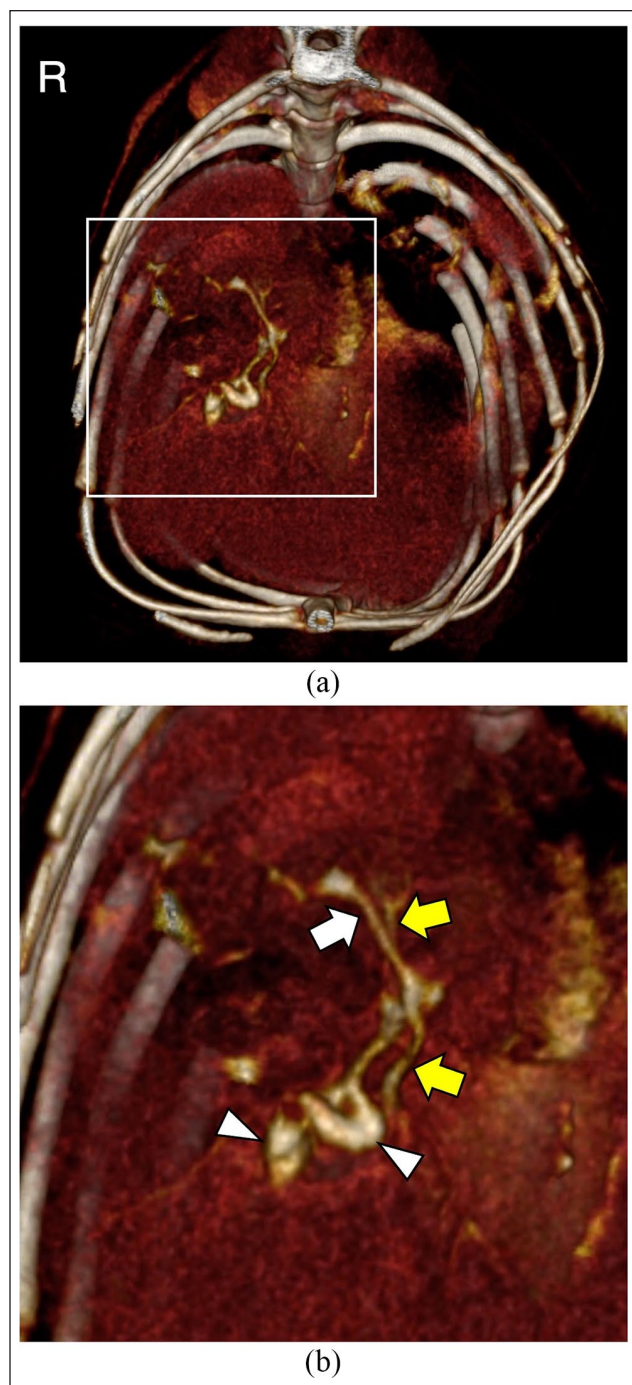


Figure 3 (a) Three-dimensional volume-rendered CT images from CT cholangiography 45 mins after contrast injection. Note that the gallbladder was absent. (b) Enlarged view of the white square area. The common bile duct (white arrow), two cystic dilations at the ends of the cystic ducts (arrowheads), and hepatic ducts (yellow arrows) were well visualised

Software). The biliary ducts were well visualised at 45mins after contrast injection, revealing intrahepatic ducts, three hepatic ducts and the CBD, but no gallbladder was visualised in the gallbladder fossa (Figure 3).

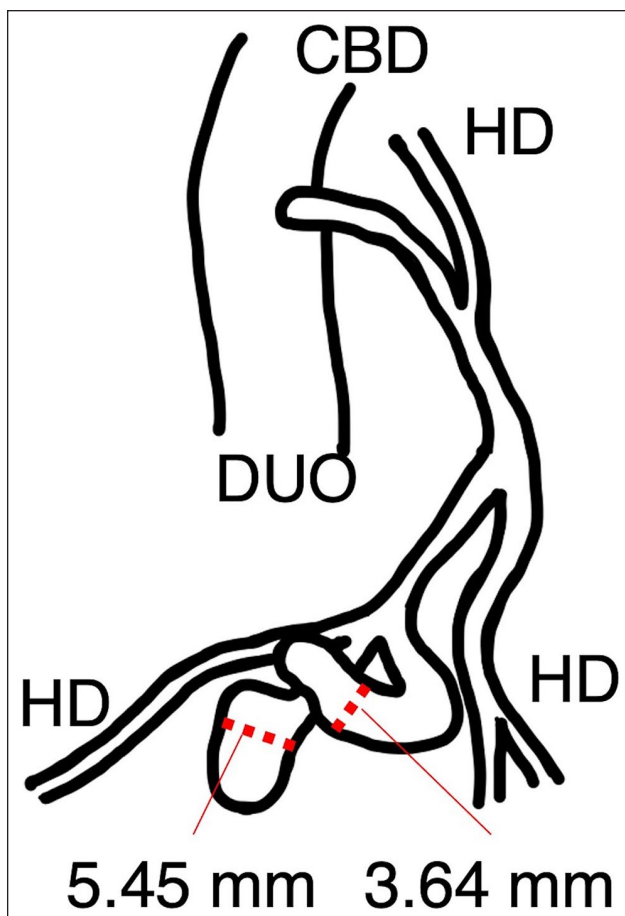


Figure 4 Diagram of the biliary tree in this cat. CBD = common bile duct; HD = hepatic duct; DUO = duodenum

In addition, two cystic dilations were found at the ends of the cystic ducts, with diameters of 5.45mm and 3.64mm, respectively. These were considered to represent vestigial remnants of a hypoplastic duplicated gallbladder. No ectopic gallbladder was identified in the abdominal cavity. A diagram of the biliary tree of the case is shown in Figure 4.

The CBD was not dilated (2.1 mm) or obstructed, and contrast medium entered into the duodenum at 45 mins. At 60 mins, more contrast medium was excreted into the duodenum, resulting in insufficient contrast enhancement in the intrahepatic bile ducts (Figure 5).

No adverse reactions to meglumine iotroxate were observed, and no recurrence of choleliths was confirmed. The cat remained alive and asymptomatic 13 months postoperatively.

Discussion

In this case, the cat initially showed mild, non-specific clinical signs associated with bacterial peritonitis, but choledocholithiasis and absence of the gallbladder was detected on ultrasonography and contrast-enhanced

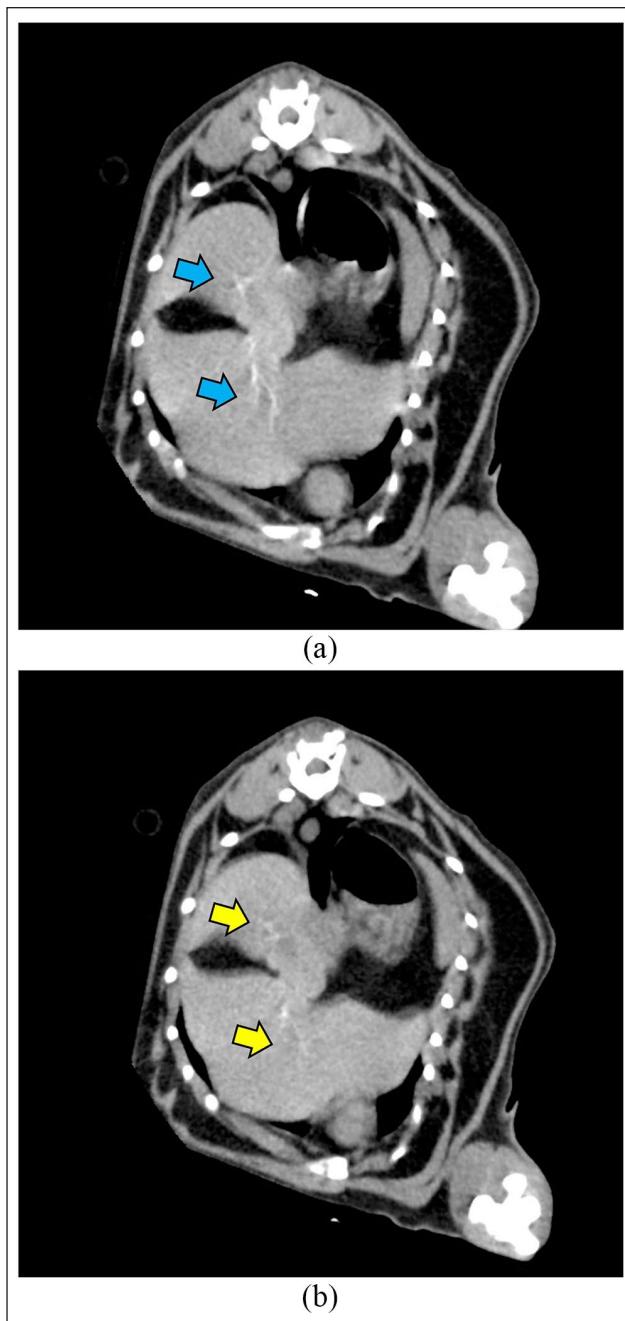


Figure 5 Transverse CT from CT cholangiography at (a) 45 mins and (b) 60 mins. Note the difference of contrast enhancement in intrahepatic bile ducts at 45 mins (blue arrows) vs 60 mins after contrast injection (yellow arrows)

CT. Exploratory laparotomy showed perforation of the CBD due to choledocholithiasis and no gallbladder was apparent in the abdominal cavity. We therefore performed CT cholangiography postoperatively to investigate the biliary tree. Based on surgical and postoperative CT cholangiography findings, we confirmed the diagnosis of gallbladder agenesis in the cat.

Gallbladder agenesis is a rare anatomical anomaly, even in humans¹ and dogs,² and is extremely rare in

cats.⁶ In humans, most patients are asymptomatic, but some show clinical signs, including abdominal pain, nausea and jaundice that is sometimes associated with intra- and/or extrahepatic cholelithiasis.^{1,12-17} Dogs with gallbladder agenesis have often been reported in the absence of clinical signs; half of canine cases are asymptomatic and a common clinical finding is increased liver enzyme activity.²⁻⁵ In cats, one previous case report documented a cat with gallbladder agenesis diagnosed from ultrasonography and exploratory laparotomy showing clinical signs in association with inflammatory bowel disease, cholangiohepatitis and pancreatitis.⁶ In our case, the cat presented with mild clinical signs associated with choledocholithiasis and septic bile peritonitis. These clinical signs may have been secondary to concurrent choledocholithiasis rather than the gallbladder agenesis itself, similar to human cases.

Choledocholithiasis is uncommon in cats and is sometimes confirmed as the underlying cause of extrahepatic bile duct obstruction.¹⁸⁻²⁰ Previous studies have reported that 25–50% of human gallbladder agenesis presented with clinical symptoms related to choledocholithiasis.^{1,12-17} In cats, congenital anomalies of the biliary tract may be a risk factor for the formation of choleliths, and clinical case reports have described cholelithiasis with congenital duplex gallbladder.^{21,22} Some congenital malformations with ductal plate malformation have been considered a risk factors for bacterial infection and cholelithiasis.²³ In the present case, we speculate that similar to human cases, gallbladder agenesis may have contributed to the formation of choleliths.

Choledochotomy for cats with obstructive choledocholithiasis or pancreatitis has been reported to offer variable prognosis.^{18,24,25} In our case, we performed choledochotomy to confirm CBD patency because a catheter was unable to be inserted through the rupture due to the tortuous CBD. We did not place a choledochal stent in this case because the CBD was markedly dilated and the risk of CBD stricture following choledochotomy was considered low.

The diagnosis of gallbladder agenesis is difficult based on ultrasound imaging alone, so imaging modalities such as endoscopic retrograde cholangiopancreatography, CT cholangiography and MRCP have been used to diagnose gallbladder agenesis in humans.^{7,13,26-30} A previous study in dogs recommended CT cholangiography for biliary tract imaging.² In our case, CT cholangiography with meglumine iotroxate was performed without anaesthesia, and the biliary tract was well visualised, confirming gallbladder agenesis and ruling out an ectopic gallbladder. CT cholangiography is useful to highlight the gallbladder and we found two cystic dilations at the ends of the cystic ducts. These were considered to represent a hypoplastic duplicated gallbladder because the two small cysts and cystic ducts joined the CBD. CT cholangiography findings in this case were

similar to findings reported from previous human^{13,14,16,31} and canine² cases of gallbladder agenesis, such as vestigial remnant, dysmorphic cystic duct and partially developed cystic duct. Adverse reactions to meglumine iotroxate in cats were not reported in a previous report,¹¹ and our case did not show any adverse effects. In humans, MRCP has been considered less invasive than CT cholangiography because MRCP can be performed without contrast medium,³² although most adverse reactions to meglumine iotroxate were minor and their incidence was low.³³ In veterinary practice, general anaesthesia is required for MRI/MRCP, whereas CT may be performed without sedation. In this case, CT cholangiography was safely performed without any side effects and may represent a feasible, less invasive technique for cats with suspected gallbladder agenesis.

The optimal scan time in CT cholangiography for cats with absence of the gallbladder is unknown. CT cholangiography has been reported for dogs with gallbladder agenesis and for cats with extrahepatic biliary obstructions,^{2,11} both performing CT at 60 mins after contrast injection. In our case, CT was performed at 45 and 60 mins after injection, and images at 45 mins provided better visualisation of the intra- and extrahepatic bile ducts. In humans, CT cholangiography has been used to detect the presence of bile leaks.³⁴ Although we performed CT cholangiography postoperatively and not at the time of CBD rupture, CT cholangiography may facilitate preoperative diagnosis of bile duct perforation in cats with specific clinical signs of septic bile peritonitis, as in this case.

Conclusions

To the best of our knowledge, this is the first report of septic bile peritonitis caused by choledocholithiasis in a cat with gallbladder agenesis, a rare congenital abnormality in cats. The formation of choleliths may be associated with gallbladder agenesis, similar to human cases. CT cholangiography should be considered to diagnose gallbladder agenesis, and meglumine iotroxate appears safe in cats with gallbladder agenesis.

Conflict of interest The authors declared no potential conflicts of interest with respect to the research, authorship, and/or publication of this article.

Funding The authors received no financial support for the research, authorship, and/or publication of this article.

Ethical approval The work described in this manuscript involved the use of non-experimental (owned or unowned) animals. Established internationally recognised high standards ('best practice') of veterinary clinical care for the individual patient were always followed and/or this work involved the use of cadavers. Ethical approval from a committee was therefore not specifically required for publication

in *JFMS Open Reports*. Although not required, where ethical approval was still obtained, it is stated in the manuscript.

Informed consent Informed consent (verbal or written) was obtained from the owner or legal custodian of all animal(s) described in this work (experimental or non-experimental animals, including cadavers) for all procedure(s) undertaken (prospective or retrospective studies). No animals or people are identifiable within this publication, and therefore additional informed consent for publication was not required.

ORCID iD Tomoko Iwanaga  <https://orcid.org/0000-0002-4127-3879>

References

- Bennion RS, Thompson JE Jr and Tompkins RK. **Agenesis of the gallbladder without extrahepatic biliary atresia.** *Arch Surg* 1988; 123: 1257–1260.
- Sato K, Sakai M, Hayakawa S, et al. **Gallbladder agenesis in 17 dogs: 2006–2016.** *J Vet Intern Med* 2018; 32: 188–194.
- Austin B, Tillson DM and Kuhnt LA. **Gallbladder agenesis in a Maltese dog.** *J Am Anim Hosp Assoc* 2006; 42: 308–311.
- Kamishina H, Katayama M, Okamura Y, et al. **Gallbladder agenesis in a Chihuahua.** *J Vet Med Sci* 2010; 72: 959–962.
- Kelly D, Moreno-Aguado B and Lamb V. **Gallbladder agenesis in a dog: clinicopathological, histopathology, and computed tomography findings.** *J Am Anim Hosp Assoc* 2019; 55. DOI: 10.5326/JAAHA-MS-6769.
- Pressel MA, Fox LE, Apley MD, et al. **Vancomycin for multi-drug resistant *Enterococcus faecium* cholangiohepatitis in a cat.** *J Feline Med Surg* 2005; 7: 317–321.
- Balakrishnan S, Singhal T, Grandy-Smith S, et al. **Agenesis of the gallbladder: lessons to learn.** *JSLs* 2006; 10: 517–519.
- Moon AM, Howe JH, McGinty KA, et al. **Gallbladder agenesis mimicking cholelithiasis in an adult.** *Radiol Case Rep* 2018; 13: 640–643.
- Pipia I, Kenchadze G, Demetrashvili Z, et al. **Gallbladder agenesis: a case report and review of the literature.** *Int J Surg Case Rep* 2018; 53: 235–237.
- Elzubeir N, Nguyen K and Nazim M. **Acute cholecystitis-like presentation in an adult patient with gallbladder agenesis: case report and literature review.** *Case Rep Surg* 2020; 2020. DOI: 10.1155/2020/8883239.
- Tanaka T, Akiyoshi H, Mie K, et al. **Drip infusion cholangiography with CT in cats.** *J Feline Med Surg* 2018; 20: 1173–1176.
- Peng Q, Zhang LJ, Gu J, et al. **Gallbladder agenesis with intrahepatic and extrahepatic bile duct stones and abnormal channel between right posterior lobe and duodenum.** *ANZ J Surg* 2017; 87. DOI: 10.1111/ans.13040.
- Kwon AH, Yanagimoto H, Matsui Y, et al. **Agenesis of the gallbladder with hypoplastic cystic duct diagnosed at laparoscopy.** *Surg Laparosc Endosc Percutan Tech* 2006; 16: 251–254.
- Kabiri H, Domingo OH and Tzarnas CD. **Agenesis of the gallbladder.** *Curr Surg* 2006; 63: 104–106.
- Afifi el-SM, Atef H and Wael B. **Agenesis of the gallbladder with primary choledochal stones.** *Med Princ Pract* 2006; 15: 379–381.

- 16 Ishida M, Egawa S, Takahashi Y, et al. **Gallbladder agenesis with a stone in the cystic duct bud.** *J Hepatobiliary Pancreat Surg* 2008; 15: 220–223.
- 17 Al-Hakkak SMM. **Agenesis of gall bladder in laparoscopic cholecystectomy – a case report.** *Int J Surg Case Rep* 2017; 39: 39–42.
- 18 Mayhew PD, Holt DE, McLearn RC, et al. **Pathogenesis and outcome of extrahepatic biliary obstruction in cats.** *J Small Anim Pract* 2002; 43: 247–253.
- 19 Gaillot HA, Penninck DG, Webster CR, et al. **Ultrasonographic features of extrahepatic biliary obstruction in 30 cats.** *Vet Radiol Ultrasound* 2007; 48: 439–447.
- 20 Griffin MA, Culp WTN, Giuffrida MA, et al. **Choledochal stenting for treatment of extrahepatic biliary obstruction in cats.** *J Vet Intern Med* 2021; 35: 2722–2729.
- 21 Woods KS, Brisson BA, Defarges AM, et al. **Congenital duplex gallbladder and biliary mucocele associated with partial hepatic cholestasis and cholelithiasis in a cat.** *Can Vet J* 2012; 53: 269–273.
- 22 Moores AL and Gregory SP. **Duplex gall bladder associated with choledocholithiasis, cholecystitis, gall bladder rupture and septic peritonitis in a cat.** *J Small Anim Pract* 2007; 48: 404–409.
- 23 Center SA, Randolph JF, Warner KL, et al. **Clinical features, concurrent disorders, and survival time in cats with suppurative cholangitis-cholangiohepatitis syndrome.** *J Am Vet Med Assoc* 2022; 260: 212–227.
- 24 Baker SG, Mayhew PD and Mehler SJ. **Choledochotomy and primary repair of extrahepatic biliary duct rupture in seven dogs and two cats.** *J Small Anim Pract* 2011; 52: 32–37.
- 25 Son TT, Thompson L, Serrano S, et al. **Surgical intervention in the management of severe acute pancreatitis in cats: 8 cases (2003–2007).** *J Vet Emerg Crit Care (San Antonio)* 2010; 20: 426–435.
- 26 Fiaschetti V, Calabrese G, Viarani S, et al. **Gallbladder agenesis and cystic duct absence in an adult patient diagnosed by magnetic resonance cholangiography: report of a case and review of the literature.** *Case Rep Med* 2009; 2009. DOI: 10.1155/2009/674768.
- 27 Tagliaferri E, Bergmann H, Hammans S, et al. **Agenesis of the gallbladder: role of clinical suspicion and magnetic resonance to avoid unnecessary surgery.** *Case Rep Gastroenterol* 2017; 10: 819–825.
- 28 Kasi PM, Ramirez R, Rogal SS, et al. **Gallbladder agenesis.** *Case Rep Gastroenterol* 2011; 5: 654–662.
- 29 Gotohda N, Itano S, Horiki S, et al. **Gallbladder agenesis with no other biliary tract abnormality: report of a case and review of the literature.** *J Hepatobiliary Pancreat Surg* 2000; 7: 327–330.
- 30 Ismail IB, Rebii S, Zenaidi H, et al. **Gallbladder agenesis in the elderly: a diagnostic challenge.** *Pan Afr Med J* 2020; 37: 259.
- 31 Pierro A, Martucci M, Maselli G, et al. **Agenesis of the gallbladder with the presence of a small dysmorphic cyst: role of magnetic resonance cholangiopancreatography.** *J Clin Imaging Sci* 2012; 2: 17.
- 32 Hyodo T, Kumano S, Kushihata F, et al. **CT and MR cholangiography: advantages and pitfalls in perioperative evaluation of biliary tree.** *Br J Radiol* 2012; 85: 887–896.
- 33 Persson A, Dahlström N, Smedby O, et al. **Three-dimensional drip infusion CT cholangiography in patients with suspected obstructive biliary disease: a retrospective analysis of feasibility and adverse reaction to contrast material.** *BMC Med Imaging* 2006; 6. DOI: 10.1186/1471-2342-6-1.
- 34 Dinkel HP, Moll R, Gassel HJ, et al. **Helical CT cholangiography for the detection and localization of bile duct leakage.** *AJR Am J Roentgenol* 1999; 173: 613–617.