

TWO CASES OF ATYPICAL MYCOBACTERIOSIS CAUSED BY MYCOBACTERIUM SZULGAI ASSOCIATED WITH MORTALITY IN CAPTIVE AFRICAN ELEPHANTS (LOXODONTA AFRICANA)

Authors: Lacasse, Claude, Terio, Karen, Kinsel, Michael J., Farina, Lisa L., Travis, Dominic A., et al.

Source: Journal of Zoo and Wildlife Medicine, 38(1) : 101-107

Published By: American Association of Zoo Veterinarians

URL: <https://doi.org/10.1638/06-051.1>

BioOne Complete (complete.BioOne.org) is a full-text database of 200 subscribed and open-access titles in the biological, ecological, and environmental sciences published by nonprofit societies, associations, museums, institutions, and presses.

Your use of this PDF, the BioOne Complete website, and all posted and associated content indicates your acceptance of BioOne's Terms of Use, available at www.bioone.org/terms-of-use.

Usage of BioOne Complete content is strictly limited to personal, educational, and non - commercial use. Commercial inquiries or rights and permissions requests should be directed to the individual publisher as copyright holder.

BioOne sees sustainable scholarly publishing as an inherently collaborative enterprise connecting authors, nonprofit publishers, academic institutions, research libraries, and research funders in the common goal of maximizing access to critical research.

TWO CASES OF ATYPICAL MYCOBACTERIOSIS CAUSED BY *MYCOBACTERIUM SZULGAI* ASSOCIATED WITH MORTALITY IN CAPTIVE AFRICAN ELEPHANTS (*LOXODONTA AFRICANA*)

Claude Lacasse, D.V.M., Karen Terio, D.V.M., Ph.D., Dipl. A.C.V.P., Michael J. Kinsel, D.V.M., Dipl. A.C.V.P., Lisa L. Farina, D.V.M., Dipl. A.C.V.P., Dominic A. Travis, D.V.M., M.S., Rena Greenwald, M.D., Konstantin P. Lyashchenko, Ph.D., Michele Miller, D.V.M., Ph.D., and Kathryn C. Gamble, D.V.M., M.S., Dipl. A.C.Z.M.

Abstract: *Mycobacterium szulgai* was associated with mortality in two captive African elephants (*Loxodonta africana*) housed at Lincoln Park Zoo. The first elephant presented with severe, acute lameness of the left rear limb. Despite extensive treatments, the animal collapsed and died 13 mo after initial presentation. Necropsy revealed osteomyelitis with loss of the femoral head and acetabulum and pulmonary granulomas with intralesional *M. szulgai*. The second elephant collapsed during transport to another institution with no premonitory clinical signs. This animal was euthanized because of prolonged recumbency. Granulomatous pneumonia with intralesional *M. szulgai* was found at necropsy. Two novel immunoassays performed on banked serum samples detected antibody responses to mycobacterial antigens in both infected elephants. It was not possible to determine when the infection was established or how the elephants were infected. When reviewing the epidemiology of this organism in humans, however, transmission between elephants seemed unlikely because human-to-human transmission of this organism has never been reported and a third elephant in the herd was not affected. In addition to *Mycobacterium bovis* and *Mycobacterium tuberculosis*, atypical mycobacterial organisms need to be considered potentially pathogenic in elephants.

Key words: African elephant, *Loxodonta africana*, atypical mycobacteriosis, *Mycobacterium szulgai*, osteoarthritis, pneumonia.

CASE REPORT

Mycobacteriosis, particularly infections with *Mycobacterium tuberculosis* and *Mycobacterium bovis*, is an important health issue in zoological collections. Zoos are a particular public health concern because of the close contact between mycobacteriosis-susceptible animals and humans, specifically animal handlers and visitors.²⁷ Evidence of *M. tuberculosis* transmission between humans and elephants, confirmed by DNA fingerprinting, has been reported.²¹ Between 1994 and June 2005, 34 cases of mycobacteriosis were confirmed in elephants in the United States.²³ To date, most reported cases have occurred in captive Asian elephants (*Elephas maximus*) with the majority exhibiting no clinical

signs suggestive of mycobacterial infection.²³ Isolation of *Mycobacterium avium* and other nontuberculous *Mycobacterium* spp. from elephant trunk wash samples is common, but most of these organisms have not been associated with clinical disease.²² However, an atypical mycobacterial organism (*Mycobacterium elephantis* sp. n.)³⁰ has been cultured from lung lesions in an elephant with fatal chronic respiratory disease. This same organism was cultured from a human patient without any contact with animals, including elephants.²⁹ Until this current case report, no other atypical mycobacterial fatalities have been reported in elephants. *Mycobacterium szulgai* has been reported previously from the trunk wash of one elephant submitted to the National Veterinary Services Laboratory (NVSL).²⁸ The following case report details fatal complications of an atypical mycobacterial infection caused by *M. szulgai* in two of the three captive African elephants (*Loxodonta africana*) housed at a single institution (Lincoln Park Zoo [LPZ]) between 2003 and 2005.

Elephant 1

In September 2003, a 34-yr-old, 4,673-kg, reproductively inactive female African elephant presented with an acute, non-weight-bearing lameness of the left rear limb with subsequent swelling of the stifle area. Diagnostic procedures over the next few

From Lincoln Park Zoo, 2001 North Clark Street, Chicago, Illinois 60614, USA (Lacasse, Travis, Gamble); University of Illinois Zoological Pathology Program, Building 101, Room 0745, 2160 South First Avenue, Maywood, Illinois 60153, USA (Terio, Kinsel, Farina); Chembio Diagnostic Systems Inc., 3661 Horseblock Road, Medford, New York 11763, USA (Greenwald, Lyashchenko); and Disney's Animal Programs, Lake Buena Vista, Florida 32830, USA (Miller). Present address (Farina): University of Florida, College of Veterinary Medicine, Department of Infectious Diseases and Pathology, P.O. Box 100880, Gainesville, Florida 32611, USA. Correspondence should be addressed to Dr. Lacasse.

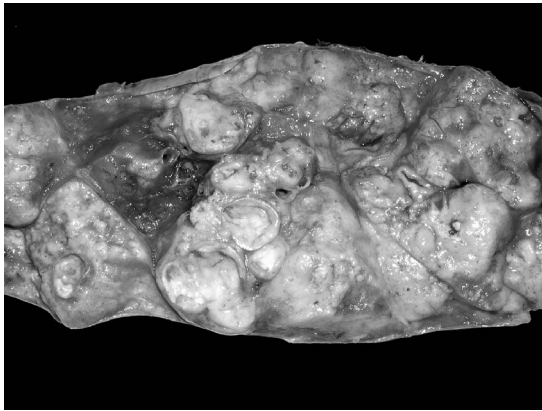


Figure 2. Granulomatous pneumonia with multiple thick-walled granulomas in an African elephant (elephant 1) as a result of *M. szulgai* infection.

ized by a thick capsule and central yellow-green viscous, often mineralized, material (Fig. 2). Intervening regions of the lung between some of the granulomas were consolidated. Acid-fast stained impression smears from both the coxofemoral and pulmonary lesions contained large numbers of acid-fast bacteria (acid-fast stain, Remel, Lenexa, Kansas 66215, USA). Histologically, chronic, granulomatous osteomyelitis of the left pelvis was noted, with regional myositis and cellulitis. Multiple coalescing granulomas with intervening granulomatous pneumonia as well as granulomatous aortic, tracheobronchial, and mediastinal lymphadenitis were also observed. Pelvic, pulmonary, and lymph node lesions contained moderate numbers of acid-fast positive bacilli. Ulcerative and necrotizing plantar pododermatitis of the right rear pes was also present.

Pulmonary and joint tissue samples were submitted to three different laboratories: National Jewish Medical Center (NJMC), NVSL, and Chicago Department of Public Health (CDPH). While awaiting confirmatory culture results, quarantine procedures were established for the remaining two elephants and supplemental testing was conducted to screen all zoo personnel in close contact with the elephant or who had participated in the necropsy. Personnel were administered a Mantoux skin test by the CDPH and all those tested showed no new positive reactors to mycobacterial antigens. *Mycobacterium szulgai* was cultured and identified at CDPH by high-performance liquid chromatography (HPLC) followed by gas chromatography and biochemical testing. CDPH then submitted the samples to the Centers for Disease Control and Prevention (CDC) for confirmation by 16S ribosomal RNA

(rRNA) gene sequencing. *Mycobacterium szulgai* was also cultured and identified by HPLC and 16S rRNA gene sequencing at NJMC and NVSL. Nucleic amplification direct test for *M. tuberculosis* complex (MTD) was negative at CDPH and NJMC. Polymerase chain reaction (PCR) for *M. tuberculosis* complex (primer IS6110),⁶ *M. avium* (primer 16S rRNA),³⁵ and *M. avium* subsp. *paratuberculosis* (primer IS900)³⁴ was negative at NVSL.

Elephant 2

A 55-yr-old, 4,140-kg, reproductively inactive female African elephant, housed at the same facility as elephant 1, was considered in good health despite chronic arthritis, most severe on the left forelimb and right rear limb. On the morning of 17 January 2005, the elephant was found in left lateral recumbency, but responsive. This particular elephant had not been observed in lateral recumbency since arrival at LPZ in 2003. Multiple efforts, including the use of ropes and a forklift, were made in the next hours to encourage the elephant to stand. Euthanasia was elected as the most humane resolution because 12 hr of recumbency were documented by an overnight videotaping and the elephant demonstrated apparent inability to stand despite assistance. Gross necropsy revealed moderate degenerative joint disease and irregular tooth wear and loss. A few small ($4 \times 3 \times 2$ cm) mineralized pulmonary granulomas were identified but not thought to be clinically significant. Histologically, granulomas were composed of central variably mineralized debris and few macrophages encompassed by a thick fibrous capsule. Impression smears and histologic sections of pulmonary granulomas were negative for any acid-fast bacteria. The only additional histologic lesion of note was chronic interstitial nephritis. MTD on pulmonary tissue was negative at two laboratories (CDPH and NJMC) and PCR at NVSL was also negative. *Mycobacterium smegmatis* was isolated from a single pulmonary granuloma by one laboratory (NVSL) which was considered an incidental finding.

Elephant 3

A 35-yr-old, 3,568-kg, reproductively inactive female African elephant was transferred to another institution 3 mo after the death of elephant 2 to provide appropriate social structure. No previous clinical signs of illness had been observed, except for intermittent colic episodes over the preceding month that had resolved with laxatives. The animal collapsed during transport and became sternally recumbent. Because of the history, the animal was conservatively treated for presumptive colic in

transport. Upon arrival at the receiving institution, the elephant received 9 hr of intensive supportive efforts including sling support, hydrotherapy, and i.v. fluids. The elephant was ultimately euthanized because of prolonged recumbency and the inability to resume standing.

At necropsy, the caudal one-third of both lungs contained numerous, often coalescing, up-to-10-cm-diameter granulomas similar to those in elephant 1. Deep cervical, thoracic, and mediastinal lymph nodes were moderately enlarged and firm. Impression smears of affected lung and lymph nodes were negative for acid-fast bacilli. Histologically, pulmonary granulomas were similar to those in elephant 1; however, only rare intralesional acid-fast bacilli were noted. A single thoracic lymph node contained a granuloma without histologically evident acid-fast bacilli. Other enlarged lymph nodes had diffuse fibrosis. Additional histologic lesions included adrenal cortical hyperplasia and chronic interstitial nephritis. *Mycobacterium szulgai* was cultured and identified by HPLC and 16s rRNA gene sequencing from the pulmonary lesions at NVSL and NJMC, but not at CDPH. MTD on pulmonary tissue was only performed by NJMC and was negative. PCR at NVSL was also negative.

Serologic testing

Two novel antibody detection technologies, rapid lateral-flow test (ElephantTB STAT-PAK[®] kit, Medford, New York 11763, USA) followed by a confirmatory test, multiantigen print immunoassay (MAPIA, Medford, New York 11763, USA), were used to analyze serial elephant serum samples. These membrane-based immunoassays using multiple mycobacterial antigens were performed as previously described.^{15–17} Sera from the three elephants at LPZ, as well as from their previous institution (San Diego Wild Animal Park [SDWAP]), were submitted to ChemBio Diagnostic Systems, Inc. (Medford, New York 11763, USA). Three banked samples from elephant 1 collected approximately 1 mo (LPZ), 6 mo (LPZ), and 4.5 yr (SDWAP) before death, two samples from elephant 2 collected approximately 3 wk (LPZ) and 2.5 yr (SDWAP) prior to euthanasia; and two samples from elephant 3 collected approximately 7 mo (LPZ) and 8 yr (SDWAP) prior to euthanasia were tested. Elephant 3 had not been compliant with venipuncture for many months before death. Serologic data are summarized in Table 2. Results obtained by the rapid lateral-flow test revealed that elephants 1 and 3 were antibody positive 1 mo and 7 mo before death, respectively, whereas elephant 2 was antibody negative for all samples. Importantly, elephants 1 and

Table 2. Summary of serologic data obtained from the three elephants at Lincoln Park Zoo (LPZ), as well as from their previous institution (San Diego Wild Animal Park [SDWAP]).

Sample ID ^a	Rapid test ^b	MAPIA ^c
Elephant 1, 4.5 yr, SDWAP	Negative	Negative
Elephant 1, 6 mo, LPZ	Negative	Negative
Elephant 1, 1 mo, LPZ	Positive	Positive
Elephant 2, 2.5 yr, SDWAP	Negative	Negative
Elephant 2, 3 wk, LPZ	Negative	Negative
Elephant 3, 8 yr, SDWAP	Negative	Negative
Elephant 3, 7 mo, LPZ	Positive	Positive

^a Elephant ID, time prior to death, source of sample.

^b ElephantTB STAT-PAK[®] kit.

^c MAPIA, multiantigen print immunoassay.

3 tested negative 4.5 yr and 8 yr before death, respectively. Further, MAPIA using a panel of 13 defined mycobacterial antigens confirmed these results and demonstrated that IgG antibody against MPB83 protein (used as a single recombinant antigen and as a fusion protein with Acr1) and *M. bovis* culture filtrate could be detected in the most recent serum samples from elephants 1 and 3 (LPZ), but not in earlier samples (SDWAP) or in sera from elephant 2 (LPZ and SDWAP) (Fig. 3). This antigen recognition pattern, essentially identical in elephants 1 and 3, was different from all those found previously by MAPIA in elephants with culture-confirmed tuberculosis due to *M. tuberculosis* or *M. bovis*.¹⁵

DISCUSSION

Mycobacterium szulgai is an uncommon atypical *Mycobacterium* sp. that is usually isolated from pathologic lesions in humans and was first identified in 1972.^{19,33} The lungs are the main site of pathologic lesions in humans and several cases have occurred in patients with acquired immunodeficiency syndrome.^{14,32,33} *Mycobacterium szulgai* infection in humans most frequently produces thin-walled, cavitated pulmonary abscesses resembling tuberculosis.⁵ Other documented sites of infection include skin, bone, and tendon sheath, the latter causing a carpal tunnel syndrome.^{3,9,10,14,18,20,31,32} Intraoperative contamination from ice water has led to *M. szulgai* keratitis after laser-assisted ophthalmic surgeries.⁸ A case of disseminated disease in a previously healthy young human has also been reported.⁷ No evidence of human-to-human transmission has been documented and cases are believed to originate from environmental sources.³³ The natural reservoir of the organism is unknown, but the organism has been cultured from a snail, African

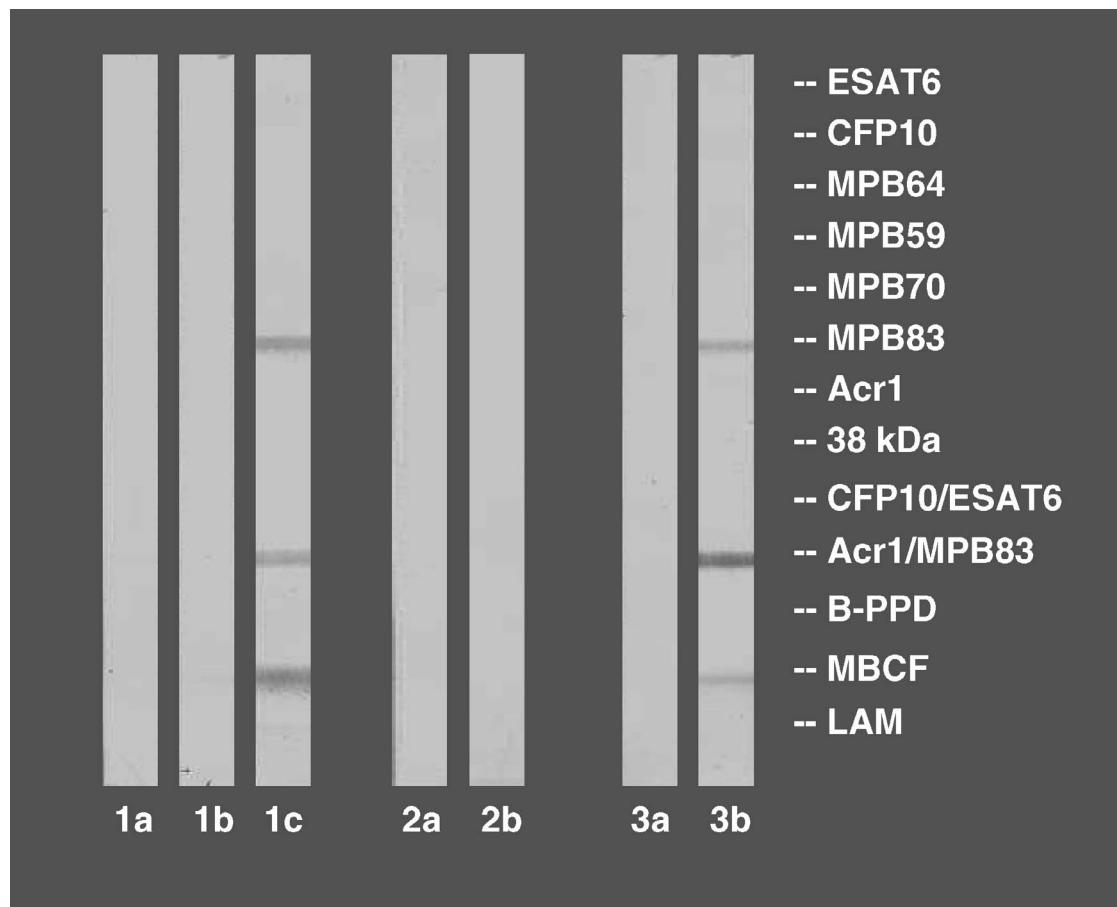


Figure 3. MAPIA results of serum samples from elephants 1, 2, and 3. Of the 13 antigens tested, visible bands on strips 1c and 3b demonstrate the presence of antibodies in the latest serum samples of elephants 1 and 3 against the corresponding antigens (MPB83 protein, fusion of MPB83 and Acr1, and *M. bovis* culture filtrates). 1a. Serum sample from elephant 1 collected 4.5 yr before death. 1b. Serum sample from elephant 1 collected 6 mo before death. 1c. Serum sample from elephant 1 collected 1 mo before death. 2a. Serum sample from elephant 2 collected 2.5 yr before euthanasia. 2b. Serum sample from elephant 2 collected 3 wk before euthanasia. 3a. Serum sample from elephant 3 collected 8 yr before euthanasia. 3b. Serum sample from elephant 3 collected 7 mo before euthanasia.

clawed frogs (*Xenopus tropicalis*), and tropical fish.^{1,2,4} Previous reports suggest an association of the bacteria with water in swimming pools and fish tanks.^{1,33} No standard recommendation for the treatment of *M. szulgai* infection in humans currently exists although the standard mycobacterial treatment of ethambutol–rifampin–isoniazid was reported with a low rate of relapses and sterilization of sputum cultures within a mean of 3 mo.⁴ In vitro sensitivity was not evaluated for the strains in the current report.

Marked contrast was observed in organism numbers between the two infected elephants. In elephant 1, a large number of organisms were readily observed cytologically and histologically, whereas in elephant 3, only rare organisms were detected,

and only histologically. Although differences in the efficiency of cell-mediated immunity between the two elephants or, perhaps, differences in bacterial virulence existed, it may have simply been that the elephants were infected for different durations with the same organism. Possibly different strains of *M. szulgai* were acquired by the two animals but this seems unlikely with the identical genetic fingerprinting although different infective doses would be possible.

Osteomyelitis in the hip of elephant 1 is presumed to have developed secondary to hematogenous spread from the lungs. It is suspected that the acute lameness resulted from a pathologic coxo-femoral fracture secondary to osteomyelitis. Alternatively, although considered less likely, a trau-

matic fracture could have occurred with subsequent bacterial inoculation as a result of increased blood flow to a site of repair. Because of the chronicity of the pulmonary lesions, it was not possible to determine when initial infection occurred or to identify the source of infection. Prevalence of *M. szulgai* in the natural habitat or captive environment of elephants has not been previously documented. The epidemiology of this organism in elephants is unknown, but in humans direct transmission has not been reported. Therefore, transmission between elephants also seems unlikely and it is speculated that the two animals became infected from the same environmental source. It is possible that one animal could have acquired infection and shed the organisms to the environment, causing subsequent environmental exposure of the second animal. It is unknown why elephant 2 was not infected with the bacteria, especially because of suspected increased susceptibility from a geriatric status. All three elephants had been housed together for over 20 yr.

In 1997, the National Tuberculosis Working Group for Zoo and Wildlife Species partnered with the U.S. Department of Agriculture (USDA) to formulate the "Guidelines for the Control of Tuberculosis in Elephants," with revisions in 2000 and 2003.²⁶ These guidelines outline criteria for the testing, surveillance, and treatment of mycobacteriosis in elephants. The guidelines recommend annual monitoring of elephants by mycobacterial culture of three direct trunk washes collected over 1 wk. After death of elephant 1, serial trunk washes were obtained from the two remaining elephants in the collection and were determined to be negative by mycobacterial culture. The annual serial trunk washes for all three elephants performed 6 mo prior to the death of elephant 1 had also been negative. The USDA advisory document also strongly recommends sample submission for ancillary testing, using methods such as enzyme-linked immunosorbent assay and MAPIA, especially when clinical cases are suspected.^{12,13,15–17,24,25}

The serologic results were obtained 2 mo before *M. szulgai* was isolated from tissues of elephant 1 and 3 mo before elephant 3 was euthanized. Based on the unique antigen recognition pattern, found by MAPIA to be similar in both elephants, it had been predicted that the fatal disease in elephant 1 could have been caused by a nontuberculous mycobacterial species, such as *Mycobacterium kansasii* (known to produce MPB83 antigen), and that elephant 3, but not elephant 2, might have been infected with the same mycobacterial organism.

The unique positive serologic results in elephant 1 and 3 from the latest LPZ samples and the neg-

ative results from the earlier SDWAP samples indicate the possibility that the elephants were exposed to *M. szulgai* after departure from their original institution. However, the sensitivity of these tests for this species remains unknown and false negatives may have occurred. Regardless of the source of infection, these cases demonstrate the fatal consequences of atypical *Mycobacterium* infection in African elephants. The serologic results, irrespective of uncertainties in specificity and sensitivity, suggested infection with an atypical mycobacterial organism months before culture results were available and were therefore an important diagnostic tool in these cases. Ancillary diagnostics are demonstrating great potential in detecting mycobacterial infection in elephants and should be considered in both preshipment and quarantine testing.

Acknowledgments: We thank the curatorial and keeper staff at LPZ for their dedication to the care of these three elephants, Susan Lippold (CDPH) and Sue Kubba (Illinois Department of Public Health) for diagnostic assistance, as well as the veterinary team of SDWAP, the staff of Hogle Zoo, and Dr. Jaime Landolfi (Zoological Pathology Program) for their help with these cases.

LITERATURE CITED

1. Abalain-Colloc, M. L., D. Guillerme, M. Salaun, S. Gouriou, V. Vincent, and B. Picard. 2003. *Mycobacterium szulgai* isolated from a patient, a tropical fish, and aquarium water. *Eur. J. Clin. Microbiol. Infect. Dis.* 22: 768–769.
2. Chai, N., L. Deforges, W. Sougakoff, C. Truffot-Pernot, A. De Luze, B. Demeneix, M. Clement, and M. Bomsel. 2006. *Mycobacterium szulgai* infection in a captive population of African clawed frogs (*Xenopus tropicalis*). *J. Zoo Wildl. Med.* 37: 55–57.
3. Cross, G. M., M. A. Guill, and J. K. Aton. 1985. Cutaneous *Mycobacterium szulgai* infection. *Arch. Dermatol.* 121: 247–249.
4. Davidson, P. T. 1976. *Mycobacterium szulgai*: a new pathogen causing infection of the lung. *Chest* 69: 799–801.
5. Dylewski, J. S., H. M. Zackon, A. H. Latour, and G. R. Berry. 1987. *Mycobacterium szulgai*: an unusual pathogen. *Rev. Infect. Dis.* 9: 578–580.
6. Eisenach, K. D., M. D. Cave, J. H. Bates, and J. T. Crawford. 1990. Polymerase chain reaction amplification of a repetitive DNA sequence specific for *Mycobacterium tuberculosis*. *J. Infect. Dis.* 161: 977–981.
7. Gur, H., S. Porat, H. Haas, Y. Naparstek, and M. Eliakim. 1984. Disseminated mycobacterial disease caused by *Mycobacterium szulgai*. *Arch. Intern. Med.* 144: 1861–1863.
8. Holmes, G. P., G. B. Bond, R. C. Fader, and S. F. Fulcher. 2002. A cluster of cases of *Mycobacterium szul-*

- gai* keratitis that occurred after laser-assisted in situ keratomileusis. Clin. Infect. Dis. 34: 1039–1046.
9. Horusitzky, A., X. Puechal, D. Dumont, T. Begue, M. Robineau, and M. Boissier. 2000. Carpal tunnel syndrome caused by *Mycobacterium szulgai*. J. Rheumatology 27: 1299–1302.
 10. Hurr, H., and T. Sorg. 1998. *Mycobacterium szulgai* osteomyelitis. J. Infect. 37: 191–192.
 11. International Species Information System (ISIS). 2002. ISIS physiological data reference values for African elephants (*Loxodonta africana*). Eagan, Minnesota 55121. CD-ROM.
 12. Larsen, R. S., M. Kay, J. Triantis, and M. D. Salman. 2005. Update on serologic detection of *Mycobacterium tuberculosis* infection in Asian elephants. Proc. Am. Assoc. Zoo Vet. 2005: 62.
 13. Larsen, R. S., M. D. Salman, S. K. Mikota, R. Isaza, R. J. Montali, and J. Triantis. 2000. Evaluation of a multiple-antigen enzyme-linked immunosorbent assay for detection of *Mycobacterium tuberculosis* infection in captive elephants. J. Zoo Wildl. Med. 31: 291–302.
 14. Luque, A. E., D. Kaminski, R. Reichman, and D. Hardy. 1998. *Mycobacterium szulgai* osteomyelitis in an AIDS patient. Scand. J. Infect. Dis. 30: 88–91.
 15. Lyashchenko, K. P., R. Greenwald, J. Esfandiari, J. H. Olsen, R. Ball, G. Dumonceaux, F. Dunker, C. Buckley, M. Richard, S. Murray, J. B. Payeur, P. Andersen, J. M. Pollock, S. Mikota, M. Miller, D. Sofranko, and W. R. Waters. 2006. Tuberculosis in elephants: antibody responses to defined antigens of *Mycobacterium tuberculosis*, potential for early diagnosis, and monitoring treatment. Clin. Vaccine Immunol. 13: 722–732.
 16. Lyashchenko, K., M. Miller, and W. R. Waters. 2005. Application of MAPIA (multiple-antigen print immunoassay) and rapid lateral flow technology for tuberculosis testing of elephants. Proc. Am. Assoc. Zoo Vet. 2005: 64–65.
 17. Lyashchenko, K. P., M. Singh, R. Colangeli, and M. L. Gennaro. 2000. A multi-antigen print immunoassay for the serological diagnosis of infectious diseases. J. Immunol. Methods 242: 91–100.
 18. Maloney, J. M., C. R. Gregg, D. S. Stephens, F. A. Manian, and D. Rimland. 1987. Infections caused by *Mycobacterium szulgai* in humans. Rev. Infect. Dis. 9: 1120–1126.
 19. Marks, J., P. A. Jenkins, and M. Tsukamura. 1972. *Mycobacterium szulgai*: a new pathogen. Tubercle 53: 210.
 20. Merlet, C., S. Aberrane, F. Chilot, and J. Laroche. 2000. Carpal tunnel syndrome complicating hand flexor tenosynovitis due to *Mycobacterium szulgai*. Joint Bone Spine 67: 247–248.
 21. Michalak, K., C. Austin, S. Diesel, J. M. Bacon, P. Zimmerman, and J. N. Maslow. 1998. *Mycobacterium tuberculosis* infection as a zoonotic disease: transmission between humans and elephants. Emerg. Infect. Dis. 4: 283–287.
 22. Mikota, S. K., R. S. Larsen, and R. J. Montali. 2000. Tuberculosis in elephants in North America. Zoo Biol. 19: 393–403.
 23. Mikota, S. K., and M. Miller. 2005. Elephant tuberculosis research workshop. Orlando, Florida.
 24. Mikota, S. K., L. Peddie, J. Peddie, R. Isaza, F. Dunker, G. West, W. Lindsay, R. S. Larsen, M. D. Salman, D. Chatterjee, J. Payeur, D. Whipple, C. Thoen, D. S. Davis, C. Sedgwick, R. J. Montali, M. Ziccardi, and J. Maslow. 2001. Epidemiology and diagnosis of *Mycobacterium tuberculosis* in captive Asian elephants (*Elephas maximus*). J. Zoo Wildl. Med. 32: 1–16.
 25. Montali, R. J., L. H. Spelman, R. C. Cambre, D. Chatterjee, and S. K. Mikota. 1998. Factors influencing interpretation of indirect testing methods for tuberculosis in elephants. Proc. Am. Assoc. Zoo Vet. 1998: 109–112.
 26. National Tuberculosis Working Group for Zoo and Wildlife Species. 2000. Guidelines for the control of tuberculosis in elephants. U.S. Department of Agriculture, Animal and Plant Inspection Services. Ames, Iowa 50011.
 27. Oh, P., R. Granich, J. Scott, B. Sun, M. Joseph, C. Stringfield, S. Thisdell, J. Staley, D. Workman-Malcolm, L. Borenstein, E. Lehnkering, P. Ryan, J. Soukup, A. Nitta, and J. Flood. 2002. Human exposure following *Mycobacterium tuberculosis* infection of multiple animal species in a metropolitan zoo. Emerg. Infect. Dis. 8: 1290–1293.
 28. Payeur, J. B., J. L. Jarnagin, J. G. Marquardt, and D. L. Whipple. 2002. Mycobacterial isolations in captive elephants in the United States. Ann. N.Y. Acad. Sci. 969: 256–258.
 29. Potters, D., M. Seghers, G. Muyldermans, D. Pierard, A. Naessens, and S. Lauwers. 2003. Recovery of *Mycobacterium elephantis* from sputum of a patient in Belgium. J. Clin. Microbiol. 41: 1344.
 30. Shojaei, H., J. G. Magee, R. Freeman, M. Yates, N. U. Horadagoda, and M. Goodfellow. 2000. *Mycobacterium elephantis* sp. nov., a rapidly growing non-chromogenic *Mycobacterium* isolated from an elephant. Int. J. Syst. Evol. Microbiol. 50: 1817–1820.
 31. Stratton, C. W., D. B. Phelps, and L. B. Reller. 1978. Tuberculoid tenosynovitis and carpal tunnel syndrome caused by *Mycobacterium szulgai*. Amer. J. Med. 65: 349–351.
 32. Tappe, D., P. Langmann, M. Zilly, H. Klinker, B. Schmausser, and M. Frosch. 2004. Osteomyelitis and skin ulcers caused by *Mycobacterium szulgai* in an AIDS patient. Scand. J. Infect. Dis. 36: 883–885.
 33. Tortoli, E., G. Besozzi, C. Lacchini, V. Penati, M. T. Simonetti, and S. Emler. 1998. Pulmonary infection due to *Mycobacterium szulgai*, case report and review of the literature. Eur. Respir. J. 11: 975–977.
 34. Vary, P. H., P. R. Andersen, and E. Green. 1990. Use of highly specific DNA probes and the polymerase chain reaction to detect *Mycobacterium paratuberculosis* in John's disease. J. Clin. Microbiol. 28: 933–937.
 35. Wilton, S., and D. Cousins. 1992. Detection and identification of multiple mycobacterial pathogens by DNA amplification in a single tube. PCR Meth. Appl. 1: 269–273.

Received for publication 10 June 2006