

## **A New Coccidian (Apicomplexa: Eimeriidae) in the Critically Endangered Central American River Turtle (*Dermatemys Mawii*) in Belize**

Authors: Jacobson, Elliott R., Ossiboff, Robert J., Paquet-Durand, Isabelle, Childress, April L., Barrett, Heather, et al.

Source: Journal of Parasitology, 108(1) : 93-99

Published By: American Society of Parasitologists

URL: <https://doi.org/10.1645/21-44>

---


BioOne Complete ([complete.BioOne.org](https://complete.BioOne.org)) is a full-text database of 200 subscribed and open-access titles in the biological, ecological, and environmental sciences published by nonprofit societies, associations, museums, institutions, and presses.

Your use of this PDF, the BioOne Complete website, and all posted and associated content indicates your acceptance of BioOne's Terms of Use, available at [www.bioone.org/terms-of-use](https://www.bioone.org/terms-of-use).

Usage of BioOne Complete content is strictly limited to personal, educational, and non - commercial use. Commercial inquiries or rights and permissions requests should be directed to the individual publisher as copyright holder.

---

BioOne sees sustainable scholarly publishing as an inherently collaborative enterprise connecting authors, nonprofit publishers, academic institutions, research libraries, and research funders in the common goal of maximizing access to critical research.



## A NEW COCCIDIAN (APICOMPLEXA: EIMERIIDAE) IN THE CRITICALLY ENDANGERED CENTRAL AMERICAN RIVER TURTLE (*DERMATEMYS MAWII*) IN BELIZE

Elliott R. Jacobson<sup>1</sup>, Robert J. Ossiboff<sup>1</sup>, Isabelle Paquet-Durand<sup>2</sup>, April L. Childress<sup>1</sup>, Heather Barrett<sup>3</sup>, Jacob Marlin<sup>3</sup>, Chris T. McAllister<sup>4</sup>, and Heather D. S. Walden<sup>1</sup>

<sup>1</sup> College of Veterinary Medicine, University of Florida, Gainesville, Florida 32610.

<sup>2</sup> Belize Wildlife & Referral Clinic, San Ignacio, Cayo, Belize, Central America.

<sup>3</sup> Belize Foundation for Research and Environmental Education, Mile Marker 58, Southern Highway, Toledo, Belize, Central America.

<sup>4</sup> Science and Mathematics Division, Eastern Oklahoma State College, Idabel, Oklahoma 74745.

Correspondence should be sent to Elliot R. Jacobson at: [jacobsons@ufl.edu](mailto:jacobsons@ufl.edu)

### KEY WORDS ABSTRACT

<i>Dermatemys mawii</i>	As part of a biannual health examination, coprological samples from 3-mo-old Central American
Central American river turtle	river turtles, <i>Dermatemys mawii</i> (Gray, 1847) in a breeding program in Belize, Central America,
Testudines	revealed a previously undescribed coccidian (Apicomplexa) in 17 of 46 (37%) samples. Of 3 positive
Dermatomydidae	fecal samples transported to the University of Florida, coccidian oocysts were observed in 1 sample.
Belize	Sporulated oocysts were measured and described, and using polymerase chain reaction (PCR), an
Apicomplexa	approximately 400–base pair (bp) region of both the small subunit ( <i>18S</i> ) ribosomal RNA gene and
Eimeriidae	1,200-bp region of the internal transcribed spacer ( <i>ITS</i> ) gene were amplified in all 3 samples and their
<i>Eimeria grayi</i> n. sp.	products were sequenced. For comparative value, the same PCR reactions and amplifications were
<i>Eimeria mitraria</i>	performed on a fecal sample containing oocysts of <i>Eimeria mitraria</i> obtained from a red-eared slider,
	<i>Trachemys scripta elegans</i> . Results indicated a new eimerian in <i>D. mawii</i> , <i>Eimeria grayi</i> n. sp.

The Central American river turtle (*Dermatemys mawii* Gray, 1847) (Fig. 1) is a large, aquatic freshwater turtle known locally in Belize as the “hicatee.” It is the single genus and species within the monotypic family Dermatomydidae. Once abundant, the hicatee has limited distribution along the coastal lowlands of southern Mexico, northern Guatemala, and Belize (Rhodin et al., 2017). It is a relatively large-bodied species, with historical records of 60 cm (24 in.) straight carapace length and weights of 22 kg (49 lb); however, more recent records have found few individuals over 14 kg (31 lb) in México or 11 kg (24 lb) in Guatemala (Vogt et al., 2011).

After decades of overexploitation for its meat and eggs, the hicatee has been virtually eliminated from much of its former range in México; its status in Guatemala is unknown. A countrywide survey conducted in 2010 by The Turtle Survival Alliance (TSA; <https://turtlesurvival.org/history-mission/>) indicated the hicatee was heavily depleted in most of Belize, with healthy populations remaining in a few remote areas. Classified as Critically Endangered (facing an extremely high risk of extinction) by the IUCN Red List, it is included as a priority species in each printing of Turtles in Trouble (Stanford et al., 2018). The hicatee

is considered one of the 25 most endangered tortoises and freshwater turtles by the Turtle Conservation Coalition (Stanford et al., 2018).

The TSA began to collaborate with the Belize Foundation for Research and Environmental Education (BFREE), to launch a multiprong conservation effort to halt the decline of the hicatee, following a 2010 survey. BFREE consists of 1,153 acres of privately owned and protected forested land and a biological field station strategically located at the foothills of the Maya Mountains. Working with multiple stakeholders, BFREE developed a conservation strategy throughout Belize. In 2013, the Hicatee Conservation and Research Center (HCRC) was formed at the BFREE Field Station, with a breeding program to return captive-bred turtles to the wild as a major objective. In 2014, breeding stock was acquired from confiscations from the Belize Fisheries Department, collections from the wild, and rehabilitated individuals. That same year, the first clutch of 8 eggs was deposited and, in June of 2015, the first captive-born turtles hatched at the HCRC. In each consecutive year since, there has been successful egg production and hatching, with a significant increase in the number of clutches and hatchlings.

Beginning in 2014, biannual health assessments have been conducted annually at the HCRC. Fecal samples were obtained from those turtles that would defecate during manual restraint, and wet mounts were examined using a light microscope. In

Version of Record, first published online with fixed content and layout, in compliance with ICZN Arts. 8.1.3.2, 8.5, and 21.8.2 as amended, 2012. ZooBank publication registration: urn:lsid:zoobank.org:pub:0AE4E6E3-3799-4FAC-8501-3AD2F969E369.



**Figure 1.** Central American River Turtle, *Dermatemys mawii*, cohort 2017 (UF:Herp: 191862), Belize Foundation for Research and Environmental Education (BFREE), Belize, Central America. Photographed on 3 March 2021. Color version available online.

September 2018, eimerian oocysts were identified in the feces of 17 of 46 (37%) 3-mo-old turtles. Fecal samples from 3 turtles were subsequently submitted to the University of Florida for identification and sequencing of coccidia in the samples. Here we report our findings including the identification of the first eimerian oocysts observed in a fecal sample from *D. mawii*. According to Duszynski and Morrow (2014), no coccidian parasites have been described in *D. mawii*.

## MATERIALS AND METHODS

**Background, turtles, and samples:** Adult hicatees at HCRC (16°33.326'N, 88°42.423'W), Belize, Central America are kept in 2 outdoor fenced-in ponds; Pond 1 is 28.7 m long × 14 m wide × 3.2 m deep with 23 adult turtles and Pond 2 is 20.1 m long × 24.1 m wide × 3.2 m deep with 22 adults. In addition to hicatees, an adult Meso-American slider (*Trachemys venusta*), a native species, shares Pond 2. Juvenile turtles (<12 mo old) were housed in groups of 10 that were kept at the HCRC laboratory in plastic-lidded tanks that measured 97.1 cm × 50.8 cm × 17.8 cm. Well water was used and ambient water temperatures ranged between 22.2 and 25.6 C.


Hicatees are herbivores and were fed primarily *Ficus* spp. and *Paspalum paniculatum* (Russell River Grass) and to a much lesser degree *Cecropia peltata* (Trumpet Tree) and *Inga* spp. Seasonally, fruits such as fig and various Belizean apples are offered. Recently, the diet of hatchlings and yearlings has been supplemented with a commercially available aquatic turtle diet (Mazuri Aquatic Turtle Diet, St. Louis, Missouri) in an attempt to prevent a “softening” of the shell that appeared in the 2–3-yr-old turtles.

During biannual health examination of turtles at BFREE in 2017 and 2018, oocysts were identified in feces. In December 2018, previously collected fecal samples from 3 individuals of 3-mo-old hicatees of unknown sex, that were previously found positive for coccidia, were transported to the University of Florida, College of Veterinary Medicine (UFCVM), for specific identification. The turtles ranged in weight from 36 to 106 g, straight carapace length (SCL) from 64 to 90 mm, straight

plastron length (SPL) from 44 to 71 mm, straight width (SW) from 54 to 78 mm, and straight depth or thickness (SD) from 26 to 38 mm. All 3 turtles were derived from captive-bred and hatched hicatees at BFREE, and were approximately 3 mo of age at the time feces were collected. In addition, for comparative purposes, feces from a red-eared slider, *Trachemys scripta elegans*, collected in June 2018 from Crooked Creek at Yellville, Marion County, Arkansas (36°13'22.134"N, -92°40'45.8292"W) was examined for coccidia.

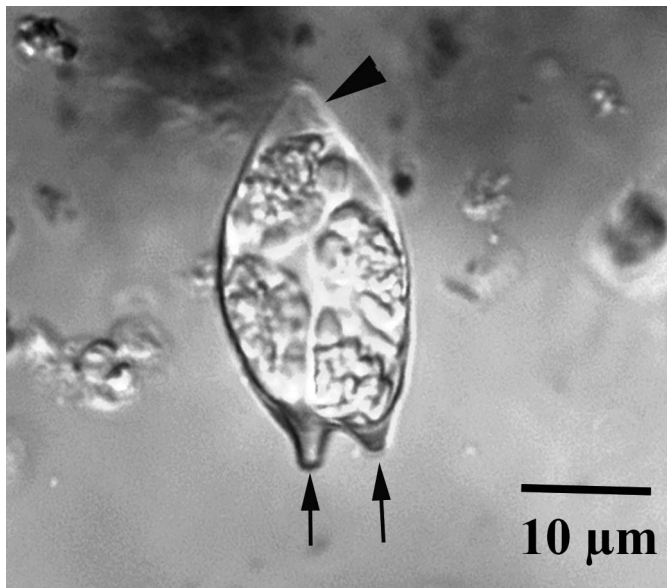
**Fecal sample analysis and oocyst morphometrics:** Upon arrival at UFCVM, the fecal samples were examined by centrifugal fecal flotation using Sheather's sugar solution (sp. gr. 1.25) (Zajac and Conboy, 2012). Flotation samples were examined at ×400 using a Zeiss Axio Scope A1 compound microscope and an Axiocam 506 color camera (Carl Zeiss Microscopy, LLC, White Plains, New York), and when present, up to 15 sporulated oocysts were measured in micrometers (μm) using a calibrated ocular micrometer. Size measurements are means followed by ranges in parentheses. Sporulated oocysts were up to 30 days old when measured and photographed. Measurements of oocysts and sporocysts are as follows: oocyst length (L) and width (W), their ranges and ratios (L/W), micropyle (M), oocyst residuum (OR), polar granule(s) (PG), sporocyst (SP) length (L) and width (W), their ranges and ratio (L/W), Stieda body (SB), sub-Stieda body (SSB), para-Stieda body (PSB), sporocyst residuum (SR), sporozoites (SZ), sporozoite refractile bodies (SRB), and nucleus (N). A photosyntype of a sporulated oocyst was accessioned into the Harold W. Manter Laboratory of Parasitology (HWML), University of Nebraska-Lincoln, as HWML 216401. Turtle taxonomy follows the reptile database (Uetz et al., 2020).

**Molecular biology:** Nucleic acids were extracted from feces of 3 hicatees found at BFREE to possess coccidian oocysts and from a fecal sample of a *T. s. elegans* containing oocysts of *Eimeria mitraria* using a DNeasy blood and tissue kit (Qiagen, Germantown, Maryland) following the manufacturer's instructions. An approximately 400-bp region of the small subunit (18S) ribosomal RNA gene was amplified as previously described (Garner et al., 2006). Briefly, 15 μl of a commercial master mix (Invitrogen, Waltham, Massachusetts), 1 μl each of 20 μM forward primer 1,135 (ACYATAAACTATGCCRACTAGA) and reverse primer 1,503 (CYTCCYTRCRTTARACACGCAA), and 3 μl of the extracted DNA were mixed and amplification reactions as follows were completed in a thermal cycler (Bio Rad T100; Bio Rad, Hercules, California): 94 C for 5 min, followed by 40 cycles of 94 C for 30 sec, annealing at 48 C for 1 min, 72 C for 1 min and then a final 7-min extension at 72 C. An approximately 1,200-bp region of the internal transcribed spacer (ITS)-1 gene, the 5.8S gene, and a portion of the ITS-2 region were amplified using a heminested reaction. The forward primer, EITSF (GATCG-GAGGGTCTCTGTGAA) was used with reverse primer EITSR1 (CCTCTCGAGGCTACAAYTCG) in the first-round PCR reaction, and then forward primer EITSF was used with reverse primer EITSR2 (GGACACGCGATTTTCACTTT) in the second round PCR reaction (Stoneburg et al., 2018). PCR reactions were mixed as above, and cycling conditions were as follows: 95 C for 2 min, followed by 40 cycles of 95 C for 30 sec, annealing at 53 C for 30 sec, 72 C for 1 min, and then a final 5-min extension at 72 C. PCR products, including a negative and previously identified positive control, were run on a 1.5% agarose gel with ethidium

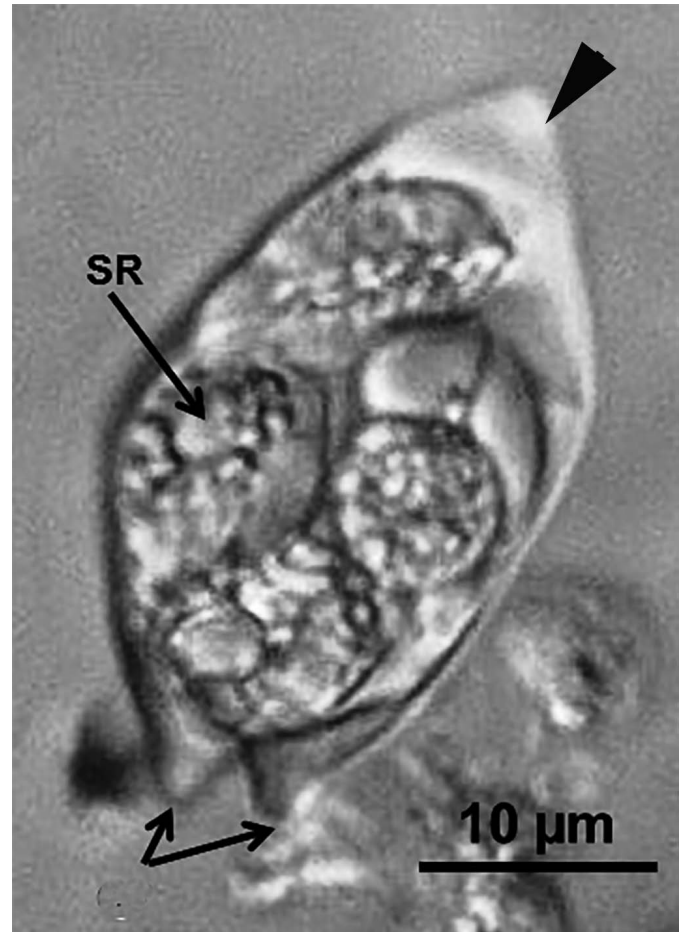


**Figure 2.** Light microscopic photomicrograph of sporulated oocyst of *Eimeria grayi* n. sp. Oocyst showing 3 surface projections (arrows) at 1 pole.

bromide and were visualized under ultraviolet light. Successfully amplified products of the expected length were excised and purified using the QIAquick® Gel Extraction kit (Qiagen) following the manufacturer's instructions and submitted to a commercial facility (Genewiz, South Plainfield, New Jersey) for sequencing. Final products were edited to remove primer sequences using commercial software (Geneious, Auckland, New Zealand), and analyzed using the nucleotide Basic Local Alignment Search Tool (BLASTn; <https://blast.ncbi.nlm.nih.gov>). Bayesian phylogenetic analysis was performed using the Mr. Bayes 3.2.6 plugin for Geneious with an HKY85 substitution model, gamma-distributed rate variation, and 4 chains of  $2 \times 10^6$  generations with 25% burn-in (Huelsenbeck and Ronquist, 2001); *Toxoplasma gondii* (EF472967) was selected as an outgroup.



**Figure 3.** Light microscopic photomicrograph of sporulated oocyst of *Eimeria grayi* n. sp. Oocyst showing 2 of 3 surface projections (arrows) at 1 pole and a broader-based projection (arrowhead) from the opposite pole.



**Figure 4.** Light microscopic photomicrograph of sporulated oocyst of *Eimeria grayi* n. sp. Oocyst showing 2 of 3 surface projections (arrows) at 1 pole, a broader-based projection (arrowhead) from the opposite pole, as well as the location of the sporocyst residuum (SR).

## RESULTS

At the September 2018 BFREE health examination, coccidia were identified in feces of 17 of 46 (37%) 3-mo-old hicatees. Of the 3 fecal samples from this age group that were examined at the University of Florida, a uniform population of oocysts was identified in 1 sample that we describe herein as new.

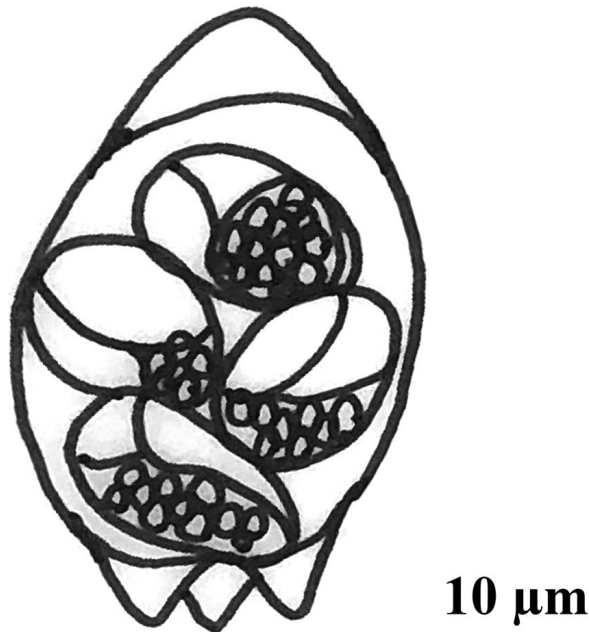
## DESCRIPTION

### *Eimeria grayi* n. sp. (Figs. 2–5)

**Description of sporulated oocyst:** Oocyst shape ( $n = 15$ ): ellipsoidal; smooth, thin-walled;  $L \times W$ :  $30.4$  ( $26$ – $35$ )  $\times$   $15.2$  ( $13$ – $17$ ),  $L/W$ :  $2.0$  ( $1.7$ – $2.5$ ); M, OR, PG: all absent. Distinctive feature of oocyst: 3 conical projections ( $2.1$ – $3.5$  long) present on 1 end, with the oocyst wall forming a broadly pointed end on the opposite pole.

**Description of sporocyst and sporozoites:** SP: ( $n = 4$ ); shape: elongate-ellipsoidal, with a smooth single-layered wall;  $L \times W$ :  $13.7 \times 7.5$  ( $12$ – $19 \times 6$ – $12$ ),  $L/W$   $1.8$  ( $1.7$ – $2.2$ ); SR: sporocyst residuum, coarsely granular, and scattered; SZ: banana-shaped,





**Figure 5.** Composite line drawing of a sporulated mitra-shaped oocyst of *Eimeria grayi* n. sp.

14.2 × 3.6 (14–15 × 3–4) in situ; N visible, slightly posterior to midpoint of SZ. Distinctive feature of SP: slightly pointed at 1 end with a distinct SB, SR of only a few globules, and a SRB in each SZ.

### Taxonomic summary

**Type host:** Central American river turtle, *Dermatemys mawii* Gray, 1847 (Testudines: Dermatemydidae). Collected 11 August and 11 November 2018. Host photovouchers: University of Florida (UF) 191862–191866.

**Type and only locality:** Belize Foundation for Research and Environmental Education, Mile Marker 58, Southern Highway, Belize, Central America (16°33.326'N, 88°42.423'W).

**Prevalence:** 1/3 (33%) based on oocyst identification in samples; 3/3 (100%) based on PCR and sequencing of the *18S* rRNA and *ITS* genes.

**Materials deposited:** Photosyntype of a sporulated oocyst is deposited in the Harold W. Manter Laboratory of Parasitology (HWML), University of Nebraska, as HWML 206401.

**ZooBank registration:** urn:lsid:zoobank.org:act:B7C62C80-DF94-49F0-A73F-586C1FB2B578.

**Etymology:** The specific epithet is named in honor of the British naturalist, John Edward Gray (1800–1875), who described the host in 1847.

**Molecular biology:** All 3 fecal samples had similar content of the *18S* rRNA and *ITS* genes. After primer editing, a 347-bp segment of the *18S* rRNA gene was determined for the hicatee coccidian (GenBank accession MW538581). BLASTn results identified 99.4% sequence identity to several apicomplexan organisms, including *Caryospora*-like sp. US3 (MN450817) from a green sea turtle (*Chelonia mydas*), *Caryospora cheloniae* genotype 1 (KT361639) from *Ch. mydas*, and multiple lizard *Schellackia* spp. The hicatee coccidian was 99.7% identical to a

347-bp segment of the *18S* rRNA gene of the reference sample of *E. mitraria* (GenBank accession MW538549). An 841-bp segment of the *ITS* region was determined for the hicatee coccidian and reference sample of *E. mitraria* (GenBank accessions MW538550 and MW538533, respectively), with 75.2% sequence identity to each other. Bayesian phylogenetic analysis placed the hicatee coccidian in a clade with *Eimeria collicie*, *E. mitraria*, *Eimeria arnyi*, and 2 coccidians of green sea turtles (*Ca. cheloniae* and *Caryospora*-like sp. US3) with a posterior probability of 0.89 (Fig. 6).

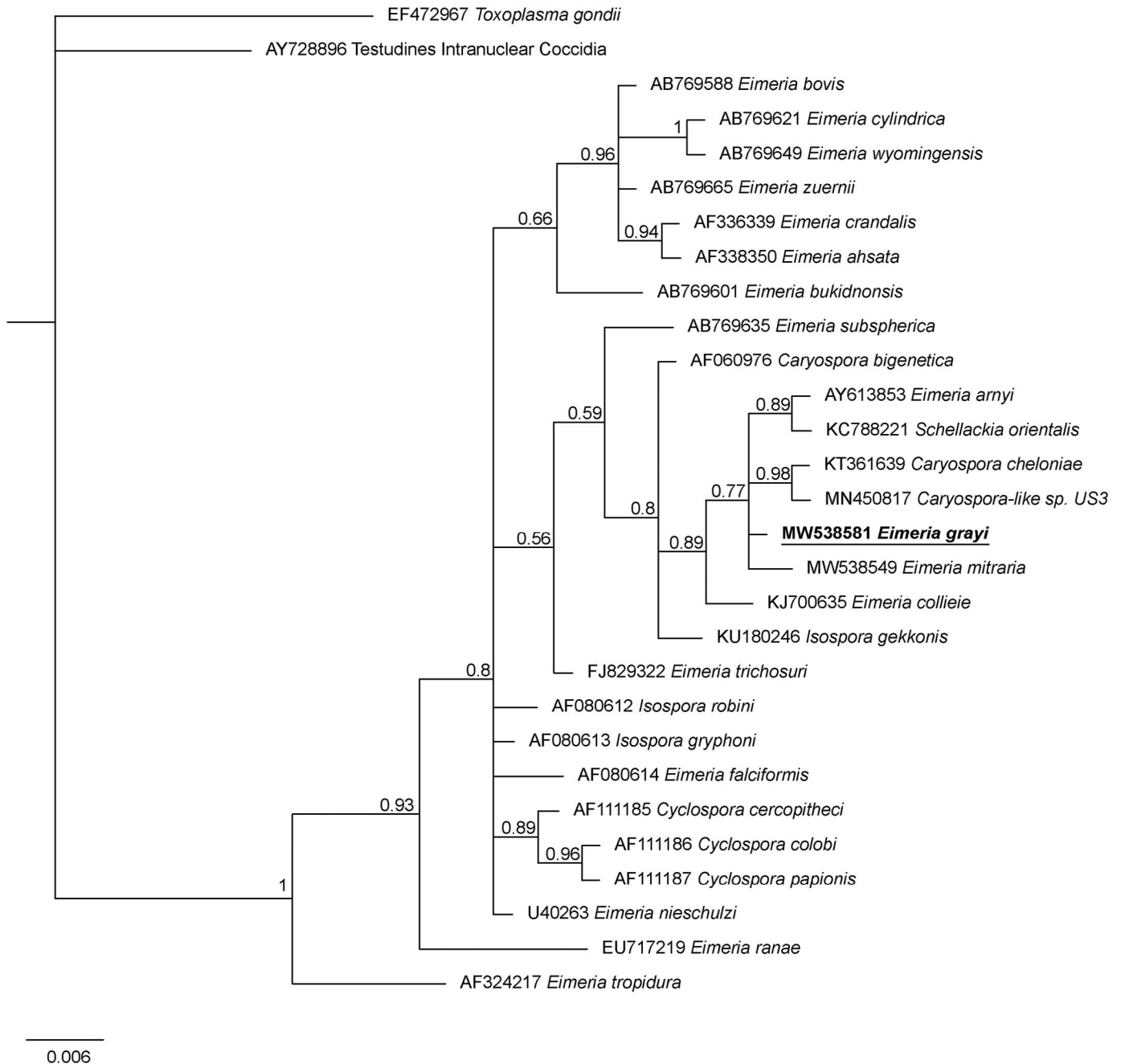
### Remarks

The oocysts being passed by the hicatee possessed multiple conical projections with 3 projecting from 1 pole and a broader-based projection from the opposite pole (Figs. 2–5). To date, the 7 previously described oocysts of Testudines having mitra-like conical projections or irregular surfaces from at least 1 end of their oocyst are (1) *Eimeria amazonensis* from the red-footed tortoise, *Chelonoidis* (formerly *Geochelone*) *carbonaria* from Brazil (Lainson et al., 2008); (2) *Eimeria hynekprokopi* from the Indochinese box turtle, *Cuora galbinifrons* from Vietnam (Široký and Modrý, 2010); (3) *Eimeria iversoni* from a captive Galapagos tortoise, *Chelonoidis* sp. (McAllister et al., 2014); (4) *Eimeria jirkamoraveci* in the Neotropical chelid turtle *Mesoclemmys* (previously *Batrachemys*) *heliostemma* (Široký et al., 2006); (5) *E. mitraria* originally described from the Asian Chinese three-keeled pond turtle, *Mauremys* (formerly *Chinemys*) *reevesii* and subsequently described in multiple species of aquatic turtles on 3 continents (Laveran and Mesnil, 1902; Duszynski and Morrow, 2014); (6) *Eimeria motelo* from the yellow-footed tortoise, *Chelonoidis* (formerly *Geochelone*) *denticulata*, from Peru (Huroková et al., 2000); and (7) *Eimeria stylosa* in the red-eared slider from Texas (McAllister and Upton, 1989). Overall, oocysts of *E. grayi* are considerably larger than other coccidians with surface projections (Table I).

### DISCUSSION

McAllister and Upton (1989) were the first to present a summation of the coccidian parasites of the Order Testudines; they reported over 30 species of *Eimeria* and a single species of *Isospora*. More recently, Duszynski and Morrow (2014) summarized the coccidian parasites of turtles of the world. They listed 66 species of *Eimeria*, 3 species of *Isospora*, and a single species each of *Caryospora* and *Sarcocystis*. However, to date, there are no coccidians known from the only extant member of the family Dermatemydidae, *D. mawii*. In addition, the only coccidian known from any turtle in Belize is *Eimeria pseudemydis* (Lainson, 1968), originally described from the emydid ornate slider, *Trachemys ornata*. Because *D. mawii* is severely threatened across its range and is listed as Critically Endangered by the IUCN Red List (Vogt et al., 2006) based on widespread, dramatic, and ongoing population declines, it is important to gain knowledge about its parasites to help mitigate these negative concerns.

During 2017–2018 there was a die-off of 3-mo-old hicatees at BFREE. Although no specific cause could be determined, in examinations, coccidia were identified in their feces. In these examinations, 17 of 46 (37%) 3-mo-old turtles were positive for coccidia. Several coccidia in aquatic turtles are known to result in



**Figure 6.** Evolutionary relationships of *Eimeria grayi* n. sp. inferred by Bayesian analysis of partial 18S rRNA sequences. Posterior probabilities are shown at branch points. *Toxoplasma gondii* (EF472967) was selected as the outgroup. *Eimeria grayi* n. sp. is bolded and underlined.

severe clinical disease and pathology. For example, sporulated oocysts were identified in captive Indo-Gangetic flap shelled turtle (*Lissemys andersoni*) that had disseminated visceral coccidiosis; 2 distinct *Eimeria* spp. were identified in 1 case (Helke et al., 2006). In addition, *Caryospora*-like coccidia were associated with an epizootic of green turtles off the coast of the southeastern United States (Stacy et al., 2019), and 2 distinct coccidian genotypes were associated with mass mortalities in green turtles off the coast of southeast Queensland, Australia (Chapman et al., 2016). Unfortunately, with the 2017–2018 die-off of hicatees at BFREE, although 22 turtles in various states of postmortem change were

necropsied in Belize, tissues were not found to be suitable for histopathology. It is currently unknown whether the coccidia identified in these turtles were responsible for the mortality event seen at BFREE.

Historically, identification of *Eimeria* spp. has been based largely on host species, oocyst morphological features, pathological changes in the host, and geographic distribution (Duszynski and Wilber, 1997; Tenter et al., 2002). Although eimerian parasites were generally considered to be highly host specific (Duszynski, 1986), strict host specificity in reptiles has been questioned (McAllister and Upton, 1989) and exceptions to host

**Table 1.** Size (length and width in micrometers) of oocysts of *Eimeria* spp. with surface projections.

Species	Host	Length (mean)	Length (range)	Width (mean)	Width (range)	Projections from oocyst wall	Reference
<i>E. amazonensis</i>	<i>Chelonoidis carbonarius</i>	11.7	10–13	9.1	8–10	Two blunt protrusions at 1 end of the oocyst	Lainson et al. (2008)
<i>E. grayi</i> n. sp.	<i>Dermatemys mawii</i>	30.4	26–35	15.2	13–17	Three conical projections present on 1 end, broad pointed end on opposite pole	This study
<i>E. hynekprokopi</i>	<i>Cuora galbinifrons</i>	15.6	14–18	8.7	8–10	Tends to be pointed at both poles	Šíroký and Modrý (2010)
<i>E. iversoni</i>	<i>Chelonoidis</i> sp.	13.5	12–15	10.3	9–11	Two conical projections present on 1 end of oocyst	McAllister et al. (2014)
<i>E. jirkamoraveci</i>	<i>Mesoclemmys</i> (previously <i>Batrachemys</i> ) <i>heliostemma</i>	10.6	8–12	8.9	7–10	One end of oocyst is conically stretched, whereas opposite end bears 3 blunt conical tubercles	Šíroký et al. (2006)
<i>E. mitraria</i>	<i>Mauremys</i> (formerly <i>Chinemys</i> ) <i>reevesii</i> ; subsequently described in multiple species of aquatic turtles on 3 continents	14.4	13–16	10.4	9–13	One end of oocyst bears 1 conical projection, with opposite end having 3 similar projections	Šíroký et al. (2006)
<i>E. motelo</i>	<i>Chelonoidis denticulatus</i>	17	15–19	9.4	8.5–11	Slightly expressed lobed protrusions and irregularities at the poles	Hurková et al. (2000)
<i>E. stylosa</i>	<i>Trachemys scripta elegans</i>	16.5	14.4–17.6	13.1	12–14.4	Each end of the oocyst bears conical projections ca. 4.0 (3.0–5.0) long; most oocysts possess 2 projections on 1 end and 3 on the opposite end	McAllister and Upton (1989)

specificity have been reported in mammals (Zhao and Duszynski, 2001; Zhao et al., 2001). In 1 of the ponds with adult hicatees is a Meso-American slider. Multiple attempts at capturing this turtle for fecal analysis were unsuccessful and we do not know if it shares coccidia with hicatees. Additionally, fecal samples need to be collected from wild hicatees to determine if they are the primary host of *E. grayi*.

Because some species of *Eimeria* are morphologically identical and cannot be distinguished using microscopy, molecular tools are needed to identify and establish phylogenetic relationships of *Eimeria* spp. accurately (Tenter et al., 2002). Yang et al. (2015) conducted molecular analysis at 3 loci: the 18S and 28S rRNA, and the mitochondrial cytochrome oxidase gene (*COI*) in reporting a new eimerian, *E. collieie* in the Western long-necked turtle (*Chelodina colliei*), a species native to Australia. At the 18S rRNA locus, *E. collieie* shared 96.4% and 98.3% genetic similarity to *Eimeria ranae* (GenBank accession number: EU717219) and *E. arnyi* (AY613853), respectively. At the 28S rRNA locus, *E. collieie* shared the highest (91.6%) genetic similarity to *Eimeria papillata* (GenBank accession number: GU593706) from chickens, and phylogenetic analysis at this locus placed *E. collieie* in a separate clade. Additional sequence data at these and other gene loci are needed to better understand the phylogenetic relationships of the *Eimeria* species of Testudines. Because the hicatee is the only member of its family, sequence data from proposed *E. grayi* n. sp. should provide important information about an eimerian in isolated populations in its limited range in Central America.

## ACKNOWLEDGMENTS

The authors assert all applicable international, national, and/or institutional guidelines for the care and use of animals were followed. The Arkansas Game and Fish Commission issued a Scientific Collecting Permit to CTM. The authors thank Dr. Ellis C. Greiner for technical help and critical evaluation of this manuscript. Thanks also to Dr. Gabor Racz and Dr. Scott L. Gardner (HWMU) for expert curatorial assistance. We also thank Thomas Pop and staff at BFREE, Belize, Central America, Nichole D. Bishop, Department of Wildlife Conservation and Ecology, University of Florida, for help in collecting and transporting fecal samples from hicatees and Dr. Coleman Sheehy and Kathryn Daly, Florida Museum of Natural History, for providing accession numbers (UF 191862-191866) for images of hicatees at BFREE. Research was conducted with the approval of the Belize Ministry of Fisheries, Forestry, the Environment, and Sustainable Development, under the Belize Fisheries Department (permit 00026-18), entitled, “Investigations into the Captive Management and Reproductive Biology of the Central American River Turtle, *Dermatemys mawii*, in Belize.”

## LITERATURE CITED

- CHAPMAN, P. A., H. OWEN, M. FLINT, R. J. TRAUB, T. H. CRIBB, AND P. C. MILLS. 2016. Molecular characterization of coccidia associated with an epizootic in green sea turtles (*Chelonia mydas*) in South East Queensland, Australia. PLoS One 11:e0149962. doi:10.1371/journal.pone.0149962.

- DUSZYNSKI, D. W. 1986. Host specificity in the coccidia of small mammals: fact or fiction? *In* Advances in protozoological research. M. Bereczky (ed.). Symposia Biologica Hungarica Vol. 33. Akademiai Kiado, Budapest, Hungary, p. 325–337.
- DUSZYNSKI, D. W., AND J. MORROW. 2014. The Biology and Identification of the Coccidia (Apicomplexa) of Turtles of the World. Elsevier Academic Press, Boston, Massachusetts, 210 p.
- DUSZYNSKI, D. W., AND P. G. WILBER. 1997. A guideline for the preparation of species descriptions in the Eimeriidae. *Journal of Parasitology* 83: 333–336.
- GARNER, M. M., C. H. GARDINER, J. F. X. WELLEHAN, A. J. JOHNSON, T. MCNAMARA, M. LINN, S. P. TERRELL, A. CHILDRESS, AND E. R. JACOBSON. 2006. Intracellular coccidiosis in tortoises: nine cases. *Veterinary Pathology* 43: 311–320.
- HELKE, K. L., T. K. COOPER, J. L. MANKOWSKI, AND S. L. POYNTON. 2006. Disseminated visceral coccidiosis in Indoganggetic flap-shelled turtles, *Lissemys punctata andersonii*. *Journal of Wildlife Diseases* 42: 788–796.
- HUELSENBECK, J. P., AND F. RONQUIST. 2001. MRBAYES: Bayesian inference of phylogenetic trees. *Bioinformatics* 17: 754–755.
- HURKOVÁ, L., D. MODRÝ, B. KOUDELA, AND J. SLAPETA. 2000. Description of *Eimeria motelo* sp. n. (Apicomplexa: Eimeriidae) from the yellow-footed tortoise, *Geochelone denticulata* (Chelonia: Testudinidae), and replacement of *Eimeria carinii* Lainson Costa & Shaw, 1990 by *Eimeria lainsoni* nom. nov. *Memórias do Instituto Oswaldo Cruz* 95: 829–832.
- LAINSON, R. 1968. Parasitological studies in British Honduras. IV. Some coccidial parasites of reptiles. *Annals of Tropical Medicine and Parasitology* 62: 260–266.
- LAINSON, R., F. M. M. DA SILVA, C. M. FRANCO, AND M. C. DE SOUZA. 2008. New species of *Eimeria* and *Isospora* (Protozoa: Eimeriidae) in *Geochelone* spp. (Chelonia: Testudinidae) from Amazonian Brazil. *Parasite* 15: 531–538.
- LAVERAN, A., AND F. MESNIL. 1902. Sur quelques protozoaires parasites d'une tortue d'Asie (*Damonie reevesii*). *Comptes Rendus de l'Académie des Sciences Series 3* 134: 609–614.
- MCALLISTER, C. T., AND S. J. UPTON. 1989. The coccidia (Apicomplexa: Eimeriidae) of Testudines, with descriptions of three new species. *Canadian Journal of Zoology* 67: 2459–2467.
- MCALLISTER, C. T., D. W. DUSZYNSKI, AND D. T. ROBERTS. 2014. A new coccidian (Apicomplexa: Eimeriidae) from Galapagos tortoise, *Chelonoidis* sp. (Testudines: Testudinidae), from the Dallas Zoo. *Journal of Parasitology* 100: 128–132.
- RHODIN, A. G. J., J. B. IVERSON, R. BAUR, U. FRITZ, A. GEORGES, H. B. SHAFFER, AND P. P. VAN DIJK. 2017. Turtles of the world. Annotated checklist and atlas of taxonomy, synonymy, distribution, and conservation status, 8th ed. Chelonian Research Monographs 7: 1–292.
- ŠIROKÝ, P., AND D. MODRÝ. 2010. Eimeriid coccidia (Apicomplexa: Eimeriidae) from Geoemydidae turtles (Testudines: Geoemydidae) with a description of six new species. *Acta Protozoologica* 49: 301–310.
- ŠIROKÝ, P., M. KAMLER, AND D. MODRÝ. 2006. A new *Eimeria* (Apicomplexa: Eimeriidae), possessing mitra-shaped oocysts from the Neotropical chelid turtle *Batrachemys helioestemma* (Testudines: Chelidae), and its comparison with *Eimeria mitraria* (Laveran & Mesnil 1902). *Memórias do Instituto Oswaldo Cruz* 101: 555–558.
- STACY, B. A., P. A. CHAPMAN, H. STOCKDALE-WALDEN, T. E. WORK, J. DAGENAIS, A. M. FOLEY, M. WIDEROFF, J. F. X. WELLEHAN, JR., A. L. CHILDRESS, C. A. MANIRE, ET AL. 2019. *Caryospora*-like coccidia infecting green turtles (*Chelonia mydas*): an emerging disease with evidence of interoceanic dissemination. *Frontiers in Veterinary Science* 6: 372. doi:10.3389/fvets.2019.00372.
- STANFORD, C. B., A. G. J. RHODIN, P. P. VAN DIJK, B. D. HORNE, T. BLANCK, E. V. GOODE, R. HUDSON, R. A. MITTERMEIER, A. CURRYLOW, C. EISEMBERG, ET AL. 2018. Turtles in Trouble: The World's 25+ Most Endangered Tortoises and Freshwater Turtles. The Turtle Conservation Coalition, Ojai, California, 84 p.
- STONEBURG, S. K., K. Z. FOX, J. SMITH, J. WELLEHAN, AND A. CHILDRESS. 2018. Speciation of unknown coccidia in house sparrows (*Passer domesticus*). *In* Proceedings of the American Association of Zoo Veterinarians, Prague, Czech Republic, p. 180–181.
- TENTER, A. M., J. R. BARTA, I. BEVERIDGE, D. W. DUSZYNSKI, H. MEHLHORN, D. A. MORRISON, R. C. A. THOMPSON, AND P. A. CONRAD. 2002. The conceptual basis for a new classification of the coccidia. *International Journal for Parasitology* 32: 595–616.
- UETZ, P., P. FREED, AND J. HOŠEK (eds.). 2020. The Reptile Database. Available at: <http://www.reptile-database.org>. Accessed 5 February 2021.
- VOGT, R. C., G. P. GONZALEZ-PORTER, AND P. P. VAN DIJK. 2006. *Dermatemys mawii* (errata version published in 2016). The IUCN Red List of Threatened Species 2006: e.T6493A97409830. Available at: <https://dx.doi.org/10.2305/IUCN.UK.2006.RLTS.T6493A12783921.en>. Accessed 1 December 2020.
- VOGT, R. C., J. R. POLISAR, D. MOLL, AND G. GONZALEZ-PORTER. 2011. *Dermatemys mawii* Gray 1847 Central American River Turtle, Tortuga Blanca, Hicatee. *In* Conservation Biology of Freshwater Turtles and Tortoises: A Compilation Project of the IUCN/SSC Tortoise and Freshwater Turtle Specialist Group, A. G. J. Rhodin, P. C. H. Pritchard, P. P. van Dijk, R. A. Samure, K. A. Buhlmann, J. B. Iverson, and R. A. Mittermeier (eds.). Chelonian Research Monographs 5, p. 058.1–058.12.
- YANG, R., B. BRICE, A. ELLOIT, E. LEE, AND U. RYAN. 2015. *Eimeria collieae* n. sp. (Apicomplexa: Eimeriidae) from the western long-necked turtle (*Chelodina colliei*). *Experimental Parasitology* 154: 75–81.
- ZAJAC, A. M., AND G. A. CONBOY. 2012. *Veterinary Clinical Parasitology*, 8th ed. Wiley-Blackwell, West Sussex, U.K., 368 p.
- ZHAO, X., AND D. W. DUSZYNSKI. 2001. Phylogenetic relationships among rodent *Eimeria* species determined by plastid ORF470 and nuclear 18S rDNA sequences. *International Journal for Parasitology* 31: 715–719.
- ZHAO, X., D. W. DUSZYNSKI, AND E. S. LOKER. 2001. Phylogenetic position of *Eimeria antrozoi*, a bat coccidium (Apicomplexa: Eimeriidae) and its relationship to morphologically similar *Eimeria* spp. from bats and rodents based on nuclear 18S and plastid 23S rDNA sequences. *Journal of Parasitology* 87: 1120–1123.