

FATAL POX INFECTION IN A ROUGH-LEGGED HAWK

Author: PEARSON, G. L.

Source: Journal of Wildlife Diseases, 11(2) : 224-228

Published By: Wildlife Disease Association

URL: <https://doi.org/10.7589/0090-3558-11.2.224>

BioOne Complete (complete.BioOne.org) is a full-text database of 200 subscribed and open-access titles in the biological, ecological, and environmental sciences published by nonprofit societies, associations, museums, institutions, and presses.

Your use of this PDF, the BioOne Complete website, and all posted and associated content indicates your acceptance of BioOne's Terms of Use, available at www.bioone.org/terms-of-use.

Usage of BioOne Complete content is strictly limited to personal, educational, and non - commercial use. Commercial inquiries or rights and permissions requests should be directed to the individual publisher as copyright holder.

BioOne sees sustainable scholarly publishing as an inherently collaborative enterprise connecting authors, nonprofit publishers, academic institutions, research libraries, and research funders in the common goal of maximizing access to critical research.

FATAL POX INFECTION IN A ROUGH-LEGGED HAWK

G. L. PEARSON, U.S. Fish and Wildlife Service, Northern Prairie Wildlife Research Center, Jamestown, North Dakota 58401, U.S.A.

D. A. PASS[†] and E. C. BEGGS, Department of Pathology, Ontario Veterinary College, University of Guelph, Guelph, Ontario, Canada N1G 2W1.

Abstract: Natural pox infection occurred in a free-living rough-legged hawk (*Buteo lagopus*) in northeastern North Dakota. Gross, histological and electron microscopic findings were typical of pox infection, and characteristic lesions developed in red-tailed hawks (*Buteo jamaicensis*) but not in great horned owls (*Bubo virginianus*) following inoculation with case material. Death of the rough-legged hawk was attributed to starvation resulting from inability to capture prey and to blood loss from foot lesions.

INTRODUCTION

Pox infections in birds of prey have been known for some time,^{1,7} although reports of natural infections in specific raptor species, especially under wild conditions, are few. Cooper³ reported pox infections in two captive peregrine falcons (*Falco peregrinus*) which apparently developed extensive lesions and were destroyed. A captive saker falcon (*Falco cherrug*) was reported by Greenwood and Blakemore⁴ to have recovered from pox infection, even though extensive foot lesions had developed and one talon had been lost. Halliwell⁵ described a non-fatal case of pox in a captive immature red-tailed hawk, and Moffatt⁶ reported a naturally occurring pox infection in a free-flying juvenile golden eagle (*Aquila chrysaetos*) but did not indicate the outcome.

Most reported cases of pox infections in free-flying wild birds have been mild and self-limiting; however, lesions resulting in impaired vision may result in severe mortality from starvation in some cases.⁶ This paper reports an additional hazard of pox infection in a bird of prey.

Case History

A female rough-legged hawk captured December 2, 1971, by a farmer in Ramsey County, North Dakota, was delivered to the manager of the Sullys Hill National Game Preserve, Fort Totten, North Dakota. The hawk had been observed in the vicinity of the farmstead for several days and at the time of capture was weak and unable to fly. A large, irregular mass involving the left foot made walking difficult. Although the hawk fed on muskrat carcasses provided at the preserve, movement and feeding activity caused bleeding of the foot, and the bird was found dead on December 5.

MATERIALS AND METHODS

Case Material

The rough-legged hawk was frozen after death. Before thawing for necropsy, sections of cutaneous lesions were collected and maintained in a frozen state for virological studies while others were fixed in 10% formalin for histopathological examination. A sample of frozen

[†] Present address: Bendigo Regional Veterinary Laboratory, Department of Agriculture, Division of Animal Health, P.O. Box 125, Bendigo, Victoria 3550, Australia.

skin nodule was prepared by the method outlined by Cheville,² negatively stained with 2% phosphotungstic acid at pH 4.3, and examined with a Philips 200 electron microscope at 60 KV. The formalin fixed tissues were processed routinely, embedded in paraffin, sectioned at 6 μ m, and stained with hematoxylin and eosin for conventional light microscopy.

Transmission Studies

Two red-tailed hawks and two great horned owls were used for transmission studies. An area approximately 0.5 cm² on the scaly area of the distal tarso-metatarsus of the hawks and on the soft skin between the digits of the owls was scarified with the tip of an 18-gauge hypodermic needle. Approximately 0.2 ml of the virus inoculum prepared² from a skin nodule of the rough-legged hawk was rubbed into the scarified areas.

At 49 days post-inoculation, a nodule which developed at the inoculation site on one red-tailed hawk was removed by excision biopsy. One half of the lesion was fixed in 10% formalin and the other half was fixed in 5% glutaraldehyde for 4 hours. The formalin fixed material was processed and stained in the same manner as the case material described above. The tissue fixed in glutaraldehyde was washed in sucrose phosphate buffer, post-fixed in 1% phosphate buffered osmium tetroxide for 1 hour, dehydrated through a graded series of acetone solutions, and embedded in Epon 812*. Ultrathin sections were stained with lead citrate⁹ and 2% aqueous uranyl acetate and then examined with a Philips 200 electron microscope at 60 KV.

RESULTS

Case Material

Gross pathological examination of the rough-legged hawk revealed an extensive (8 x 8 x 5 cm), irregular, dark, encrusted mass involving the entire left

foot and resulting in sloughing of the talons from the anterior digits (Figure 1). Three small (0.5 - 1.0 cm), raised, dark, encrusted lesions were present on the right foot. Similar lesions were also present on the lower left palpebra, on the cere, and at the commissures and on the right lingual surfaces of the beak, but were not sufficiently extensive to have interfered with vision or ingestion. The hawk, which was severely emaciated, weighed 708 g. The blood appeared pale and watery, the gallbladder was distended, and the cloaca was filled with urates. No pharyngeal or esophageal lesions were observed.

Histopathological examination of the skin lesions revealed hyperplasia of the stratum spinosum of the epidermis, eosinophilic intracytoplasmic inclusion bodies in the hyperplastic cells and parakeratosis. Areas of necrosis and bacterial infiltration were present in the hyperplastic epithelium of the left foot.

Virus particles were observed in the negatively stained preparation, although they were not plentiful. The virions were oval, had an outer coat of filaments that criss-crossed the surface and measured $265 \pm 19 \times 353 \pm 10$ nm at their widest parts.

Transmission Studies

Lesions did not develop on the feet of the two great horned owls, but small (approximately 5 mm diameter), firm nodules with ulcerated surfaces were seen at 46 days at the sites of inoculation in the two red-tailed hawks. The birds were not observed between the 39th and 46th days post-inoculation, but lesions had not been observed on the 39th day. The nodules increased slightly in size over the next 3 days, and an excision biopsy was performed on one hawk on the 49th day post-inoculation. The nodule on the other bird remained approximately the same size for another 14 to 21 days, but the surface appeared more cornified and less ulcerated. This lesion then regressed and was no longer visible

* Fisher Scientific, Don Mills, Ontario.



FIGURE 1. Feet of rough-legged hawk with pox infection.

by the 98th day post-inoculation. Histologically, the skin lesion on the first red-tailed hawk was similar to the smaller lesions in the rough-legged hawk.

Sections of the stratum spinosum only were examined with the electron microscope. In the cytoplasm of the epithelial cells of the stratum spinosum, oval accumulations of virus particles were seen (Figure 2). These were considered to be inclusion bodies. The virus particles had an outer envelope and an oval or dumb-bell-shaped internal core, and measured $203 \pm 10 \times 396 \pm 19$ nm. Electron-dense granular material was present in the matrix of the inclusion bodies.

DISCUSSION

The gross, histopathologic and electron microscopic finding in the rough-legged hawk, and in the red-tailed hawks inocu-

lated with lesion material from the rough-legged hawk, were typical of avian pox.⁶ Transmission of the infection between the two *Buteo* species (i.e., rough-legged hawk and red-tailed hawk) indicates that the virus is not a monospecific strain, but failure to infect the great horned owls suggests that there may be some generic specificity. Transmission studies utilizing other species are needed to verify this.

The fact that, following capture, the rough-legged hawk was observed to feed on muskrat carcasses, even though it was too weak to fly, indicates its emaciated condition was not the result of inability to locate or ingest food. However, the extensive left foot lesion was observed to inhibit walking and undoubtedly interfered with the capture of prey. In fact,

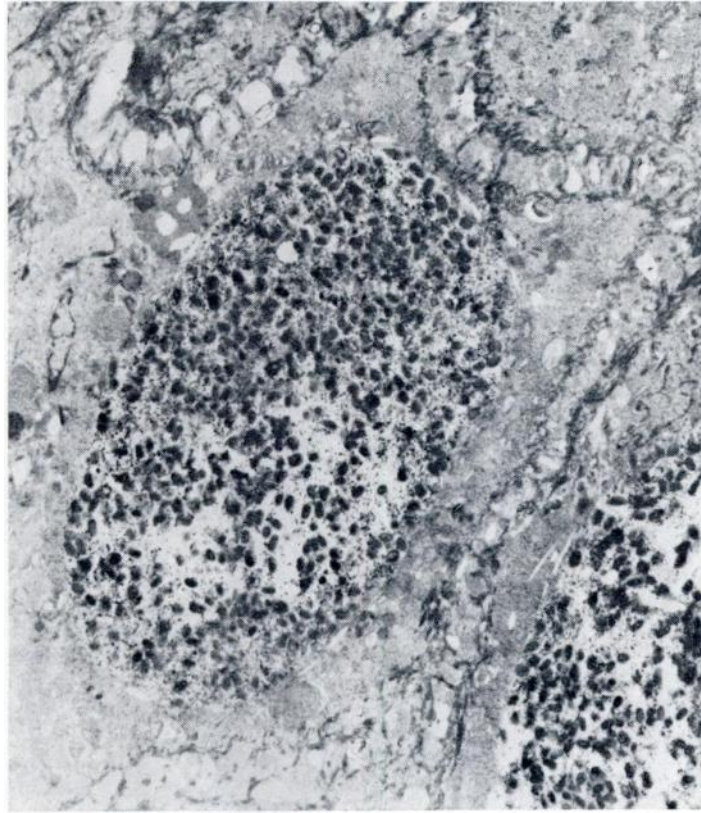


FIGURE 2. Electron micrograph of cytoplasmic inclusion in epithelial cell of stratum spinosum of red-tailed hawk artificially infected with pox virus from rough-legged hawk. X5720

the hawk may have stayed in the vicinity of the farmstead in an attempt to utilize a more abundant supply of small rodents. Inability to capture prey efficiently because of extensive foot lesions, es-

pecially when coupled with chronic blood loss from lesions and high energy demands of cold weather, apparently can contribute to the mortality from pox infections in birds of prey.

Acknowledgements

The authors extend their appreciation to Mr. and Mrs. Louis Bryl of Webster, North Dakota, for their concern in capturing and seeking aid for the rough-legged hawk and to Mr. David Goeke, Manager of Sullys Hill National Game Preserve, for submitting the bird for postmortem examination and providing the history of the case.

REFERENCES

1. BURNETT, E. L. 1943. Fowl pox, pp. 481-492 in *Diseases of Poultry*. Edited by H. E. Biester and L. Devries. The Iowa State College Press, Ames, Iowa.
2. CHEVILLE, N. F. 1966. The cytopathology of swine pox in the skin of swine. *Am. J. Path.* 49: 339-352.
3. COOPER, J. E. 1969. Two cases of pox in recently imported peregrine falcons (*Falco peregrinus*). *Vet. Rec.* 85: 683-684.
4. GREENWOOD, A. G. and W. F. BLAKEMORE. 1973. Pox infection in falcons. *Vet. Rec.* 93: 468-470.
5. HALLIWELL, W. H. 1972. Avian pox in an immature red-tailed hawk. *J. Wildl. Dis.* 8: 104-105.
6. KARSTAD, L. 1971. Pox, pp. 34-41 in *Infectious and Parasitic Diseases of Wild Birds*. Edited by J. W. Davis et al. The Iowa State University Press, Ames, Iowa.
7. KIRMSE, P. 1967. Pox in wild birds: An annotated bibliography. *Wildl. Dis.* 49.
8. MOFFATT, R. E. 1972. Natural pox infection in a golden eagle. *J. Wildl. Dis.* 8: 161-162.
9. VENABLE, J. H. and R. COGGESHALL. 1965. A simplified lead citrate stain for use in electron microscopy. *J. Cell. Biol.* 25: 407-408.

Received for publication 5 September 1974
