

**Babesia moshkovskii (SCHURENKOVA, 1938) LAIRD
AND LARI, 1957; FROM THE PRAIRIE FALCON, *Falco
mexicanus*, IN WYOMING; WITH COMMENTS ON OTHER
PARASITES FOUND IN THIS HOST 1**

Authors: CROFT, ROBERT EARL, and KINGSTON, NEWTON

Source: Journal of Wildlife Diseases, 11(2) : 229-233

Published By: Wildlife Disease Association

URL: <https://doi.org/10.7589/0090-3558-11.2.229>

BioOne Complete (complete.BioOne.org) is a full-text database of 200 subscribed and open-access titles in the biological, ecological, and environmental sciences published by nonprofit societies, associations, museums, institutions, and presses.

Your use of this PDF, the BioOne Complete website, and all posted and associated content indicates your acceptance of BioOne's Terms of Use, available at www.bioone.org/terms-of-use.

Usage of BioOne Complete content is strictly limited to personal, educational, and non - commercial use. Commercial inquiries or rights and permissions requests should be directed to the individual publisher as copyright holder.

BioOne sees sustainable scholarly publishing as an inherently collaborative enterprise connecting authors, nonprofit publishers, academic institutions, research libraries, and research funders in the common goal of maximizing access to critical research.

***Babesia moshkovskii* (SCHURENKOVA, 1938) LAIRD AND LARI, 1957; FROM THE PRAIRIE FALCON, *Falco mexicanus*, IN WYOMING; WITH COMMENTS ON OTHER PARASITES FOUND IN THIS HOST¹**

ROBERT EARL CROFT^{2,3} and NEWTON KINGSTON²

Abstract: *Babesia moshkovskii**† was found in the blood of 6 of 30 downy (D) Prairie Falcons and in none of 5 adults (A) from Wyoming. Intestinal parasites included *Neodiplostomum* (C.) *spathula**† (A,3), *Cladotaenia globifera**, (A,1), *Physaloptera* sp.†, (A,1), and *Serratospiculum amaculatum*†, (A,4). *Ornithodoros concanensis*, (D,3), *Thrassis francisi**, (D,1), *Opisocrostitis* sp.*, (D,1), *Degeeriella rufa*, (D,2), *Simulium* (E.) *canonicola**† (D,2), and an unidentified hippoboscid fly*, (D,2) were external parasites. It is considered that the soft tick, *O. concanensis*, is the most likely vector of the hematozoon. The morphological forms of *B. moshkovskii* are described and discussed. This is the first report of an avian babesoid on this continent. (*new host record, †new distribution record).

INTRODUCTION

There are few records of parasites from the Prairie Falcon, *Falco mexicanus*, and almost nothing is known from this host in Wyoming.¹⁴ A survey of the parasites of this host was initiated in the spring of 1971 in order to determine what parasites were present and their effect on this host species.

MATERIALS AND METHODS

Adult birds were taken by shooting or trapping. Young were sampled by fecal and blood collections in the eyrie or were brought to the laboratory where they (and adult birds) were examined for parasites. Thin blood films were prepared from dead and live hosts and stained with Giemsa's stain. Internal parasites were fixed in formalin, stained

and mounted. Ectoparasites were collected in the field in alcohol and slides prepared of some of these. We wish to thank Dr. A. M. Barnes, USPHS Disease Ecology Section, Fort Collins, Colorado for identification of the fleas; Dr. D. M. Wood, Entomology Research Institute, Ottawa, Ontario, Canada for identification of the black flies; Dr. J. R. Lichtenfels, National Animal Parasite Lab., Vet. Sciences Research Division, USDA, Beltsville, Maryland for confirming a nematode identification; and James B. White, Director of the Wyoming Game and Fish Department, for allowing the study of these falcons.

RESULTS

The parasites found in this survey in Prairie Falcons from Wyoming are summarized in Table 1.

¹ Publication approved by Director, Agriculture Experiment Station, University of Wyoming, Laramie, Wyoming 82071 U.S.A.; as JA 697.

² Division of Microbiology and Veterinary Medicine, Box 3354, University of Wyoming, Laramie, Wyoming 82071.

³ Present Address: Northwest Analytical Laboratory, Northwest Community College, Powell, Wyoming 82435.

The haematozoon was detected in thin, peripheral blood films of two of 10 male and four of 20 female downy Prairie Falcons. Neither sex of adult birds was infected. In thin films from parasitized birds there was a higher number of poikilocytic red blood cells (RBC), indicative, according to Lucas and Jamroz⁸ and Biester and Schwarte,² of some blood abnormality; however, these abnormal RBCs were not infected. Parasitized erythrocytes (up to 8% of RBCs) appeared normal in size and shape, and were usually mature, though some immature RBCs were infected; rarely was a displaced nucleus seen. The parasites were seen as small and large ring forms, comma shapes, paired and tetra-radiate fan-shaped forms and other less definable stages. The organism lacked pigment and

usually was found in the end(s) of the host cell, except in multiple infections where several organisms were scattered throughout the cytoplasm both at the ends and sides of the RBC. Where poikilocytosis was evident in some of the thin films, the corresponding packed cell volume (PCV) was low (29%, in two of the infected birds resulting in a marked anemia and accompanying weakness especially in the younger nestlings). Normal PCV range in uninfected birds was 37-55%. In infected birds the ratio of mature RBCs to immature RBCs was 1:20 while the opposite prevailed in both young and older uninfected birds.

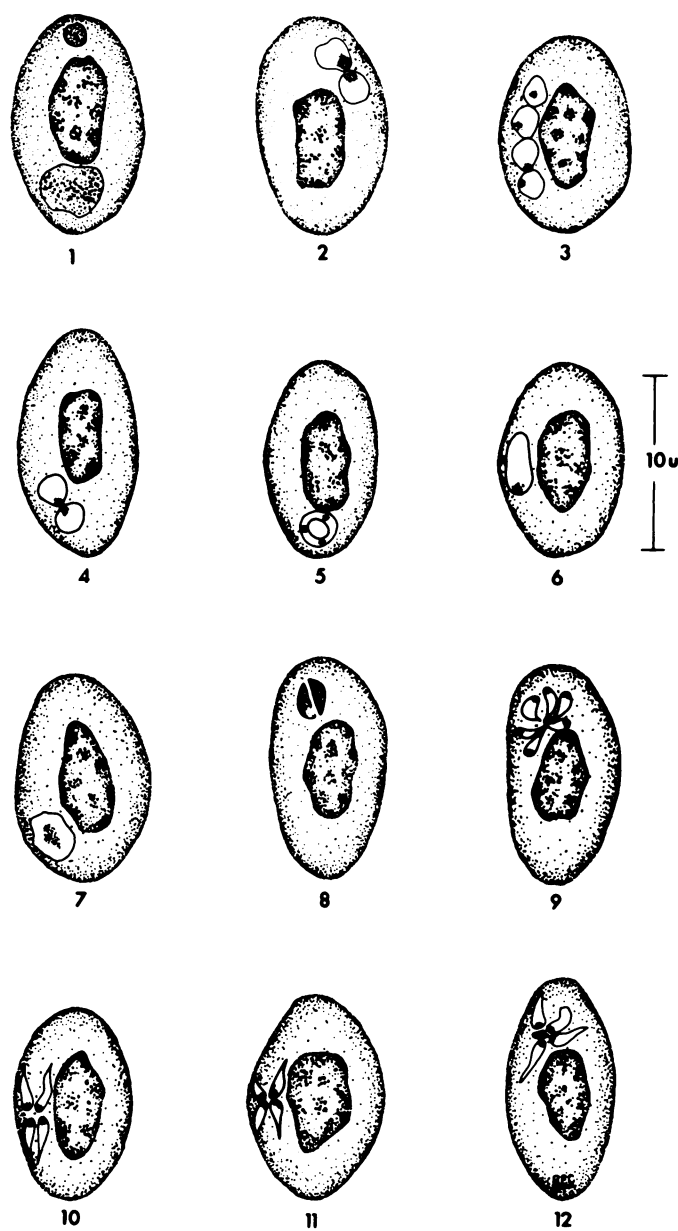
The organism parasitizing the RBCs of Prairie Falcons in Wyoming is considered to belong to the genus *Babesia* Starcovici, 1893, owing to the lack of

TABLE 1. Parasites of the Prairie Falcon, *Falco mexicanus*, (Number positive/number sampled).

Parasite	Host	
	Adults	Young
Protozoa (Blood)		
<i>Babesia moshkovskii</i> (*†)	0/5	6/30
Trematode		
<i>Neodiplostomum</i> (C.) <i>spathula</i> (*†)	3/5	0/30
Cestode		
<i>Cladotaenia globifera</i> (*)	1/5	0/30
Nematodes		
<i>Physaloptera</i> sp. (†)	1/5	0/30
<i>Serratospiculum amaculatum</i> (†)	4/5	0/30
Ticks		
<i>Ornithodoros concanensis</i>	0/5	3/30
Fleas		
<i>Thrassis francisi</i> (*)	0/5	1/30
<i>Opisocrostis</i> sp. (*)	0/5	1/30
Lice		
<i>Degeeriella rufa</i>	0/5	2/30
Flies		
<i>Simulium</i> (E.) <i>canonicola</i> (*†)	0/5	2/30
Hippoboscids fly (*)	0/5	2/30

* New host record.

† new distribution record.



FIGURES 1 - 12. Various stages of *Babesia moshkovskii* from the Prairie Falcon, *Falco mexicanus*.
Explanation of figures in text.

pigment in infected RBCs and division of the pear-shaped individuals to form two or four organisms (rarely six); it cannot be distinguished from *Babesia moshkovskii* (Schurenkova, 1938) Laird and Lari, 1957. The morphological categories of Laird and Lari⁵ are utilized in the following description of the parasite from the Prairie Falcon.

Anaplasmod forms: Minute dark spots similar in staining characteristics to *Anaplasma marginale* (Fig. 1) seen only as single entities within any REC. **Ring forms:** Forms vary from circular (Figs. 2, 5) to ovoid (Fig. 6), to irregular (Fig. 7); usually with a dark red staining periphery and clear, sometimes pinkish-looking central cytoplasm, some resembling the ring stages of *Plasmodium spp.*; range in diameter from 1.92 to 3.02 μm . **Elongate forms:** Forms whose length exceed their width with a terminal nuclear mass, range from 1.11 to 3.31 μm in length (Fig. 6). **Solid forms:** Forms which may overlap with the small ring forms (see above) though usually larger in size, range from 0.92 to 5.6 μm in diameter, and which stain rather darkly throughout (Fig. 1). Differentiation of the nuclear mass from the cytoplasm is difficult due to the conglomerate nature of the parasite. **Dividing forms:** Ring forms undergoing division appear as figure-of-eight forms (Fig. 2), while those assumed to be more advanced have moved apart but still exhibit evidence of recent division (Fig. 4). Several erythrocytes were seen having four ring stages in line; in one case all four rings appeared to have been connected (Fig. 3). This condition may be the result of a simultaneous division of two rings and alignment is probably based on available space within the cell. It may be possible for a multiple division to have occurred resulting in four ring forms. Laird and Lari⁵ illustrated a similar condition but made no comment as to the frequency of this condition. The large, solid and elongate forms appeared to divide longitudinally with a very distinct line of cleavage (Fig. 8). **Schizogony:** Schizonts in cross and fan-shaped forms are characteristic of this parasite, even though they occurred less frequently

than the other forms. There are several characteristic types: cross forms made up usually of four individuals (rarely six) with both central (Figs. 10, 11) and peripheral chromatin-cytoplasm arrangements (Fig. 9). Some of both forms are arranged around a central mass, possibly residual material left from schizogony.

DISCUSSION

Levine^{8,7} cited only one piroplasm from birds, viz., *Babesia moshkovskii*: found in an eagle, *Gypaetus barbatus* by Schurenkova,¹⁰ from Tadzhikistan (S. Russia). It has also been reported as present in the blood of a kestrel, *Falco tinnunculus rupicolaeformis* and a barn owl, *Tyto alba alba*, in Egypt by Mohammed⁹; and in the Indian House Crow, *Corvus splendens* in Pakistan by Laird and Lari.⁸ The finding of this parasite in the blood of the Prairie Falcon in Wyoming represents both new host and geographical distributions for the parasite and extends its range to the North American continent. Other authors have referred to non-pigmented, intracorpuseular parasites which may be babesoids: from the little owl, *Athene noctua* by Wasielewski¹⁸; from *Hypoleis hypoleis* (Italy) by Franchini¹; from the heron, *Ardea cinerea rectirostris* in Indo-China by Toumanoff¹²; and from quail, *Coturnix c. coturnix* in Algeria by Sergeant¹¹ and *Colinus virginianus* in Mexico by Beltran (in Mohammed⁹). The parasites of quail and *Hypoleis hypoleis* are considered by Mohammed⁹ to be *Aegyptianella pullorum*⁷ now placed among the Rickettsiales; Mohammed⁹ considers the descriptions of forms from the little owl and the heron inadequate for generic or species designation.

The soft tick, *Ornithodoros concanensis*, (Ixodoidea, Argasidae) was present on only three of the downy Prairie Falcons. While only one of these birds was infected with *B. moshkovskii*, this arthropod is considered the most likely vector for the haematozoon.^{1,10}

Neodiplostomum (C.) *spathula* and *Cladotaenia globifera* were likely acquired by the adult birds as a result

of feeding on Richardson's ground squirrels, *Citellus richardsoni*, which are thought to harbor immature forms of these species. *Physaloptera* sp. and *Serratospiculum amaculatum* were probably acquired by the Prairie Falcons eating small birds, themselves infected from eating grasshoppers and crickets. *Thrassis francisi* and *Opisocrostitis* sp. are doubtless accidental parasites acquired from the rodent prey species. *Degeeriella rufa*, *Simulium* (E.) *canonicola* and the unidentified Hippoboscids may represent

normal ectoparasites living and/or feeding on *Falco mexicanus*.

Babesia moshkovskii and *Serratospiculum amaculatum* apparently represent a danger to their hosts, the former resulting in anemia with weakness and possible death in the young birds and the latter, being located in the air sacs, seriously interfering with the host's external respiration. Also of interest is that *S. amaculatum* is acquired before the birds are 17 days of age with the first ova detectable in the feces at 83 days.³

LITERATURE CITED

1. BEDFORD, G. A. H. and J. D. W. A. COLES. 1933. The transmission of *Aegyptianella pullorum* Carpano, to fowls by means of ticks belonging to the genus *Argas*. Onderstepoort, J. Vet. Sci. and Animal Indust. 1: 15-18.
2. BIESTER, H. E. and L. H. SCHWARTE. 1965. *Diseases of Poultry*. Iowa State Univ. Press. Ames, Iowa. pp. 100-119.
3. CROFT, R. E. 1973. Parasites of the Prairie Falcon (*Falco mexicanus*) in Southeastern Wyoming. Master's Thesis, University of Wyoming.
4. FRANCHINI, G. 1924. Hematozoaires particuliers d'un oiseau *Hypoleis hypoleis*. Bull. Soc. Pathol. Exotique. 17: 884-885.
5. LAIRD, M. and F. A. LARI. 1957. The avian blood parasite *Babesia moshkovskii* (Schurenkova, 1938), with a record from *Corvus splendens*. Vieillot in Pakistan. Can. J. Zool. 35: 783-795.
6. LEVINE, N. D. 1971. Taxonomy of the piroplasms. Tr. Am. Micro. Soc. 90: 2-33.
7. LEVINE, N. D. 1973. *Protozoan Parasites of Domestic Animals and of Man*. 2nd Ed. Burgess, Minneapolis. pp. 335.
8. LUCAS, A. M. and C. JAMROZ. 1961. *Atlas of Avian Hematology*. Agri. Monograph 25; USDA Washington, D.C. pp. 271.
9. MOHAMMED, A. H. H. 1958. *Systematic and Experimental Studies on Protozoal Blood Parasites of Egyptian Birds*. 1:2 Cairo Univ. Press, pp. 77-104.
10. SCHURENKOVA, A. I. 1938. *Sogdianella moshkovskii* gen. nov. sp. nov. A parasite belonging to the Piroplasmidea in a raptorial bird, *Gypaetus barbatus* (L.) Med. Parazitol. Parazitar. Bolezni. 7: 932-937.
11. SERGENT, ED. 1941. *Aegyptianella pullorum* Carpano, 1929 = *Aegyptianella granulosa peneirans* (Balfour, 1911) chez la caille, *Coturnix coturnix* (L.) en Algerie. Arch. Inst. Pasteur Algerie. 19: 26-28.
12. TOUMANOFF, C. 1940. La Parasite sanguin endoglobulaire du heron cendre de l'Indochine (*Ardea cinerea* var. *rectirostris* Gould) *Babesia* (*Nicollia*) *ardeae* nov. sp. Rev. Med. Franc. d'Extreme-Orient. 18: 491-496.
13. VON WASIELEWSKI, T. K. W. N. and G. WULKER. 1918. Die *Hämoproteus* Infektion des Turmfalken. Beihefte (2), Arch. Schiffs-u. Tropenhyg. 22: 1-100.
14. WILLIAMS, R. B. 1947. Infestation of Raportials by *Ornithodoros aquilae*. Auk. 64: 185-188.

Received for publication 23 September 1974