



UNIDENTIFIED KIDNEY INCLUSION BODIES IN A LEAD-POISONED LORIKEET

Author: GOUGH, A. W.

Source: Journal of Wildlife Diseases, 12(3) : 390-391

Published By: Wildlife Disease Association

URL: <https://doi.org/10.7589/0090-3558-12.3.390>

BioOne Complete (complete.BioOne.org) is a full-text database of 200 subscribed and open-access titles in the biological, ecological, and environmental sciences published by nonprofit societies, associations, museums, institutions, and presses.

Your use of this PDF, the BioOne Complete website, and all posted and associated content indicates your acceptance of BioOne's Terms of Use, available at www.bioone.org/terms-of-use.

Usage of BioOne Complete content is strictly limited to personal, educational, and non - commercial use. Commercial inquiries or rights and permissions requests should be directed to the individual publisher as copyright holder.

BioOne sees sustainable scholarly publishing as an inherently collaborative enterprise connecting authors, nonprofit publishers, academic institutions, research libraries, and research funders in the common goal of maximizing access to critical research.

UNIDENTIFIED KIDNEY INCLUSION BODIES IN A LEAD-POISONED LORIKEET

A. W. GOUGH, Veterinary Services Laboratory, Ontario Ministry of Agriculture and Food,
Guelph, Ontario, Canada N1H 6R8

L. SILEO,[†] Department of Pathology, University of Guelph, Guelph, Ontario, Canada N1G 2W1

Abstract: A lorikeet (unidentified species of subfamily Loriinae), which died of coliform septicemia subsequent to an esophageal ulcer also had intranuclear inclusion bodies in the proximal convoluted tubular lining cells of the kidney. The ultrastructure of these inclusion bodies was compared with those described in experimental lead-induced inclusion bodies of rats.

INTRODUCTION

A dead male lorikeet (unidentified species of subfamily Loriinae) from the Metropolitan Toronto Zoo, was submitted to the Wildlife Disease Laboratory, Department of Pathology on 14 March 1974. Caged with another lorikeet, this bird was noticed fighting frequently on 10 March. On 11 March, this bird was placed in a separate cage and was found dead in the early morning of 13 March. No further mortality in the lorikeets at the zoo was reported.

A thorough post-mortem examination was performed and a definitive diagnosis of coliform septicemia subsequent to an esophageal ulcer was made. Coincidental with the diagnostic findings, intranuclear inclusion bodies were found in the proximal convoluted tubular epithelia of the kidney. An investigation was launched to discover the cause of these inclusion bodies.

RESULTS AND DISCUSSION

Intranuclear inclusion bodies were found in the proximal convoluted tubular epithelia of the kidney. On hematoxylin and eosin (H & E) stain, the nucleus of these cells was swollen and contained a large, pale, eosinophilic inclusion (Fig. 1). Lead poisoning was considered, and

several acid-fast stains were attempted. The faint outline of most inclusions were discernible on sections stained by the Ziehl-Neelsen acid-fast method. However, very few of these inclusions were acid-fast.

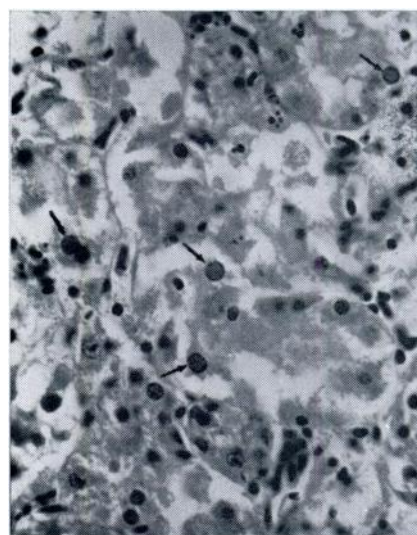


FIGURE 1. Histologic section of kidney illustrating marked autolytic change and acidophilic intranuclear inclusion bodies (arrows). H&E stain. X800.

[†] Present address: P.O. Box 29202, Kabete, Kenya.

The lead concentrate of liver tissue was analysed and found to be 4.5 ppm.

Intranuclear inclusion bodies morphologically resembling those seen on H & E stained sections were observed on electron microscopic examination of kidney tissue. These inclusions did not resemble the lead-induced inclusions described by

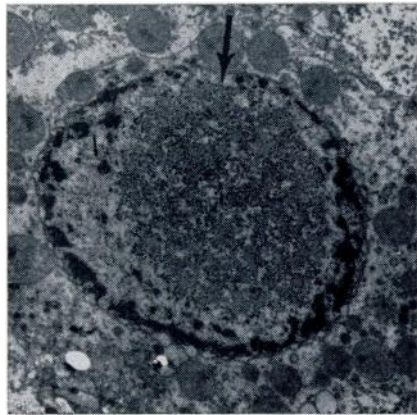


FIGURE 2. Electronmicrograph of inclusion body (large arrow) and fibrillar element (small arrow) in the nucleus of tubular epithelial cell. Separation of nuclear membranes and margination of chromatin are the result of cell death (i.e. autolysis).

Uranyl-acetate and Renold's lead stain X 6, 500.

Goyer and others.^{1,2,3,6} in rats. Moreover, typical "lead" inclusions were not found in several grids examined under the electron microscope. This is not surprising, since only two to three acid-fast inclusions were recognized in any given histological kidney section.

The ultrastructure of the unidentified inclusions consisted of fine granular structure of medium density. Fibrillar elements were located in the light density area between the nuclear membrane and inclusion body (Fig. 2). These fibrillar elements are similar to the structures which compose the outer filamentous zone of a lead-induced inclusion.³

Goyer³ did chemical analysis of isolated lead-induced inclusions and discovered that they contained both lead and protein in the form of a lead-protein complex. Moore⁴ suggested that morphologically distinguishable inclusion bodies may only occur when lead-protein complexing is sufficient to form aggregates. The fibrillar elements in the inclusion-bearing nuclei of this lorikeet may represent foci of lead-protein complexes which have not aggregated to form "lead" inclusions. Consequently, very few distinct acid-fast inclusions were observed.

The granularity and density of the unidentified inclusion body is similar in structure to a nucleolus⁵ and hence these inclusions, in actuality, may be enlarged nucleoli in metabolically active cells.

LITERATURE CITED

1. ANGEVINE, J. M., A. KAPPAS, R. L. DE GOWIN and B. H. SPARGO. 1962. Renal tubular nuclear inclusions in lead poisoning. A clinical and experimental study. *Arch. Path. (Chicago)*. 73: 486-490.
2. BEAVER, D. L. 1971. The ultrastructure of the kidney in lead intoxication with particular reference to intranuclear inclusions. *Am. J. Path.* 39: 195-201.
3. GOYER, R. A., P. MAY, M. M. CATES and M. R. KRIGMAN. 1970. Lead and protein content of isolated intranuclear inclusion bodies from kidneys of lead poisoned rats. *Lab. Invest.* 22: 245-251.
4. MOORE, J. F., R. A. GOYER and M. WILSON. 1973. Lead-induced inclusion bodies. Solubility, amino acid content and relationship to residual acidic nuclear protein. *Lab. Invest.* 29: 488-495.
5. RHODIN, J. A. 1963. *An Atlas of Ultrastructure*. 1st Edition. W. B. Saunders Co., Philadelphia and London.
6. RICHTER, G. W., Y. KRESS and C. C. CORNWALL. 1968. Another look at lead inclusion bodies. *Am. J. Path.* 53: 189-195.

Received for publication 6 August 1975