

Notoedres muris INFESTATION IN A NAKED-TAILED RAT *Melomys cervinipes*

Authors: McKENZIE, R. A., GREEN, P. E., and KNOX, ELIZABETH

Source: Journal of Wildlife Diseases, 12(4) : 486-487

Published By: Wildlife Disease Association

URL: <https://doi.org/10.7589/0090-3558-12.4.486>

BioOne Complete (complete.BioOne.org) is a full-text database of 200 subscribed and open-access titles in the biological, ecological, and environmental sciences published by nonprofit societies, associations, museums, institutions, and presses.

Your use of this PDF, the BioOne Complete website, and all posted and associated content indicates your acceptance of BioOne's Terms of Use, available at www.bioone.org/terms-of-use.

Usage of BioOne Complete content is strictly limited to personal, educational, and non - commercial use. Commercial inquiries or rights and permissions requests should be directed to the individual publisher as copyright holder.

BioOne sees sustainable scholarly publishing as an inherently collaborative enterprise connecting authors, nonprofit publishers, academic institutions, research libraries, and research funders in the common goal of maximizing access to critical research.

Notoedres muris INFESTATION IN A NAKED-TAILED RAT *Melomys cervinipes*

R. A. MCKENZIE, P. E. GREEN and ELIZABETH KNOX, Queensland Department of Primary Industries, Animal Research Institute, Yeerongpilly, Brisbane 4105, Australia

Abstract: Large numbers of *Notoedres muris* were present in thick crusty lesions on both ears, the nose, one forelimb and tail-base of a free-living naked-tailed rat, *Melomys cervinipes*, on North Stradbroke Island, Queensland, Australia. The source of infestation was obscure.

INTRODUCTION

Notoedric mange due to *Notoedres muris* has been recorded in the laboratory rat (*Rattus norvegicus*), the black rat (*Rattus rattus*), the multimammate mouse (*Praomys natalensis*) and wild rodents in North America, Europe and Africa.² In Australia, *N. muris* has been recorded from the brush-tailed possum (*Trichosurus vulpecula*) and the brindled bandicoot (*Isodon macrourus*).¹ Infestations of Australian feral rodents by *N. muris* appear to be unrecorded. This report is of a case in a free-living native rat (*Melomys cervinipes* Gould, 1852).

CASE REPORT

A female *Melomys cervinipes* was captured at the Eighteen Mile Swamp, North Stradbroke Island off the eastern Australian coast. At the time of capture, gross thickenings of the external ears were noted. The animal died in captivity and was examined at necropsy.

Thick yellow crusts were present on the dorsal surface of the pinnae of both ears (Fig. 1), on the dorsal surface of the left forelimb and on the skin of the dorsum of the nose. A few small scaly lesions, approximately 0.2 cm in diameter, were present on the tail near its base. The lesions were most severe on the pinnae, where the crusts contained some areas of haemorrhage, were 1.5 cm thick and covered the entire dorsal surface. The normal pinnae were approximately 0.1 cm thick. The lesion on the nose was 0.5 cm thick, and covered an area 2.0 cm x 1.0 cm.

Examination of the lesions for dermatophytes and *Dermatophilus congolensis* was negative.

Histologically, the lesions consisted of very thickened parakeratotic stratum corneum perforated by numerous tunnels containing many mites, mite eggs and excreta. The stratum corneum was heavily infiltrated by neutrophils. The remaining epidermis was acanthotic, and the dermis was congested and heavily infiltrated by neutrophils and mononuclear inflammatory cells. The inflammatory response did not involve the cartilage of the pinna. These changes were consistent with those described in notoedric mange of laboratory rats.²

Scrapings from the lesions contained numerous mites identified as *Notoedres muris* (Megnin, 1877).¹

DISCUSSION

Naked-tailed or mosaic-tailed rats of the genus *Melomys* are widely distributed in New Guinea, the Solomon Islands and northern and eastern Australia. *M. cervinipes* is adapted for an arboreal life and inhabits closed forests of the eastern Australian coast from northern New South Wales to Cape York.⁴ On North Stradbroke Island, this species is confined to a narrow strip of closed palm forest bordering the Eighteen Mile swamp on the eastern coast.³

There appears to be no published information on the occurrence and distribution of *N. muris* in rodents in Australia, thus we are unable to comment at

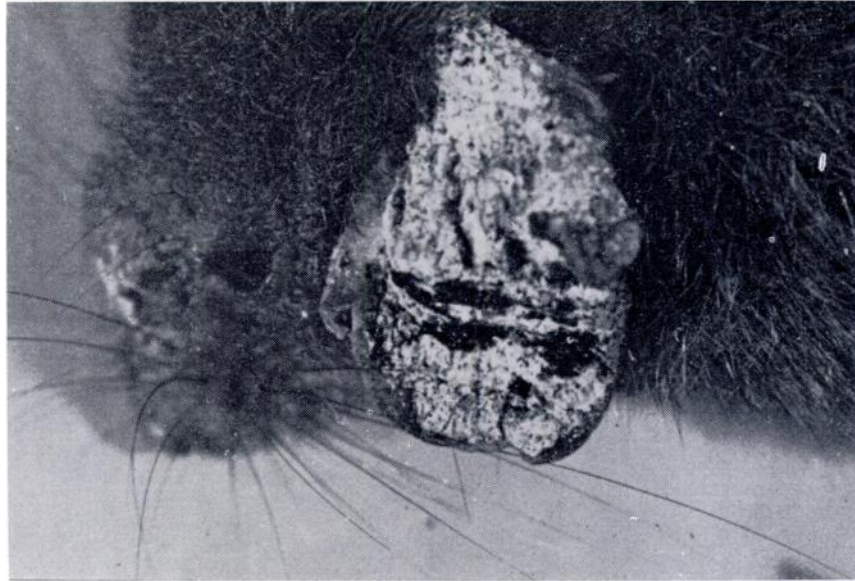


FIGURE 1. Lesion on pinna of *Melomys cervinipes* due to *Notoedres muris* Infestation.

length on the epizootiological circumstances leading to the present case. Transmission of *N. muris* is thought to be by direct contact, but experimental transmission by *Musca domestica* has been demonstrated.³ The former method probably led to this case, but the latter cannot be discounted, as native rats are thought unlikely to come into frequent contact with *Rattus norvegicus*, the prob-

able major host of *N. muris* on North Stradbroke Island.

Whatever the epizootiology of the case, the capability of *N. muris* to naturally infest free-living native rodents has been demonstrated. Thus this parasite probably exists latently in the Queensland mammalian fauna as a viable population hitherto unrecognised apart from one case in a bandicoot (*Isodon macrourus*) seen in 1955.⁴

Acknowledgements

We wish to thank Dr. R. Domrow, Queensland Institute of Medical Research, Brisbane, for identification of the mites.

LITERATURE CITED

1. DOMROW, R. 1974. Miscellaneous mites from Australian Vertebrates 1-48. Proc. Linn. Soc. N.S.W. 99: 15-35.
2. FLYNN, R. J. 1973. *Parasites of Laboratory Animals*. Iowa State University Press, Ames, Iowa.
3. MARTIN, J. H. D. 1975. A List of Mammals from Stradbroke Island. Proc. R. Soc. Qd. 86: 73-76.
4. TROUGHTON, E. 1973. *Furred Animals of Australia*. 9th Edition revised. Angus and Robertson, Sydney.

Received for publication 21 July 1975