

## **Dipetalonema spirocauda INFECTION IN THE ATLANTIC HARBOR SEAL (*Phoca vitulina concolor*) 1**

Author: DUNN, J. LAWRENCE

Source: Journal of Wildlife Diseases, 12(4) : 531-538

Published By: Wildlife Disease Association

URL: <https://doi.org/10.7589/0090-3558-12.4.531>

---

BioOne Complete ([complete.BioOne.org](https://complete.BioOne.org)) is a full-text database of 200 subscribed and open-access titles in the biological, ecological, and environmental sciences published by nonprofit societies, associations, museums, institutions, and presses.

Your use of this PDF, the BioOne Complete website, and all posted and associated content indicates your acceptance of BioOne's Terms of Use, available at [www.bioone.org/terms-of-use](https://www.bioone.org/terms-of-use).

Usage of BioOne Complete content is strictly limited to personal, educational, and non - commercial use. Commercial inquiries or rights and permissions requests should be directed to the individual publisher as copyright holder.

---

BioOne sees sustainable scholarly publishing as an inherently collaborative enterprise connecting authors, nonprofit publishers, academic institutions, research libraries, and research funders in the common goal of maximizing access to critical research.

## *Dipetalonema spirocauda* INFECTION IN THE ATLANTIC HARBOR SEAL (*Phoca vitulina concolor*)<sup>1</sup>

J. LAWRENCE DUNN,\* Mystic Marinelife Aquarium, Mystic, Connecticut 06355, USA

R. E. WOLKE, Department of Animal Pathology, University of Rhode Island, Kingston, Rhode Island 02881, USA

**Abstract:** The clinical and pathologic effects of the filarioid nematode *Dipetalonema spirocauda* were studied in the harbor seal, *Phoca vitulina concolor*. Aberrant behavior of both adults and microfilariae resulted in previously unreported pulmonary, vascular and hepatic lesions.

### INTRODUCTION

The first reports of filarioid nematodes in the cardiovascular systems of phocids were from the harbor seal, *Phoca vitulina*, and the ringed seal, *Pusa hispida*, in 1858.<sup>1</sup> Since then they have been reported in another phocid, the hooded seal, *Cystophora cristata*.<sup>11</sup> The confused taxonomy of these nematodes was clarified by Anderson in 1959 and the name *Dipetalonema spirocauda* assigned. His review indicated that the occurrence of *Dirofilaria immitis* in pinnipeds could be verified only in California sea lions, *Zalophus californianus*.<sup>3</sup> Since that time there have been additional reports of *D. immitis* infections in *P. vitulina*<sup>2,13,17</sup> and *Z. californianus*.<sup>9,28</sup> The issue has been further complicated by the presence of another filarioid, *Dipetalonema odendhali*, in otarids.<sup>6,20,21</sup>

In North America *D. spirocauda* has been reported from harbor seals from Puget Sound,<sup>16</sup> in southern California,<sup>23,25,</sup> New England,<sup>3</sup> and Atlantic Canadian Maritime populations.<sup>7</sup>

This report details the clinical and previously undescribed pathologic changes seen in Atlantic harbor seals, *Phoca vitulina concolor*, infected with *D. spirocauda* and summarizes the available information on the parasite's life history.

### MATERIALS AND METHODS

The material presented was obtained from three harbor seals found dead or dying on the Rhode Island and Connecticut coastlines and from five harbor seals maintained at Mystic Marinelife Aquarium in Mystic, Connecticut.

The beached animals were: an approximately one-year-old male (C76), a young, one-meter-long female (C237), both found on Rhode Island beaches, and a young, 35 kg male (E99) found entangled in a net in a Connecticut inlet.

The five captive animals (males 108, 206; females 104, 110, 201) were all born in mid-May, 1973, on Sable Island, Nova Scotia. The animals were removed from the island early in June and taken to Dalhousie University in Halifax, Nova Scotia, where they resided in an outdoor pool with several other harbor seals of varying ages. In late June they were transported to Mystic, Connecticut, where they have been kept inside the aquarium in an air-conditioned exhibit.

Blood samples from the captive animals were obtained from the extradural vein while the animals were manually restrained. Microfilaremia was determined by use of the direct smear or the filter membrane technique.<sup>22</sup>

<sup>1</sup> This study was supported in part by a grant from Mystic Marinelife Aquarium and from Sea Grant funds of the University of Rhode Island. Contribution No. 1671 of the Rhode Island Agricultural Experiment Station.

<sup>2</sup> Wylie Heartworm Diagnostic Kit: E. R. Squibb & Sons, Inc., Princeton, New Jersey 08540, USA.

\* Dr. Dunn's present address is Department of Animal Pathology, University of Rhode Island, Kingston, Rhode Island 02881, USA.

All tissues for histologic examination were fixed in 10% buffered formalin, embedded in paraffin, sectioned at 6  $\mu$ m and stained with hematoxylin and eosin.

Adult *D. spirocauda* were preserved in AFA or 10% buffered formalin.

## RESULTS

### Clinical

Much of the early clinical history of the captive animals has been reviewed previously.<sup>7</sup> Animals 108, 201, and 206 were treated with niclosamide<sup>3</sup> at a dosage of 110 mg/kg when at the age of three months they began passing segments of an unidentified cestode. At the age of four months all animals were administered dichlorvos<sup>4</sup> at a dosage of 30 mg/kg. Blood samples from the animals in September, 1973, were negative for microfilariae, whereas in January, 1974, all animals except 110 had microfilariae identified as *D. spirocauda*. Animal 110 continued negative for microfilariae in six additional samplings conducted during the next nine months.

In September, 1974, 110 (38 kg ♀) was anesthetized with 6.5 mg/kg ketamine hydrochloride,<sup>5</sup> a level at the low end of the range recommended for surgical anesthesia of seals.<sup>10</sup>

Shortly after completion of a biopsy procedure the animal went into respiratory arrest. It was manually ventilated but, within one min, its heartbeat became markedly arrhythmic and cardiac arrest ensued. Intracardial injections of epinephrine were unsuccessful in initiating normal cardiac rhythm.

The second captive animal (108) was a 45 kg male which died during a blood sampling procedure in November, 1974. The usual sampling procedure was followed uneventfully in this animal, but at the completion of the sampling, the animal was noted to be dyspneic and within minutes both cardiac and respiratory activity ceased. Intubation, ventila-

tion and intracardial epinephrine were employed without success.

On several occasions since late 1974, animal 201 has experienced severe hemoptysis. On one such occasion at least three living *D. spirocauda* were expelled.

Microfilaremia persists in two of the three surviving captive harbor seals.

### Gross Pathology

All seals examined appeared in a normal nutritional state. One of the wild animals (C76) had been frozen and was in an advanced state of postmortem autolysis. Seal E99 was heavily infested with *Echinophthirus horridus*.

Gross lesions were present in the lungs, heart, great vessels and the liver.

In all animals except 110, adult filarioids identified as *Dipetalonema spirocauda* were present in both the right heart (atrium; ventricle) and pulmonary artery. In one instance the worms extended into the pulmonary artery approximately 15 cm and were responsible for complete occlusion. The number of worms in each heart varied from five in seal C76 to 86 in seal E99. No ventricular dilatation or hypertrophy were noted. Ten adult *D. spirocauda* were found in the pulmonary artery of 110; none were present in the heart.

Two of the feral animals (C76; C237) were heavily infested with lungworms (*Otostrongylus circumlitus*). In these animals, patchy red consolidated areas were randomly distributed throughout the lobes of the lung. Lungworms were present in a mucinous froth within the bronchi. Focal, circumscribed, hard (0.5-1 cm) areas were palpable within the parenchyma. On cut section, these masses contained white caseous material.

The lungs of the remaining three seals were free of pulmonary nematodes. All were reddish purple in color, mottled, failed to collapse completely, and were wet on cut surface. The lungs of one

<sup>3</sup> Yomesan: Baychem Corporation, Kansas City, Missouri 64120, USA.

<sup>4</sup> Task: Shell Chemical Company, San Ramon, California 94583, USA.

<sup>5</sup> Vetalar: Parke Davis & Company, Detroit, Michigan 48232, USA.

(E99) had small (0.5 cm) focal areas composed of a white caseous material. All livers had small (1-5 mm), level, round, white foci on their surfaces. These areas were also present within the parenchyma on cut surface and were random in distribution.

No intermediate stages of *D. spirocauda* were seen in squash preparation of 100 lice taken from seal E99. Attempts to isolate bacteria on blood agar from the heart, lungs and liver of seals 103 and 110 were unsuccessful.

#### Histopathology

Lesions related to *D. spirocauda* infection were present in the vascular system, lungs, liver and spleen. The lesions could be attributed to either the adult or the microfilariae of the parasite.

**Vascular system:** Masses of the adult parasites were present in the pulmonary artery. Their contact with the arterial intima resulted in a villous proliferation of the endothelial layer. The usually flattened intima increased greatly in thickness and was thrown into intricate folds resembling intestinal villi (Figure 2). In some instances, the intimal width was equal to the combined widths of the tunica media and tunica adventitia. Endothelial cells were rounded to ovoid in shape and often lay at right angles to the long axis of the artery. Many of these cells, however, retained their normal flattened appearance. Hyperplasia of the endothelium was present, but was not the primary cause of intimal thickening. The portion of the intima responsible for its increase in width was the connective tissue layer between the endothelium and the internal elastic membrane. This layer contained proliferating fibroblasts and was loose and edematous in appearance. No inflammatory cells were associated with the proliferation.

In one of the feral seals (E99) vermiform emboli were present in the smaller branches of the pulmonary arteries. The emboli were composed of degenerating adult nematodes. There was necrosis of the arterial wall and an eosinophilic granulomatous arteritis.

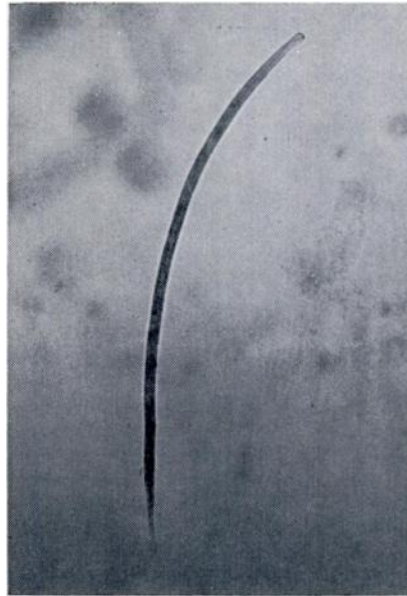

FIGURE 1. Microfilaria of *Dipetalonema spirocauda*. X1000

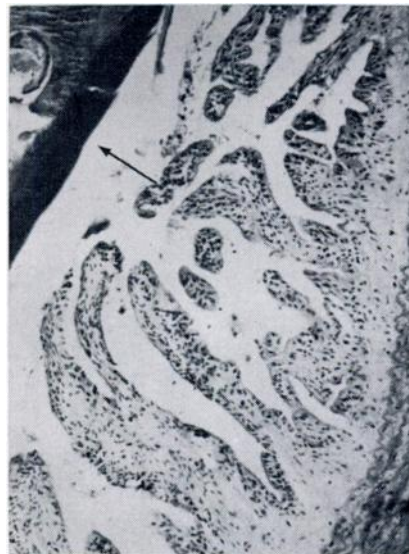

FIGURE 2. Massive villous proliferation of the aortic endothelium. A portion of adult parasite (arrow) is seen in upper right corner. X1000 H & E.

The lesions associated with microfilariae were an acute vasculitis and perivasculitis and were found in all five seals. Frequently, microfilariae were present free within the lumen of vessels and were unrelated to any pathologic changes. However, in other instances an acute vasculitis and perivasculitis was present in relation to apparent migration tracts of the microfilariae (Figure 3). Such lesions were present in the liver and lung. The wall of the vessel was disrupted and infiltrated by eosinophils and mononuclear cells, primarily lymphocytes.

The smaller ramifications of the pulmonary artery often had hypertrophy of the medial layer and some proliferation of the endothelium.

Liver: Focal areas of necrosis with both acute and chronic inflammation were randomly distributed throughout the livers of affected animals.

The acute foci were frequently proximal to a vessel and occasionally contained microfilariae. Hepatocytes within the foci were necrotic or absent. The lesions were spongy and loose in nature and composed of fibroblasts, lymphocytes and eosinophils (Figure 3).

The more chronic manifestations of these lesions were either collections of lymphocytes or granulomas characterized by reticulo-endothelial cells with an occasional giant cell. Microfilariae were not seen in the chronic lesions (Figure 4).

Spleen: Randomly distributed granulomas with occasional foreign body giant cells were present in the spleen of one animal. No microfilariae were found in the centers of these granulomas.

Lung: Two of the wild seals (C76; C237) also were infected by the pulmonary nematode *Otostrongylus circumlitis*. The resulting verminous pneumonia masked the pulmonary lesions attributable to the filarial worms alone. However, none of the other three seals had lungworms and pulmonary lesions were present which ranged from acute interstitial pneumonia to eosinophilic granulomatous pneumonia.



FIGURE 3. Vasculitis and perivasculitis of hepatic vessel (white arrow) with migration tracts to two adjacent necrotic foci. Two microfilariae are present within foci (arrow heads). X 100 H & E.




FIGURE 4. Focus of hepatic granulomatous inflammation with a solitary giant cell (arrow). X 160 H & E.

The acute pneumonitis was characterized by a thickening of the interstitium with a mixture of inflammatory cells including occasional eosinophils.

The eosinophilic granulomatous pneumonia (E99) was present in relation to verminous emboli. The reaction often was quite fibrous and a few microfilariae were found free within the inflammatory tissue. The granuloma was characterized by a central area of necrosis surrounded by eosinophils in turn bounded by histiocytes, macrophages and giant cells. These granulomas were often bounded by connective tissue.

#### DISCUSSION

The life cycle of *D. spirocauda* remains a mystery. The transmission of infective larvae can occur at an early age as evidenced by reports of heartworms present in the cardiovascular system of harbor seals estimated on the basis of size to be only one month of age.<sup>25</sup> Microfilaremia was not reported in these animals. In beach-stranded phocids, size is an unreliable indicator of age. In a six-month-old female harbor seal from the Puget Sound area, both adult and microfilarial *D. spirocauda* were present.<sup>10</sup> Large numbers of circulating microfilariae also were present in four of the five eight-month-old harbor seals in this study. The available evidence indicates that in harbor seals *D. spirocauda* reaches the cardiovascular system and attains sexual maturity in six months or less.

*E. horridus*, by virtue of its ubiquitous distribution and a near 100% prevalence in feral harbor seals, has been suspected as the intermediate host of *D. spirocauda*.<sup>18</sup> Walker<sup>26</sup> was justly criticized by Delyamure<sup>9</sup> for maintaining, without supporting evidence, that *E. horridus* was the intermediate host. No intermediate stages of *D. spirocauda* were found in *E. horridus* by Taylor *et al.*<sup>5</sup> or in this study.

The long periods of time spent hauled-out on beaches leave harbor seals, especially pups, vulnerable to attack by blood-sucking arthropods. Mosquitoes and simuliids are frequently present in large numbers in haul-out areas on the New England and Canadian coastlines and should be examined more intensively for their possible role in transmission of heartworm in seals.

A recently published report on the presence of *D. immitis*<sup>17</sup> in a captive harbor seal is deserving of comment. This animal lived in close proximity to a California sea lion with a confirmed *D. immitis* infection.<sup>6</sup> The absence of circulating microfilariae six months prior to death could have been due to sterility or immaturity of the heartworms, the presence of heartworms of only one sex or, as the authors suggested, immunity inhibiting the development of the microfilaremia or the fact that the seal is an unnatural host for *D. immitis*. Seal 110 in the present study never developed a detectable microfilaremia even though adult *D. spirocauda* of both sexes were present within the pulmonary artery and a few microfilariae were found in the tissue sections. The presence of adult *D. immitis* including gravid females without a detectable circulating microfilaremia has been reported in the dog.<sup>22</sup>

Identifications in other reports<sup>8,13</sup> describing a *D. immitis* infection in a harbor seal are suspect as they do not describe the parasite and give no information as to how the parasite was identified. Thus, the possibility exists that the parasite involved in this case was *D. spirocauda*, making Medway's report<sup>17</sup> the first and only verified case of *D. immitis* in a pinniped other than the California sea lion. A possible explanation for the development of this case is that passage of *D. immitis* through the sea lion host in some way altered its antigenicity thereby permitting its establishment in another pinniped species which could not normally act as a host to this parasite.

<sup>6</sup> Medway, W. 1975. Personal communication. School of Veterinary Medicine, University of Pennsylvania, Philadelphia, Pennsylvania 19104, USA.

If this hypothesis is correct, the establishment of *D. immitis* infections in feral sea lions could result in infection of other pinniped species which live in close association with sea lions, such as the harbor seal, *Phoca vitulina richardii*, and the northern elephant seal, *Mirounga angustirostris*. One recent report suggests that, after the dog, the California sea lion is one of the most susceptible hosts for *D. immitis*.<sup>19</sup>

The behavior of the parasites in seal 201 should be considered aberrant. Presumably the worms either migrated or travelled as emboli into the pulmonary vasculature. They then penetrated the airways from which they were expelled as the animal coughed. A similar occurrence has been reported in the dog.<sup>4</sup> The significance of the absence of detectable circulating microfilariae in the most recent samples from this animal has not yet been determined. A sea lion with a *D. immitis* infection experienced similar episodes of hemoptysis.<sup>20</sup> The enclosure housing the animal did not permit close observation, so it was impossible to determine whether heartworms were expelled during any of these episodes.<sup>7</sup>

It is of interest to note the manner in which the seal responds to intravascular filarioids in contrast to other species infected with similar parasites.

Villous endothelial proliferation in relation to adult parasites in direct contact with the intima has been reported in the fox and dog.<sup>1,12,15,24,27</sup> Unlike the seal, however, an inflammatory component was present in conjunction with the proliferation in the fox. Similarly, endothelial and medial hypertrophy of smaller pulmonary arterial ramifications have been reported in these species.

Pulmonary lesions reported in other animals are similar to those observed in the seal. In most instances, the primary change has been interstitial pneumonia.<sup>1</sup> Eosinophilic granulomatous pneumonia has been reported in the dog.<sup>1</sup> The granulomatous response appears due to ver-

minous emboli and follows death and disintegration of adult parasites. The role of microfilariae in the reaction is unknown. Microfilariae were occasionally observed within seal lungs adjacent to the granulomatous response. They were not observed in the center of such granulomas and appeared incidental to the lesion.

The hepatic lesions appear unique to the seal. Focal areas of necrosis, acute eosinophilic inflammation and eventual focal granulomas in relation to microfilariae have not been previously reported. Taylor *et al.*<sup>28</sup> reported foci of necrosis in the liver of one seal. Histologically, this was described as a "chronic infection". No reference to etiology was made, although bacteria was a suggested possibility. In addition, an acute eosinophilic vasculitis and perivasculitis was present in the liver of the seals in the present study. Tracts of inflammation were observed between the affected vessel and the parenchymal foci of eosinophils. An interesting hypothesis is that the microfilariae have penetrated the vessel walls resulting in vasculitis and travelled into the parenchyma producing migration tracts to the inflammatory foci. However, such activity on the part of the larval form of the parasite is antithetic to its evolutionary development. Consideration of dipetalonematid evolution points out that the presence of microfilariae in the blood stream is the most efficient method to assure their spread to new hosts.<sup>2</sup> Reinvasion of other organs not easily accessible to a blood-sucking vector would, therefore, be self-defeating. Aberrant parasite behavior and the ability to elicit severe host response may indicate that the parasite is not well adapted to the host or that the parasitized animal is not the normal host.<sup>5</sup>

Since *D. spirocauda* has not been reported affecting animals other than phocids, its apparent aberrant behavior may indicate in evolutionary terms, a short-lived host/parasite relationship.

<sup>7</sup> White, G. L. 1975. Personal communication. Division of Comparative Medicine, University of Oklahoma Health Sciences Center, Oklahoma City, Oklahoma 73190, USA.

**Acknowledgements**

The authors are grateful to Dr. Roy C. Anderson of the Department of Zoology of the University of Guelph and Dr. Lawrence D. Roberts of the Department of Zoology of the University of Massachusetts for assistance with parasite identifications. Dr. William Medway of the School of Veterinary Medicine of the University of Pennsylvania kindly provided samples of *D. immitis* from a harbor seal. The animals discussed in this report were procured by Dr. R. W. Dykes, Department of Physiology and Biophysics, Dalhousie University, Halifax, Nova Scotia, with the assistance of NRC and MRC funds from the Canadian Government, and by Dr. H. E. Winn of the Graduate School of Oceanography, University of Rhode Island, Kingston, Rhode Island.

**LITERATURE CITED**

1. ADCOCK, J. O. 1961. Pulmonary arterial lesions in canine dirofilariasis. *Am. J. vet. Res.* 22: 655-662.
2. ANDERSON, R. C. 1957. The life cycle of dipetalonematid nematodes (Filarioidea, Dipetalonematoidea): The problem of their evolution. *J. Helminthol.* 31: 203-224.
3. ———. 1959. The taxonomy of *Dipetalonema spirocauda* (Leidy, 1858) N. comb. (= *Skrjabinaria spirocauda*) and *Dirofilaria reomeri* (Linstow, 1905) N. comb. (= *Dipetalonema reomeri*). *Can. J. Zool.* 37: 481-493.
4. BORING, J. G. 1975. Radiographic diagnosis of heartworm disease. *Proc. Heartworm Symp. 1974* (Ed. H. C. Morgan) VM Publishing, Inc., Bonner Springs, Kansas.
5. CHENG, T. 1964. *Biology of Animal Parasites*. W. B. Saunders Co. Philadelphia and London. pp. 465.
6. DELYAMURE, S. L. 1955. *Helminthofauna of Marine Mammals*. Academy of Science USSR, Moscow. (translated from Russian), U.S. Dept. of the Interior and Nat. Sci. Found., Washington, D.C., 1968.
7. DUNN, J. L. and S. SPOTTE. 1974. Some clinical aspects of seal pox in captive Atlantic harbor seals. *J. Zoo. an. Med.* 5, no. 4: 27-30.
8. ERIKSEN, E. 1962. Diseases of seals in the Copenhagen Zoo. *Nord. vet.-Med.* 14: Suppl. 1, 141-149.
9. FORRESTER, D. J., R. F. JACKSON, J. F. MILLER and B. C. TOWNSEND. 1973. Heartworms in captive California sea lions. *J. Am. vet. med. Ass.* 163: 568-570.
10. GERACI, J. R. 1973. An appraisal of ketamine as an immobilizing agent in wild and captive pinnipeds. *J. Am. vet. med. Ass.* 163: 574-577.
11. HELLE, O. and A. S. BLIX. 1973. Some morphologic characteristics of *Dipetalonema spirocauda* Leidy, 1858, isolated from the hooded seal, *Cystophora cristata* Erxleben, 1777. *J. Parasit.* 59: 217-218.
12. HIRTH, R. S. and S. W. NEILSEN. 1966. Vascular lesions of *Dirofilaria immitis* in the red fox. *J. Am. vet. med. Ass.* 149: 915-919.
13. LARSEN, S. 1962. A survey of post mortem findings in Pinnipedia autopsied during the ten year period 1952-1961. *Nord. vet.-Med.* 14: Suppl. 1, 150-160.
14. LEIDY, T. 1858. Contributions to helminthology. *Proc. acad. nat. sci. Phila.* 10: 110-112.
15. LIU, S. I., K. M. DAS and R. J. TASHIJAN. 1966. Adult *Dirofilaria immitis* in the arterial system of a dog. *J. Am. vet. med. Ass.* 148: 1501-1507.
16. MacDONALD, D. W. and E. W. GILCHRIST. 1969. *Dipetalonema spirocauda* and *Pseudomonas aeruginosa* infection in a harbor seal (*Phoca vitulina*). *Can. vet. J.* 10: 220-221.



17. MEDWAY, W. and T. C. WEILAND. 1975. *Dirofilaria immitis* infection in a harbor seal. J. Am. vet. med. Ass. 167: 549-550.
18. NATIONAL MARINE FISHERIES SERVICE. 1974. Administration of the Marine Mammal Protection Act of 1972. Fed. Reg. 39, no. 122: 23896-23932.
19. OTTO, G. F. 1975. Occurrence of the heartworm in unusual locations and in unusual hosts. Proc. Heartworm Symp. 1974. (Ed. H. C. Morgan) VM Publishing, Inc., Bonner Springs, Kansas.
20. PERRY, M. L. 1967. A new species of *Dipetalonema* from the California sea lion and a report of microfilariae from a Stellar sea lion (Nematoda: Filarioidea). J. Parasit. 53: 1076-1081.
21. ——— and D. J. FORRESTER. 1971. *Dipetalonema odendhali* (Nematoda: Filarioidea) from the northern fur seal, with a description of the microfilaria. J. Parasit. 57: 469-472.
22. SAWYER, T. K. 1975. The venae cavae syndrome in dogs experimentally infected with *Dirofilaria immitis*. Proc. Heartworm Symp. 1974 (Ed. H. C. Morgan) VM Publishing, Inc., Bonner Springs, Kansas.
23. SCHROEDER, R. J., C. A. DELLI QUADRI, R. W. McINTYRE and W. A. WALKER. 1973. Marine mammal disease surveillance program in Los Angeles County. J. Am. vet. med. Ass. 163: 580-581.
24. SIMPSON, C. F. and R. F. JACKSON. 1975. Pathophysiology of Heartworm Disease. Proc. Heartworm Symp. 1974. (Ed. H. C. Morgan) VM Publishing, Inc., Bonner Springs, Kansas.
25. SWEENEY, J. C. 1974. Common diseases of pinnipeds. J. Am. vet. med. Ass. 165: 805-810.
26. TAYLOR, A. E., D. H. BROWN, D. HEYNEMAN and R. W. McINTYRE. 1961. Biology of filarioid nematode *Dipetalonema spirocauda* (Leidy, 1858) from the heart of captive harbor seals and sea lions, together with pathology of the hosts. J. Parasit. 47: 971-976.
27. VON LICHTENBERG, F., R. F. JACKSON and G. F. OTTO. 1962. Hepatic lesions in dogs with dirofilariasis. J. Am. vet. med. Ass. 141: 121-128.
28. WHITE, G. L. 1975. *Dirofilaria immitis* and heartworm disease in the California sea lion. J. Zoo. an. Med. 6, no. 2: 23-24.
29. WULKER, G. 1930. Ueber Nematoden aus Nordeetieren I. Zool. anz. Leipzig. 87: 293-302.

Received for publication 4 March 1976