



A SURVEY OF BLOOD AND OTHER TISSUE PARASITES OF LEOPARD FROGS *Rana pipiens* IN THE UNITED STATES

Authors: LEVINE, NORMAN D., and NYE, RICHARD R.

Source: Journal of Wildlife Diseases, 13(1) : 17-23

Published By: Wildlife Disease Association

URL: <https://doi.org/10.7589/0090-3558-13.1.17>

BioOne Complete (complete.BioOne.org) is a full-text database of 200 subscribed and open-access titles in the biological, ecological, and environmental sciences published by nonprofit societies, associations, museums, institutions, and presses.

Your use of this PDF, the BioOne Complete website, and all posted and associated content indicates your acceptance of BioOne's Terms of Use, available at www.bioone.org/terms-of-use.

Usage of BioOne Complete content is strictly limited to personal, educational, and non - commercial use. Commercial inquiries or rights and permissions requests should be directed to the individual publisher as copyright holder.

BioOne sees sustainable scholarly publishing as an inherently collaborative enterprise connecting authors, nonprofit publishers, academic institutions, research libraries, and research funders in the common goal of maximizing access to critical research.

A SURVEY OF BLOOD AND OTHER TISSUE PARASITES OF LEOPARD FROGS *Rana pipiens* IN THE UNITED STATES

NORMAN D. LEVINE and RICHARD R. NYE, College of Veterinary Medicine and Agricultural Experiment Station, University of Illinois, Urbana, Illinois 61801, USA

Abstract: In a survey of blood and other tissue parasites from 137 leopard frogs, *Rana pipiens* complex, purchased from 13 commercial vendors in 8 states in the United States, *Trypanosoma pipientis* was found in 2 *R. p. berlandieri*, *Toxoplasma ranae* in 1 *R. pipiens*, *Isospora lieberkuehni* in 1 leopard frog, *Haemogregarina magna* in 44, *Lankesterella minima* in 3, *Leptotheca ohlmacheri* in 3 and microfilariae of *Foleyella* sp. in 6. The report of *I. lieberkuehni* is presumably a new host record. *Haemogregarina temporariae* (Nöller, 1920) nov. comb. is established as a new combination for *Nematopsis temporariae*.

INTRODUCTION

A conference on frog resources for biomedical research was held by the Animal Resources Branch, Division of Research Resources, National Institutes of Health in Bethesda, Maryland on 7 March 1975, because the supply of frogs for biomedical research and teaching in the United States and the world is dangerously low.¹² Since it was known that blood protozoa occur in frogs, we subsequently carried out a limited survey to determine their prevalence in frogs purchased from American vendors. In this survey, 137 leopard (grass) frogs, *Rana pipiens*, purchased between late July and early September, 1975 from 13 commercial vendors in Illinois, Louisiana, Massachusetts, New Jersey, New York, Tennessee, Vermont and Wisconsin were examined.

MATERIALS AND METHODS

Immediately upon the frogs' arrival, blood smears were made from the heart, fixed with 100% methanol and stained with Giemsa. Impression smears were made from the frogs' livers, spleens, lungs, kidneys, hearts and brains, fixed with 100% methanol and stained with Giemsa. Representative samples of these organs also were preserved in 10% neutral formalin, embedded in paraffin, sec-

tioned at 5 μ m, stained with hematoxylin and eosin, and examined under the microscope. Additional stains were made if indicated.

RESULTS

Trypanosoma pipientis Diamond, 1950 was found in the blood of 2 of the frogs. Both were *R. pipiens berlandieri*; they came from a vendor in Wisconsin, but had probably originated in Mexico.

Toxoplasma ranae Levine & Nye, 1977 was found in the brain of a single *R. pipiens*. The host animal probably came from Mexico and was probably *R. pipiens berlandieri*. It was described in detail by Levine and Nye.²³

Isospora lieberkuehni (Labbé, 1894) Laveran and Mesnil, 1902 (Figs. 1, 2) was found in the kidneys of a single, small *R. pipiens* from Wisconsin. This appears to be a new host and geographic record. Only merozoites were seen; there were 1 to perhaps a dozen per host cell. They lay loosely in no particular order in the cytoplasm of the kidney tubule epithelial cells, completely destroying the cytoplasm, but leaving the nucleus intact although sometimes shrunken. Because of the destruction of the host cytoplasm, it looked as if the merozoites were in a compartmented cyst, but this was not the case. The merozoites were elongate and

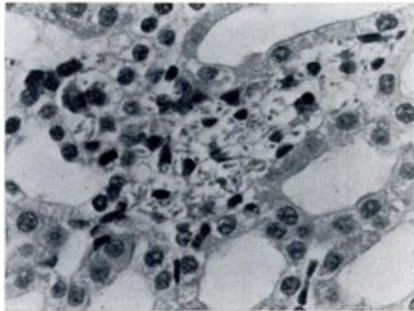

FIGURE 1. *Isospora lieberkuehni* in *Rana pipiens* kidney tubules. Hematoxylin and eosin stain. X 350.

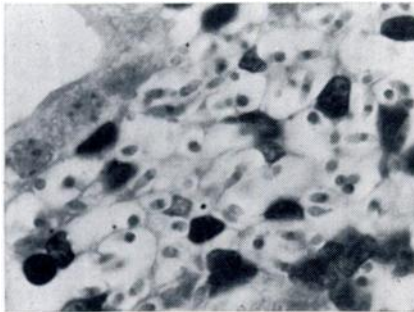


FIGURE 2. *Isospora lieberkuehni* in *Rana pipiens* kidney tubules. The "compartments" are host cell membranes. Hematoxylin and eosin stain. X 1,750.

slightly curved, about 6-7 μm long, with a central or subcentral spherical or squarish nucleus about 1 μm in diameter. Although no oocysts were seen, the merozoites did not differ significantly from those described by Nöller²⁸ for *I. lieberkuehni*.

An organism indistinguishable from *Haemogregarina magna* (Grassi and Felletti, 1891) Labbé, 1899 (Figs. 3-5) was found in 44 *R. pipiens* (including 12 *R. p. berlandieri*) from 5 vendors—in Illinois, Louisiana, New York, Tennessee and Wisconsin. The gamonts in the erythrocytes were about 18 x 6 μm , with a tail about 5 μm long bent back on the body, making the body 7 μm wide in the tail region. The gamont nucleus was about 4 x 4 μm , but slightly broader than

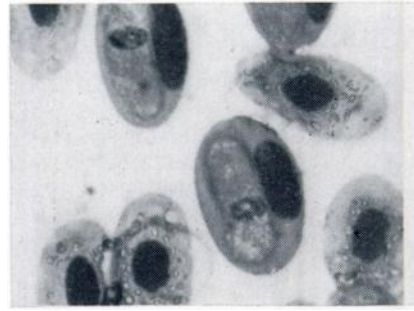


FIGURE 3. *Haemogregarina magna* gamont in *Rana pipiens* erythrocyte. Note that the host cell nucleus has been displaced. Giemsa stain. X 1,750.

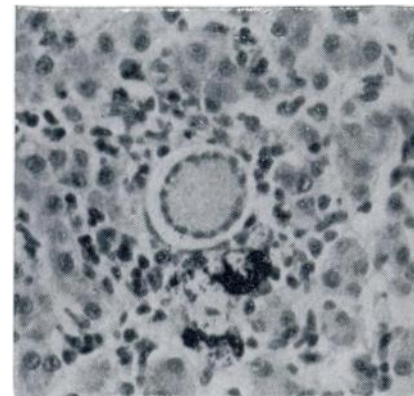


FIGURE 4. *Haemogregarina magna* young meront in *Rana pipiens* liver. Hematoxylin and eosin stain. X 350.

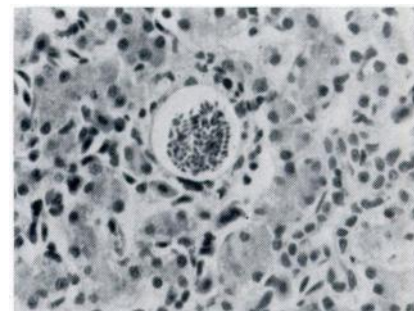


FIGURE 5. *Haemogregarina magna* almost mature meront in *Rana pipiens* liver. Hematoxylin and eosin stain. X 350.

long; its anterior edge was 10 μm from the anterior end of the gamont. The anterior end of the gamont was often slightly pointed and had a vague triangular "vacuole" just behind it. A narrow parasitophorous vacuole was sometimes visible.

Host erythrocytes, about 24 x 14 μm , were not enlarged, but their nucleus, 13 x 4 μm , were sometimes longer than normal. They were always displaced, usually to the side of the erythrocyte, but sometimes toward one end.

In some cases free forms were seen in the blood plasma. They were about 29 x 4 μm , narrowing both anteriorly and posteriorly, with or without a visible nucleus about 3 x 3 μm , with the anterior edge about 14 μm from the anterior end. The anterior end itself usually came to a rounded point and was sometimes a little wider than the adjacent "neck", forming a sort of "head"; the head was about 3 μm wide and the neck 2 μm wide. A tail about 4 μm long was sometimes bent at an angle to the body.

Meronts were seen in liver sections of 2 frogs, both of which had gamonts in their erythrocytes. In one frog, 10 meronts were seen in a single section. They were spherical to subspherical. Eight meronts were 20-45 x 20-41 μm , with a mean of 33.7 x 31.0 μm . (The meronts were not always cut across the center, of course, so our figures are not accurate.) They lay in a parasitophorous vacuole 2-11 μm (mean, 5.3 μm) wide. The meronts were presumably in liver parenchyma cells, but the host cells were so greatly stretched that they could not be recognized, although in some cases one host cell nucleus or more could be seen right next to the parasitophorous vacuole.

Only one meront was mature, i.e., contained fully developed merozoites. It was about 43 μm in diameter. Its merozoites were not arranged in any particular order. They were elongate lanceolate, straight to somewhat curved, about 9 x 1.5 μm , with one end pointed and the other somewhat rounded. The nucleus of each was subcentral, displaced somewhat to the broad end, and about 3 x 1.5 μm . About 100 merozoites were counted in a

section 5 μm thick. Assuming that the meront was a sphere and that it has been cut in the middle, this would mean that it contained about 3,000 merozoites.

The other meronts were immature, containing only nuclei. They contained more or less residual cytoplasmic material and usually a single or double row of nuclei around their periphery. The nuclei were usually subspherical but occasionally spherical or ellipsoidal, and averaged about 3.5 x 3.1 μm . Seventeen to 47 (mean, 30) nuclei were counted in the immature meronts. On the basis of the 5 meronts that were presumably cut across the middle, and assuming that nuclei were only on the surface, each meront contained perhaps several hundred nuclei.

Lankesterella minima (Chaussat, 1850) Nöller, 1912 (Fig. 6) was found in the erythrocytes of 3 small *R. pipiens* from the same vendor in Wisconsin in whose frog *I. lieberkuehni* had been found. Ordinarily, only a single sporozoite was seen in each host erythrocyte. The sporozoites appeared not to affect the host cell or displace its nucleus. They ordinarily lay on one side of the host cell nucleus. They were colorless, elongate, convex on one side and straight or slightly concave on the other, about 14 x 3.6 μm , with rather pointed ends but

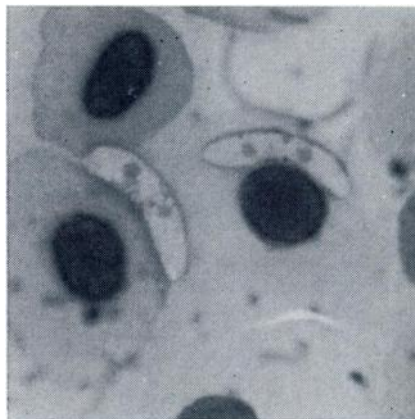

FIGURE 6. *Lankesterella minima* sporozoite in *Rana pipiens* erythrocyte. Giemsa stain. X 1,750.

with one end a little wider than the other, with a central bluish nucleus and an eosinophilic globule ("paranuclear body," "refractile globule") about 1.3 μ m in diameter at each end of the nucleus. These parasites were relatively inconspicuous compared with the hemogregarines.

The myxosporan *Leptotheca ohlmacheri* (Gurley, 1893) Labbé, 1899 (Fig. 7) was found in the lumen of the kidney tubules of 3 *R. pipiens* from the same vendor in Wisconsin in whose frog *I. lieberkuehni* had been found. We have nothing to add to the description of this

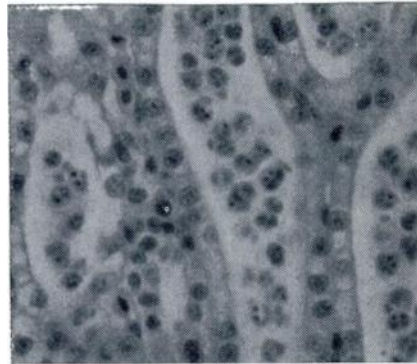


FIGURE 7. *Leptotheca ohlmacheri* in *Rana pipiens* kidney tubule lumen. Hematoxylin and eosin stain. X 400.

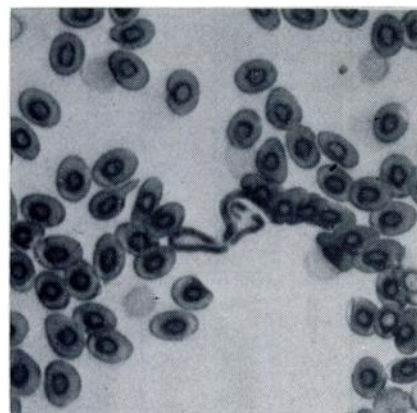


FIGURE 8. *Foleyella* sp. microfilaria in *Rana pipiens* blood. Giemsa stain. X 350.

species given by Kudo.^{16,17} He found it in *R. pipiens* from the Midwest and *R. clamitans* from New York.

Foleyella sp. microfilariae (Fig. 8) were found in the blood of 6 *R. pipiens* from vendors in Wisconsin and Louisiana.

DISCUSSION

In what has been said, we have accepted the frog identifications and names given by the vendors, since this is what the ordinary customer would do. However, it should be pointed out that "*Rana pipiens*" is actually a species complex and frog taxonomists are not agreed as to the correct names to give its members.^{25,26} The most recent attempt seems to be that by Pace,²⁹ who accepted 4 species (*R. pipiens*, *R. utricularia*, *R. berlandieri* and *R. blairi*). The degree of geographic overlap is indicated by the fact that all these species except *R. berlandieri* have been reported from Illinois. The name "*Rana pipiens*" is used by commercial vendors for all these forms and it is often impossible for the buyer to determine where a particular frog came from or even to which subspecies (or species, if one prefers) it belongs. For instance, the vendor from whom we obtained the frog in which *Toxoplasma* occurred was located in Louisiana, but he informed us that the frog itself most likely came from Mexico or possibly from Wisconsin.

Isospora lieberkuehni was first seen in *R. esculenta* in France by Labbé.¹⁴ It has since been found in *R. temporaria*, *R. ridibunda* and *Bombina variegata*. Cox⁸ said that it occurs in the toad *Bufo bufo*. Walton³⁴ listed the following additional hosts without giving references: *R. clamitans*, *R. pipiens*, *R. sphenoccephala*, *Pelobates fuscus* and the toad *B. valliceps*. It was said by Pellérdy³⁰ to be a frequent renal parasite of the frog in Central Europe. Nöller²⁸ described its life cycle. The oocysts infect tadpoles, but meronts and later stages do not develop until the next spring, after metamorphosis.

Among other Apicomplexa, 13 named species of *Haemogregarina*, 1 of *Karyolysus*, 1 of *Hepatozoon* and 4 of *Lankesterella* have been reported from frogs.

In addition, several investigators have reported various forms without giving them names. Most species have been seen just once, and have been given separate names because they were found in a new host. The only species for which vectors are known are *L. minima* and *Hepatozoon leptodactyli*. Most forms have been found in members of the genus *Rana*. No cross transmission experiments have been carried out with blood protozoa from one continent to hosts from another. It is likely that some of the names which have been given are synonyms of others.

Three species of *Haemogregarina* have been reported from Europe: *H. magna* in *R. esculenta* and *R. ridibunda*,¹⁸ *H. temporaria* (Nöller 1920) nov. comb. in *R. temporariae*,²⁷ and *H. hortai* in *R. esculenta*.

Four named species of *Haemogregarina* have been reported from Africa: *H. neireti* in *Rana* sp. on Madagascar,¹⁹ *H. theileri* in *R. angolensis* in the Transvaal,¹⁹ *H. epuluensis* in *R. oxyrhynchus* in Zaire³ and *H. hyperolii* in *Hyperolius* sp. in Uganda.¹⁵

Two named species have been reported from Asia: *H. berestneffi* in *R. tigrina* and *R. limnocharis* in India⁸ and *H. scheini* in *R. tigrina* in Vietnam.²⁴

So far as North America is concerned, Stebbins²³ described *H. catesbeiana* from *R. catesbeiana*, and *H. clamatae* from *R. clamitans* and *R. catesbeiana*, both from New York. Kudo¹⁶ reported an organism from *R. pipiens* and *R. clamitans* in Illinois and New York which he said "seems to agree with" *H. magna* and *H. clamatae*. Sanders³² found what she called *Karyolysus* sp. and *Lankesterella* sp. in *R. clamitans* and *R. catesbeiana* in New York. Brandt⁴ found *Karyolysus* sp. or *Lankesterella* sp. (he was uncertain which) in *R. catesbeiana* and *R. sphenoccephala* (a member of the *R. pipiens* complex) in North Carolina. Fantham, Porter and Richardson¹⁰ found *Haemogregarina* sp. in *R. pipiens* and *R. catesbeiana* in Canada. Fowler¹¹ and Bailey¹ found hemogregarines which they did not attempt to name in *R. pipiens*. Lehman^{20,21,22} named *H. boylii* and *K. sonomae* from *R. boylii* in California and *H. aurorae* from *R. aurora* in Oregon. More

recently, Baker and Lainson² reported *Haemogregarina* sp. from *R. montezumae* in Mexico, Heller¹³ in our laboratory from *R. pipiens* in Wisconsin, and Desser and Weller⁹ from *R. berlandieri* (a member of the *R. pipiens* complex) in Mexico. All of these hemogregarines occur in the erythrocytes.

The only named species of *Hepatozoon* recognized from frogs is *H. leptodactyli*, which was found in *Leptodactylus ocellatus* and *L. pentadactylus* in Argentina, Brazil and Goa.³¹ Its experimental vector is the leech *Haementeria lutzi*. Perhaps some of the frog *Haemogregarina* species are actually *Hepatozoon*.

Two valid species of *Lankesterella* have been named from frogs. *L. minima* occurs commonly in *R. esculenta* in Europe. Its vector was found by Nöller²⁷ to be the leech *Hemiclepsis marginata*. *L. hylae* was found in the tree frog *Hyla caerulea* in Australia.⁷ *L. canadensis* was described from *R. catesbeiana* in Canada.¹⁰ It may or may not be a small *Haemogregarina*, but it is certainly not a *Lankesterella* species, and we consider this name a *nomen inquirendum*. In addition to the above species in North America, Heller¹⁴ in our laboratory described a *Lankesterella* sp. from *R. pipiens* in Wisconsin.

The species of *Haemogregarina* that we saw in *R. pipiens* corresponds in all respects to *H. magna*, and we think that it belongs to this species. However, cross-transmission studies between *R. pipiens* and *R. esculenta* should be carried out to establish this fact incontrovertibly. Some of the other named species are also probably *H. magna*.

The species of *Lankesterella* that we found in *R. pipiens* corresponds in all respects to *L. minima*, which is the only valid species so far reported from *Rana*. We consider that it belongs to this species.

All the frogs in which these blood parasites were found appeared to be healthy. There seems to be no proof that any of these parasites is pathogenic, but further study is needed to determine whether this view is true.

Acknowledgements

This study was supported in part by National Science Foundation Research Grant BMS-71-01294.

LITERATURE CITED

1. BAILEY, J. K. 1948. Studies on a haemogregarine from the leopard frog. *J. Parasit.* 34: 23-24.
2. BAKER, J. R. and R. LAINSON. 1967. The fine structure of the gametocytes of an adeleine haemogregarine. *J. Protozool.* 14: 233-238.
3. VAN DEN BERGHE, L. 1942. Enquête parasitologique. I. Parasite du sang des vertébrés. Explor. Parc Natnl. Albert, Bruxelles. Mission L. van den Berghe (1936). 1: 3-15.
4. BRANDT, B. B. 1936. Parasites of certain North Carolina Salienta. *Ecol. Monog.* 6: 491-532.
5. BRUMPT, E. 1928. Une nouvelle hémogrégarine: *Haemogregarina hortai* n. sp. de la grenouille verte (*Rana esculenta*) de Corse. *Ann. Parasit.* 6: 145-151.
6. CASTELLANI, A. and A. WILLEY. 1905. Observations on Haematozoa in Ceylon. *Quart. J. Micr. Sci.* 49: 383-402.
7. CLELAND, J. B. and T. H. JOHNSTON. 1910. The haematozoa of Australian batrachians. No. 1. *J. Roy. Soc. New S. Wales.* 4: 252-260.
8. COX, F. E. G. 1971. Parasites of British amphibians. *J. Biol. Educ.* 5: 35-51.
9. DESSER, S. S. and I. WELLER. 1973. Structure, cytochemistry, and locomotion of *Haemogregarina* sp. from *Rana berlandieri*. *J. Protozool.* 20: 65-73.
10. FANTHAM, H. B., A. PORTER and L. R. RICHARDSON. 1942. Some haematozoa observed in vertebrates in eastern Canada. *Parasitology.* 34: 199-226.
11. FOWLER, J. A. 1946. Reptiles and amphibians as a source of blood parasites in protozoology and parasitology. *Turtlox News.* 24: 73-75.
12. GIBBS, E. L., G. W. NACE and M. B. EMMONS. 1971. The live frog is almost dead. *BioScience.* 21: 1027-1034.
13. HELLER, G. 1973. Elektronenmikroskopische Untersuchungen zur Wechselwirkung zwischen einer Haemogregarine und ihrer Wirtszelle. *Prog. Protozool.* 4: 177.
14. ———. 1974. The fine structure of *Lankesterella* sp. sporozoites parasitic in the frog *Rana pipiens*. *Acta Vet. Acad. Sci. Hungar.* 24: 151-157.
15. HOARE, C. A. 1932. On protozoal blood parasites collected in Uganda: With an account of the life-cycle of the crocodile haemogregarine. *Parasitology.* 24: 210-224.
16. KUDO, R. R. 1922. On the protozoa parasitic in frogs. *Trans. Am. Micr. Soc.* 41: 59-76.
17. ———. 1922a. On the morphology and life history of a myxosporidian, *Lep-totheca ohlmacheri*, parasitic in *Rana clamitans* and *R. pipiens*. *Parasitology.* 14: 221-224.
18. LABBE, A. 1899. Sporozoa. In: *Das Tierreich*. Schulze, F. E. and O. Bütschli, eds. Eine Zusammenstellung und Kennzeichnung der rezenten Tierformen. 5: xx + 180 pp.
19. LAVERAN, A. 1905. Contribution a l'étude des grandes hémogrégarines des grenouilles. *C. R. Soc. Biol.* 59: 172-175.
20. LEHMANN, D. L. 1959. The description of *Haemogregarina boylii* n. sp. from the yellow-legged frog, *Rana boylii boylii*. *J. Parasit.* 45: 198-203.

21. ———. 1959a. *Karyolysus sonomae* n. sp., a blood parasite from the California yellow-legged frog, *Rana boylii boylii*. Proc. Am. Phil. Soc. 103: 545-547.
22. ———. 1960. *Haemogregarina aurorae* n. sp. from *Rana a. aurora*. Proc. Am. Phil. Soc. 104: 202-204.
23. LEVINE, N. D. and R. R. NYE. *Toxoplasma ranae* n. sp. from the leopard frog *Rana pipiens* L. J. Protozool. (in press)
24. MATHIS, C. and M. LEGER. 1911. Hémogregarines de reptiles et des batraciens du Tonkin. Bull. Soc. Path. Exot. 4: 446-451.
25. MOORE, J. A. 1975. *Rana pipiens*—the changing paradigm. Am. Zool. 15: 837-849.
26. NACE, G. W. 1976. The frog and other amphibians. Lab Animal. 5: 52-54.
27. NOLLER, W. 1920. Kleine Beobachtungen an parasitischen Protozoan. (zugleich vorläufige Mitteilung über die Befruchtung und Sporogonie von *Lankesterella minima* Chaussat). Arch. Protistenk. 41: 169-189.
28. ———. 1923. Zur Kenntnis einem Nierencoccids. Der Entwicklungskreis des Coccids des Wasserfroschniere [*Isospora lieberkuhni* (Labbé 1894)]. Arch. Protistenk. 47: 101-108.
29. PACE, A. E. 1974. Systematic and biological studies of the leopard frog (*Rana pipiens* complex) of the United States. Mus. Zool. Univ. Mich. Publ. No. 148. 140 pp.
30. PELLERDY, L. P. 1974. Coccidia and coccidiosis. 2nd ed. Akad. Kiado, Budapest and Paul Parey, West Berlin. 959 pp.
31. PESSOA, S. B. 1970. Formas evolutivas do *Hepatozoon leptodactyli* (Lesage, 1908) na sanguessuga *Haementeria lutzi* Pinto, 1920. Rec. Goiana Med. 16: 35-39.
32. SANDERS, E. P. 1928. Observations and experiments on the haemogregarines of certain amphibia. J. Parasit. 14: 188-192.
33. STEBBINS, J. H. 1904. Upon the occurrence of Haemosporidia in the blood of *Rana catesbiana*, with an account of their probable life history. Trans. Am. Micr. Soc. 25: 55-62.
34. WALTON, A. C. 1964. The parasites of amphibia. Wildl. Dis. 32: 56 pp.

Received for publication 12 July 1976