

PLASMA CELL TUMOR IN AN EAST INDIAN WATER LIZARD (*Hydrosaurus amboinensis*)

Author: Schmidt, R. E.

Source: Journal of Wildlife Diseases, 13(1) : 47-48

Published By: Wildlife Disease Association

URL: <https://doi.org/10.7589/0090-3558-13.1.47>

BioOne Complete (complete.BioOne.org) is a full-text database of 200 subscribed and open-access titles in the biological, ecological, and environmental sciences published by nonprofit societies, associations, museums, institutions, and presses.

Your use of this PDF, the BioOne Complete website, and all posted and associated content indicates your acceptance of BioOne's Terms of Use, available at www.bioone.org/terms-of-use.

Usage of BioOne Complete content is strictly limited to personal, educational, and non - commercial use. Commercial inquiries or rights and permissions requests should be directed to the individual publisher as copyright holder.

BioOne sees sustainable scholarly publishing as an inherently collaborative enterprise connecting authors, nonprofit publishers, academic institutions, research libraries, and research funders in the common goal of maximizing access to critical research.

PLASMA CELL TUMOR IN AN EAST INDIAN WATER LIZARD (*Hydrosaurus amboinensis*)

R. E. SCHMIDT, Veterinary Sciences Division, USAF School of Aerospace Medicine, Aerospace Medical Division, AFSC, United States Air Force, Brooks Air Force Base, Texas 78235, USA

Abstract: A neoplasm involving the stomach, liver and lungs was seen in an East Indian water lizard (*Hydrosaurus amboinensis*). The largest mass was in the stomach, with smaller nodules in the lung and liver. The tumor was diagnosed as a plasma cell tumor by its histologic and ultrastructure characteristics.

INTRODUCTION

Neoplasms in reptiles have been reported infrequently and a total of 41 specimens were listed in a tumor registry in 1974.^{2,3} In lizards, 2 lymphoid tumors and 1 reticulum cell sarcoma have been reported.¹ One of the lymphoid tumors, a lymphoblastic lymphoma in an East Indian water lizard, was the first hematopoietic neoplasm reported in the suborder Sauria.⁴

A disseminated plasma cell tumor was found in an East Indian water lizard (*Hydrosaurus amboinensis*) which died after a brief period of non-specific clinical signs. Tumor masses involving the stomach, liver and lung were found at necropsy.

CASE REPORT

The lizard, a subadult female, had been in a zoologic collection for 1.5 yr. It had no specific clinical signs and was found dead after a short period of anorexia and depression. At necropsy 1-2 mm diameter gray-white nodules were seen in the lungs and liver. A 2.0 x 2.5 cm gray-white ulcerated mass was present in the wall of the greater curvature of the stomach. No clinical laboratory examination was done.

Histologically, the stomach mass was necrotic over a portion of its surface, and was extremely cellular below the necrotic area and in the adjacent mucosa (Figure 1). Although a pleocellular inflammatory response was present at the edge of the ulcer, cells making up the mass were

round or ovoid, with eccentric nuclei (Figure 2). Most nuclei contained clumped chromatin, cells had distinct cytoplasmic borders, and stroma was minimal.

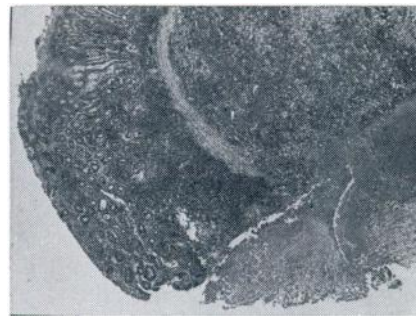


FIGURE 1. Neoplastic mass in stomach of East Indian water lizard. Ulcerated, necrotic area has a sharp line of demarcation from the tumor mass. H&E stain, x 40.

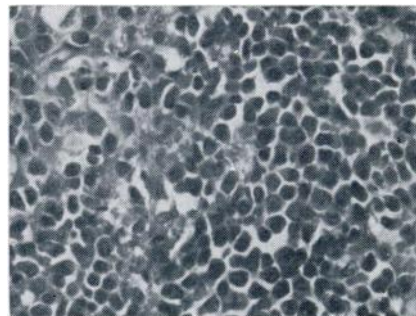


FIGURE 2. Cellular detail of the mass illustrated in Figure 1. The majority of the neoplastic cells have eccentric nuclei. H&E stain, x 695.

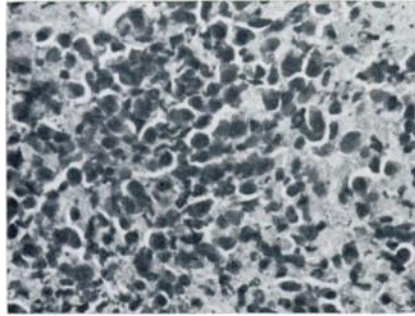


FIGURE 3. Neoplastic infiltrate in the liver of an East Indian water lizard. Necrosis is a prominent feature of this lesion. H&E stain, $\times 695$.

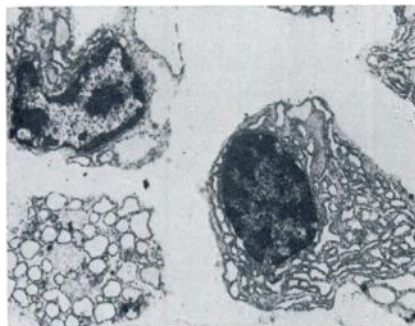


FIGURE 4. Ultrastructural detail of neoplastic cells from the gastric mass. Note the clumped nuclear chromatin and prominent rough endoplasmic reticulum. $\times 12,000$.

Few mitotic figures were seen. The histologic appearance of the lung and liver nodules was similar to that of the stomach mass, although a considerable

amount of necrosis was present in the liver (Figure 3). This was probably due to pressure from the enlarging tumor nodules. No evidence of neoplasia was seen in any other organ.

A portion of the stomach tumor was post-fixed in OsO_4 , stained with lead citrate and uranyl acetate, embedded in epon, cut at 990 \AA , and examined with an RCA EMU-3G. The ultrastructural appearance of the neoplasm is illustrated by Figure 4. The cells have features typical of plasma cells, including prominent clumping of nuclear chromatin in the center and at the periphery of the nucleus, and extensive rough endoplasmic reticulum (RER).

DISCUSSION

Because of the relative paucity of reports of lizard tumors, it is interesting that this tumor and one other hematopoietic tumor have been reported in East Indian water lizards. Whether this represents a species susceptibility to hematopoietic tumors—indicating a possible area for comparative oncologic research, a reflection of a higher percent of water lizards in captivity, or some other factor—has yet to be discerned. Plasma cell tumors are not common in any species, and the occurrence of one in a reptile is of comparative interest, if not of comparative importance. It is unfortunate that bone marrow was not available for histologic study, since the limited number of organs examined may give an erroneous impression of the actual extent of the neoplastic process in this lizard.

LITERATURE CITED

1. BILLUPS, L. H. and J. C. HARSHBARGER. 1975. Reptiles. In: *Handbook of Laboratory Animal Science*, E. C. Melby and N. H. Altman, Eds., CRC Press, Cleveland, Ohio, Vol. 3, Chapter 12.
2. HARSHBARGER, J. C. 1965-1973. Activities Report, Registry of Tumors in Lower Animals, Smithsonian Institute, Washington, D.C.
3. ———. 1974. Activities Report, Registry of Tumors in Lower Animals, Supplement, Smithsonian Institute, Washington, D.C.
4. ZWART, P. and J. C. HARSHBARGER. 1972. Hematopoietic neoplasms in lizards: Report of a typical case of *Hydrosaurus amboinensis* and of a probable case in *Varanus salvator*. *Int. J. Cancer*, 9: 548-553.

Received for publication 24 June 1976