

MYXOSARCOMA IN A WAPITI

Authors: SNYDER, S. P., DAVIES, R. B., and KEISS, R. E.

Source: Journal of Wildlife Diseases, 15(2) : 307-308

Published By: Wildlife Disease Association

URL: <https://doi.org/10.7589/0090-3558-15.2.307>

BioOne Complete (complete.BioOne.org) is a full-text database of 200 subscribed and open-access titles in the biological, ecological, and environmental sciences published by nonprofit societies, associations, museums, institutions, and presses.

Your use of this PDF, the BioOne Complete website, and all posted and associated content indicates your acceptance of BioOne's Terms of Use, available at www.bioone.org/terms-of-use.

Usage of BioOne Complete content is strictly limited to personal, educational, and non - commercial use. Commercial inquiries or rights and permissions requests should be directed to the individual publisher as copyright holder.

BioOne sees sustainable scholarly publishing as an inherently collaborative enterprise connecting authors, nonprofit publishers, academic institutions, research libraries, and research funders in the common goal of maximizing access to critical research.

MYXOSARCOMA IN A WAPITI

S. P. SNYDER,[□] R. B. DAVIES[□] and R. E. KEISS[□]

Abstract: Myxosarcoma was diagnosed in an adult male wapiti (*Cervus canadensis*) from western Colorado. The neoplasm was located on the medial aspect of the right thigh and had extensively infiltrated adjacent soft tissue.

INTRODUCTION

There are few accounts of spontaneous neoplasms in free-ranging wapiti, (*Cervus canadensis*); however, individual cases of osteosarcoma,^{2,3} thyroid adenoma,¹ round cell sarcoma,⁴ and embryonal nephroma⁷ have been reported.

CASE HISTORY

During the 1977 hunting season a large mass was detected on the medial aspect of the right thigh near the pubis of an adult bull wapiti killed near Gunnison, Colorado. Personnel of the Colorado Division of Wildlife were notified and the excised tumorous mass and adjacent musculature were taken to the Wild Animal Disease Center at Colorado State University for examination.

The tumor was large (25 × 9 × 5 cm), amorphous, non-encapsulated, and had a gray to pink, translucent appearance. It contained pockets of slimy mucinous material that escaped from cut surfaces. Strands of white fibrous tissue subdivided the mass into lobules. The gracilis and other major muscles of the medial aspect of the thigh were extensively infiltrated.

Histologically, the neoplasm consisted of scattered fusiform to stellate cells embedded in a mucinous stroma (Fig. 1). Nuclei of tumor cells were round to oval,

hyperchromatic, and there were moderate numbers of mitotic figures. Collagen bundles were scattered throughout the tumor, but were concentrated in areas where connective tissue septae subdivided the mass. The bulk of the stroma consisted of mucinous ground substance that stained prominently with Alcian blue, but failed to stain by the periodic-acid-Schiff method, indicating that it consisted largely of acidic sulfated mucosubstances. The neoplasm had infiltrated peripheral tissues extensively, primarily between skeletal muscle fibers, along fascial planes and along the course of vessels. Skeletal muscle fibers along the margin of neoplastic growth were atrophic and degenerating.

DISCUSSION

Observations on neoplastic diseases of free-ranging wild cervids, other than the relatively common cutaneous fibromas of white-tailed deer, (*Odocoileus virginianus*), are infrequent. Affected individuals are likely to die unobserved or be more prone to predation.

To our knowledge, this is the first report of a myxosarcoma in wapiti, although a similar neoplasm was diagnosed in the upper jaw of a roedeer (*Capreolus capreolus*).⁵ The gross and microscopic characteristics of the tumor in the elk were similar to those found in

[□] Wild Animal Disease Center, Department of Pathology, College of Veterinary Medicine and Biomedical Sciences, Colorado State University, Fort Collins, Colorado 80523, USA.

[□] Colorado Division of Wildlife, 317 W. Prospect, Fort Collins, Colorado 80521, USA.

domestic animals. The hunter who killed the affected animal did not notice any evidence of metastatic spread, and it is unlikely that metastases occurred as this neoplasm is usually invasive but localized.⁶

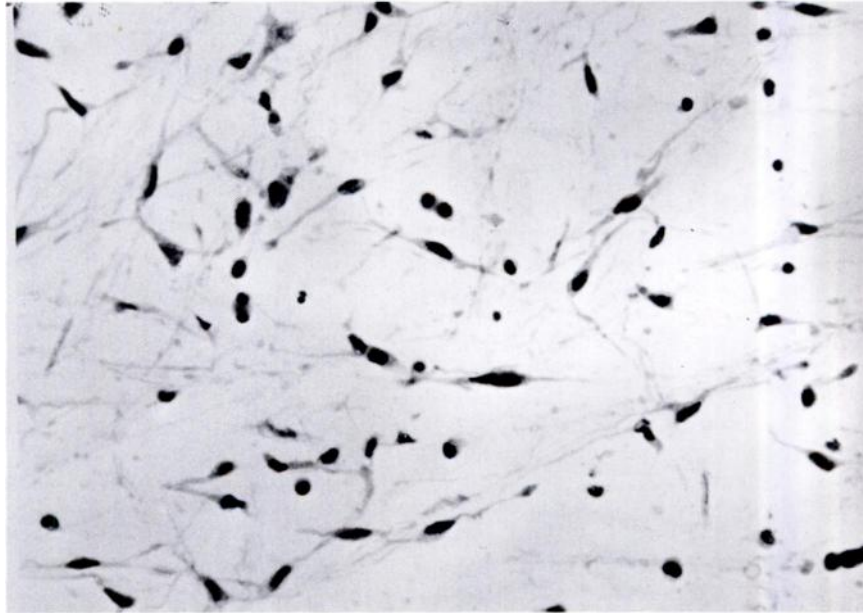


FIGURE 1. Photomicrograph of the neoplasm showing fusiform and stellate cells separated by mucinous matrix, H&E $\times 220$.

LITERATURE CITED

1. BOYD, R.J. 1970. Elk of the White River Plateau, Colorado. Tech. Publ. no. 25, Colorado Division of Game, Fish and Parks, pp. 14-15.
2. CLARK, K.A. 1973. Neoplasms of wild animals. *Southwest. Vet.* 26: 185-188.
3. DRAKE, C.H. 1951. Mistaken diagnosis of actinomycosis for osteogenic sarcoma in an American elk (*Cervus canadensis*). *J. Wildl. Manage.* 15: 284-287.
4. KRONBERGER, H. 1962. Geschwulste bei zootieren. *Nord. Vet. Med.* 14: 297-304.
5. MEH, B. 1933. Ein Myxosarkom am Oberkiefer eines Rehbockes. *Wein. Tierarztl. Monatsschr.* 22: 379-387.
6. MOULTON, J.E. 1978. *Tumors in Domestic Animals* (second edition), Univ. Calif. Press, Berkeley, pp. 23-24.
7. SNYDER, S.P., R.B. DAVIES, T.R. SPRAKER and H. BROWNING. 1978. Embryonal nephroma in an elk. *J. Wildl. Dis.* (In Press).

Received for publication 20 June, 1978