

OBSERVATIONS ON THE EPIDEMIOLOGY OF THE HERPESVIRUS OF INFECTIOUS BOVINE RHINOTRACHEITIS/INFECTIOUS PUSTULAR VULVOVAGINITIS IN WILDEBEEST

Authors: MUSHI, E. Z., KARSTAD, L., JESSETT, D. M., and
ROSSITER, P. B.

Source: Journal of Wildlife Diseases, 15(3) : 481-487

Published By: Wildlife Disease Association

URL: <https://doi.org/10.7589/0090-3558-15.3.481>

BioOne Complete (complete.BioOne.org) is a full-text database of 200 subscribed and open-access titles in the biological, ecological, and environmental sciences published by nonprofit societies, associations, museums, institutions, and presses.

Your use of this PDF, the BioOne Complete website, and all posted and associated content indicates your acceptance of BioOne's Terms of Use, available at www.bioone.org/terms-of-use.

Usage of BioOne Complete content is strictly limited to personal, educational, and non - commercial use. Commercial inquiries or rights and permissions requests should be directed to the individual publisher as copyright holder.

BioOne sees sustainable scholarly publishing as an inherently collaborative enterprise connecting authors, nonprofit publishers, academic institutions, research libraries, and research funders in the common goal of maximizing access to critical research.

OBSERVATIONS ON THE EPIDEMIOLOGY OF THE HERPESVIRUS OF INFECTIOUS BOVINE RHINOTRACHEITIS/INFECTIOUS PUSTULAR VULVOVAGINITIS IN WILDEBEEST

E. Z. MUSHI, L. KARSTAD, D. M. JESSETT [□] and P. B. ROSSITER, [□] Veterinary Research Department, Muguga, P.O. Box 32, Kikuyu, Kenya, and Veterinary Research Laboratory, Kabete, Kenya.

Abstract: Spontaneous vulvovaginitis erupted in wildebeest (*Connochaetes taurinus*) after betamethasone inoculation. Infectious bovine rhinotracheitis/infectious pustular vulvovaginitis (IBR/IPV) is probably a venereal disease because virgin wildebeest did not develop vulvovaginitis after betamethasone injections, nor was the virus transmitted to these virgin wildebeest and steers which were in pen contact with the affected animals. A domestic bovine heifer developed mild IPV and became a virus carrier, when exposed to the wildebeest IPV virus by vaginal instillation.

INTRODUCTION

Serologic studies in wildlife have demonstrated antibodies to infectious bovine rhinotracheitis/infectious pustular vulvovaginitis (IBR/IPV) in wildebeest (*Connochaetes taurinus*).^{11,12,13} Also IBR/IPV virus has been isolated from the genital tracts of wildebeest following corticosteroid inoculation.⁶

IPV is believed to be a transmissible venereal disease in cattle.^{2,5,9,12} As evidence, IPV virus has been isolated from the prepuce and semen of infected bulls.^{1,8}

The present report concerns the probable mode of transmission of IPV in wildebeest.

MATERIALS AND METHODS

Animals

Wildebeest were captured in 1973 and 1974 on the Athi-Kapiti plains of Kenya by immobilization with etorphine, ace-

promazine and xylazine [□] and transferred to a paddock at Muguga where they have grazed freely since that time.

To facilitate handling, five mature female wildebeest, one mature male and three immature virgin wildebeest (Table 1) were injected with 0.4 mg/kg xylazine via projectile syringes. The wildebeest were moved into pens, two per pen, except for the male which was kept alone, and all were inoculated intramuscularly with 0.2 mg/kg betamethasone [□] daily for 7 consecutive days. Each animal was also injected with 5 mg/kg oxytetracycline to prevent secondary bacterial infections.

Six IBR seronegative steers, each about 3 years old, were introduced into the wildebeest pens. The pens were of open wooden bar construction, so that the animals could see and touch each other through the bars.

Cell cultures

Calf thyroid (B.Th.) cells were prepared as described by Plowright and Ferris¹⁰ but were grown in Eagle's

[□] Members of the United Kingdom Ministry of Overseas Development, Scheme R3253.

[□] Bayer, Leverkusen, West Germany.

[□] Glaxo Laboratories Ltd., Greenford, England.

TABLE 1. Virus neutralising antibodies to IBR/IPV virus in wildebeest.

Wildebeest No.	Description	Days Post Betamethasone Inoculation			
		0	7	14	21
87	1 yr ♀	0.0	0.0	0.0	0.0
1	2 yr ♀	0.0	0.0	0.0	0.0
90	1 yr ♀	0.0	D		
21	Adult ♀	2.2*	2.2	2.4	2.8
31	Adult ♀	2.8	3.2	2.4	3.2
46	Adult ♀	2.8	2.6	2.8	3.2
30	Adult ♀	2.2	2.2	D	
29	Adult ♀	2.2	D		
77	Adult ♂	2.2	D		

*log₁₀ VN₅₀

D = died during the experiment of causes unrelated to IBR/IPV.

Minimum essential medium \square supplemented with 10% ox serum and antibiotics. Calf thyroid cells were used after one passage.

Collection of specimens

Fourteen ml of blood were collected into universal bottles containing 7 ml EDTA (0.015 mg/ml). Vaginal, nasal, oral and conjunctival swabs were collected into 3 ml of phosphate buffered saline containing 0.1% bovine albumin (BAPBS). This solution was supplemented with 400 IU/ml penicillin, 400 mg/ml streptomycin, 100 units mycostatin and 10% IBR virus antibody-free ox serum.

Specimens were collected on alternate days for 4 weeks and inoculated immediately into confluent secondary B.Th. cultures. The cell cultures were examined for the development of cytopathic effects (c.p.e.) for 14 days. The wildebeest sera were tested for virus neutralising (VN) antibodies to one of the virus isolates by incubating heat-inactivated serum dilutions for 18 to 24 h at 4 C with 100 fifty per cent tissue culture infective doses (TCID₅₀) of the virus. The serum-virus mixtures were inoculated into calf kidney monolayers and exam-

ined for the development of c.p.e. for 7 days. The serum titres were calculated by the method of Karber.⁷

RESULTS

Clinical Observations

Yellowish raised plaques and hyperaemia were observed on the vulva and vagina of all five adult parous wildebeest 5 days after the start of betamethasone inoculation (Fig. 1). A mucoid, later mucopurulent, discharge from the vagina was also observed. The plaques turned into pustules and healed without scar formation. Generally, the lesions healed completely in 10 to 14 days. Histopathological examination revealed changes in the vulvar skin and vaginal mucous membranes that were either vesicular (Fig. 2) or pustular, depending presumably on their duration and stage of development. Intranuclear inclusions were present in epithelial cells at the borders of the vesicular lesions. Vulvovaginitis lesions were not observed in the three sexually immature wildebeest aged 1 and 2 years.

Abortion occurred in two wildebeest and three of the females and the male

\square Wellcome Reagents Ltd., Beckenham, England.

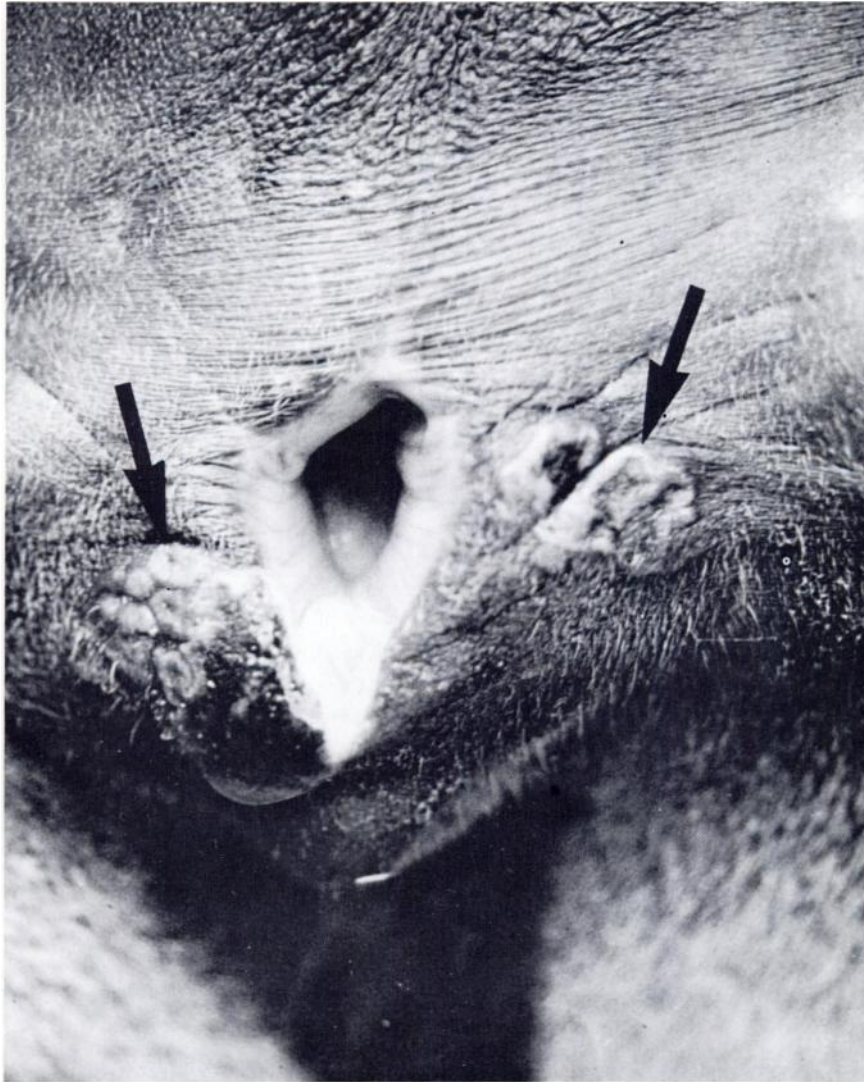


FIGURE 1. Wildebeest vulva with focal, slightly raised, yellowish, plaque-like lesions of the skin lateral to the vulvar lips (arrows). Similar lesions on the mucous membrane are not easily discernible in this photograph.

died during the course of the experiment, the male on day 1 and two of the females during the first week and one in the second week of the experiment, all from causes unrelated to IPV. The male died

as a result of injuries self-inflicted in trying to escape from the pen and death of the females appeared to be related to the stress of confinement and handling and the artificial stress of the

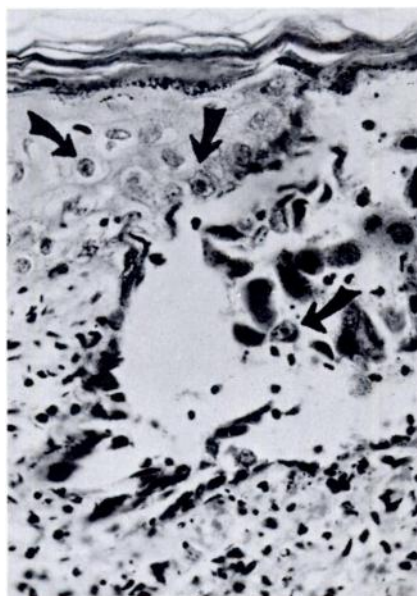


FIGURE 2. Wildebeest vulvar skin at the margin of a vesicle. Several epithelial cells contain intranuclear inclusions (arrows). Haematoxylin-eosin $\times 800$.

betamethasone injections. Lesions observed in these animals included ulcers of mucous membranes and histologically, degenerative changes in the adrenal glands. The two mature female wildebeest which died also had the described vulvar and vaginal lesions of IPV.

Virus isolation

No virus isolates were made before the betamethasone treatment was started, but virus was readily recovered from vaginal swabs taken on the fifth day after betamethasone treatment. Virus was isolated repeatedly until the lesions started to heal.

IBR/IPV virus was not isolated from spleen, lymph nodes, lung, kidney and liver of the two adult wildebeest which died when active vulvovaginitis was present. Similarly, no virus was isolated

from the internal organs of a 23 cm aborted foetus.

No virus was isolated from the vaginal swabs of the three sexually immature female wildebeest, nor from saliva, nasal secretions, conjunctival swabs or blood of any of the animals.

IBR/IPV virus was not recovered from the preputial washings of 8 sexually mature wildebeest bulls which were captured on the Athi-Kapiti plains and released immediately after specimens were collected.

Virus identification

The virus isolates recovered from the vaginal swabs of the adult wildebeest had the following properties: The viral agent produced cell rounding and small syncytia; this c.p.e. was evident 24 to 48 h post inoculation (p.i.) and advanced to affect the entire cell sheet in 3 to 4 days. The virus grew equally well in B.Th. and calf kidney cell cultures. When infected coverslips were stained with haematoxylin-eosin, small syncytia with 3 to 6 nuclei were seen 24 h p.i. Intranuclear inclusion bodies of Cowdry type A were also present. Intranuclear inclusion bodies were also observed in the vulvar epithelium of the wildebeest with active vulvovaginitis (Fig. 2). The virus was completely ether and chloroform sensitive and was neutralised with antiserum to IBR virus, Oxford strain.

Serology

VN antibodies were present in the sera of all the wildebeest from which virus was recovered (Table 1). Antibodies were detected both before and after betamethasone treatment. Antibodies were also detected in the bull (No. 77) which had run with and had bred the wildebeest cows, but antibodies were not detected in the sexually immature wildebeest. The steers which were in pen contact with the wildebeest for 7 days, during which the vulvar and vaginal lesions were present, did not develop VN antibodies to IBR/IPV virus.

Experimental infection

A 7 month old domestic bovine heifer, devoid of VN antibodies to IBR/IPV virus, was exposed by intravaginal instillation with $10^{6.0}$ TCD₅₀ of the wildebeest isolate of IBR/IPV virus. Mild lesions were observed on day 5 post infection and consisted of yellowish raised palques on the lateral walls of the vulvar mucosa. The lesions had healed by day 10 without any systemic disturbance.

IBR/IPV virus was isolated from the vaginal secretions of this heifer and reached a peak titer on days 5 to 6 p.i. (Fig. 3). Virus was not recovered from the vaginal secretions once the lesions had healed. IBR/IPV virus was not recovered from blood or nasal secretions.

When this heifer was inoculated with 20 mg betamethasone for seven days, 7 weeks after the initial infection, IBR/IPV virus was recovered from vaginal secretions on p.i. days 2, 4 and 5. Again, virus could not be isolated from blood, nasal secretions or saliva. Clinically, small vaginal lesions were observed again on day 5 after the start of

the betamethasone inoculations and had healed on the tenth day.

DISCUSSION

Spontaneous vulvovaginitis erupted in wildebeest after corticosteroid inoculation. Karstad *et al.*⁶ had shown that vulvovaginitis developed in wildebeest that already had antibodies to IBR/IPV virus and our report confirms the high prevalence of latent IBR/IPV in sexually mature female wildebeest in Kajiado District. The wildebeest in captivity have each been producing a calf about once in 2 years. Thus it is apparent that being carriers of IPV did not interfere with reproduction.

The time of entry of IPV into the herd cannot now be determined. It is probable, however, that the virus was introduced in mature wildebeest carriers in 1973 or 1974, since no animals were added to the herd during the last years. Disease resembling IBR or IPV had never been observed in the captive wildebeest.

Vulvovaginitis did not appear in three sexually immature wildebeest that had

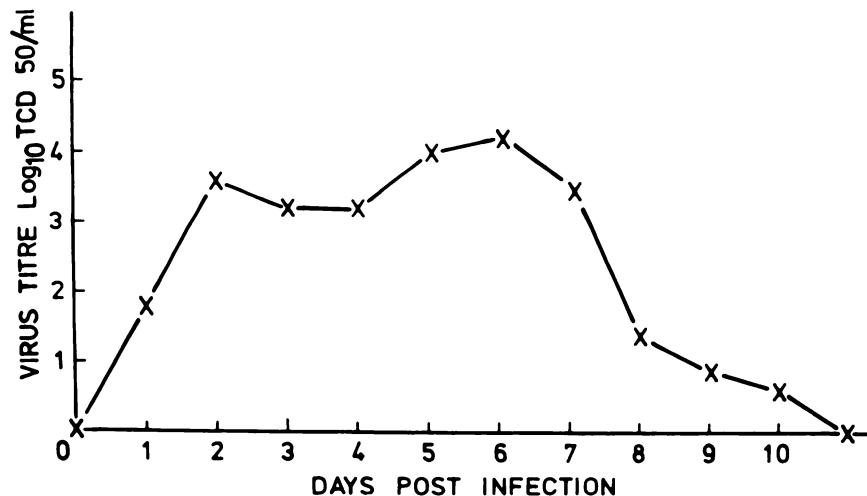


FIGURE 3. Vaginal secretion of IBR virus in a bovine heifer.

no VN antibodies to IBR/IPV virus, suggesting that IBR/IPV is a venereal disease as it is in cattle.^{1,2} This suggestion was further strengthened by the demonstration of VN antibodies in the bull which ran with the wildebeest cows. The confirmation of the venereal transmission of this disease awaits the demonstration of IBR/IPV virus from wildebeest bull preputial washings or semen.

This viral isolate did not induce the respiratory form of the disease in the in-contact immature wildebeest, nor was there any evidence of respiratory infection in the latently infected genital carriers. Attempts to isolate virus from blood, nasal and ocular secretions were

not successful. Furthermore, the virus did not produce a generalized disease, for no virus was isolated from the internal organs of two wildebeest which died with active vulvovaginitis.

Experimentally, the virus was able to induce a mild vulvovaginitis in a domestic heifer without any generalized disease and was shown to be capable of establishing a continuing latent genital infection.

Since the steers kept in close contact with the infected wildebeest did not show clinical signs or VN antibodies, probably this infection is not readily transferable from wildebeest to cattle. Cattle-to-cattle transmission, on the other hand, is said to occur readily.⁴

Acknowledgements

A cooperative project of the Government of Kenya, supported in part by the Canadian International Development Agency, with the International Development Research Centre as executing agency. Published with permission of the Director, Veterinary Research Department, Kenya Agricultural Research Institute, and the Director of Veterinary Services, Kenya. The technical assistance of Messrs D. Waweru, J. Mumira and H. Agili is gratefully acknowledged.

LITERATURE CITED

1. COLLINGS, D.F., E.P.J. GIBBS and L.P. STAFFORD. 1972. Concurrent respiratory and genital disease associated with infectious bovine rhinotracheitis/infectious pustular vulvovaginitis (IBR/IPV) virus in a dairy herd in the United Kingdom. *Vet. Rec.* 91: 214-219.
2. GIBBS, E.P.J. and M.M. RWEYEMAMU. 1977. Bovine herpesviruses. *Vet. Bull.* 47: 317-425.
3. GROOTENHUIS, J.G., L.H. KARSTAD and S.A. DREVEMO. 1976. Experience with drugs for capture and restraint of wildebeest, impala, eland and hartebeest in Kenya. *J. Wildl. Dis.* 12: 435-443.
4. KAHRS, R.F. 1977. Infectious bovine rhinotracheitis: a review and update. *J. Am. vet. med. Ass.* 171: 1055-1064.
5. KAMINJOLO, J.S. Jr., P.N. NYAGA, J.K. OMUSE and E.R. MUTIGA. 1975. Infectious bovine rhinotracheitis/infectious pustular vulvovaginitis viral isolates from cattle with epididymitis and vaginitis. *Am. J. vet. Res.* 36: 123-125.
6. KARSTAD, L., D.M. JESSETT, J.C. OTEMA and S. DREVEMO. 1974. Vulvovaginitis in wildebeest caused by the virus of infectious bovine rhinotracheitis. *J. Wildl. Dis.* 10: 392-396.
7. LENNETTE, E.H. and N.J. SCHMIDT. 1964. *Diagnostic Procedures for Viral and Rickettsial Diseases*, p. 48. American Public Health Association Inc., New York.

8. LORETU, K., P. MARIV, I. GENOV and H. BOHNEL. 1974. Virus isolations from cases of infectious bovine pustular vulvovaginitis and posthitis (IPV/IPB) in cattle in Tanzania. *Bull. Epizoot. Dis. Afr.* 22: 303-309.
9. McKERCHER, D.G. 1973. The viruses of other vertebrates. In: *The Herpesviruses*. A.S. Kaplan, Ed. pp. 427-493. Academic Press, New York and London.
10. PLOWRIGHT, W. and R.D. FERRIS. 1961. The preparation of bovine thyroid monolayers for use in virological investigations. *Res. Vet. Sci.* 2: 149-152.
11. RAMPTON, C.S. and D.M. JESSETT. 1976. The prevalence of antibody to infectious bovine rhinotracheitis virus in some game animals of East Africa. *J. Wildl. Dis.* 12: 2-6.
12. RWEYEMAMU, M.M. 1970. Probable occurrence of infectious bovine rhinotracheitis virus in Tanzanian wildlife and cattle. *Nature, London.* 225: 738-739.
13. ———. 1974. The incidence of infectious bovine rhinotracheitis antibody in Tanzanian game animals and cattle. *Bull. Epizoot. Dis. Afr.* 22: 19-22.

Received for publication 2 October 1978
