



## **A SQUAMOUS CELL CARCINOMA IN A CALIFORNIA GROUND SQUIRREL (*Spermophilus beecheyi*)**

Authors: TRIGO, FRANCISCO J., and RISER, MARIANNA

Source: Journal of Wildlife Diseases, 17(3) : 405-406

Published By: Wildlife Disease Association

URL: <https://doi.org/10.7589/0090-3558-17.3.405>

---

BioOne Complete ([complete.BioOne.org](https://complete.BioOne.org)) is a full-text database of 200 subscribed and open-access titles in the biological, ecological, and environmental sciences published by nonprofit societies, associations, museums, institutions, and presses.

Your use of this PDF, the BioOne Complete website, and all posted and associated content indicates your acceptance of BioOne's Terms of Use, available at [www.bioone.org/terms-of-use](https://www.bioone.org/terms-of-use).

Usage of BioOne Complete content is strictly limited to personal, educational, and non - commercial use. Commercial inquiries or rights and permissions requests should be directed to the individual publisher as copyright holder.

---

BioOne sees sustainable scholarly publishing as an inherently collaborative enterprise connecting authors, nonprofit publishers, academic institutions, research libraries, and research funders in the common goal of maximizing access to critical research.

## A SQUAMOUS CELL CARCINOMA IN A CALIFORNIA GROUND SQUIRREL (*Spermophilus beecheyi*)

FRANCISCO J. TRIGO, Department of Pathology, College of Veterinary Medicine, Washington State University, Pullman, Washington 99164, USA.

MARIANNA RISER, Clearwater Animal Clinic, Kennewick, Washington 99336, USA.

**Abstract:** The presence of a typical and circumscribed squamous cell carcinoma located in the right carpus of a California ground squirrel (*Spermophilus beecheyi*) is described. The prevalence of this carcinoma is discussed.

### INTRODUCTION

Squamous cell carcinoma is an invasive malignant tumor of squamous epithelial cells commonly observed in adult domestic animals,<sup>8</sup> but it is not reported frequently in wild rodents, including squirrels.<sup>1-4</sup> However, squirrels are known to be commonly affected by skin tumors as a result of infection with the squirrel fibroma virus, which produces multiple fibromas in the skin and in internal organs.<sup>6,7</sup>

This report describes a squamous cell carcinoma on the anterior right leg of a California ground squirrel (*Spermophilus beecheyi*).

### CLINICAL HISTORY

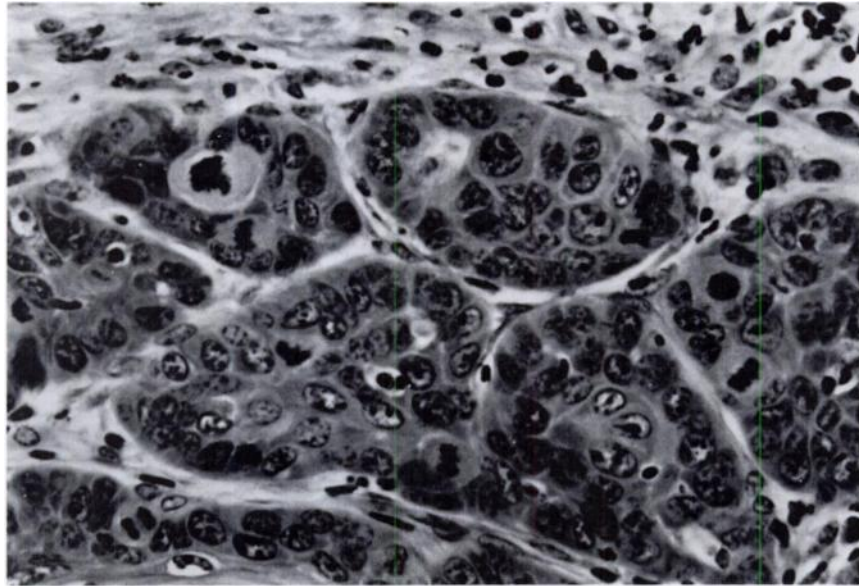
A 7-year-old male California ground squirrel was presented on 20 May 1980 for clinical examination because of a tissue mass, which had been slowly growing for months, located on the anterior aspect of the right carpus. The mass was hairless, erythematous and measured 1 cm in diameter. The tissue was surgically removed on that day, but unfortunately this mass was not sent for histological examination. One month later, there was another 1 cm in diameter tumor regrowth in the same place, but now with an ulcerated cauliflower-like appearance. The mass was presumably very irritating, provoking the animal to chew continuously on the limb. No clinical evidence of local lymph node

involvement was noticed. At this time a biopsy specimen sent to Washington State University indicated the presence of a squamous cell carcinoma, so amputation of the limb was performed on 11 July. The animal recovered satisfactorily from surgery and is still living as a household pet, without any evidence of metastatic spread to other parts of the body.

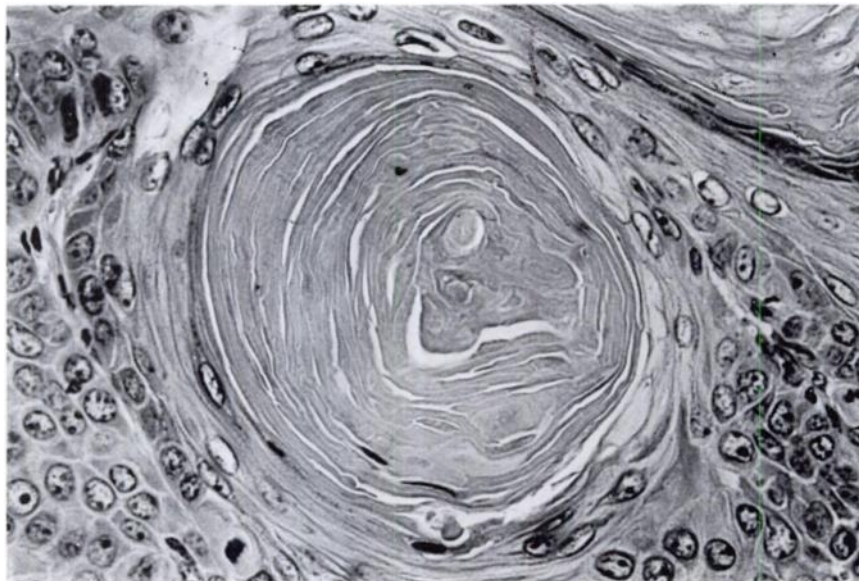
### HISTOPATHOLOGY

The sample received for histological examination was fixed in 10% neutral buffered formalin and routinely processed for histopathology. Sections were cut at 5  $\mu$ m and stained with hematoxylin and eosin and phosphotungstic acid hematoxylin (PTAH).

Histopathologic examination of the tissue indicated a well-differentiated squamous cell carcinoma<sup>9</sup> (Figure 1). The tumor was composed of squamous cells organized in cords, with keratinized centers arranged in the typical shape of lamellated pearls and proliferating downwards into the dermis (Figure 2). The neoplastic cells were pleomorphic, with abundant eosinophilic glassy-looking cytoplasm and ovoid nuclei with prominent single or multiple nucleoli. There was a high mitotic index, with an average of three mitotic figures per high power field; some mitotic figures had a bizarre morphology. With PTAH, well-defined intercellular bridges were clearly



**FIGURE 1.** Neoplastic squamous cells arranged in cords where multiple mitotic figures are observed. H&E 320  $\times$ .



**FIGURE 2.** Typical lamellated pearl composed of concentric layers of squamous cells showing gradual keratinization towards the center. H&E 330  $\times$ .

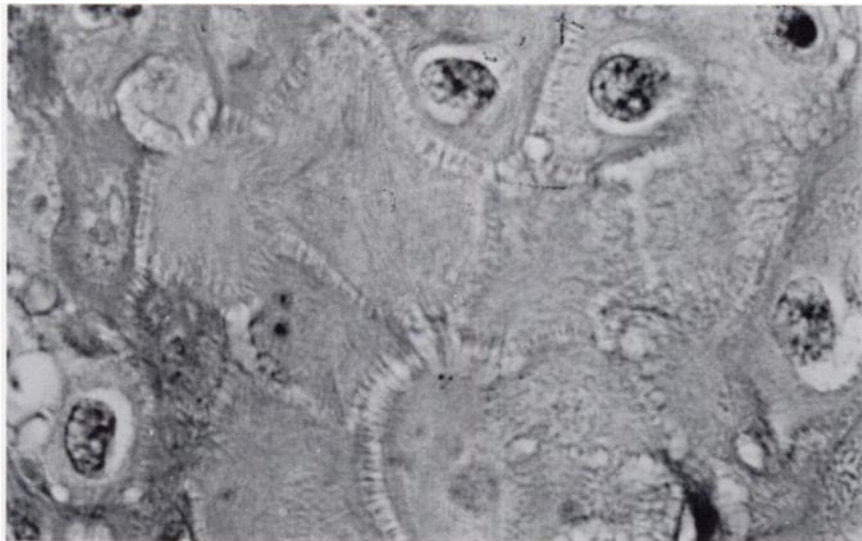


FIGURE 3. Clearly defined intercellular bridges among the neoplastic squamous cells. PTAH 1,100  $\times$ .

seen in most parts of the tumor. The borders of the neoplastic mass at the interface with normal dermis indicated that the tumor was growing by expansion rather than infiltration. Local lymphatic and blood vessels were free of tumor permeation or metastatic invasion.

#### DISCUSSION

The pathology and behaviour of skin tumors, such as squamous cell carcinoma, are well documented in domestic animals, whereas little is known about wild animal counterparts, presumably because most animals living in the wild are not examined for neoplasms. This is reflected in the sparse literature on naturally occurring neoplasms in squirrels, which includes brief descrip-

tions of a sternal osteoma, a renal hydronephroma, an hepatic adenoma<sup>2</sup> and a report on viral induced cutaneous fibromas.<sup>7</sup>

Squamous cell carcinoma is a common malignant skin tumor in the dog, horse and cat.<sup>8,9</sup> The gross and microscopic features of this case closely resemble typical descriptions of this neoplasm in domestic animals, as an irritating and ulcerating tumor, slow to metastasize, and composed of squamous cells arranged in cords with keratinized centers.<sup>8,9</sup>

The sudden rapid growth of this tumor and its localized invasive behaviour, with no apparent spread to distant tissues, is similar to the pattern in the dog, where the limbs are also a common primary site.<sup>5</sup>

#### LITERATURE CITED

1. FOX, H. 1912. Neoplasms in wild animals. *J. Path. Bact.* 17: 217-231.
2. ——. 1923. *Diseases in Captive Wild Mammals and Birds*. Lippincot Co. Philadelphia. p. 464.

3. HALLORAN, P.O. 1955. Diseases of wild mammals and birds. A bibliography of references. *Am. J. Vet. Res.* 16: 106-117.
4. HAMERTON, A.E. 1931. Report on the deaths occurring in the society's gardens during 1930. *Proc. zool. Soc. Lond.* 1: 527-540.
5. HEAD, K.W. 1953. Skin diseases: Neoplastic diseases. *Vet. Rec.* 65: 926-929.
6. HERMAN, C.M. 1955. Skin tumors on squirrels. *J. Wildl. Manage.* 19: 402-403.
7. KING, J.M., A. WOOLF and J.N. SHIVELY. 1972. Naturally occurring squirrel fibroma with involvement of internal organs. *J. Wildl. Dis.* 8: 321-324.
8. STANNARD, A.A. and L.T. PULLEY. 1978. Tumors of the skin and soft tissues, In: *Tumors of Domestic Animals*, 2nd ed. J.E. Moulton, Ed., University of California Press, Berkeley. p. 45.
9. WEISS, E. and K. FRESSE. 1974. Tumours of the skin. *International Histological Classification of Tumours in Domestic Animals. Bull. WHO.* 50: 79-100.

*Received for publication 21 August 1980*

---