



A HERPESVIRUS-LIKE AGENT ASSOCIATED WITH A PHARYNGEAL ABSCESS IN A DESERT TORTOISE

Authors: HARPER, P.A.W., HAMMOND, D.C., and HEUSCHELE, W.P.

Source: Journal of Wildlife Diseases, 18(4) : 491-494

Published By: Wildlife Disease Association

URL: <https://doi.org/10.7589/0090-3558-18.4.491>

BioOne Complete (complete.BioOne.org) is a full-text database of 200 subscribed and open-access titles in the biological, ecological, and environmental sciences published by nonprofit societies, associations, museums, institutions, and presses.

Your use of this PDF, the BioOne Complete website, and all posted and associated content indicates your acceptance of BioOne's Terms of Use, available at www.bioone.org/terms-of-use.

Usage of BioOne Complete content is strictly limited to personal, educational, and non - commercial use. Commercial inquiries or rights and permissions requests should be directed to the individual publisher as copyright holder.

BioOne sees sustainable scholarly publishing as an inherently collaborative enterprise connecting authors, nonprofit publishers, academic institutions, research libraries, and research funders in the common goal of maximizing access to critical research.

A HERPESVIRUS-LIKE AGENT ASSOCIATED WITH A PHARYNGEAL ABSCESS IN A DESERT TORTOISE

P.A.W. HARPER, Pathology Department, Zoological Society of San Diego, San Diego, California, 92112, USA.
D.C. HAMMOND and W.P. HEUSCHELE, Research Department, Zoological Society of San Diego, San Diego, California, 92112, USA.

A 6-yr old male tortoise (*Gopherus agassizi*) which had been maintained in captivity since a hatchling, was found dead in its enclosure. No clinical signs were observed in this animal or in its sibling cagemate prior to the mortality. The animal was presented for necropsy and selected tissue specimens were fixed in buffered 10% formalin solution. Sections were cut at 6 μ m thickness and stained by hematoxylin and eosin, P.A.S., and the Brown-Brenn gram stain for bacteria. Pieces of pharyngeal tissue, originally fixed in 10% formalin, were then rinsed in several changes of phosphate buffer, pH 7.4, and fixed overnight in phosphate buffered 2.5% glutaraldehyde and post-fixed for 1 hr in 1% OsO₄ in phosphate buffer. They were then dehydrated in alcohol and propylene oxide and finally embedded in araldite. Thin sections were cut on a Sorvall MT-2B ultramicrotome, stained with uranyl acetate and lead citrate, and examined with a Zeiss 10 electron microscope.

The tortoise was in poor nutritional condition, with depletion of fat from most depots. The posterior dorsal pharynx contained a 2 cm diameter superficial accumulation of yellow caseous material that occluded the glottis. The material was adherent to a thickened pharyngeal epithelium. The stomach contained mucus only; however, the colon was distended by green fibrous food material. No lesions were noted in other organs.

Histologic examination of sections of the lesion revealed a dense accumulation of eosinophilic caseonecrotic debris overlying a hypertrophic pharyngeal

mucosa (Fig. 1). There was extensive vacuolation of the cytoplasm of the superficial epithelial cells, and many nuclei were shrunken and contained large, homogeneous, eosinophilic inclusion bodies (Fig. 2). Margination of chromatin was present in some affected nuclei. A moderate infiltrate of eosinophilic granulocytes and mononuclear cells surrounded blood vessels in the submucosa. Occasional mixed bacterial populations were seen within and lining the margins of the caseonecrotic exudate. Sections from other parenchymatous organs were normal, apart from mild peribronchiolar accumulations of mononuclear cells and eosinophilic granulocytes in the lung.

Ultrastructural examination of the lesion revealed numerous enveloped icosahedral viral particles (143 nm in size) within cytoplasmic vesicles and free in the cytoplasm of pharyngeal epithelial cells (Fig. 3A). Most of these viral particles had a dense core measuring about 80 nm in diameter, but some empty capsids were also seen.

Within the nuclei of some of the pharyngeal epithelial cells there were large, prominent, reticulated fibrous structures varying in width from 100-200 nm, and in length from 1-3 μ m (Fig. 4). We interpret these structures to be developing viral DNA nucleoid precursors. Within other nuclei there were herpesvirus-like particles (Fig. 5A) of approximately 100 nm diameter. The interior of some of these particles had four to five focal denser areas, giving a wheel and spoke-like appearance (Fig. 5B). The majority of particles had a multilayered hexagonal envelope and a dense nucleoid

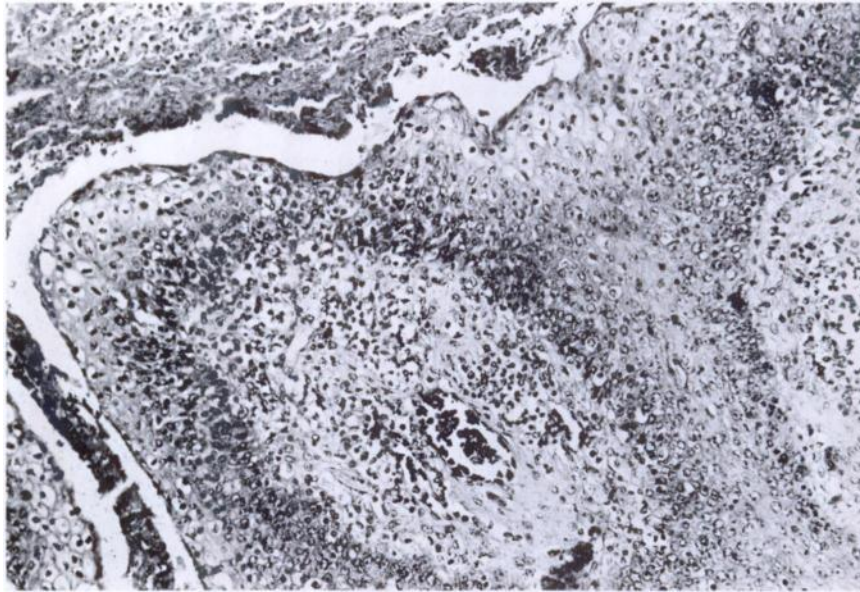


FIGURE 1. Pharyngeal lesion with caseonecrotic exudate, vacuolation of epithelial cells, and submucosal infiltrate. H & E $\times 125$.

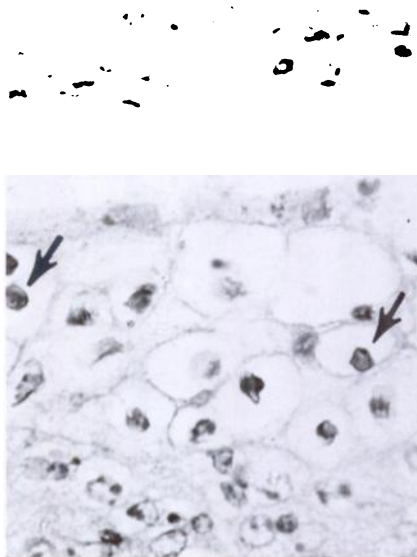


FIGURE 2. Pharyngeal epithelium with intranuclear inclusions in superficial cells (arrows). H & E $\times 425$.

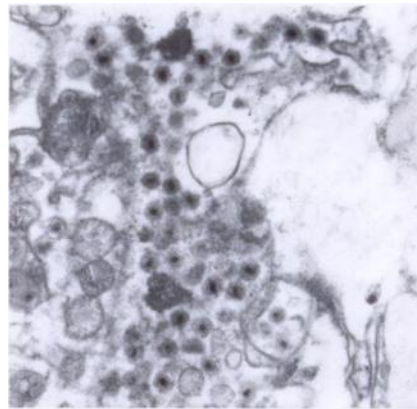


FIGURE 3A. Herpesvirus-like virions within the cytoplasm of a pharyngeal epithelial cell. $\times 25,000$.

core (Fig. 3B). Some naked particles were also seen.

Reptiles, as hosts of viral agents, remain a relatively unexplored group of

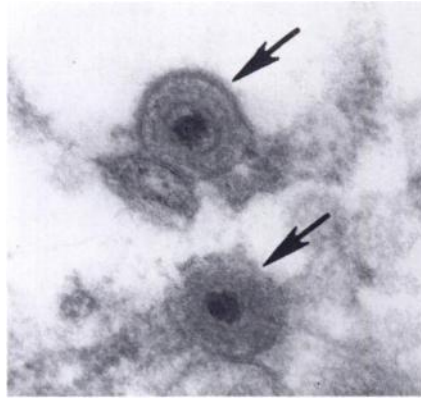


FIGURE 3B. High magnification of complete mature herpesvirus-like virions (arrows) in the cytoplasm of a pharyngeal epithelial cell. $\times 89,000$.

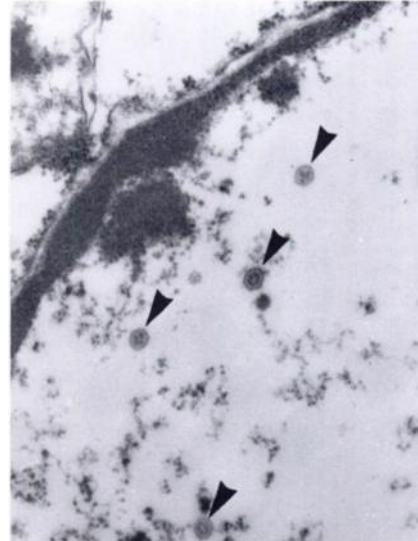


FIGURE 5A. Developing virions (arrows) in nucleus of a pharyngeal epithelial cell. $\times 40,000$.

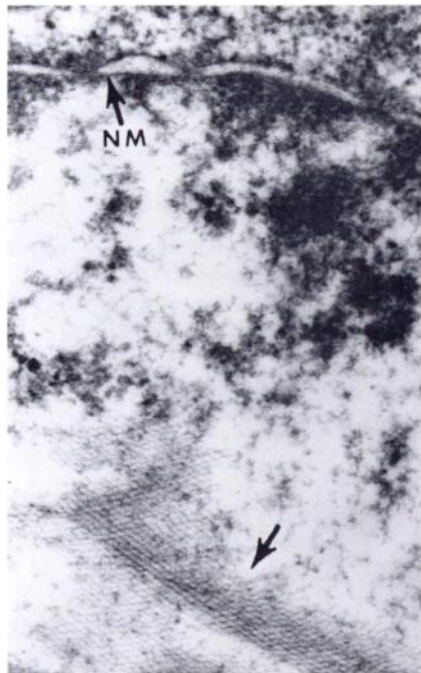


FIGURE 4. Electron-dense intranuclear reticular fibers (arrow) in nucleus of a pharyngeal epithelial cell. $\times 63,000$. NM is the nuclear membrane.

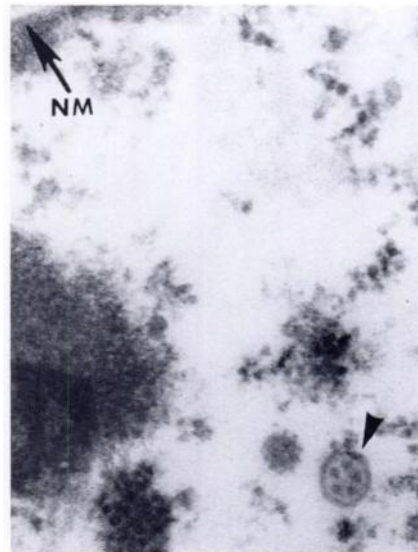


FIGURE 5B. Higher magnification of developing virion (arrow) in nucleus of a pharyngeal epithelial cell. $\times 75,000$. NM is the nuclear membrane.

vertebrates, and it has been suggested that most virus-related diseases of reptiles go unrecorded. (Jacobson, 1980, In: *Reproductive Biology and Diseases of Captive Reptiles*. J.B. Murphy and J.T. Collins, (eds.). Soc. for the Study of Reptiles and Amphibians, pp. 197-199). Although no viral agents were observed in a study of 1,500 reptiles with liver disease (Will, 1975, *Zentralbl. Veterinärmed.* 22: 626-634), and a study of 70 cases of disease in tortoises did not mention viral agents (Holt et al., 1979, *J. Small Anim. Pract.* 20: 269-286), there have been several recent reports of herpesvirus-like infections in turtles. Herpesvirus-like inclusions and virions were demonstrated in the liver and spleen of two captive Pacific pond turtles (*Clemmys marmorata*) that died with hepatic necrosis following a sudden onset of lethargy, anorexia and weakness (Frye et al., 1977, *J. Am. Vet. Med. Assoc.* 171: 882-884; Frye, 1981, *Biomedical and Surgical Aspects of Captive Reptile Husbandry*. Veterinary Medicine Publishing Company, Edwardsville, Kansas, pp. 161-165). A similar report describes intranuclear inclusion bodies and herpesvirus-like particles in hepatocytes and respiratory epithelial cells of a painted turtle (*Chrysemys picta*) with necrosis in the liver and lungs (Cox et al., 1980, *J. Wildl. Dis.* 16: 445-449). In addition, a herpesvirus has been shown to be the causative agent of epizootics of a cutaneous infection, termed grey-patch disease, in 2-3 mo old green turtles (*Chelonia mydas*). (Haines and Kleese,

1977, *Infect. Immun.* 15: 756-759; Rebell et al., 1975, *Am. J. Vet. Res.* 36 1221-1224).

In the present study, a desert tortoise was necropsied with an unusual pharyngeal abscess, that at gross examination was presumed to be of bacterial etiology. On histologic examination, intranuclear inclusions suggesting herpesvirus infection were found in the mucosal epithelial cells, and electron microscopic examination confirmed the presence of virions morphologically consistent with a herpesvirus, in various stages of development and maturation. The mature virions were morphologically similar to those previously reported in chelonians (Cox et al., op. cit.; Frye et al., op. cit.; Rebell et al., op. cit.). Unfortunately, additional virologic studies were not possible, as only formalin-fixed tissues were retained.

It is becoming apparent that herpesviruses are widespread in vertebrates (Nahmias, 1972, In: *Pathobiology Annual* 2. Ioachin (ed.) Appleton-Century-Crofts, New York, N.Y., pp. 153-181). The addition of this report to the literature suggests that herpesvirus infection may be an important cause of cutaneous and systemic disease in captive chelonians.

The authors are grateful to Ms. Audrey Young for typing the manuscript, Mr. Richard Rimmel for histologic technical assistance, and to Capt. W. O'Harrison, Clinical Investigations Center, Naval Regional Medical Center, San Diego, California, for use of electron microscope facilities.

Received for publication 11 March 1982