

Granulomatous Peritonitis in a Fish Caused by a Flagellated Protozoan

Authors: Gardiner, C. H., and Bunte, Ralph M.

Source: Journal of Wildlife Diseases, 20(3) : 238-240

Published By: Wildlife Disease Association

URL: <https://doi.org/10.7589/0090-3558-20.3.238>

BioOne Complete (complete.BioOne.org) is a full-text database of 200 subscribed and open-access titles in the biological, ecological, and environmental sciences published by nonprofit societies, associations, museums, institutions, and presses.

Your use of this PDF, the BioOne Complete website, and all posted and associated content indicates your acceptance of BioOne's Terms of Use, available at www.bioone.org/terms-of-use.

Usage of BioOne Complete content is strictly limited to personal, educational, and non - commercial use. Commercial inquiries or rights and permissions requests should be directed to the individual publisher as copyright holder.

BioOne sees sustainable scholarly publishing as an inherently collaborative enterprise connecting authors, nonprofit publishers, academic institutions, research libraries, and research funders in the common goal of maximizing access to critical research.

pure culture of *D. congolensis* was recovered after 48 hr incubation at 37 C. The colonies were buff colored, raised, adherent, wrinkled, and surrounded by a zone of hemolysis. The isolated organism had morphologic and biochemical characteristics typical of *D. congolensis* (Pier et al., 1963, J. Am. Vet. Med. Assoc. 142: 995-1000).

This report adds an additional animal, the mule deer, to the growing list of animal hosts of *D. congolensis*. It seems possible that wildlife may act as a reservoir of this infection in many areas, considering the long list of known wildlife hosts (Richard and Schotts, 1976, Wildlife Diseases, Plenum Press, New York, New York, pp. 205-214). Despite extensive laboratory effort, *D. congolensis* has never been isolated as a free-living agent in the environment. It is considered to be an obligate parasite that is transmitted by direct contact or arthropod vectors from animal to animal (Richard and Pier, 1966, Am. J.

Vet. Res. 27: 419-423). Moisture enhances transmission presumably due to release of the motile zoospore phase of the organism (Pier, 1981, op. cit.). In much of Wyoming, the summer of 1983 was unusually wet due to abundant rainfall; however, in the Clearmont area summer rainfall was below normal.

Recognition of this condition in mule deer in Wyoming may have been the basis for the report of mycotic dermatitis in 1957 (Post and Winter, 1957, op. cit.), a term often applied to dermatophilosis of sheep and goats (Austwick, 1958, Vet. Rev. Annot. 4: 33-48). If that were the situation, the 1957 Wyoming report antedated other reports of this disease in the United States by 4 yr. However, lack of described cultural or microscopic data leaves this issue unresolved.

The authors thank Mr. Frank Auzque, Mr. Mark Owens, Ms. M. A. Reis, Ms. Sal Etherton, Mrs. Inez Johnson and Dr. E. Tom Thorne for assistance.

Journal of Wildlife Diseases, 20(3), 1984, pp. 238-240
© Wildlife Disease Association 1984

Granulomatous Peritonitis in a Fish Caused by a Flagellated Protozoan

C. H. Gardiner and Ralph M. Bunte, Department of Veterinary Pathology, Armed Forces Institute of Pathology, Washington, D.C. 20306, USA

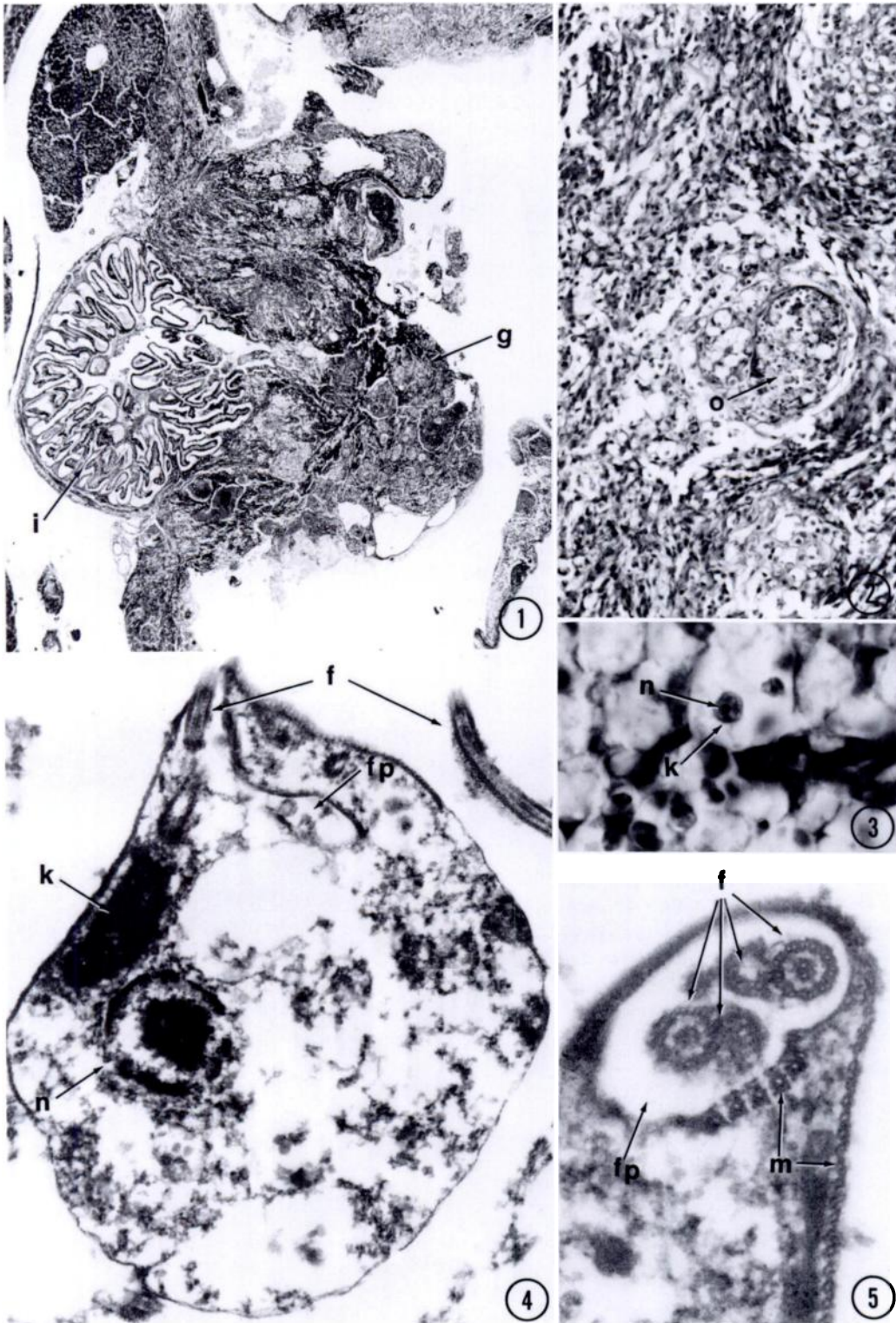
An immature African cichlid (*Lamprologus elongatus* Boulenger, 1898), housed in a large show aquarium, was no-

ticed to have a worm-like structure protruding from the ventral mid-line. The fish was killed and submitted for histopathology.

In histologic section, abundant granu-

Received for publication 21 November 1983.

FIGURES 1-5. Granuloma in abdominal cavity of an African cichlid caused by flagellates. 1. Granuloma eroding through intestine. (i), intestine; (g), granuloma. H&E, $\times 25$ (AFIP MIS #83-8290). 2. Granuloma consisting of histiocytes and fibroblasts surrounds nests (o) of organisms. Most organisms appear to be contained within vacuoles. H&E, $\times 250$ (AFIP MIS #83-8291). 3. Organism has one nucleus (n) and a dark kinetoplast nucleoid (k) which gives rise to the flagella. H&E, $\times 1,000$ (AFIP MIS #83-8294). 4. Transmission electron micrograph of flagellate. (n), nucleus; (k), kinetoplast nucleoid; (f), flagella; (fp), flagellar pocket. $\times 19,700$ (AFIP MIS #83-8298). 5. Transmission electron micrograph of flagellar pocket. (f), flagella; (fp), flagellar pocket; (m) pellicular microtubules. Note 9 + 2 axoneme structure. $\times 63,350$ (AFIP MIS #83-8295).



lomatous tissue replaced a large portion of the intestine (Fig. 1), filled much of the ventral abdominal cavity, covered and eroded into parts of the ventral serosa and muscle, and extended through the body wall. The granulomatous tissue was composed predominantly of macrophages and interspersed fibroblasts, which frequently formed discreet microgranulomas (Fig. 2), and a few scattered granulocytes and lymphocytes. Random multifocal areas of moderate coagulative and caseous necrosis were also present. Numerous oval to crescent organisms formed nests throughout the reaction. The organisms were 5 μ m in greatest width and appeared to be in vacuoles in histiocytes. With hematoxylin and eosin stains, a large eccentric nucleus and dense organelle were discernible (Fig. 3). With transmission electron microscopy the organisms were identified as flagellated protozoans (Fig. 4). The nucleus contained a large nucleolus and peripheral clumps of chromatin. A large kinetoplast nucleoid gave rise to at least four flagella. The flagella were present both in a flagellar pocket and external to the organisms in most sections (Fig. 5). On cross section the axoneme (i.e., 9 + 2) structure of the flagellum could be discerned. The plasma membrane contained rows of pellicular microtubules.

Two genera of flagellates are reported from the intestine of fish, *Hexamita* and *Spironucleus* (Becker, 1977, *In Parasitic Protozoa*, Kreier (ed.), Academic Press, San Francisco, California, pp. 356–416). All are members of the family Hexamitidae,

order Diplomonadida. *Hexamita* is much more common than *Spironucleus*. The flagellate in this case differs from the above genera in several ways: 1) This organism is uninucleate; members of the Hexamitidae are binucleate; and 2) this organism is much smaller than these two genera.

The flagellate in this case has several ultrastructural similarities to *Ichtyobodo* (*Costia*) *necator* (Henneguy, 1883) Pinto, 1928 (Joyon and Lom, 1969, *J. Protozool.* 16: 703–719). *Ichtyobodo* has a longitudinal groove which contains two or four flagella. This groove is similar to the flagellar pocket in this organism. *Ichtyobodo* has an elongated mitochondrion, but does not have a prominent kinetoplast nucleoid as is seen in this organism. In addition, *Ichtyobodo* has only been reported from the gill filaments and has never been reported from the peritoneal cavity.

The exact identity of this organism is unknown but it is evident that the necrogranulomatous enteritis, peritonitis, and myositis with extension through the ventral abdominal wall was caused by the organism. The pathogenesis of the infection is unknown. The organisms may have initially been in the lumen of the intestine and extended outwardly through the intestine and ventral abdominal wall. They could have actively penetrated these structures or could have invaded ulcers present in the intestine.

Thanks to Dr. C. Dale Becker for his review of the case and to Mrs. Marion S. Kamins for technical assistance.