



Avian Pox in a Red-tailed Hawk (*Buteo jamaicensis*)

Authors: Fitzner, R. E., Miller, R. A., Pierce, C. A., and Rowe, S. E.

Source: Journal of Wildlife Diseases, 21(3) : 298-301

Published By: Wildlife Disease Association

URL: <https://doi.org/10.7589/0090-3558-21.3.298>

BioOne Complete (complete.BioOne.org) is a full-text database of 200 subscribed and open-access titles in the biological, ecological, and environmental sciences published by nonprofit societies, associations, museums, institutions, and presses.

Your use of this PDF, the BioOne Complete website, and all posted and associated content indicates your acceptance of BioOne's Terms of Use, available at www.bioone.org/terms-of-use.

Usage of BioOne Complete content is strictly limited to personal, educational, and non - commercial use. Commercial inquiries or rights and permissions requests should be directed to the individual publisher as copyright holder.

BioOne sees sustainable scholarly publishing as an inherently collaborative enterprise connecting authors, nonprofit publishers, academic institutions, research libraries, and research funders in the common goal of maximizing access to critical research.

tory of Rabies, Vol. II, Academic Press, New York, pp. 3–22) in the southeastern states during the 1960's. The geometric mean titer (GMT) of virus in salivary glands tested in these earlier studies was $10^{4.90}$ in raccoons and $10^{4.09}$ in red foxes. Among the raccoons from Virginia, 81% (85/105) shed measurable amounts of vi-

rus and the GMT of virus in the salivary glands was $10^{3.21}$.

It seems clear from these data that the salivary glands of many rabid raccoons contain substantial amounts of infectious rabies virus. Bites by such animals should be regarded as potentially capable of transmitting rabies.

Journal of Wildlife Diseases, 21(3), 1985, pp. 298–301

Avian Pox in a Red-tailed Hawk (*Buteo jamaicensis*)

R. E. Fitzner, R. A. Miller, C. A. Pierce, and S. E. Rowe, Battelle, Pacific Northwest Laboratory, P.O. Box 999, Richland, Washington 99352, USA

Avian pox has been reported in at least 60 species of birds belonging to 20 different families (Kirmse, 1967, Wildl. Dis. 49). However, poxvirus infection in birds of prey is apparently uncommon (Cooper, 1969, Vet. Rec. 85: 683–684; Greenwood and Blakemore, 1973, Vet. Rec. 93: 468–470; Halliwell, 1972, J. Wildl. Dis. 8: 104–105; Moffatt, 1972, J. Wildl. Dis. 8: 161–162; Pearson et al., 1975, J. Wildl. Dis. 11: 224–228; Thiele et al., 1979, Arch. of Virol. 62: 77–82; Tantawi et al., 1981, J. Wildl. Dis. 17: 145–146; Schmeling and Docherty, 1982, *In Workshop on Raptor Management and Biology in Alaska and W. Canada*, Ladd and Schempf (eds.), U.S. Fish and Wildlife Service, Alaska Regional Office, pp. 255–262). Attempts at isolating the causal virus in falcons were made by Cooper (1969, op. cit.) and Greenwood and Blakemore (1973, op. cit.), but were unsuccessful. Later, Thiele et al. (1979, op. cit.) and then Tantawi et al. (1981, op. cit.) were successful in isolating avian poxvirus from saker falcons (*Falco cherrug*) and from a European sparrow hawk (*Accipiter nisus*), respectively. This

short communication reports a pox infection in a wild red-tailed hawk.

On 18 May 1981, an adult male red-tailed hawk was found on the U.S. Department of Energy's "Arid Land Ecology Reserve" in Benton County, Washington. The bird was incapable of flight and was extremely thin. Nodular proliferations were noted on both feet and cutaneous scab-like lesions around the beak and eyes. No other lesions were seen during the field examination.

The bird was killed in the field and submitted promptly to the diagnostic laboratory for necropsy. Tissue sections were taken from the skin above the eye, skin adjacent to the beak, right kidney, liver, adrenal, peritoneal wall, heart, aorta, spleen and lung and preserved in 10% neutral buffered formalin (NBF). Direct smears from the foot lesion, pleura, kidney, peritoneal fluid, beak, lungwash and liver were Gram stained. Samples of foot lesions, pleura, peritoneal fluid, liver, kidney, lungwash and mouth lesions were cultured aerobically on 5% sheep blood agar and MacConkey agar.

Tissues fixed in 10% NBF were paraffin embedded, sectioned at 8 μ m and stained

Received for publication 16 August 1984.

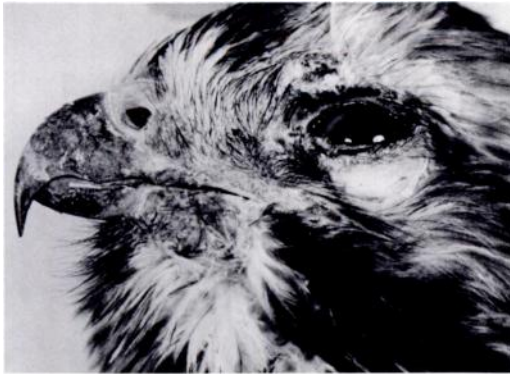

FIGURE 1. Head of adult male red-tailed hawk with pox infection. Note crusted, raised lesion on the brow of the eye and subtle lesions on the skin by the maxillary and mandibular areas.

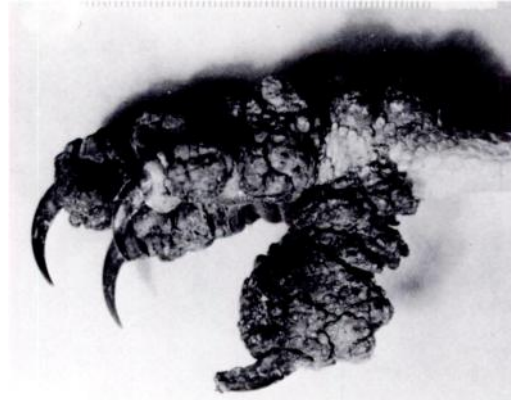

FIGURE 2. Proliferative, fissured foot lesion in an adult male red-tailed hawk.

with hematoxylin and eosin, Grocott's method for fungus, and Brown and Brenn Gram Stain (Luna (ed.), 1968, Manual of Histologic Staining Methods of the Armed Forces Institute of Pathology, 3rd Ed., McGraw-Hill Book Co., New York, 258 pp.).

The tissue for electron microscopy was post-fixed in 1% cacodylate buffered osmium tetroxide, dehydrated in a series of graded acetone and embedded in Medcast (Ted Pella, Inc., Tustin, California 92106, USA). Ultrathin sections were cut with an LKB ultramicrotome, mounted on copper grids, stained with uranyl acetate and lead citrate, examined and photographed with a Philips 300 transmission electron microscope.

Necropsy examination revealed a 0.7 cm raised and crusted lesion on the brow of the left eye and subtle 0.5 cm and 1.0 cm focal, crusted lesions on the skin adjacent to the beak from the left maxillary and mandibular areas, respectively (Fig. 1). There was a 0.5 cm slightly crusted lesion on the commissure of the right side of the mouth. The left foot had severe, diffuse cutaneous thickening over all the toes (Fig. 2). This proliferative lesion was dark brown, crusty, deeply fissured and had a cobblestoned, multinodular appearance.

The right foot had similar lesions but they were not as extensive. Where the scabs were easily removed, the underlying tissue was covered by a sero-purulent exudate on the bleeding granulated surface.

The crop contained approximately 20 nematodes (*Capillaria* sp.) with no apparent tissue reaction to them. There were two focal areas, 1.5 cm × 0.4 cm, containing yellow caseous debris, on the ventral peritoneum and the peritoneal cavity contained about 20 ml of light yellow, cloudy fluid. The liver was swollen, pale and had a thickened capsule. The oral cavity and esophagus appeared normal.

Gram-stained impression smears made from the viable tissue beneath the scabs on the left foot contained many staphylococcus-like organisms. Aerobic cultures from the same area yielded several organisms, the predominant one being *Staphylococcus aureus*. This organism was the main isolate recovered from the peritoneal fluid and the skin lesion at the right commissure of the mouth.

Histologic sections of the skin from over the eye, from the foot, and around the mouth showed marked epithelial hyperplasia, resulting in deep folds, especially on the foot. Most of the hypertrophic cells within the proliferative epithelium con-

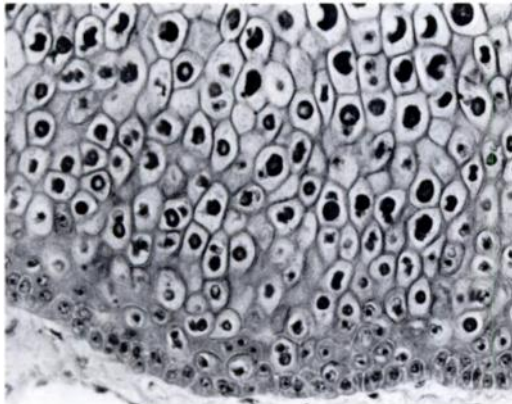


FIGURE 3. Markedly hyperplastic epithelium with numerous intracytoplasmic inclusion bodies in the hypertrophic epithelial cells from skin over the eye of an adult male red-tailed hawk. H&E., $\times 250$.

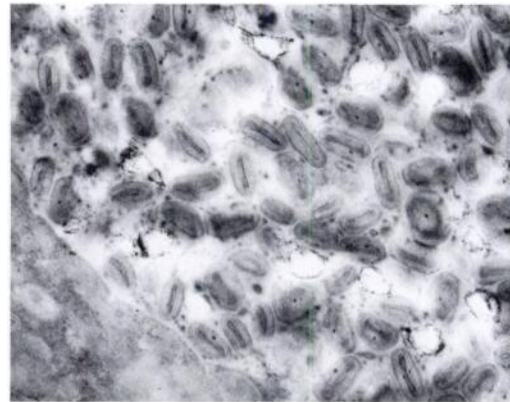


FIGURE 4. Electron micrograph demonstrating the poxvirus particles from the epithelial lesions in the skin over the eye of an adult male red-tailed hawk. $\times 50,000$.

tained large eosinophilic, intracytoplasmic inclusion bodies (Bollinger bodies) displacing nuclei to the periphery (Fig. 3). The epithelial surface had a variable amount of exudate. One section of the skin had focal granulomas characterized by multinucleated giant cells, heterophils, and mononuclear inflammatory cells aggregated around islands of necrotic debris, keratin and inclusion bodies.

Other lesions of importance were multifocal hepatic necrosis and inflammation and a severe suppurative peritonitis involving the surface of the liver, pancreas, adrenal, and spleen. The Grocott fungus stain faintly outlined septate mycelial elements in the inflammatory crust, granulomas, and hyperplastic epithelium of one section of skin.

Electron microscopic examination showed abundant oval and brick-like poxvirus particles some of which have the conspicuous dumbbell-shaped core (Fig. 4).

Avian poxvirus infection in free-living raptorial birds is uncommon. The majority of reported cases were in captive birds from the Arabian Gulf that were held primarily for falconry purposes. Greenwood

and Blakemore (1973, op. cit.) suspected that the pox infections were acquired by the Arabian Gulf birds of prey after capture, particularly if they were maintained under poor conditions which may exist when birds are intended for export. Captive raptors used for falconry purposes are also often kept lean, particularly during training, so that they will hunt aggressively, and respond and return to their keeper. Captive falcons are probably not representative of free-living wild birds and may be more susceptible to poxvirus infection. The only reported cases we can find of pox in wild raptors were by Tantawi et al. (1981, op. cit.) for a European sparrow hawk (*Accipiter nisus*), by Pearson et al. (1975, op. cit.) for a rough-legged hawk (*Buteo lagopus*), by Moffatt (1972, op. cit.) for a golden eagle (*Aquila chrysaetos*) and by Schmeling and Docherty (1982, op. cit.) for bald eagles (*Haliaeetus leucocephalus*). The golden and bald eagles and rough-legged hawk appear to be the only authenticated records of poxvirus infection in free-living raptors in North America. Halliwell (1972, op. cit.) observed pox lesions in a young captive red-tailed hawk from central Missouri. Our report of pox infection in a free-living

adult red-tailed hawk represents one of the few such cases reported in the United States. The potential for spread of the virus to other hawks may occur particularly during the nesting season when an infected adult could conceivably pass the virus to a mate and nestlings by direct contact or fomites.

The foot lesions in this bird were severe and probably partially attributable to secondary infection with *Staphylococcus aureus* and fungi. The lesions grossly resembled "scaly-leg" caused by mites of the genus *Knemidocoptes*, however, none was found in our examination of the red-tailed hawk. Foot lesions as severe as those we observed were noted also by Pearson et al. (1975, op. cit.) and undoubtedly can result

in a diminished ability to capture prey. The apparent systemic bacterial infection was also a major reason for debility in this case.

Little is known of the natural history of avian pox infection in birds of prey. In other birds it is generally considered mild and self-limiting; however, eye lesions resulting in impaired vision may lead to starvation (Karstad, 1971, *In Infectious and Parasitic Diseases of Wild Birds*, Davis et al. (eds.), The Iowa State Press, Ames, Iowa, pp. 34-41).

We appreciate the technical assistance of Kathy Lauhala for the electron microscopic efforts. This work was supported by Department of Energy under contract number DE-AC06 76RLO 1830.

Journal of Wildlife Diseases, 21(3), 1985, pp. 301-305

Mycotic Pneumonia and Meningoencephalitis due to *Aspergillus terreus* in a Neonatal Snow Leopard (*Panthera uncia*)

W. M. Peden¹ and J. L. Richard, National Animal Disease Center, Agricultural Research Service, United States Department of Agriculture, P.O. Box 70, Ames, Iowa 50010, USA; **D. W. Trampel**, Department of Veterinary Pathology, Iowa State University, Ames, Iowa 50011, USA; and **R. E. Brannian**, Kansas City Zoo, Swope Park, Kansas City, Missouri 64132, USA

On 14 May 1983, two female snow leopard (*Panthera uncia*) cubs were born in the Kansas City Zoological Gardens to a primiparous female. The female showed little interest in the cubs, one of which had a body temperature of 30 C, so they were removed for hand-rearing. On 15 May, one cub was less active, and did not nurse as well as its littermate. Parenteral antibiotics were started (Ampicillin—11 mg/kg BID, Kanamycin—5.5 mg/kg BID). By 16 May, the cub had lost 20 g, and although antibiotics were continued, the cub continued to deteriorate. Blood was noted

in the stool, and a bloody nasal discharge was seen on 17 May. The cub was more depressed on 18 May, and had increased difficulty in breathing, due to the bloody nasal discharge. A blood sample was obtained, and revealed a packed cell volume of 42, total protein of 5.4 g/dl, and a white blood count of 5,200. A differential of the white blood cells showed a prominent immature neutrophil component with both bands and progranulocytes present. Small radiodense lesions were visible in a radiograph of the lungs. On the afternoon of 18 May, the cub became cyanotic and was placed in an oxygen chamber. Samples of the stool, nasal discharge, and blood were taken for culture. Atropine (0.5 mg/kg)

¹ Received for publication 2 November 1984.

¹ To whom correspondence should be addressed.