

## **Isolation of Primate Calicivirus *Pan paniscus* Type 1 from a Douc Langur (*Pygathrix nemaeus* L.)**

Authors: Smith, Alvin W., Skilling, Douglas E., Anderson, Marilyn P., and Benirschke, Kurt

Source: Journal of Wildlife Diseases, 21(4) : 426-428

Published By: Wildlife Disease Association

URL: <https://doi.org/10.7589/0090-3558-21.4.426>

---

BioOne Complete ([complete.BioOne.org](https://complete.BioOne.org)) is a full-text database of 200 subscribed and open-access titles in the biological, ecological, and environmental sciences published by nonprofit societies, associations, museums, institutions, and presses.

Your use of this PDF, the BioOne Complete website, and all posted and associated content indicates your acceptance of BioOne's Terms of Use, available at [www.bioone.org/terms-of-use](https://www.bioone.org/terms-of-use).

Usage of BioOne Complete content is strictly limited to personal, educational, and non - commercial use. Commercial inquiries or rights and permissions requests should be directed to the individual publisher as copyright holder.

---

BioOne sees sustainable scholarly publishing as an inherently collaborative enterprise connecting authors, nonprofit publishers, academic institutions, research libraries, and research funders in the common goal of maximizing access to critical research.

# RESEARCH NOTES/CASE REPORTS

*Journal of Wildlife Diseases*, 21(4), 1985, pp. 426–428  
© Wildlife Disease Association 1985

## Isolation of Primate Calicivirus *Pan paniscus* Type 1 from a Douc Langur (*Pygathrix nemaeus* L.)

Alvin W. Smith,<sup>1</sup> Douglas E. Skilling,<sup>1</sup> Marilyn P. Anderson, and Kurt Benirschke, Research Department, Zoological Society of San Diego, San Diego, California 92112, USA

Caliciviruses have been associated with an array of disease manifestations that are being identified increasingly in a number of animal species (Smith, 1983, U.S.D.A. Foreign Animal Disease Report No. 11-3, pp. 8–16). Pigs, marine mammals, marine fishes, cats, dogs, cattle, mink, and primates (including human beings) are species from which caliciviruses have been recovered (Smith et al., 1983, J. Am. Vet. Med. Assoc. 183: 1223–1225; Cubitt and Barrett, 1984, J. Gen. Virol. 65: 1123–1126; Barlough et al., 1985, Avian/Exotic Pract., in press). All four caliciviruses isolated thus far from species of nonhuman primates (pygmy chimpanzee (*Pan paniscus*), silver leaf langur (*Presbytis cristata*), spider monkey (*Ateles fusciceps*), and lowland gorilla (*Gorilla gorilla*)—all residing at the primate facility of the San Diego Zoo) belong to a single novel serotype, tentatively designated as primate calicivirus *Pan paniscus* type 1 (PCV-Pan 1) (Smith et al., 1983, Science 221: 79–80; Smith et al., 1985, Am. J. Vet. Res., in press). Although this virus has been recovered from a vesicular lesion (pygmy chimpanzee) and from a case of chronic gingivitis (spider monkey), conclusive etiological links to these or to any other specific disease process(es) have not been demonstrated. This communication reports the first isolation

of PCV-Pan 1 from the douc langur (*Pygathrix nemaeus*), a very rare nonhuman primate species.

Weight-loss, vomiting, and episodes of hypoglycemia had been observed over a period of weeks in an orphaned 4-mo-old male douc langur housed at the Children's Zoo facility of the San Diego Zoo. Despite symptomatic treatment, the animal's condition deteriorated. At necropsy subcutaneous adipose tissue was absent. Hilar areas of all lung lobes were purplish-red and extremely consolidated; however, there was no evidence of foreign-body aspiration. The right ventricle of the heart was mildly dilated and a small amount of serous fluid was in the pericardial sac. Peripheral lymph nodes were generally edematous. Mesenteric nodes were mottled red. The leptomeninges were extremely edematous, with congested blood vessels. Microscopic examination of formalin-fixed, hematoxylin and eosin-stained tissue sections revealed purulent bronchopneumonia, hepatic hemosiderosis, and depletion of B cell-dependent regions of the spleen and lymph nodes. The skeleton showed an overall paucity of physal osteoid deposition, suggesting protein and/or ascorbic acid deficiency. Moderately large numbers of birefringent calculi, suggestive of oxalates, were identified in the kidneys. Interlobular edema and occasional acinar cell necrosis were noted in the pancreas. There were no significant lesions in the heart. The cerebrum had edema of the gray matter and subepen-

---

Received for publication 15 January 1985.

<sup>1</sup> Present address: College of Veterinary Medicine, Oregon State University, Corvallis, Oregon 97331, USA.

dyma, pyknotic nuclei in the neuronal layers, and a mild lymphocytic meningeal infiltrate. *Escherichia coli* was isolated from brain tissue by streaking standard blood agar and MacConkey agar plates.

Samples of lung, liver, kidney, thymus, heart, small intestine, and brain were collected for virus isolation attempts. Approximately 1 g of each tissue was ground in a Ten Broeck homogenizer with a few ml of cell culture medium (Eagle MEM), transferred to 4-ml glass vials, and centrifuged at 2,000 *g* for 10 min. Initial isolation attempts were made by adsorbing 0.2 ml of the supernatant fluids onto PK-15 (pig kidney, *Sus scrofa domestica*) and Vero cell monolayers in 16 × 125-mm roller tubes at 37 C for 60 min. The cells were rinsed, 1.5 ml of medium containing 2% fetal calf serum was added, and cultures were incubated at 37 C on a roller drum (0.33 rpm). Cultures were examined daily for cytopathic effect. Three blind passages were performed before samples were considered negative.

A cytopathic agent was isolated in both PK-15 and Vero cells on the second blind passage of brain material. The agent was subsequently plaque-purified and identified as a calicivirus on the basis of its physicochemical characteristics—ether stability, nucleic acid (RNA) determination by means of 5-fluoro-2-deoxyuridine, pH stability, heat lability, and divalent cation effects (Schaffer et al., 1980, Intervirology 14: 1–6; Smith et al., 1983, op. cit.)—and on its morphologic appearance by negative-contrast electron microscopy (Fig. 1). Typing antiserum to the agent was prepared in rabbits (Smith et al., 1981, Am. J. Vet. Res. 42: 693–694) for use in standard cross-neutralization tests with known calicivirus serotypes, reacting 20 antibody units of typing serum with 100 TCID<sub>50</sub> of test virus (Smith et al., 1976, J. Wildl. Dis. 12: 326–334). The viral isolate was identified as PCV-Pan 1 due to its inhibition in vitro only by its homologous antiserum

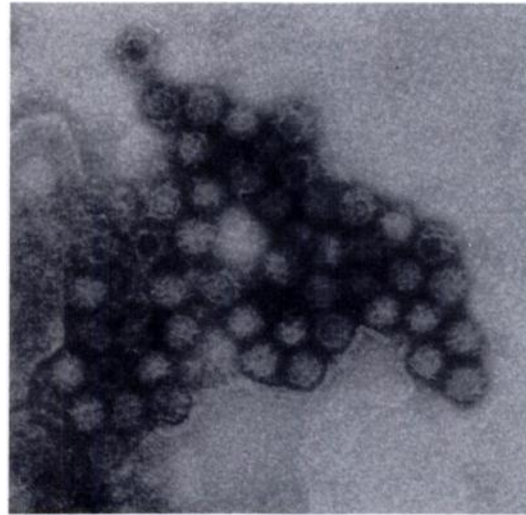


FIGURE 1. Immunoelectron photomicrograph of PCV-Pan 1 recovered from the brain of a douc langur (*Pygathrix nemaeus*), demonstrating the cup-shaped surface depressions characteristic of the caliciviruses. Phosphotungstic acid, ×114,000.

and by typing sera to previous PCV-Pan 1 isolates.

The precise cause of death in this young animal was not determined. None of the concurrent disease processes identified at necropsy was considered severe enough, on its own, to have produced a fatal outcome. The widespread depletion of B cell-dependent areas in the lymph nodes and spleen suggested immunosuppression—perhaps virus-induced, or perhaps resulting secondarily in an increased susceptibility to viral infection. Thus the exact relationship between PCV-Pan 1 and the disease processes in this animal, and the method of virus transmission, remain unknown. However, the lymphocytic cell infiltrates observed in the cerebral meninges did appear consistent with a viral (PCV-Pan 1?) etiology. Isolation of caliciviruses from the brain and/or calicivirus-associated encephalitis have been reported previously—in pigs infected with vesicular exanthema virus (Gelberg and Lewis, 1982, Vet. Pathol. 19: 424–443), in pinipeds and pigs infected with San Miguel

sea lion virus (Smith et al., 1980, Am. J. Vet. Res. 41: 1846–1850; Gelberg and Lewis, 1982, op. cit.), and in cats infected with feline calicivirus (Love and Baker, 1972, Aust. Vet. J. 48: 643). By contrast, we were unable to correlate the cerebral histopathology with the subsequent isolation of *E. coli*; possibly this represented postmortem contamination from another body site.

The douc langur is indigenous to the tropical rain forests of southeast Asia and is classified as an endangered species by both the International Union for Conservation of Nature and Natural Resources (I.U.C.N., 1972–1978, Red Data Book, Vol. I, Morges, Switzerland) and the United States Department of the Interior (Fed. Reg. 45: 33768–33781). It is impossible at present to assess the impact of caliciviruses (if they are present) on the douc langur in its natural habitat. It is apparent, however, that, as a group, the caliciviruses are

pathogens and can produce a variety of disease manifestations in a number of animal species (Smith, 1983, op. cit.). We have yet to demonstrate an etiological link between PCV-Pan 1 and a specific disease entity. However, the documented presence of this agent within an established primate collection, its recognized capacity for spreading and establishing infections in several different species of primates within this collection (Smith et al., 1983, op. cit.; Smith et al., 1985, op. cit.), and the widening recognition of the role of caliciviruses in diverse disease processes of animals (Smith, 1983, op. cit.; Barlough et al., 1985, op. cit.), together suggest to us an underlying potential for disease production by this virus.

This work was supported by the Zoological Society of San Diego, San Diego, California 92112, and by the College of Veterinary Medicine, Oregon State University, Corvallis, Oregon 97331.

*Journal of Wildlife Diseases*, 21(4), 1985, pp. 428–430  
© Wildlife Disease Association 1985

## Serologic Survey of Canine Coronavirus in Wild Coyotes in the Western United States, 1972–1982

**W. J. Foreyt**, Department of Veterinary Microbiology and Pathology, Washington State University, Pullman, Washington 99164, USA; and **J. F. Evermann**, Department of Veterinary Clinical Medicine and Surgery and Washington Animal Disease Diagnostic Laboratory, Washington State University, Pullman, Washington 99164, USA

Viral agents were first identified as causes of infectious canine enteritis in the early 1970's (Carmichael and Binn, 1981, Adv. Vet. Sci. Comp. Med. 25: 1–37). In 1979 canine parvovirus-2 (CPV-2) and canine coronavirus (CCV) were reported in captive juvenile coyotes (*Canis latrans*) with severe diarrhea and high mortality (Evermann et al., 1980, J. Am. Vet. Med. Assoc. 177: 784–786). Although the clini-

cal significance of CCV could not be determined at that time, it was speculated that a concurrent infection with CPV-2 could result in a more severe case of enteritis (Evermann et al., 1980, op. cit.) in coyotes held in captivity. The multiple etiology of enteric infections in domestic dogs has been reported (Carmichael and Binn, 1981, op. cit.). The major route of CCV transmission is through fecal contamination. Therefore, crowding, unsanitary conditions and other environmental

Received for publication 20 July 1984.