



Psoroptes ovis (Acarina: Psoroptidae) in a Rocky Mountain Bighorn Sheep (*Ovis canadensis canadensis*) in Idaho

Authors: Foreyt, W. J., Coggins, Vic, and Parker, Tom

Source: Journal of Wildlife Diseases, 21(4) : 456-457

Published By: Wildlife Disease Association

URL: <https://doi.org/10.7589/0090-3558-21.4.456>

BioOne Complete (complete.BioOne.org) is a full-text database of 200 subscribed and open-access titles in the biological, ecological, and environmental sciences published by nonprofit societies, associations, museums, institutions, and presses.

Your use of this PDF, the BioOne Complete website, and all posted and associated content indicates your acceptance of BioOne's Terms of Use, available at www.bioone.org/terms-of-use.

Usage of BioOne Complete content is strictly limited to personal, educational, and non - commercial use. Commercial inquiries or rights and permissions requests should be directed to the individual publisher as copyright holder.

BioOne sees sustainable scholarly publishing as an inherently collaborative enterprise connecting authors, nonprofit publishers, academic institutions, research libraries, and research funders in the common goal of maximizing access to critical research.

***Psoroptes ovis* (Acarina: Psoroptidae) in a Rocky Mountain Bighorn Sheep (*Ovis canadensis canadensis*) in Idaho**

W. J. Foreyt, Department of Veterinary Microbiology and Pathology, Washington State University, Pullman, Washington 99164, USA; **Vic Coggins**, Oregon Department of Fish and Game, Enterprise, Oregon 97828, USA; and **Tom Parker**, Idaho Department of Fish and Game, Salmon, Idaho 83467, USA

On 28 December 1984, 27 Rocky Mountain bighorn sheep (*Ovis canadensis canadensis*) were trapped under a drop net along the Salmon River near the mouth of Cove Creek in Lemhi County, Idaho, and transported by truck to Wallowa County, Oregon, a distance of 300 km, and released. Crusty lesions were noted in the ears of two of the sheep and a scraping was made from the ear of one, a 3½-yr-old ewe. All sheep were treated with ivermectin (IVOMEC®, 22–23 dihydroavermectin B₁, Merck & Company, Rahway, New Jersey 07065, USA) at 0.2 mg/kg of body weight intramuscularly before release. Subsequently, 70–75 larvae, nymphs and adults of *Psoroptes ovis* were observed in direct smears of the crusty material (Fig. 1). Specific identification was based on length on the outer opisthosomal setae ($n = 22$, mean length = 161 μm , range = 114–284 μm) from 13 adult male mites (Wright et al., 1984, J. Parasitol. 70: 141–143). Although the lengths of the setae are variable and may prove inadequate for accurate identification to species, it is the most reliable characteristic employed until alternate methods are found. Lengths provided here are in the *P. ovis* range (F. C. Wright, pers. comm.).

To our knowledge, scabies (*P. ovis*) has not been reported from bighorn sheep in Idaho since 1970 (Morgan, 1970, P-R Report W-142-R-1, pp. 24–27) and has not been reported from bighorns in Oregon or Washington during the last 50 yr. This

finding illustrates the importance of routine health examination of wild animals before their release into new areas. This infested sheep was released into an area near the Oregon-Washington border that contains local populations of *O. c. canadensis* and *O. c. californiana*.

Although the specific requirements for transmission of *P. ovis* among bighorns have not been investigated, it is likely that direct contact is the usual route. Because

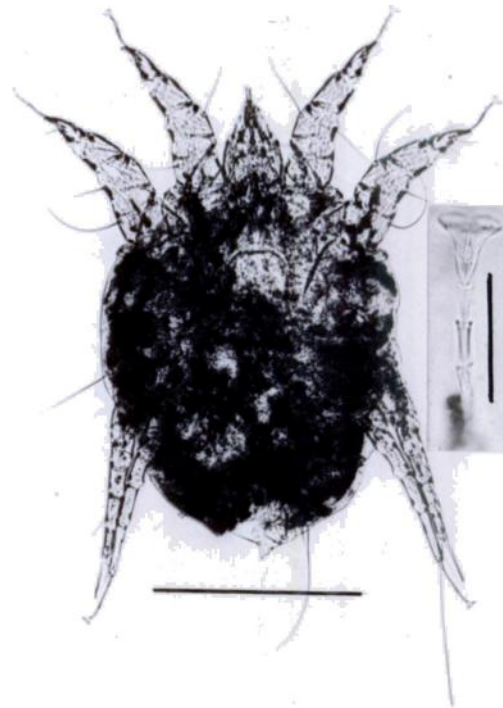


FIGURE 1. Adult male *Psoroptes ovis* from *Ovis c. canadensis*. Horizontal bar = 250 μm . Insert is enlarged pedicle on front leg illustrating characteristic joints. Vertical bar = 40 μm .

Received for publication 8 February 1985.

the ewe was treated, the infestation may have been eliminated; ivermectin has been reported to be effective against *P. ovis* in cattle at this dosage (Guillot and Meleney, 1982, Vet. Parasitol. 10: 73–78; Wright and Guillot, 1984, Am. J. Vet. Res. 45: 2132–2134). Ivermectin at a dosage of 0.5 and 1.0 mg/kg of body weight has been shown to be an effective drug for the treatment of *P. ovis* infestations in desert bighorn sheep (*O. c. mexicana*) in New Mexico (Kinzer et al., 1983, J. Wildl. Dis. 19: 52–54). However, mites may survive on the host for approximately 7–9 days after treatment and are capable of infesting new hosts during this time (Wright and Guillot, 1984, Am. J. Vet. Res. 45: 228–229). Hence, it is possible that mites could infest other bighorn sheep in the area. Fortunately, it is unlikely that *P. ovis* from bighorn sheep will infest cattle or domestic sheep under normal conditions (Wright et al., 1981, J. Wildl. Dis. 17: 381–386), so

danger of transmission to livestock is remote.

This diagnosed case of *P. ovis* in *O. c. canadensis* should alert wildlife workers and veterinarians in the Pacific Northwest to be aware of the potential hazard of this disease in bighorn sheep. Recent case histories in *O. c. mexicana* in New Mexico have documented the devastating effects of the disease, which may have been responsible for a significant decline in that population of bighorn sheep (Lange et al., 1980, J. Wildl. Dis. 16: 17–82).

Representative specimens of the mites were verified as *P. ovis* by F. C. Wright, Scabies and Mange Research Unit, U.S. Livestock Insects Laboratory, Agricultural Research, Science and Education Administration, U.S. Department of Agriculture, Kerrville, Texas, and deposited in the Acarology Laboratory, the Ohio State University, Columbus, Ohio (Accession No. AL-3048).

Journal of Wildlife Diseases, 21(4), 1985, pp. 457–458
© Wildlife Disease Association 1985

Harpyrhynchid Mites in a Scaly-breasted Lorikeet, *Trichoglossus chlorolepidotus* (Kühl)

L. J. Filippich, Department of Veterinary Medicine, University of Queensland, St. Lucia, Queensland 4067, Australia; and **R. Domrow**, Queensland Institute of Medical Research, Herston, Queensland 4006, Australia

Numerous large (0.5–1.5 cm) white lumps were noted to cause ruffling of the feathers on the wings and body proper of a mature scaly-breasted lorikeet captured at Maryborough in southeastern Queensland (25.32S, 152.36E). The bird was otherwise bright and in good bodily condition. The lumps were confined to the skin and on cross section consisted of an amor-

phous white material interspersed with remnants of feather shafts. Samples were fixed in 10% buffered neutral formalin, embedded in paraffin, sectioned and then stained with hematoxylin and eosin for histopathological examination.

Microscopic examination revealed the lumps to be a papillomatous reaction to mites contained in multiple spaces lined by epidermis (Fig. 1). The epidermis was in most areas acanthotic and showed orthokeratotic hyperkeratosis. Each cyst

Received for publication 15 October 1984.