

## **Harpyrhynchid Mites in a Scaly-breasted Lorikeet, *Trichoglossus chlorolepidotus* (Kühl)**

Authors: Filippich, L. J., and Domrow, R.

Source: Journal of Wildlife Diseases, 21(4) : 457-458

Published By: Wildlife Disease Association

URL: <https://doi.org/10.7589/0090-3558-21.4.457>

---

BioOne Complete ([complete.BioOne.org](https://complete.BioOne.org)) is a full-text database of 200 subscribed and open-access titles in the biological, ecological, and environmental sciences published by nonprofit societies, associations, museums, institutions, and presses.

Your use of this PDF, the BioOne Complete website, and all posted and associated content indicates your acceptance of BioOne's Terms of Use, available at [www.bioone.org/terms-of-use](https://www.bioone.org/terms-of-use).

Usage of BioOne Complete content is strictly limited to personal, educational, and non - commercial use. Commercial inquiries or rights and permissions requests should be directed to the individual publisher as copyright holder.

---

BioOne sees sustainable scholarly publishing as an inherently collaborative enterprise connecting authors, nonprofit publishers, academic institutions, research libraries, and research funders in the common goal of maximizing access to critical research.

the ewe was treated, the infestation may have been eliminated; ivermectin has been reported to be effective against *P. ovis* in cattle at this dosage (Guillot and Meleney, 1982, Vet. Parasitol. 10: 73–78; Wright and Guillot, 1984, Am. J. Vet. Res. 45: 2132–2134). Ivermectin at a dosage of 0.5 and 1.0 mg/kg of body weight has been shown to be an effective drug for the treatment of *P. ovis* infestations in desert bighorn sheep (*O. c. mexicana*) in New Mexico (Kinzer et al., 1983, J. Wildl. Dis. 19: 52–54). However, mites may survive on the host for approximately 7–9 days after treatment and are capable of infesting new hosts during this time (Wright and Guillot, 1984, Am. J. Vet. Res. 45: 228–229). Hence, it is possible that mites could infest other bighorn sheep in the area. Fortunately, it is unlikely that *P. ovis* from bighorn sheep will infest cattle or domestic sheep under normal conditions (Wright et al., 1981, J. Wildl. Dis. 17: 381–386), so

danger of transmission to livestock is remote.

This diagnosed case of *P. ovis* in *O. c. canadensis* should alert wildlife workers and veterinarians in the Pacific Northwest to be aware of the potential hazard of this disease in bighorn sheep. Recent case histories in *O. c. mexicana* in New Mexico have documented the devastating effects of the disease, which may have been responsible for a significant decline in that population of bighorn sheep (Lange et al., 1980, J. Wildl. Dis. 16: 17–82).

Representative specimens of the mites were verified as *P. ovis* by F. C. Wright, Scabies and Mange Research Unit, U.S. Livestock Insects Laboratory, Agricultural Research, Science and Education Administration, U.S. Department of Agriculture, Kerrville, Texas, and deposited in the Acarology Laboratory, the Ohio State University, Columbus, Ohio (Accession No. AL-3048).

*Journal of Wildlife Diseases*, 21(4), 1985, pp. 457–458  
© Wildlife Disease Association 1985

### **Harpyrhynchid Mites in a Scaly-breasted Lorikeet, *Trichoglossus chlorolepidotus* (Kühl)**

**L. J. Filippich**, Department of Veterinary Medicine, University of Queensland, St. Lucia, Queensland 4067, Australia; and **R. Domrow**, Queensland Institute of Medical Research, Herston, Queensland 4006, Australia

Numerous large (0.5–1.5 cm) white lumps were noted to cause ruffling of the feathers on the wings and body proper of a mature scaly-breasted lorikeet captured at Maryborough in southeastern Queensland (25.32S, 152.36E). The bird was otherwise bright and in good bodily condition. The lumps were confined to the skin and on cross section consisted of an amor-

phous white material interspersed with remnants of feather shafts. Samples were fixed in 10% buffered neutral formalin, embedded in paraffin, sectioned and then stained with hematoxylin and eosin for histopathological examination.

Microscopic examination revealed the lumps to be a papillomatous reaction to mites contained in multiple spaces lined by epidermis (Fig. 1). The epidermis was in most areas acanthotic and showed orthokeratotic hyperkeratosis. Each cyst

---

Received for publication 15 October 1984.

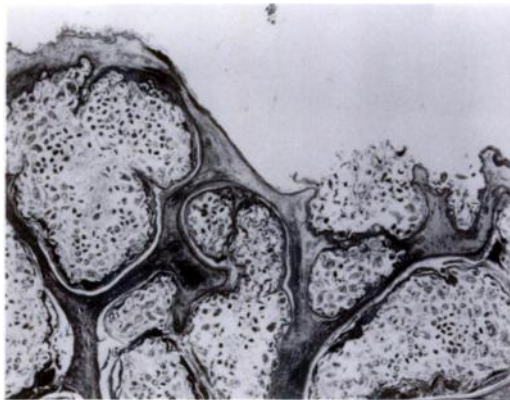


FIGURE 1. Skin lesion from a scaly-breasted lorikeet. Note cysts lined with epithelium and containing numerous harpyrhynchid mites. H&E,  $\times 10$ .

contained large numbers of mites including adults, immatures and eggs as well as parasitic and amorphous debris. Dense accumulations of bacteria, indicative of secondary infection, were present in some cysts, close to the outer margin of the lesion. The reaction to the mite was confined to the epidermis, although plasma cell and histiocyte infiltration in the dermis was present in some areas close to the epidermal layer (Fig. 2).

The mites in the cysts belong to the Harpyrhynchidae. This family is restricted to birds, and the endoparasitic habit of some species is well known (Fritsch, 1954, Zool. Anz. 152: 177–198; Ward et al., 1965, Ibis 107: 543–544). Though no key, or even full description for some species, is yet available, our specimens have been compared closely with the type-series of *Harpyrhynchus rosellacinus* (Lawrence, 1959, Proc. Linn. Soc. N.S.W. 84: 238–241), and are identified as that species. Voucher specimens have been deposited in the

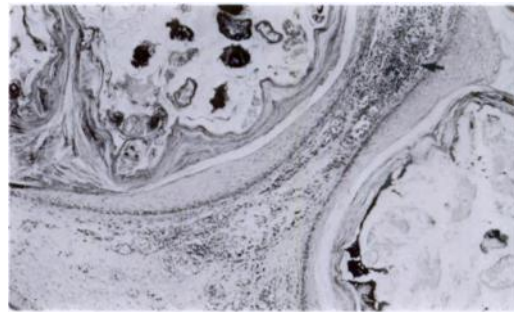


FIGURE 2. Epidermis from a scaly-breasted lorikeet showing acanthotic, orthokeratotic hyperkeratosis and harpyrhynchid mites. Note plasma and histiocyte cell infiltration in dermis (arrow). H&E,  $\times 50$ .

South Australian Museum, Adelaide (N198522). The species was originally described from a “cyst in the skin” of the eastern rosella, *Platycercus eximius* (Shaw), at Sydney, New South Wales, but has not been recorded since.

Specimens from a musk lorikeet, *Glosopsitta concinna* (Shaw) caught at Lobethal, South Australia (34.54S, 138.52E) in 1977 are held in the South Australian Museum (N198523). These are labelled as found in a “large fibroma-like tumour with alveoli packed with mites,” and likewise have been identified as *H. rosellacinus*.

We thank D. Seton, Queensland National Parks and Wildlife Service for providing the material, D. C. Lee, South Australian Museum and M. H. Naudo, Museum National d'Histoire Naturelle, Paris for the loan of specimens, including the type slide of *H. rosellacinus*, P. Fabbri, Department of Veterinary Pathology and Public Health, University of Queensland for the photographic work, and the Australian Research Grants Scheme for financial support.