

**Histopathology of Infections by *Learedius learedi* Price, 1934 and *Neospororchis schistosomatoides* Price, 1934 (Digenea: Spirorchidae) in Wild Green Turtles, *Chelonia mydas* L, from Bermuda**

Authors: Rand, Thomas G., and Wiles, Michael

Source: Journal of Wildlife Diseases, 21(4) : 461-463

Published By: Wildlife Disease Association

URL: <https://doi.org/10.7589/0090-3558-21.4.461>

---

BioOne Complete ([complete.BioOne.org](https://complete.BioOne.org)) is a full-text database of 200 subscribed and open-access titles in the biological, ecological, and environmental sciences published by nonprofit societies, associations, museums, institutions, and presses.

Your use of this PDF, the BioOne Complete website, and all posted and associated content indicates your acceptance of BioOne's Terms of Use, available at [www.bioone.org/terms-of-use](https://www.bioone.org/terms-of-use).

Usage of BioOne Complete content is strictly limited to personal, educational, and non - commercial use. Commercial inquiries or rights and permissions requests should be directed to the individual publisher as copyright holder.

---

BioOne sees sustainable scholarly publishing as an inherently collaborative enterprise connecting authors, nonprofit publishers, academic institutions, research libraries, and research funders in the common goal of maximizing access to critical research.

These infections result in a loss of tissue in the nephridial tubule. Each organ may harbor up to 10 worms, which have the

effect of transforming it into a "hollow shell."

*Journal of Wildlife Diseases*, 21(4), 1985, pp. 461–463  
© Wildlife Disease Association 1985

### **Histopathology of Infections by *Learedius learedi* Price, 1934 and *Neospiorchis schistosomatoides* Price, 1934 (Digenea: Spirorchiidae) in Wild Green Turtles, *Chelonia mydas* L., from Bermuda**

**Thomas G. Rand**, Bermuda Aquarium, Museum and Zoo, P.O. Box 145, Flatts, Smith's 3, Bermuda; and **Michael Wiles**, Saint Mary's University, Halifax, Nova Scotia B3H 3C3, Canada

Green turtles are known to harbor 10 species of spirorchid digeneans which parasitize the circulatory system (see review by Smith, 1972, *Helminthol. Abstr. Ser. A41*: 161–204). In this group from turtles, adults of three genera are known to release encapsulated embryos (eggs), which were first detected in 1861 (Smith, 1972, *op. cit.*) and which penetrate host tissues and elicit a focal inflammatory host response (Glazebrook et al., 1981, *J. Comp. Pathol.* 91: 361–368).

Although eggs of trematodes have been reported often in tissues of green turtles since 1861, there is apparently only one description of lesions associated with their presence in wild hosts, that of Glazebrook et al. (1981, *op. cit.*). Most reports are from either green turtles in aquaria (Smith and Coates, 1938, *Zoologica* 23: 93–98; Smith and Coates, 1939, *Zoologica* 24: 379–382) or mariculture facilities (Greiner et al., 1980, *Proc. Helminthol. Soc. Wash.* 47: 142–144).

Our study gives details of infections with the spirorchids *Learedius learedi*, and *Neospiorchis schistosomatoides* in wild

green turtles from Bermuda and describes the histopathology of lesions caused by eggs of these parasites.

Between September and November 1981, five moribund green turtles were recovered from inshore Bermuda waters after storms. All were listless, weak and gulping vigorously. Copious viscous fluid was discharging from both mouth and nares. Respiration was rapid, but shallow. Both eyes were sunken into their sockets. Subcutaneous neck tissues were fluid-filled. We kept the turtles in aquaria for 24 hr after their capture, but as their health deteriorated they were killed and necropsied. Five other recently dead green turtles, collected from September to November 1980 and then frozen, and one killed by a boat and collected in a putrefied condition in January 1983, were also examined. Mean carapace length and breadth for all the turtles was  $43.2 \pm 18$  cm by  $41.0 \pm 17$  cm, respectively.

The fatty layer underlying the plastron of the five turtles collected in 1981 was clear and jelly-like, a sign characteristic of mucoid degeneration (Wolke et al., 1982, *J. Wildl. Dis.* 18: 175–185). The lungs of two of these turtles had petechiae on the serosal surface and exuded a frothy fluid.

---

Received for publication 19 September 1983.

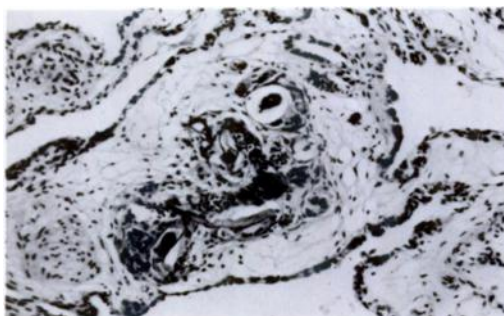


FIGURE 1. Small interstitial lung granuloma consisting of eggs of *Learedius learedi*, Langhan's giant cells and lymphocytes. H&E.  $\times 50$ .

Squashes of brain, liver, kidney and spleen were prepared from all turtles and examined microscopically for the presence of spirorchid eggs. Small pieces of infected organs, including the intestine from the moribund turtles collected in 1981, were fixed in 10% formol-saline, dehydrated in a graded ethanol series, cleared in xylene, embedded in paraffin wax and sectioned at 7  $\mu$ m. Sections of each organ were stained with Mayer's hematoxylin and alcoholic eosin, and the Prussian blue reaction for hemosiderin (Humason, 1972, Animal Tissue Techniques, Freeman, San Francisco, California, pp. 260–271).

Three to 53 adults (mean no. per infected host was 21.5) of *L. learedi* were recovered from all three heart chambers of six of 11 turtles examined. The turtle infected with 53 worms had a single concentration of these in one chamber. One to 23 *Neospiroorchis schistosomatoides* adults were present also in hearts of two turtles; the latter infection consisted of a clump of worms in the heart. Adults of both species were recovered in only one turtle. Eggs of *L. learedi*, which are thin-walled, spindle-shaped (167–213  $\mu$ m wide) and golden-yellow, were found in all squashes and sections prepared. In contrast, eggs of *N. schistosomatoides*, which are thick-walled, ovoid (37–59  $\mu$ m long by 26–41  $\mu$ m wide), golden-brown and lack-

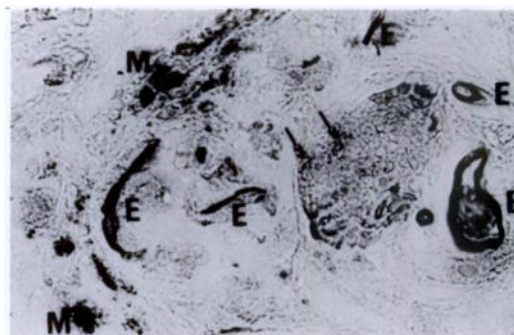

FIGURE 2. Intracellular hemosiderin granules (arrows) within a lesion of the lung. Visible are fragments of egg capsules (E) and pigment-bearing melanomacrophages (M). Perles' Prussian Blue stain for hemosiderin against an unstained background.  $\times 200$ .

ing terminal processes, were seen in tissues of only six of the 11 turtles. In sections, eggs of both species were usually indistinguishable because most were collapsed or shattered. Nevertheless, some could be distinguished and in all such instances eggs of both evoked a similar granulomatous host reaction with multiple foci in all tissues examined. Most lesions consisted of one to 20 eggs surrounded by large numbers of epithelioid cells, Langhan's giant cells and fibrous connective tissue (Fig. 1). Occasionally, the granulomas contained a central zone of necrosis bordered by accumulations of melanomacrophages, lymphocytes and eosinophilic granulocytes. Small granulomas, consisting of one to three eggs and situated close to blood capillaries, and egg clumps in the capillaries of spleen and lung, were often surrounded by lymphocytes.

Holliman et al. (1971, op. cit.) showed experimentally that eggs of *Spiroorchis parva* (Stunkard, 1923) had a debilitating effect on freshwater painted turtles when penetrating their tissues. Glazebrook et al. (1981, op. cit.) and Wolke et al. (1982, op. cit.) provided histopathological evidence that spirorchid eggs probably caused a similar response in heavily infected wild marine turtles. Our results confirm these

earlier findings. Presence of small intracellular accumulations of hemosiderin in hepatocytes of infected liver, in red pulp cells of spleen and in alveolar epithelial cells of lungs may indicate that chronic vascular congestion leading to minute hemorrhages is the host response to eggs of *L. learedi* and *N. schistosomatoides*. Furthermore, Wolke et al. (1982, op. cit.), who also found hemosiderin in kidney, liver and spleen of heavily infected loggerhead turtles, *Caretta caretta* (L.), suggested that hemolytic anemia may be a significant factor in spirorchid infections, but we did not investigate this aspect.

Clinical signs of the disease that we observed resembled those described for other species of turtles by various workers, namely Glazebrook et al. (1981, op. cit.) in green turtles, Holliman et al. (1971, J. Parasitol. 57: 71–77) in painted turtles, *Chrysemys picta picta* (Herm.), and Wolke et al. (1982, op. cit.) in loggerhead turtles infected with spirorchids in each case.

In one turtle there were intense, multifocal lymphocytic infiltrations among red pulp cells of spleen, hepatocytes and lung epithelial cells. In two others, small intracellular accumulations of hemosiderin were present throughout the liver in hepatocytes and spleen in red pulp cells, but

were confined within granulomas in the lungs (Fig. 2), which also exhibited a marked interstitial pulmonary edema. Edema also occurred in subcutaneous tissues. This condition may be a sign of cachexia resulting from vascular damage and from increased blood pressure caused by obstruction of blood capillaries by eggs. It may have been compounded by the clumps composed of many spirorchid adults that we saw in all heart chambers and in a major arteriole serving the lungs. The structural changes and physiological impairment caused by the spirorchid infections may make the turtles more susceptible to predators and to bacterial and mycotic pathogens, and less able to cope with inclement weather. In these ways mortality in populations of wild turtles may be increased.

Representative specimens of *L. learedi* and *N. schistosomatoides* have been deposited in the U.S. National Parasite Collection, Beltsville, Maryland 20705, USA (USNM Nos. 77970 and 77971).

We are indebted to Dr. David Cone who provided research facilities, helpful advice and generous hospitality at Saint Mary's University, Halifax, Nova Scotia, Canada during the preparation of this manuscript.

*Journal of Wildlife Diseases*, 21(4), 1985, pp. 463–466  
© Wildlife Disease Association 1985

## Cleft Palate in a Tule Elk Calf

**Peter J. P. Gogan**, Department of Forestry and Resource Management, University of California, Berkeley, California 94720, USA; and **David A. Jessup**, Wildlife Investigations Laboratory, California Department of Fish and Game, 1701 Nimbus Rd., Suite D, Rancho Cordova, California 95670, USA

Causes of mortality of fetuses or neonates of free-ranging cervids are frequently difficult to determine because of

the secretive nature of females near parturition and the rapid disappearance of carcasses of young in the wild. We report here a previously unrecorded congenital deformity, a case of cleft palate in a premature stillborn tule elk (*Cervus elaphus*

---

Received for publication 28 January 1985.