

An Unusual Clinical and Pathological Variant of Malignant Catarrhal Fever in a White-tailed Deer

Authors: Shulaw, William P., and Oglesbee, Michael

Source: Journal of Wildlife Diseases, 25(1) : 112-117

Published By: Wildlife Disease Association

URL: <https://doi.org/10.7589/0090-3558-25.1.112>

BioOne Complete (complete.BioOne.org) is a full-text database of 200 subscribed and open-access titles in the biological, ecological, and environmental sciences published by nonprofit societies, associations, museums, institutions, and presses.

Your use of this PDF, the BioOne Complete website, and all posted and associated content indicates your acceptance of BioOne's Terms of Use, available at www.bioone.org/terms-of-use.

Usage of BioOne Complete content is strictly limited to personal, educational, and non - commercial use. Commercial inquiries or rights and permissions requests should be directed to the individual publisher as copyright holder.

BioOne sees sustainable scholarly publishing as an inherently collaborative enterprise connecting authors, nonprofit publishers, academic institutions, research libraries, and research funders in the common goal of maximizing access to critical research.

An Unusual Clinical and Pathological Variant of Malignant Catarrhal Fever in a White-tailed Deer

William P. Shulaw¹ and Michael Oglesbee² ¹ Departments of Veterinary Preventive Medicine and ² Veterinary Pathobiology, The Ohio State University, 1900 Coffey Road, Columbus, Ohio 43210, USA.

ABSTRACT: A captive male white-tailed deer (*Odocoileus virginianus*) developed an acute illness over a 3-day period characterized predominantly by neurological, ocular and respiratory signs which were accompanied by prominent gross lesions of multiple organ systems. Histologically, a proliferative vasculitis consisting primarily of lymphocytic-lymphoblastic cellular infiltration was found in ocular, oral, respiratory, cardiac and neural tissues. The extensive nature of these infiltrations resulted in grossly apparent nodular foci in the lung, lymphoid tissue and myocardium which were suggestive of a lymphoproliferative disorder. This is contrasted to the more necrotizing nature of the vasculitis observed in other reported cases of malignant catarrhal fever in white-tailed deer. Although virus isolation was not attempted, serologic findings of antibodies to malignant catarrhal fever virus detected by indirect immunofluorescence and virus neutralization supported a diagnosis of malignant catarrhal fever in this deer.

Key words: Malignant catarrhal fever, white-tailed deer, *Odocoileus virginianus*, herpesvirus, vasculitis, lymphocytic-lymphoblastic infiltration, case report.

Naturally occurring malignant catarrhal fever (MCF) in white-tailed deer (*Odocoileus virginianus*) has been described (Clark et al., 1970; Wyand et al., 1971; Wobeser et al., 1973) as have experimentally induced infections (Clark et al. 1972; Whitnack and Castro, 1981). Plowright (1981) has reviewed this disease in wild ungulates and discussed the discovery of the causative herpesvirus of the African form of MCF and the nature of the sheep-associated disease whose etiology is suspected to be a related herpesvirus. An etiologic agent has not been described for naturally occurring cases of MCF in white-tailed deer.

Clinically, MCF is characterized in multiple host species as a severe inflammatory process affecting predominantly the respiratory tract, eyes and buccal cavity; less

often, the remainder of the alimentary tract is affected (Plowright, 1981). The underlying histopathological change is a disseminated segmental vasculitis affecting medium and small arteries and veins. The vasculitis is manifest in arterioles as adventitial and medial mononuclear cellular accumulations often with infiltration of adjacent tissues. Fibrinoid necrosis of myocytes in the tunica media may be present and is considered by some to be pathognomonic for the disease. The clinical signs and pathologic changes are adequate for a diagnosis (Clark et al., 1970; Wyand et al., 1971; Wobeser et al., 1973). This report describes a case of MCF in a white-tailed deer exhibiting unique clinical signs and lesions.

A captive 4-yr-old male white-tailed deer developed anorexia and depression over a 3-day period in March 1985. This animal had been captive since birth and was housed in an individual indoor pen at a small nature park near Delphos (Ohio, USA). Other species housed in close proximity included aoudad (*Ammotragus lervia*), mouflon (*Ovis musimon*), fallow deer (*Dama dama*), bison (*Bison bison*), domestic sheep (*Ovis aries*), and domestic goats (*Capra hircus*) as well as other white-tailed deer. Other animals were not observed to be ill at this time. Physical examination revealed the animal in sternal recumbency and unwilling, but able, to rise. The head was held at a slight angle and close to the floor. The conjunctiva of both eyes was edematous and injected, and copious mucopurulent ocular discharge was present. The muzzle was cracked and eroded. A mucopurulent nasal discharge was observed and auscultation revealed increased broncho-vesicular sounds. Rectal temperature was 40.8 C. Improvement was

not evident after 48 hr of treatment with oral fluids and electrolytes (Norden Laboratories, Inc., 601 West Cornhusker, Lincoln, Nebraska 68521, USA), penicillin (Pfizer, Inc., New York, New York 10017, USA), gentamicin (Schering Corporation, Kenilworth, New Jersey 07033, USA), and phenylbutazone (Coopers Animal Health Inc., Kansas City, Missouri 64141, USA). The animal was referred to the Ohio State University College of Veterinary Medicine (Columbus, Ohio 43210, USA) for examination but died shortly after presentation and was necropsied. Blood was collected from the heart for subsequent serologic studies.

Gross lesions consisted of bilateral mucopurulent ocular discharge, conjunctival hyperemia, moderate diffuse corneal opacity, the presence of fibrin clots in the anterior chamber, multinodular thickening of the iris and moderate multifocal retinal hemorrhage. A moderate mucopurulent nasal exudate with erosions, ulceration and crust formation over the muzzle was present. There was moderate to marked widespread mucosal erosion and ulceration affecting the gingivae, tongue, and hard and soft palate, with palatine lesions being most pronounced. Significant gross lesions in the remainder of the alimentary tract were absent. Peripheral and visceral lymph nodes were moderately enlarged, with a multinodular expansion of the cortex which was homogenous and yellowish white on section. Corticomedullary architecture was retained in these nodes. The lung was diffusely reddish-brown, consolidated, with widespread 4 to 5 mm white firm nodules evident on pleural surfaces and present throughout the parenchyma. Cardiac lesions were most striking, consisting of marked widespread occurrence of subepicardial, subendocardial and transmural white firm nodules 2 to 6 mm in diameter (Fig. 1).

Histologically, the spectra of gross lesions were associated with a generalized segmental vasculitis of small and medium sized arteries and veins. Arteriolar vascu-

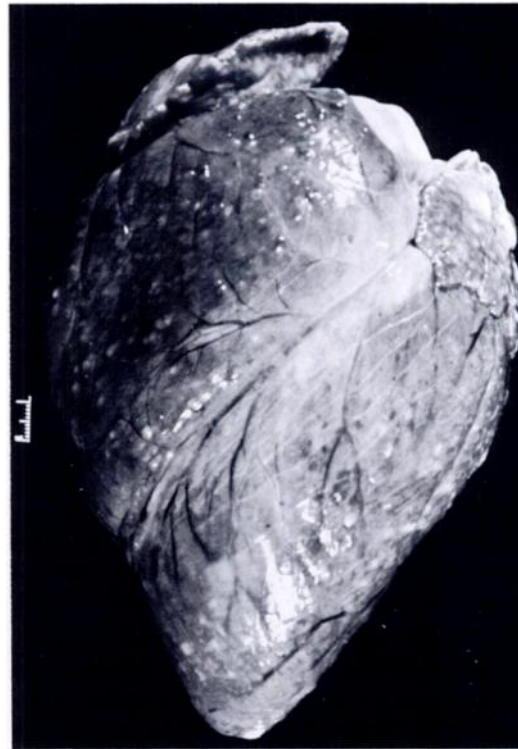


FIGURE 1. Gross appearance of the lymphocytic vasculitis in the heart of the white-tailed deer with malignant catarrhal fever (bar = 1 cm).

litis was characterized by a generally extensive accumulation of lymphocytic and lymphoblastic (LC-LB) cells in the tunica media and adventitia, and adjacent tissues with attendant myocytic vacuolar degeneration and endothelial hypertrophy (Fig. 2). Fibrinoid necrosis was rarely present and thrombosis was not observed.

There was marked diffuse cellular infiltration and arteritis of the uvea and uveal vessels, particularly affecting the ciliary body. This process extended into contiguous sclera, affecting associated extraocular musculature and the substantia propria of the cornea at the corneoscleral junction. The latter was accompanied by corneal edema, infiltration of the corneal epithelium associated with epithelial degeneration, and bulbar conjunctival epithelial hyperplasia.

Oral lesions consisted of widespread cellular infiltrates and vasculitis in the submucosa with superficial edema (Fig. 3).

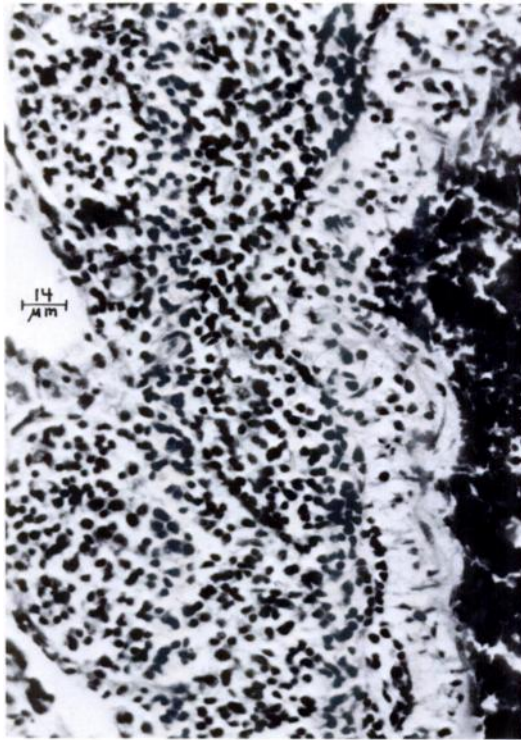


FIGURE 2. Tangential section of an affected pulmonary arteriole of a white-tailed deer with malignant catarrhal fever. The predominantly adventitial infiltration of a monomorphic lymphocytic cell population is demonstrated. Vacuolar degeneration of myocytes of the tunica media is pronounced.

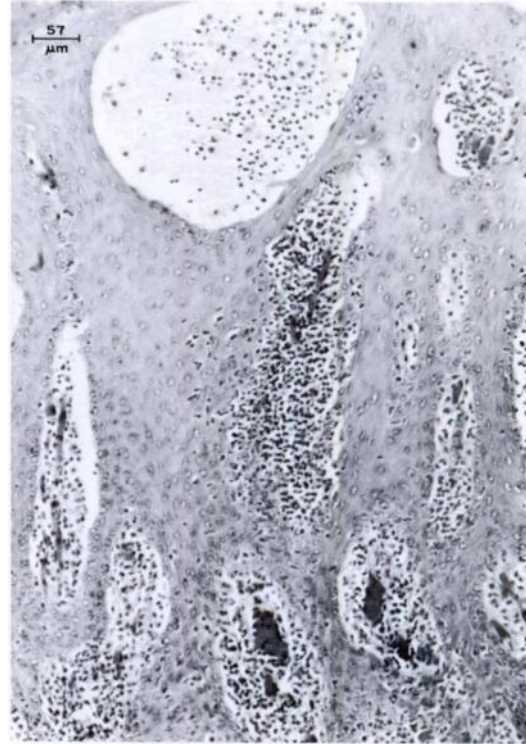

FIGURE 3. Perivascular infiltrates of the superficial lamina propria of the palatine mucosa of a white-tailed deer with malignant catarrhal fever. Lymphocytic infiltrates extend into the contiguous lamina epithelialis and are accompanied by epithelial degenerative changes and vesicle formation.

The inflammatory cell population contained smaller numbers of macrophages and occasional neutrophils in addition to the predominantly LC-LB populations. Infiltrates into deeper tissues and overlying epithelium, predominantly the stratum basale, were present. The latter was associated with widespread ballooning degeneration and necrosis, progressing to vesicle formation, of cells in the overlying stratum granulosum. Vesicles contained proteinaceous fluid, necrotic and degenerative cellular debris, and mixed inflammatory cell infiltrates. They were occasionally associated with full thickness epithelial necrosis and ulceration. Moderate widespread cellular infiltrates, edema, and vasculitis of the abomasal lamina propria mucosa, submucosa and subjacent tunica

muscularis were present. Involvement of the esophagus, rumen, reticulum, and intestine was not evident. Moderate widespread multifocal acute hepatocellular coagulation necrosis was present. Periductular infiltrates extending into adjacent parenchyma also were observed in the pancreas.

Marked expansion of the cortex, paracortex, and medullary cords with the LC-LB cell population resulted in effacement of germinal centers of lymph nodes. In addition, cellular accumulations within the subcapsular sinus, infiltration of the capsule, involvement of capsular vessels, and moderate sinusoidal reticuloendothelial hyperplasia were evident. Mild expansion of splenic nodules was present and, where such nodules were in apposition with the

splenic capsule, minimal lymphocytic capsular infiltrates were present.

Pulmonary vascular, pleural and peribronchiolar involvement was pronounced. Cellular accumulations also were present within the lamina propria of larger airways in association with multifocal ulceration of the overlying epithelium. The predominantly LC-LB cell population was accompanied by smaller numbers of macrophages and plasma cells. Secondary changes included diffuse pulmonary congestion and alveolar edema.

Cardiac vascular involvement was most pronounced. Cellular accumulations, containing small numbers of macrophages and plasma cells, tended to compress vascular lumina and extended for a short distance into adjacent myocardium. There was central degeneration and necrosis in some of the larger accumulations. Secondary changes included prominent multifocal myodegeneration and atrophy.

Gross lesions were not observed in the urinary and nervous systems. However, moderate, predominantly glomerular, renal cortical interstitial LC-LB infiltrates were observed histologically. Perivascular accumulations were present in sections of cerebral cortex, pons and medulla.

Serum samples were obtained on 2 January 1985, and at death on 4 March 1985. These were tested for MCF antibodies by indirect fluorescent antibody (IFA) at 1:20 and 1:100 dilutions and by virus neutralization (VN) (W. P. Heuschele, Research Department, Zoological Society of San Diego, San Diego, California 92112, USA). Weak fluorescence was seen in the 2 January 1985 sample at the 1:20 dilution. The VN test was positive at a 1:4 dilution on serum from 2 January 1985 and at a 1:3 dilution on serum from 4 March 1985.

Serum samples from both dates were tested by agar-gel immunodiffusion for bluetongue virus and bovine leukemia virus antibodies and found negative (Ohio Department of Agriculture, Diagnostic Laboratory, Reynoldsburg, Ohio 43068, USA). Tissue samples from nasal mucosa,

esophagus and liver were negative for bovine virus diarrhea antigen by direct immunofluorescence (Ohio Department of Agriculture, Diagnostic Laboratory).

The vasculitis observed in this case, which is typical of MCF in other species (Liggit and DeMartini, 1980), together with compatible lymphoid changes, multiple organ involvement and serologic data, supports a diagnosis of MCF. Virus isolation was not attempted in this case and "sheep associated MCF" was assumed, based on the history of exposure. It should be recognized that the IFA and VN tests were performed using the WC11 strain of MCF virus. Cross reactivity with other herpesviruses in IFA has been reported (Heuschele and Fletcher, 1984; Orsorio et al., 1985). However, IFA has been used to identify antibodies in healthy sheep suggesting that they possess an agent antigenically related to MCF virus (Rossiter, 1981). Virus neutralization is considered to be the most specific assay for MCF virus infection (Heuschele and Fletcher, 1984) although neutralizing antibodies may be absent or present in low titers in cattle that succumb to the disease (Plowright, 1981; Wan and Castro, 1986). Some investigators have considered a VN titer of 1:4 seropositive for alcelaphine herpesvirus-1 infection (Wan and Castro, 1986). Until the agent of sheep associated MCF is identified, the interpretation of serologic results will remain difficult.

Lymphosarcoma remains a possible diagnosis particularly due to the degree of the perivascular LC-LB cellular accumulation and infiltration of associated tissues. The relationship between MCF and lymphosarcoma is not clear when one considers the report of lymphosarcoma arising in association with the recrudescence of clinical MCF in a young Sika deer (African form) (Heuschele et al., 1985), together with the evolving concept of the MCF herpesvirus as having more biological characteristics in common with oncogenic rather than cytotoxic herpesviruses (Hunt and Billups, 1979).

Other differential diagnoses were considered. Negative results of tissue immunocytochemistry for BVD antigen (Ohio Department of Agriculture) did not support a diagnosis of mucosal disease. In addition, upper alimentary tract ulcerative lesions, which were present in this case, have not been observed with mucosal disease in white-tailed deer (Richards et al., 1956). Bluetongue, which must be considered as a differential diagnosis due to the vascular nature of the disease, was excluded as a diagnosis by negative serologic data and pathology. The changes produced by bluetongue center on the vascular endothelium with thrombosis; perivascular accumulations of inflammatory cells are not pronounced. Vesicular stomatitis is characterized by oral vesicles, although attending disseminated vascular changes are not present and recovery is usually rapid (Karstad and Hanson, 1957).

Clinically and pathologically, this case is unusual among other reported cases of MCF in white-tailed deer. The clinical disease was acute and characterized predominantly by neurological and respiratory signs accompanied by prominent gross lesions of multiple organ systems. This is contrasted to the consistently peracute disease previously reported in which a hemorrhagic enteritis accompanied by few gross lesions is described (Clark et al., 1970; Wyand et al., 1971; Wobeser et al., 1973; Whitnack and Castro, 1981).

Although the distribution of histologic lesions was similar to cases reported previously, significant differences were observed. Fibrinoid necrosis was previously determined to be a consistent and prominent component of the vascular lesions of MCF in white-tailed deer (Clark et al., 1970; Wyand et al., 1971; Wobeser et al., 1973). In this case, however, fibrinoid necrosis was seldom evident. Myocytic changes were predominantly degenerative and associated with adventitial and medial cellular infiltrates. Furthermore, the medial and adventitial accumulations of a LC-LB cell type was pronounced and consisted

of a more pure population of these cells. This is comparable to vascular changes attending experimentally induced and naturally occurring disease in calves (Liggit and Martini, 1980) and is contrasted to previously reported cases in white-tailed deer in which lesser accumulations of a more mixed inflammatory cell population is described. It is this difference, the more proliferative versus necrotizing nature of the vasculitis, which distinguishes the clinical and pathological differences between this and other reported cases of MCF in white-tailed deer. Whether this difference is due to host specific determinants of disease or differences in the balance of oncogenic versus cytotoxic properties of an infecting herpesvirus is unknown.

The authors wish to thank W. P. Heuschele for encouragement and laboratory support and the Ohio Department of Agriculture, Diagnostic Laboratory, for laboratory support.

LITERATURE CITED

- CLARK, K. A., R. M. ROBINSON, R. G. MARBURGER, L. P. JONES, AND J. H. ORCHARD. 1970. Malignant catarrhal fever in Texas cervids. *Journal of Wildlife Diseases* 6: 373-383.
- , ———, L. L. WEISHUHN, AND S. MCCONNELL. 1972. Further observations on malignant catarrhal fever in Texas deer. *Journal of Wildlife Diseases* 8: 72-74.
- HEUSCHELE, W. P., AND H. R. FLETCHER. 1984. Improved methods for the diagnosis of malignant catarrhal fever. *Proceedings of 27th Annual Meeting of American Association of Veterinary Laboratory Diagnosticians, American Association of Veterinary Laboratory Diagnosticians, Reynolds Printing Company, Brookings, South Dakota*, pp. 137-150.
- , N. O. NIELSEN, J. E. OOSTERHUIS, AND A. E. CASTRO. 1985. Dexamethasone-induced recrudescence of malignant catarrhal fever and associated lymphosarcoma and granulomatous disease in a Formosan sika deer (*Cervus nippon taiouanus*). *American Journal of Veterinary Research* 46: 1578-1583.
- HUNT, R. D., AND L. H. BILLUPS. 1979. Wildebeest-associated malignant catarrhal fever in Africa: A neoplastic disease of cattle caused by an oncogenic herpesvirus? *Comparative Immunology and Microbiology of Infectious Diseases* 2: 275-283.
- KARSTAD, L., AND R. P. HANSON. 1957. Vesicular

- stomatitis in deer. *American Journal of Veterinary Research* 18: 162-166.
- LIGGIT, H. C., AND J. C. DE MARTINI. 1980. The pathomorphology of malignant catarrhal fever: Generalized lymphoid vasculitis. *Veterinary Pathology* 17: 58-72.
- ORSORIO, F. A., D. E. REED, M. J. VAN DER MAATEN, AND C. A. METZ. 1985. Comparison of the herpesviruses of cattle by DNA restriction endonuclease analysis and serologic analysis. *American Journal of Veterinary Research* 46: 2104-2109.
- FLOWRIGHT, W. 1981. Herpesviruses in wild ungulates, including malignant catarrhal fever virus. In *Infectious diseases of wild mammals*, 2nd ed., J. W. Davis, L. H. Karstad, and D. O. Trainer (eds.). Iowa State University Press, Ames, Iowa, pp. 126-138.
- RICHARDS, S. H., I. A. SCHIPPER, D. F. EVELETH, AND R. F. SHUMARD. 1956. Mucosal disease of deer. *Veterinary Medicine* 51: 358-362.
- ROSSITER, P. B. 1981. Antibodies to malignant catarrhal fever virus in sheep sera. *Journal of Comparative Pathology* 91: 303-310.
- Wan, S., and A. E. Castro. 1986. Detection of antibody to alcelaphine herpesvirus-1 by ELISA in cattle with sheep associated malignant catarrhal fever. In *The bovine practitioner*, No. 21, E. I. Williams (ed.). American Association of Bovine Practitioners, Frontier Printers, Stillwater, Oklahoma, pp. 47-51.
- WHITNACK, D. L., AND A. E. CASTRO. 1981. Experimental malignant catarrhal fever (African form) in white-tailed deer. *Journal of Wildlife Diseases* 17: 443-451.
- WOBESER, G., J. A. MAJKA, AND J. H. L. MILLA. 1973. A disease resembling malignant catarrhal fever in captive white-tailed deer in Saskatchewan. *Canadian Veterinary Journal* 14: 106-109.
- WYAND, D. S., C. F. HELMBOLT, AND S. W. NIELSEN. 1971. Malignant catarrhal fever in white-tailed deer. *Journal of American Veterinary Medical Association* 159: 605-610.

Received for publication 7 April 1988.