

Multiple Feather Follicle Cysts in a Wild Turkey

Authors: Couvillion, C. E., Maslin, W. A., and Montgomery, R. M.

Source: Journal of Wildlife Diseases, 26(1) : 122-124

Published By: Wildlife Disease Association

URL: <https://doi.org/10.7589/0090-3558-26.1.122>

BioOne Complete (complete.BioOne.org) is a full-text database of 200 subscribed and open-access titles in the biological, ecological, and environmental sciences published by nonprofit societies, associations, museums, institutions, and presses.

Your use of this PDF, the BioOne Complete website, and all posted and associated content indicates your acceptance of BioOne's Terms of Use, available at www.bioone.org/terms-of-use.

Usage of BioOne Complete content is strictly limited to personal, educational, and non - commercial use. Commercial inquiries or rights and permissions requests should be directed to the individual publisher as copyright holder.

BioOne sees sustainable scholarly publishing as an inherently collaborative enterprise connecting authors, nonprofit publishers, academic institutions, research libraries, and research funders in the common goal of maximizing access to critical research.

Multiple Feather Follicle Cysts in a Wild Turkey

C. E. Couvillion, W. A. Maslin, and R. M. Montgomery, College of Veterinary Medicine, Mississippi State University, Mississippi State, Mississippi 39762, USA

ABSTRACT: A hunter-killed wild turkey (*Meleagris gallopavo silvestris*) was submitted for examination because of numerous 2 to 30 mm diameter, yellowish, hard nodules in the skin. The nodules were confined to the skin and did not involve subcutaneous tissues. Nodules consisted of dilated feather follicles packed with a caseous tan to pale yellow material. Histologically, affected feather follicles were markedly dilated and filled with laminated keratin debris. The lesions were determined to be multiple feather follicle cysts of unknown etiology.

Key words: Wild turkey, *Meleagris gallopavo silvestris*, multiple feather follicle cysts, pathology, anomaly, unknown etiology, case report.

A wild turkey (*Meleagris gallopavo silvestris*) hen that was killed by a hunter on a private club (Catfish Point Hunting Club, Bolivar County, Mississippi (33°50'N, 91°00'W) was submitted to the Diagnostic Laboratory at the College of Veterinary Medicine (Mississippi State University, Mississippi State, Mississippi 39762, USA) because of the presence of multiple skin lesions. The bird was in good physical condition as determined by adequate muscle masses and the presence of internal and external fat deposits. There were no gross internal lesions. Externally, there were numerous 2 to 30 mm diameter, yellowish, hard nodules (Fig. 1). The nodules were circular or irregularly shaped and involved the skin but not the subcutaneous tissues. Remnants of feather shafts protruded from the nodules. Some of the nodules were covered by excoriated necrotic skin and were filled with layers of tan to pale yellow caseous material. The nodules were distributed in the skin over most of the body except for the head, neck and legs. On the dorsum of the wings, nodules were distributed in a bilaterally symmetrical pattern and involved follicles of the primary feathers and the skin over both humeri. On the back, nodules were restricted to

the midline from the base of the neck to the uropygial gland. Ventrally, lesions were scattered randomly over the breast (Fig. 1) but were bilaterally symmetrical on the underside of the wings. The skin lesions did not have any apparent physical effect on the bird.

Sections of lesions and other tissues were preserved in neutral buffered formalin, processed by standard methods, and stained with hematoxylin and eosin. Scrapings of skin lesions were taken for examination for parasites. Attempts to isolate viruses were done by inoculating ground nodules into specific-pathogen-free embryonated chicken eggs via the chorioallantoic membrane or chorioallantoic sac routes or in chicken embryo kidney cells.

All sections of skin lesions that were examined microscopically had similar changes characterized by marked dilation of feather follicles that were filled with laminated keratin debris (Fig. 2). Sometimes the stroma surrounding affected feather follicles was thickened with granulation tissue that was infiltrated by heterophils, lymphocytes, plasma cells, and macrophages. Histologic sections of liver, spleen, kidney, lung, heart, ovary, intestine, pancreas and brain were not remarkable. Parasites were not seen in scrapings of skin lesions. Virus isolation attempts were negative. No attempts were made to isolate bacteria or fungi, but neither was associated with the affected feather follicles on histopathologic examination. Gross and microscopic lesions were consistent with a diagnosis of multiple feather follicle cysts.

Feather follicle cysts have been described primarily in pet birds such as canaries, parakeets, and macaws (Altman, 1969; Harrison et al., 1986; Choudary, 1986). According to Olszewski (1987), cysts develop when young growing feathers become curled over in their follicles so that

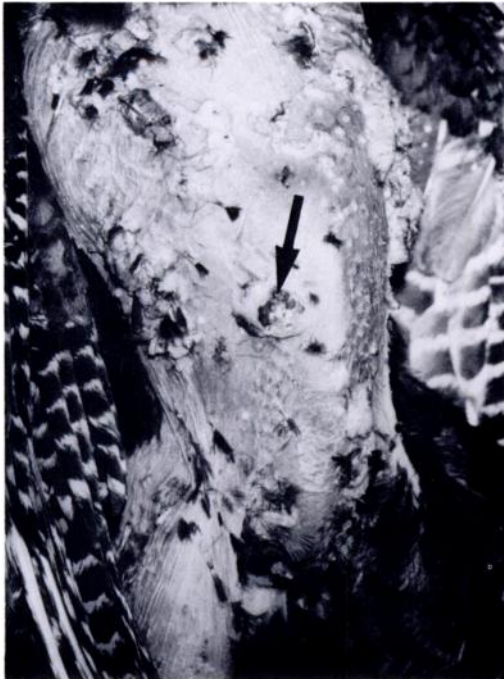

FIGURE 1. Multiple feather follicle cysts on breast of wild turkey.

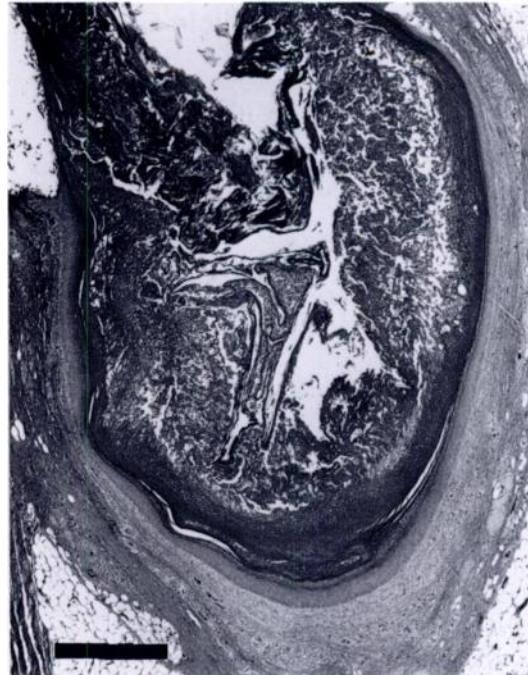


FIGURE 2. Lower portion of a feather follicle distended with keratin debris (H&E). Bar = 500 μ m.

the feather sheath fails to erupt. Affected follicles may coalesce and produce cysts containing abortive sheaths, keratin, and sebaceous gland secretions (Olszewski, 1987). The condition is thought to be hereditary in pet birds, especially canaries and canary hybrids (Altman, 1969; Harrison, 1986; Olszewski, 1987); however cysts from primary or secondary feathers on the wings may also be secondary to trauma (Harrison, 1986). Some cystic skin conditions of inbred canaries have been classified as neoplasms analogous to benign hair follicle tumors in dogs (Wheeldon and Culbertson, 1982). However, the cysts in this turkey probably were simple dilations of pre-existing feather follicles without differentiation toward complex epithelial structures. Feather follicle cysts previously have not been described from wild turkeys or related birds. Other cases of feather follicle cysts have not been reported from this area in spite of regular and intensive harvest of wild turkeys during the past 15 yr.

The authors thank the following agencies for cooperative support: Mississippi Department of Wildlife Conservation, National Wild Turkey Federation, National Rifle Association, Anderson Tully Corporation, Walker Wildlife Foundation, Izaak Walton League of American Endowment, United States Forest Service, Max McGraw Wildlife Foundation; and Mr. Fred Ziemman of Catfish Point Hunting Club.

LITERATURE CITED

- ALTMAN, R. B. 1969. Conditions involving the integumentary system. *In Diseases of cage and aviary birds*, M. L. Petrak (ed.). Lea and Febiger, Philadelphia, Pennsylvania, pp. 243–254.
- CHOUDARY, D. 1986. Neoplasms, cysts, and obstructive diseases. *In Companion bird medicine*, E. W. Burr (ed.). Iowa State University Press, Ames, Iowa, pp. 231–239.
- HARRISON, G. J. 1986. Disorders of the integument. *In Clinical avian medicine and surgery*, G. J. Harrison and L. R. Harrison (eds.). W. B. Saunders Co., Philadelphia, Pennsylvania, pp. 509–524.
- HARRISON, L. R., K. FLAMMER, AND G. J. HARRISON. 1986. Choosing a bird. *In Clinical avian medicine and surgery*, G. J. Harrison and L. R. Har-

- Oliver (ed.). W. B. Saunders Co., Philadelphia, Pennsylvania, pp. 3-11.
- OLSZEWSKI, A. B. 1987. Mutations and hereditary disorders. *In* Companion bird medicine, E. W. Burr (ed.). Iowa State University Press, Ames, Iowa, pp. 33-35.
- WHEELDON, E. B., AND M. R. CULBERTSON. 1982. Feather folliculoma in the canary (*Serinus canarius*). *Veterinary Pathology* 19: 204-206.

Received for publication 2 May 1989.