



## **Gill Sphaerosporosis in Goldfish (*Carassius auratus*)**

Authors: Hedrick, R. P., Groff, J. M., and McDowell, T. S.

Source: Journal of Wildlife Diseases, 26(4) : 558-560

Published By: Wildlife Disease Association

URL: <https://doi.org/10.7589/0090-3558-26.4.558>

---

BioOne Complete ([complete.BioOne.org](https://complete.BioOne.org)) is a full-text database of 200 subscribed and open-access titles in the biological, ecological, and environmental sciences published by nonprofit societies, associations, museums, institutions, and presses.

Your use of this PDF, the BioOne Complete website, and all posted and associated content indicates your acceptance of BioOne's Terms of Use, available at [www.bioone.org/terms-of-use](https://www.bioone.org/terms-of-use).

Usage of BioOne Complete content is strictly limited to personal, educational, and non - commercial use. Commercial inquiries or rights and permissions requests should be directed to the individual publisher as copyright holder.

---

BioOne sees sustainable scholarly publishing as an inherently collaborative enterprise connecting authors, nonprofit publishers, academic institutions, research libraries, and research funders in the common goal of maximizing access to critical research.

## Gill Sphaerosporosis in Goldfish (*Carassius auratus*)

R. P. Hedrick, J. M. Groff, and T. S. McDowell, Department of Medicine, School of Veterinary Medicine, University of California, Davis, California 95616, USA

**ABSTRACT:** Infections caused by a *Sphaerospora* sp. resembling *S. chinensis* are reported for the first time in goldfish (*Carassius auratus*) from North America. The myxosporean was found in the respiratory epithelium of the gill of pond-reared fish. Spores from stained tissue sections were spherical with an equal mean length and width of 6.3  $\mu\text{m}$ . Spore valves were thickened at the suture which lies in a plane perpendicular to two prominent pyriform polar capsules. The polar capsules were 4.0  $\times$  2.8  $\mu\text{m}$  in length and width. Both monosporous and disporous development within a surrounding "pseudoplasmodium" was detected. Infections caused moderate hyperplasia and occasional necrosis of the respiratory epithelial cells of the gill.

**Key words:** Goldfish, *Carassius auratus*, *Sphaerospora* sp., myxosporean infection, gill epithelial hyperplasia, case report.

Thirty seven species of *Sphaerospora* (Myxosporaea) have been described, most from the uriniferous tubules and bladder of fish (Arthur and Lom, 1985). Two species parasitize the gills of cyprinid fishes (Lom et al., 1983). *Sphaerospora carassius* was found from gills of the crucian carp (*Carassius carassius*) by Kudo (1919) but was later characterized as the cause of epizootic gill sphaerosporosis of common carp (*Cyprinus carpio*) in Hungary (Molnár, 1979, 1980). A second species, *S. branchialis*, was reported from common carp from the USSR (Lom et al., 1983) and China (Chen Chih, 1973). Lom et al. (1983) reclassified the gill sphaerospores and proposed two new species names, *S. molnári* which was formerly *S. carassii* and *S. chinensis* as a replacement for *S. branchialis*.

Abnormally high losses among 2 g goldfish (*Carassius auratus*) from a commercial farm were submitted to the laboratory in March of 1989. The fish were being reared in ¼ acre earthen ponds and the water temperature was 17 C. Affected fish had pale gills but were otherwise normal

in external appearance. Skin and gills scrapings showed numerous *Ichthyoboda necatrix*. Two fish were fixed in Davidson's solution (Humason, 1979) for later examination following standard techniques for paraffin embedding, sectioning and staining with hematoxylin and eosin.

Sections of the gills of two fish showed a moderate to severe hyperplasia of the gill epithelium with some fusion of secondary lamellae (Fig. 1). On closer study numerous developmental stages and sphaerospores in the gill epithelium were detected (Fig. 2). Prespore stages were characterized by a large diffuse cytoplasm or "pseudoplasmodium" with one to six internal cells. This enclosing cell has been referred to as a "pseudoplasmodium" because spore development occurring within this enveloping cell differs from that of most myxosporians in which sporogonic cells are surrounded by plasmodia distributed throughout a larger enclosing sack-like body or pansporoblast (Lom, 1987).

Spores were spherical with an equal mean length and width of 6.3  $\mu\text{m}$  ( $n = 10$ ), as measured from the sections. Spore valves were slightly thickened at the suture, particularly anteriorly. The suture lies in a plane perpendicular to two prominent pyriform polar capsules of 4.0  $\times$  2.8  $\mu\text{m}$  in length by width. One, occasionally two, spores developed within a surrounding pseudoplasmodium. Development and release of the spores caused spaces to be formed in the epithelium and several spores were found in the interlamellar spaces (Fig. 2). Multicellular aggregates found in the interstitium of the kidney had some similar features to blood stages of *Sphaerospora* spp. as described by Lom et al. (1985) for other cyprinid fishes (Fig. 3). Sporogonic stages of the myxosporean were not found in the lumina of the kidney tubules nor in

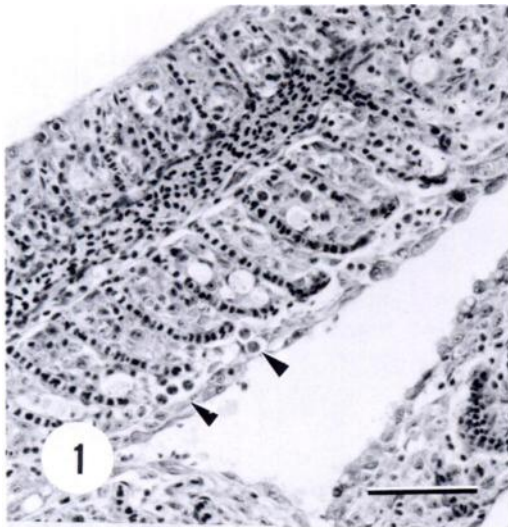


FIGURE 1. Hyperplasia of the gill epithelium of goldfish associated with the presence of sphaerospores (arrows). Bar = 100  $\mu$ m. H&E.

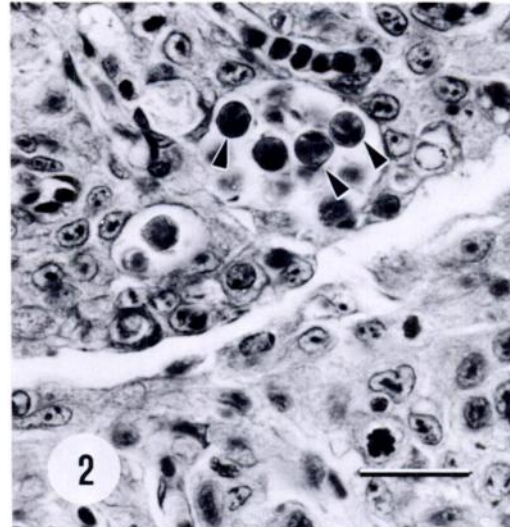


FIGURE 2. Sphaerospores (arrows) in the gill epithelium between adjacent secondary lamellae of goldfish. Bar = 10  $\mu$ m. H&E.

the blood as described for *S. molnári* infections (Lom et al., 1983).

Although renal sphaerospores have been detected among several fishes in the U.S.A. and Canada, including cyprinids in California (Hedrick et al., 1988), we could not find any reports of gill sphaerosporosis in North America. We have found renal sphaerospores in Calico goldfish (*C. auratus*) imported from Japan and among feeder goldfish from farm ponds (unpubl. data) and in neither case were they associated with disease. In contrast, the gill sphaerospores in our study were associated with pathological changes in the gills of the goldfish.

The myxosporean observed in our study resembles *S. chinensis* as found in the gills of common carp in USSR, eastern Europe and China (Lom et al., 1983). *Sphaerospora chinensis* spores are nearly spherical ( $7.4 \times 7.0 \mu$ m in length by width) and two pyriform polar capsules occupy up to two thirds of the length of the spore (Lom et al., 1983). Although the spores we found were smaller than those reported for *S. chinensis* this may have been due to shrinkage during fixation. The size and shape of the polar capsules clearly sepa-

rates *S. chinensis* in the goldfish sphaerospores from *S. molnári* which possesses two small spherical polar capsules (Lom et al., 1983; Desser et al., 1983). Further studies on fresh spores are needed to confirm our identification. Importations of ornamental cyprinids from eastern Asia are the probable origin of this myxosporean now

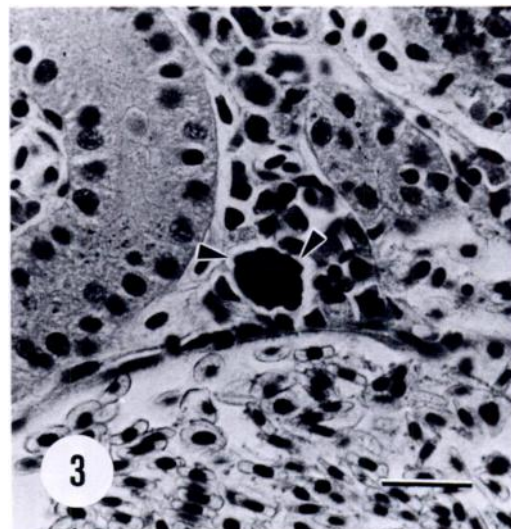


FIGURE 3. Multicellular forms (arrows) in the sinusoids of the kidney of goldfish with gill sphaerosporosis. Bar = 10  $\mu$ m. H&E stain.

present in populations of goldfish in California.

#### LITERATURE CITED

- ARTHUR, J. R., AND J. LOM. 1985. *Sphaerospora araii* n. sp. (Myxosporea: Sphaerosporidae) from the kidney of a longnose skate (*Raja rhina* Jordan and Gilbert) from the Pacific Ocean off Canada. Canadian Journal of Zoology 63: 2902-2906.
- CHEN CHIH, L. 1973. An illustrated guide to the fish diseases and causative pathogenic fauna and flora in the Hubei Province. Science Press, Peking, Peoples Republic of China, 456 pp.
- DESSER, S. S., K. MOLNÁR, AND I. HORVATH. 1983. An ultrastructural study of the myxosporeans, *Sphaerospora angulata* and *Sphaerospora carassii*, in common carp, *Cyprinus carpio* L. Journal of Protozoology 30: 415-422.
- HEDRICK, R. P., M. L. KENT, R. J. TOTH, AND J. K. MORRISON. 1988. Fish infected with *Sphaerospora* spp. Thélohan (Myxosporea) from waters enzootic for proliferative kidney disease of salmonids. Journal of Protozoology 35: 13-18.
- HUMASON, G. L. 1979. Animal tissue techniques. W. H. Freeman Co., San Francisco, California, 661 pp.
- KUDO, R. 1919. Studies on the Myxosporidia. Illinois Biological Monographs 5: 265.
- LOM, J. 1987. Myxosporea: A new look at long-known parasites of fish. Parasitology Today 3: 327-332.
- , I. DYKOVÁ, M. PAVLÁSKOVÁ, AND G. GRUPCHEVA. 1983. *Sphaerospora molnári* sp. nov. (Myxozoa: Myxosporea), an agent of gill, skin and blood sphaerosporosis of common carp in Europe. Parasitologica 86: 529-535.
- , M. PAVLÁSKOVÁ, AND I. DYKOVÁ. 1985. Notes on kidney-infecting species of genus *Sphaerospora* Thélohan (Myxosporea), including a new species *S. gobionis* sp. nov., and on myxosporean life cycle stages in the blood of some freshwater fish. Journal of Fish Diseases 8: 221-232.
- MOLNÁR, K. 1979. Gill sphaerosporosis in the common carp and grass carp. Acta Veterinaria Academiae Scientiarum Hungaricae 27: 99-113.
- . 1980. Cutaneous sphaerosporosis of the common carp fry. Acta Veterinaria Academiae Scientiarum Hungaricae 28: 371-374.

Received for publication 2 March 1990.