Chlamydial and Poxvirus Infections of Circulating Monocytes of a Flap-necked Chameleon (Chamaeleo dilepis)

Authors: Jacobson, Elliott R., and Telford, Sam. R.

Source: Journal of Wildlife Diseases, 26(4) : 572-577

Published By: Wildlife Disease Association

URL: https://doi.org/10.7589/0090-3558-26.4.572

Journal of Wildlife Diseases, 26(4), 1990, pp. 572–577

Chlamydial and Poxvirus Infections of Circulating Monocytes of a Flap-necked Chameleon (*Chamaeleo dilepis*)

Elliott R. Jacobson[1] **and Sam. R. Telford,**[2] [1] Department of Small Animal Clinical Sciences, College of Veterinary Medicine, Box J-126, Health Sciences Center, University of Florida, Gainesville, Florida 32610, USA; [2] Florida Museum of Natural History, University of Florida, Gainesville, Florida 32610, USA

ABSTRACT: Of blood films examined from 170 specimens of 15 *Chamaeleo* spp. in Tanzania, three *C. dilepis* had an intracytoplasmic inclusion within monocytes. One of the lizards was maintained in captivity and was sequentially bled over a 55 day period. At 46 days, a second type of inclusion was occasionally seen within monocytes. The lizard became ill and was euthanatized on day 55. All circulating monocytes were found to have either one or both types of inclusions. Histologic examination of multiple tissues demonstrated similar inclusions within macrophages in the spleen and liver. Transmission electron microscopic examination of monocytes revealed the presence of a chlamydia-like organism and pox-like virus. These pathogens have not been reported previously in chameleons, nor has a combined infection of circulating monocytes with these two pathogens been reported for any animal.

Key words: *Chlamydia* sp., poxvirus, infection, monocytes, chameleon, *Chamaeleo dilepis*, case reports.

Chlamydiae (Storz, 1971) and poxviruses (Andrewes et al., 1978) infect many birds and mammals. Although *Chlamydia pneumoniae* has only been isolated from humans (Grayston et al., 1989) and *Chlamydia trachomatis* is isolated only from humans and rodents (Moulder, 1984), *Chlamydia psittaci* has one of the largest host ranges of any pathogen. It is the causative agent of psittacosis of birds and man, and recently Newcomer et al. (1982) found that it was responsible for mortality in laboratory reared African clawed frogs (*Xenopus laevis*). In reptiles, a *Chlamydia* sp. has only been reported by Jacobson et al. (1989) in puff adders (*Bitis arietans*).

Compared to *C. psittaci*, the various strains of poxvirus are considerably more host specific. While poxvirus infections have been reported for captive reptiles (Jacobson et al., 1979; Foggin, 1988; Horner, 1988), nothing is known about this virus in wild populations. Herein, we describe a unique dual infection in a flap-necked chameleon (*Chamaeleo dilepis*) with poxvirus and chlamydial infection.

Over a 4 yr period, 170 representatives of 15 *Chamaeleo* spp. from Tanzania were collected by one of us (S.R.T.) and examined for hemoparasites. Multiple smears were made of blood collected from clipped toe-nails and were stained either by the Giemsa or May-Grunwald Giemsa methods (Garnham, 1966). By light microscopy, three of 50 *C. dilepis* from the vicinity of Morogoro, at the north slope of the Uluguru Mountains in south central Tanzania (6°51′S, 37°38′E) were found to have intraleucocytic inclusions (IN1). Inclusions stained lightly eosinophilic, had a lacy appearance, and often contained a blue-green staining body. Inclusions were intracyto-

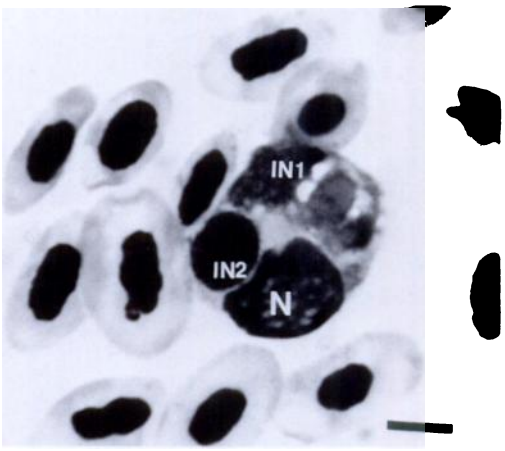

FIGURE 1. Photomicrograph of circulating monocyte of *Chamaeleo dilepis*. In addition to the host cell nucleus (N), two distinct inclusions (IN1 and IN2) can be seen. Giemsa stain. Bar = 10 μm.

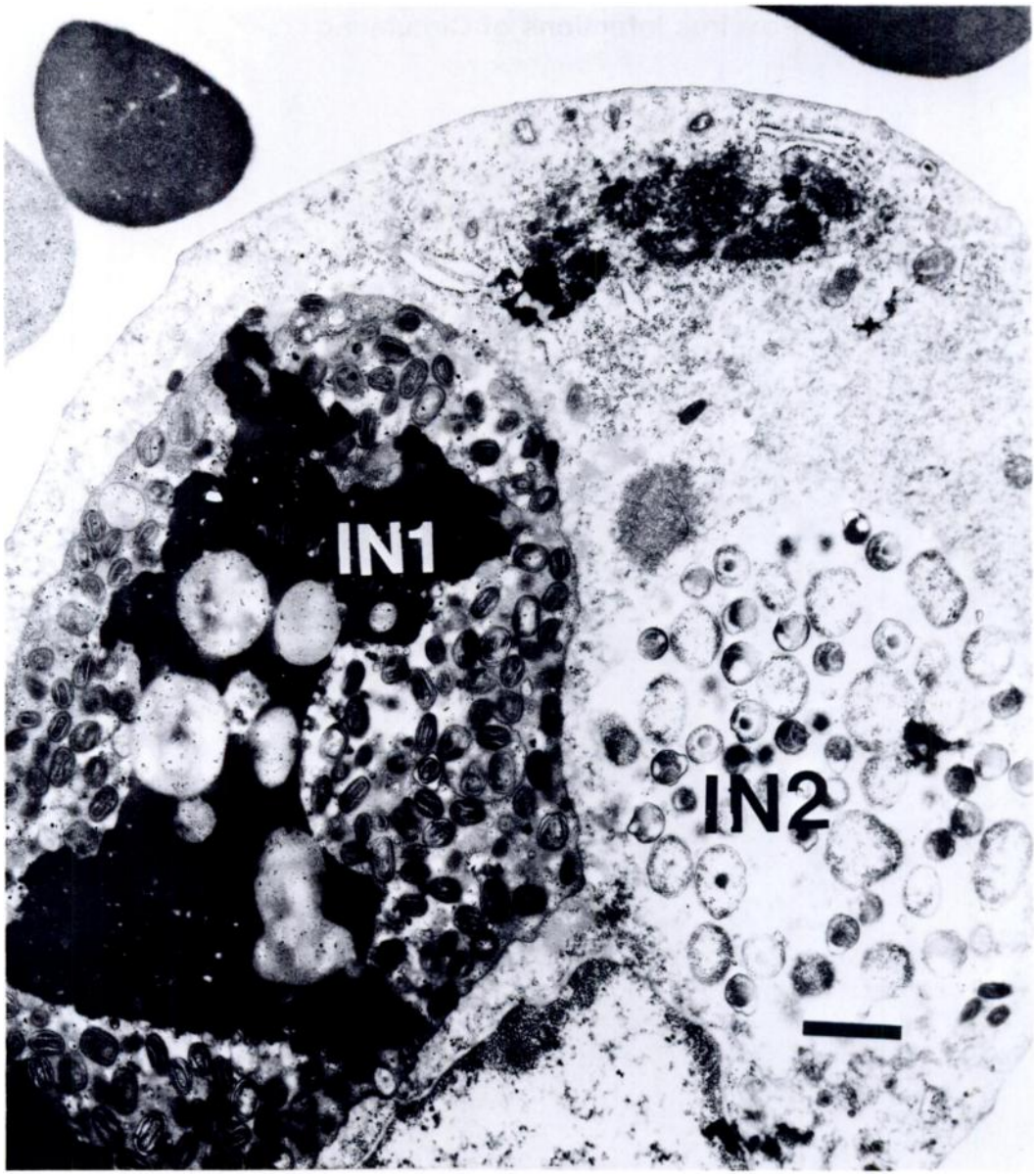

FIGURE 2. Electron photomicrograph of circulating monocyte of *Chamaeleo dilepis*. IN1 is membrane bound and is composed of numerous viral particles. The vacuole membrane of IN2 has ruptured, with organisms free in the cytoplasm. Bar = 1 μm.

plasmic and most infected cells were monocytes. On the day of capture, ≤13% of circulating white blood cells were monocytes and ≤96% of monocytes contained IN1. In one lizard, IN1 was seen also in circulating thrombocytes and lymphocytes.

One of the three infected *C. dilepis* was maintained in captivity and was sequentially bled over a 55 day period. At 46 days following capture, a second type of intracytoplasmic inclusion (IN2) was seen in circulating monocytes, either alone (1%) or in combination (1%) with IN1 (Fig. 1). At 55 days the lizard was found moribund and was euthanatized. At the time of death,

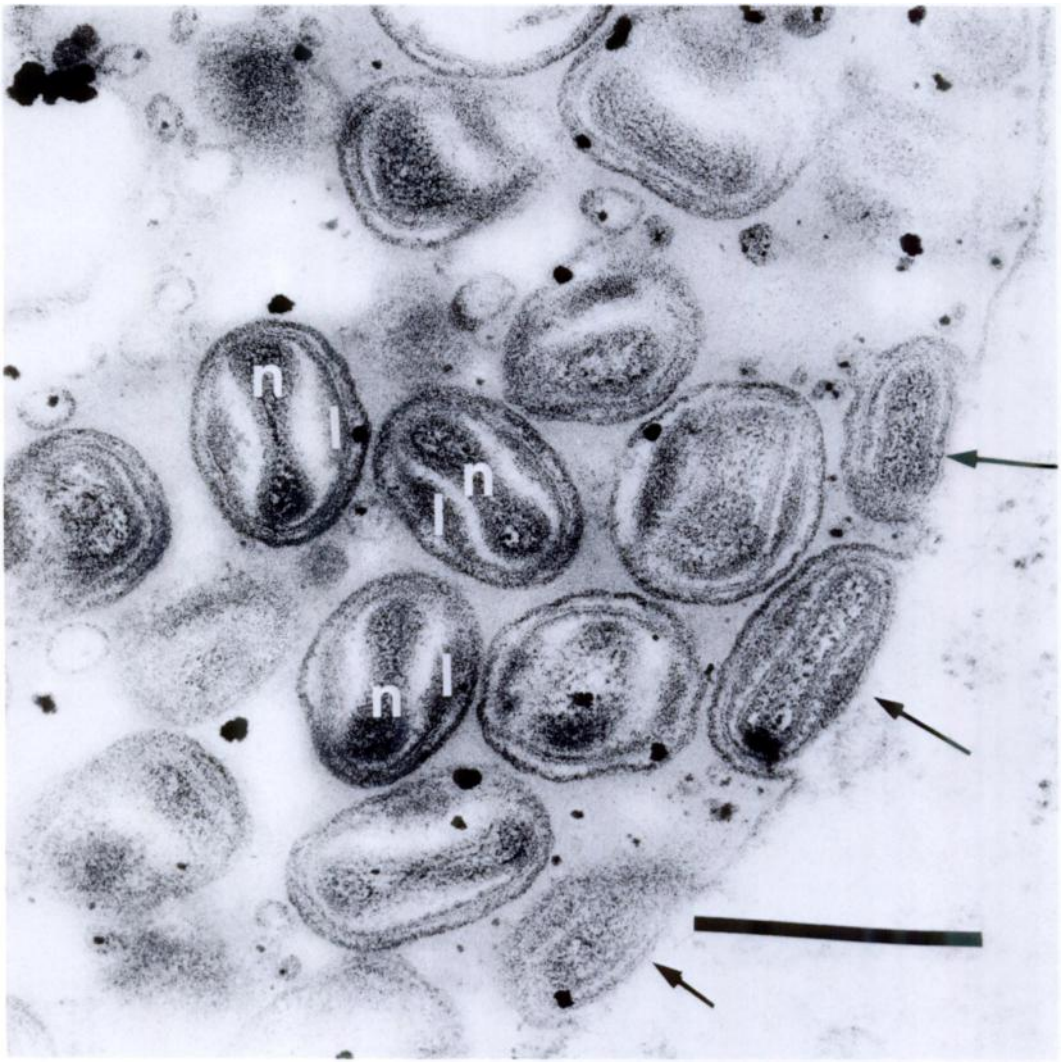

FIGURE 3. Electron photomicrograph of circulating monocyte of *Chamaeleo dilepis*. Mature poxvirus particles are seen within IN1. Features of the group include a dumbbell-shaped nucleoid (n) and lateral bodies (l). Virions partially surrounded by inclusion membranes can be seen (arrows). Bar = 400 nm.

36% of circulating cells were monocytes, of which 88% contained IN1 alone, 11% contained both inclusions, and 1% had IN2 alone. Although packed cell volumes were not determined for estimating white blood cell counts, the relative proportion of monocytes to other leucocytes and red blood cells had increased over the period of sampling and the lizard was considered to have a relative and absolute monocytemia at death. Blood and tissues from all major organ systems were collected and fixed in a buffered 4% formalin/1% glutaraldehyde mixture for light and electron microscopy.

Light microscopy revealed IN1 and IN2 within macrophages in the liver and spleen. Transmission electron microscopy of infected monocytes revealed both types of inclusions (Fig. 2). IN1 was membrane-bound and was composed of a uniform population of 340 to 390 nm by 210 to 235 nm oval-shaped virions containing dumbbell-shaped nucleoids and lateral bodies

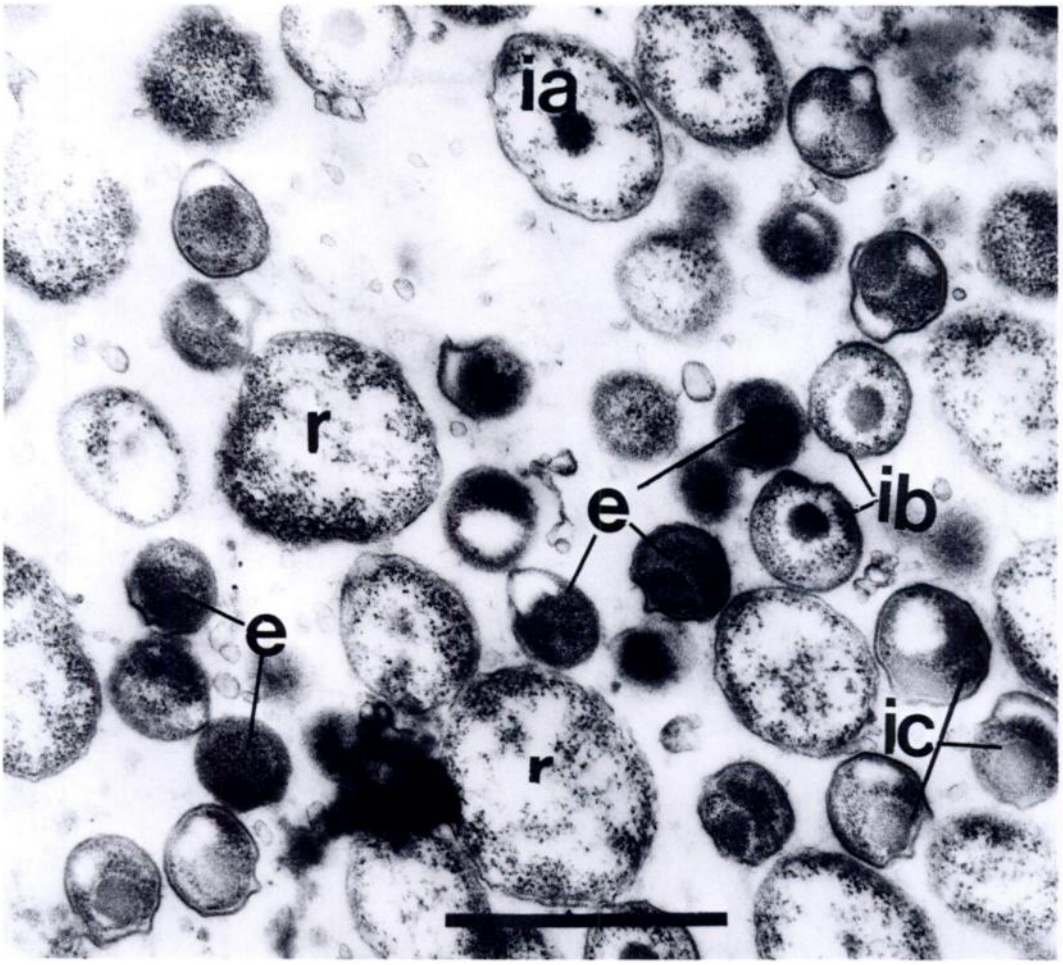

FIGURE 4. *Chlamydia* sp. from a monocyte inclusion of *Chamaeleo dilepis* showing all three developmental stages: large reticulate bodies (r), intermediate bodies in early stage (ia), middle stage (ib), and late stage (ic) of nucleoid condensation; and condensed elementary bodies (e). Bar = 1,000 nm.

(Fig. 3) typical of poxvirus (Dales and Pogo, 1981). IN2 was composed of pleomorphic bodies compatible with the three stages of chlamydiae (Moulder, 1984): (1) large oval, 800 to 900 nm reticulate bodies; (2) contracted 440 to 680 nm intermediate bodies containing an electron-dense center; and (3) small, round, dense 400 to 440 nm elementary bodies (Fig. 4). In most cells the membrane surrounding the *Chlamydia* sp. had ruptured, so that the organisms were free in the cytoplasm. Unfortunately, tissues were unavailable for chlamydial isolation and specific identification was not made.

IN1 was similar in appearance to inclusions described for *Chamaeleo lateralis* from Madagascar (Brygoo, 1963). Although these were considered to be viral inclusions, ultrastructural studies were not done. While transmission was accomplished with oral and intraperitoneal inoculations of infected white blood cells to naive *C. lateralis*, attempts to infect other species of chameleons were unsuccessful.

Poxviral inclusions within circulating white blood cells have not previously been reported for any animal. In the chameleons, inclusions were seen primarily in monocytes with one of the three lizards having relatively few inclusions in thrombocytes and lymphocytes. In vitro studies

have shown that there are differences in the susceptibility of human blood cell lines to vaccinia poxvirus (Pogo et al., 1988). While HL_{60} cells (derived from peripheral blood leukocytes of a patient with acute promyelocytic leukemia) infected with vaccinia virus showed a decrease in virus infectivity with time, cells induced to become macrophages with TPA (12-0-tetradecanoylphorbol-13-acetate) resulted in an increase in viral DNA synthesis. It is unknown whether these differences in cell susceptibility are because of presence of endogenous chemical inhibitors of viral replication or lack of a host factor essential for replication.

In the chameleon, the poxvirus inclusions were membrane bound and in this regard were different from inclusions of other poxviral infections of vertebrates and invertebrates. Within inclusions, blue-green staining bodies seen by light microscopy were found by electron microscopy to be composed of a uniformly radiodense material. Vacuoles containing mature poxvirus surrounded this material and the material was consistently devoid of virions.

Peculiar to the maturation process of the poxvirus within monocytes of the chameleon, particles which initially formed in the cytoplasm adjacent to the inclusions acquired another envelope by moving through the membrane surrounding the inclusion. While the poxvirus inclusions in the chameleon showed some similarities to A-type inclusions seen in cowpox, ectromelia, fowl pox and insect poxvirus infections (Dales and Pogo, 1981), A-type inclusions are not membrane bound.

What is most intriguing about the coinfection of monocytes of *C. dilepis* with *Chlamydia* sp. and poxvirus was the intensity of the infection. At the time of death, the lizard exhibited a monocytemia with all monocytes infected with one or both pathogens. This massive infection probably contributed to the moribund condition of the lizard. As with poxviral inclusions, chlamydial inclusions have not been reported to occur in circulating white blood cells of any animal and are seldom appreciated in hematoxylin and eosin stained tissue sections in mammals and birds. In *Xenopus laevis* (Newcomer et al., 1982) and *C. dilepis*, inclusions were seen in impressive numbers in the liver and spleen. At least on a light microscopic level these organisms appear to replicate to a much greater degree in their poikilothermic hosts than in mammals and birds. Whether this is due to strain differences or immunologic differences between reptiles and amphibians and higher vertebrates needs to be elucidated. Chameleons may serve as an interesting model to study infection of circulating blood cells with these two pathogens, and since the body temperatures of these animals can be environmentally manipulated, to allow in vivo developmental studies unavailable in higher vertebrates.

This paper is published as University of Florida, College of Veterinary Medicine Journal Series Number 187.

LITERATURE CITED

ANDREWES, C., H. G. PEREIRA, AND P. WILDY. 1978. Viruses of vertebrates. Bailliere Tindall, London, England, 421 pp.

BRYGOO, E. R. 1963. Contribution a la connaissance de la parasitologie des chamelons malgaches (2° partie). Annales de Parastologie Humaine et Comparee 38: 335–739.

DALES, S., AND B. G.-T. POGO. 1981. Biology of poxviruses. Springer-Verlag, New York, New York, 109 pp.

FOGGIN, C. M. 1988. Diseases and disease control of crocodile farms in Zimbabwe. *In* Wildlife management, crocodiles and alligators, G. J. W. Webb, S. C. Manolis, and P. W. Whitehead (eds.). Surrey Beatty and Sons Pty. Limited, New South Wales, Australia, pp. 351–362.

GARNHAM, P. C. C. 1966. Malaria parasites and other hemosporidia. Blackwell Scientific Publications, Oxford, England, 1114 pp.

GRAYSTON, J. T., C-C. KUO, L. A. CAMPBELL, AND S-P. WANG. 1989. *Chlamydia pneumoniae* sp. nov. for *Chlamydia* sp. strain TWAR. International Journal of Systematic Bacteriology 39: 88–90.

HORNER, R. E. 1988. Poxvirus in farmed Nile crocodiles. Veterinary Record 1988: 459–461.

JACOBSON, E. R., J. M. GASKIN, AND J. M. MANSELL.

1989. Chlamydial infection in puff adders (*Bitis arietans*). Journal of Zoo and Wildlife Medicine 20: 364–369.

———, J. A. POPP, R. P. SHIELDS, AND J. M. GASKIN. 1979. Pox-like skin lesions in captive caimans. Journal of the American Veterinary Medical Association 175: 937–940.

MOULDER, J. W. 1984. Chlamydiaceae. *In* Bergey's manual of systematic bacteriology, N. R. Kreig and J. G. Holt (eds.). William and Wilkins, Baltimore, Maryland, pp. 729–739.

NEWCOMER, C. E., M. R. ANVER, J. L. SIMONS, W. WILCKE, AND G. W. NACE. 1982. Spontaneous and experimental infections of *Xenopus laevis* with *Chlamydia psittaci*. Laboratory Animal Science 32: 680–686.

POGO, B. G.-T., A. C. K. LAI, J. G. HOLLAND, AND C. FRIEND. 1988. Differences in the susceptibility of human blood cell lines to vaccinia virus. Intervirology 29: 11–20.

STORZ, J. 1971. Chlamydia and chlamydia-induced diseases. Thomas, Springfield, Illinois, 376 pp.

Received for publication 12 December 1989.