

Herpesviruses Detected in Papillomatous Skin Growths of Koi Carp (*Cyprinus carpio*)

Authors: Hedrick, R. P., Groff, J. M., Okihiro, M. S., and McDowell, T. S.

Source: Journal of Wildlife Diseases, 26(4) : 578-581

Published By: Wildlife Disease Association

URL: <https://doi.org/10.7589/0090-3558-26.4.578>

BioOne Complete (complete.BioOne.org) is a full-text database of 200 subscribed and open-access titles in the biological, ecological, and environmental sciences published by nonprofit societies, associations, museums, institutions, and presses.

Your use of this PDF, the BioOne Complete website, and all posted and associated content indicates your acceptance of BioOne's Terms of Use, available at www.bioone.org/terms-of-use.

Usage of BioOne Complete content is strictly limited to personal, educational, and non - commercial use. Commercial inquiries or rights and permissions requests should be directed to the individual publisher as copyright holder.

BioOne sees sustainable scholarly publishing as an inherently collaborative enterprise connecting authors, nonprofit publishers, academic institutions, research libraries, and research funders in the common goal of maximizing access to critical research.

Herpesviruses Detected in Papillomatous Skin Growths of Koi Carp (*Cyprinus carpio*)

R. P. Hedrick, J. M. Groff, M. S. Okihiro, and T. S. McDowell, Department of Medicine, School of Veterinary Medicine, University of California, Davis, California 95616, USA

ABSTRACT: Herpesviruses were found associated with epidermal hyperplasia of koi carp (*Cyprinus carpio*) in northern California (USA). Papillomas were found principally on the caudal regions of the fish including the fins. The growths occurred most commonly in the fall and winter among populations of captive carp. Infected epidermal cells were characterized by greatly enlarged nuclei depleted of chromatin but with thickened nuclear membranes. Numerous virions were detected in infected cells. Herpesvirus nucleocapsids in the cell nucleus had a diameter of 109 nm. Virions with envelopes with a diameter of 157 nm were abundant in cytoplasmic vacuoles. The characteristics of the papillomatous growths and the viruses were consistent with descriptions of *Herpesvirus cyprini* known in koi carp populations in Japan and extends the range of this pathogen to koi carp to North America.

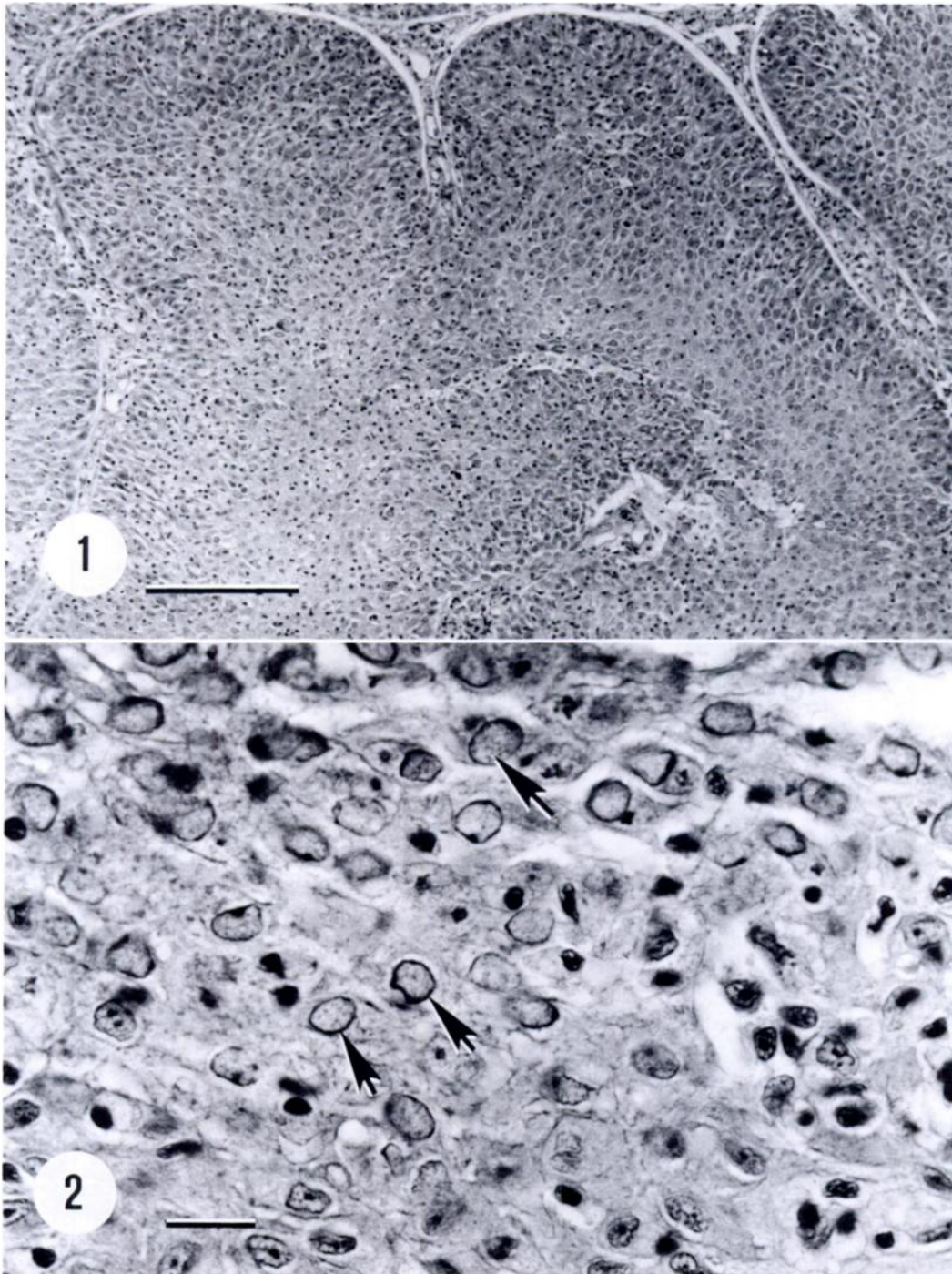
Key words: Koi carp, papillomas, herpesvirus, epidermal hyperplasia, *Cyprinus carpio*, *Herpesvirus cyprini*.

Herpesviruses are the most commonly encountered DNA viruses in teleost fish. At least 16 distinct herpesviruses have been isolated or identified by electron microscopy from fish (Hedrick and Sano, 1989). Most of the herpesviruses are associated with proliferative conditions of the epidermis although several others cause significant systemic diseases (Hedrick and Sano, 1989).

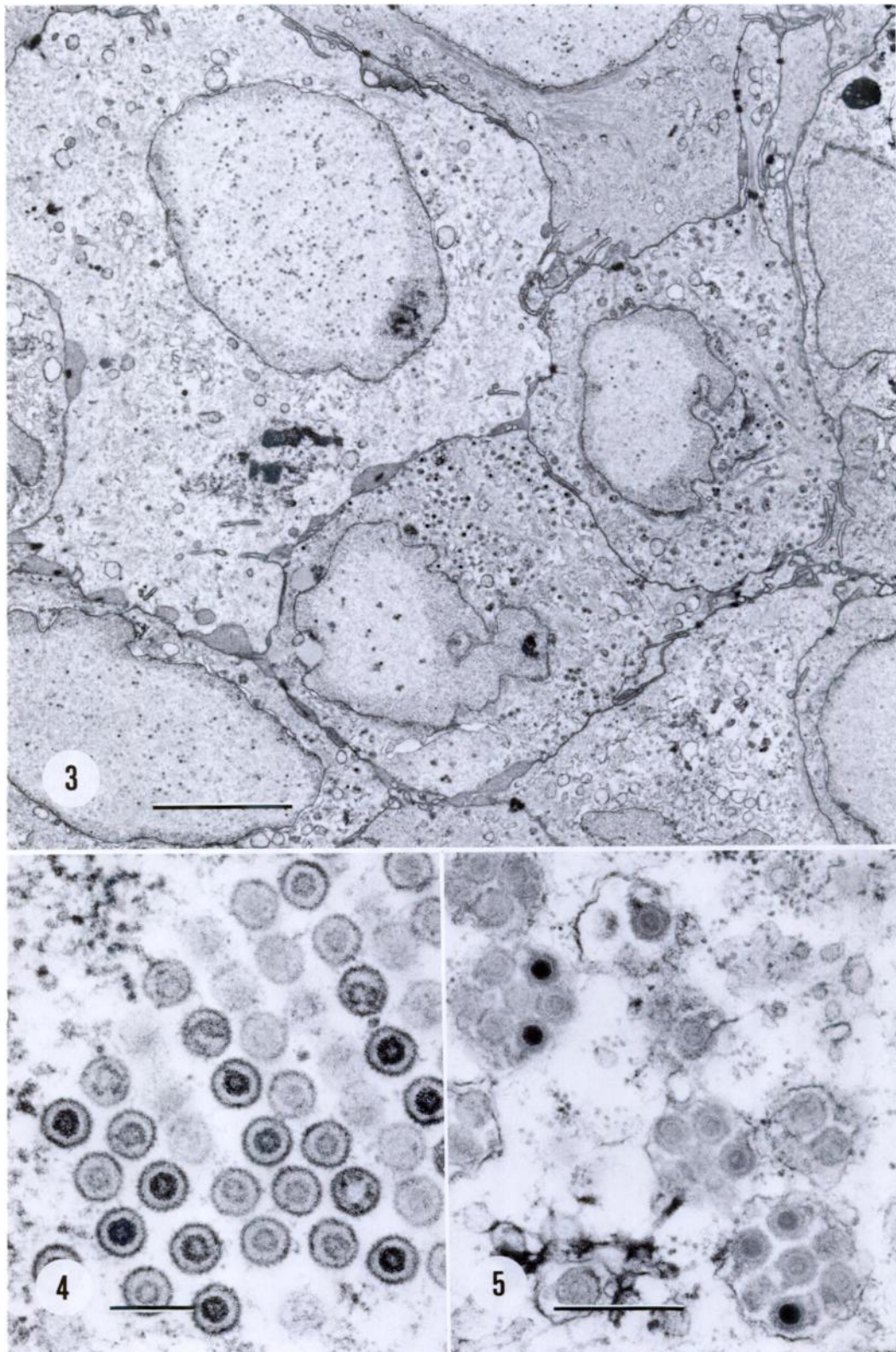
Koi or fancy carp (*Cyprinus carpio*) are a very popular ornamental fish in California (USA). There are several major producers and many hobbyists rearing koi carp in earthen or small concrete ponds. Several serious diseases have affected koi carp in California as observed in the past 5 yr during routine disease diagnostic activities of the University of California, Fish Disease Diagnostic Laboratory (Davis, California 95616, USA). The most common skin diseases are ulcerative epidermal infections

with gram-negative bacterial pathogens, principally *Aeromonas* spp. (including *A. hydrophila*, *A. salmonicida* and *A. sobria*) and a more benign but cosmetically compromising epidermal hyperplasia. Epidermal hyperplasias are most prevalent in the late fall and winter as water temperatures decline. These growths are self limiting and regress with a seasonal pattern as temperatures increase in the spring. However, attempts to observe or isolate herpesviruses as reported for other papillomatous skin conditions in several species of fish, including koi carp in Japan (Sano et al., 1985a, b), have been unsuccessful.

In November of 1989, a 3-yr-old koi carp was brought to the laboratory because of shallow ulcerative lesions on the head. The fish was from an 8,000 L outside concrete pond with a water temperature of 12 C. Several mucoid to white, raised growths (3 × 7 mm) were observed on the skin of this carp, principally located in the caudal areas including the caudal fin. These growths were removed with a scalpel with no injury to the fish, and portions fixed for light and electron microscopy. Tissue fixed for light microscopy was fixed in Davidson's solution (Humason, 1979) for 12 hr, processed for routine paraffin embedding, sectioned and stained with hematoxylin and eosin. A small piece of the fresh tissue was also placed into 2.5% glutaraldehyde in 0.1 M cacodylate buffer (pH 7.4) and fixed for 24 hr at 4 C. The tissue was rinsed twice in buffer and then post-fixed in 1% aqueous OsO₄, dehydrated through a graded ethanol series, infiltrated and embedded in epoxy medium. Thin sections (10 to 20 nm) were stained with uranyl acetate and lead citrate prior to examination with a Phillips EM 400 electron microscope at



FIGURES 1, 2. Papillomatous skin growths on koi carp (*Cyprinus carpio*) associated with herpesvirus infections. (1) Folds of the affected epidermal tissue, bar = 200 μm . (2) Enlarged nuclei of herpesvirus-infected cells in the papilloma, bar = 20 μm . H&E.



80 kV. A third portion of the fresh tissue was processed by standard methods for virus isolation and then inoculated onto FHM and EPC cells at 20 C (Amos, 1985).

Light microscopy of affected tissues showed that the growth was principally a hyperplasia of epidermal cells thrown into large papillomatous folds (Fig. 1). The nuclei of these cells were greatly enlarged (Fig. 2). Chromatin was depleted in the center of the nucleus but margination at the nuclear membrane was evident (Figs. 2, 3). There was no evidence of nuclear inclusions. Electron microscopy showed numerous virions both in the nucleus and cytoplasm (Figs. 3–5). Nucleocapsids without envelopes were abundant in affected nuclei and arranged into a loose crystalline appearance (Fig. 4). The nucleocapsids had a mean diameter of 109 nm ($n = 10$, SD = 2.6 nm), were circular to hexagonal, had a rough appearance due to protruding capsomeres and possessed a circular electron dense core (58 nm diameter). Enveloped virions with a mean diameter of 157 nm ($n = 10$, SD = 15.9 nm) were found in cytoplasmic vacuoles (Fig. 5).

The size and shape of the virions were consistent with previous observations of herpesviruses associated with skin hyperplasias including that described for koi carp in Japan by Sano et al. (1985a). Sano et al. (1985a) were able to isolate a herpesvirus from koi carp with epidermal hyperplasia by inoculating two cyprinid cell lines (EPC and FHM) with filtrates from the affected tissues. The diameter of the nucleocapsids and enveloped virions they observed were 113 and 190 nm, respectively. They were later able to demonstrate that the virus, *Herpesvirus cyprini*, was pathogenic for younger carp and survivors were found to develop similar skin growths from which

the virus was originally isolated (Sano et al., 1985b). Although we were unable to isolate the virus using the methods described by Sano et al. (1985a), we presume that the herpesvirus we have observed is similar or identical to *H. cyprini* and extends the geographic range of the virus to North America. Although this is the first report of *H. cyprini* in koi carp in North America, McAllister et al. (1985) have observed similar virus particles in the cyprinid, golden ide (*Leuciscus idus*), imported from Europe. We suspect, as with the golden ide herpesvirus, that the koi herpesvirus has been imported to California from Japan with the popular fancy carp. Further attempts to isolate the virus and to examine its potential pathogenicity for young carp are under investigation.

LITERATURE CITED

- AMOS, K. 1985. Procedures for the detection and identification of certain fish pathogens, 3rd ed. Fish Health Section Blue Book, American Fisheries Society, Corvallis, Oregon, 114 pp.
- HEDRICK, R. P., AND T. SANO. 1989. Herpesviruses of fish. In *Viruses of lower vertebrates*, W. Ahne and E. Kurstak (eds.), Springer-Verlag, Berlin, Federal Republic of Germany, pp. 161–170.
- HUMASON, G. L. 1979. Animal tissue techniques. W. H. Freeman Co., San Francisco, California, 661 pp.
- MCALLISTER, P. E., B. C. LIDGERDING, R. L. HERMAN, L. C. HOYER, AND J. HANKINS. 1985. Viral diseases of fish: First report of carp pox in golden ide (*Leuciscus idus*) in North America. *Journal of Wildlife Diseases* 21: 199–204.
- SANO, T., H. FUKUDA, M. FURUKAWA, H. HOSOYA, AND Y. MORIYA. 1985a. A herpesvirus isolated from carp papilloma in Japan. In *Fish and shellfish pathology*, A. E. Ellis (ed.), Academic Press, London, England, pp. 307–311.
- , ———, AND ———. 1985b. *Herpesvirus cyprini*: Biological and oncogenic properties. *Fish Pathology* 20: 381–388.

Received for publication 5 February 1990.

FIGURES 3–5. Electron micrographs of herpesvirus-infected epidermal cells from koi carp (*Cyprinus carpio*). (3) Enlarged cells within the papilloma showing distended nuclei, bar = 5 μ m. (4) An array of nucleocapsids within the nucleus of an infected cell, bar = 200 nm. (5) Enveloped virions with electron dense cores within cytoplasmic vacuoles of infected cells, bar = 500 nm.